

## **HYDROXYAPATITE CEMENT VERSUS AUTOLOGOUS ABDOMINAL FAT IN OBLITERATION OF FRONTAL SINUS AFTER TRAUMA**

Hesham Fattouh\*

### ***ABSTRACT***

**Objectives:** To assess the efficacy of the hydroxyapatite (HA) cement alone or with simvastatin in obliteration of the frontal sinus after trauma as an alternative to the widely used autologous abdominal fat.

**Patients and Methods:** 4 out of 9 patients underwent frontal sinus obliteration with autologous abdominal fat (Fat group) and the remaining 5 patients were obliterated with HA cement (HA group) where 2 patients out of those 5 patients were obliterated with HA alone and the remaining 3 patients of this group were obliterated with HA cement mixed with simvastatin as an osteoinductive material.

**Results:** Both the autogenous fat and the HA cement has a comparable results; Fat obliteration failed in 1 patient and none of the patients in the HA cement group has acquired any complications that necessitates the material removal, no significant difference in the results obtained from the HA cement when used alone or when mixed with simvastatin.

**Conclusion:** HA cement is a promising obliterating material in frontal sinus obliteration with comparable results to autogenous fat with the advantages of no donor site morbidity and the potential for complete osseointegration. Addition of simvastatin to the HA cement does not seem to enhance the obtained results.

**KEYWORDS:** Trauma, frontal sinus obliteration, fat, hydroxyapatite, simvastatin.

### **INTRODUCTION**

Frontal sinus (FS) fractures usually occur in head trauma as a result of great force and record for 5–15% of all maxillofacial injuries. Despite the relative infrequency, these fractures have enormous catastrophic consequences extending from aesthetic

complications to life-threatening sequel due to the proximity to the orbit and the brain. Serious complications of FS fractures include cerebrospinal fluid (CSF) leak, encephalitis, meningitis, chronic sinusitis, brain abscess, occlusion of the drainage pathway and mucocele formation <sup>(1)</sup>.

\* Lecturer of Oral and Maxillofacial Surgery, Faculty of Oral and Dental Medicine, Cairo University.

FS fracture management remains a controversial issue with no single algorithm for the choice of management, however proper treatment relies upon an accurate diagnosis utilizing physical examination, computed tomography (CT) information and the findings of intraoperative exploration. The amount and location of fixation and the need for obliteration of the nasofrontal duct (NFD) and the FS rely upon the anatomy of the fracture in general and the degree of involvement of the anterior table of the sinus, the NFD and the posterior table in specific. The most common debate associated with FS trauma is the type of material utilized for FS obliteration. Definitive studies on the best, most efficacious material do not exist as long-term follow-up in patients with FS fractures is hard to achieve <sup>(2)</sup>.

Non displaced or minimally displaced (< 1-2 mm) isolated anterior table fractures can be managed conservatively with analgesics and local wound care, as they rarely lead to functional or aesthetic disability, or mucocele development, while displaced fractures greater than 1-2 mm require surgical intervention to secure intracranial contents mainly by obliteration of the NFD and FS, restoration of aesthetic and forehead contour, and the return of FS function. Obliteration of the FS is currently done using autogenous fat, bone and different alloplastic materials <sup>(3)</sup>.

The technique of obliteration with freshly harvested abdominal fat dates back to **Bergara and Tato et al.** <sup>(4-5)</sup>. Later **Goodale and Montgomery** established the osteoplastic flap technique with fat obliteration as the standard approach for dealing with difficult FS fractures. According to Montgomery, the complication rate in FS obliteration using fat is 18%, including wound complications, abdominal donor site morbidity, postoperative infections, fat necrosis and recurrent chronic sinusitis <sup>(6)</sup>.

The advantages of using synthetic materials in FS obliteration are the avoidance of both the donor site morbidity and also the prolongation of operation time needed to harvest the autograft. Different synthetic

materials can be utilized as; Glass ionomer cement, Proplast, Bioactive Glass, tricalcium phosphate and hydroxyapatite (HA) cement <sup>(7)</sup>. In addition to its favorable tissue interaction, HA cement can be easily shaped and contoured, sets in just 15 minutes and changes to solid HA in around 4 to 6 hours <sup>(8)</sup>. Reported utilization of HA cement include, dental augmentation, frontal sinus obliteration and other cranial defect reconstruction, as it has been effectively used to shape and contour different skull defects including reconstruction of the fronto-facial skeleton <sup>(9)</sup>.

Simvastatin is an osteoinductive material that can stimulate osteoprogenitor cells proliferation and furthermore up – regulate the bone morphogenic protein (BMP-2) production by osteoblast, it was first mentioned by **Mundy et al** in 1999 <sup>(10)</sup>. Beside its direct effect on bone, statins are additionally known for owing other biological properties that has a critical role in inducing bone formation as angiogenic and anti-inflammatory properties <sup>(11)</sup>. It was also concluded that the local application of statins were 50–80 times more effective in inducing bone formation than if infused subcutaneously or given orally <sup>(12)</sup>.

## PATIENTS AND METHODS

This study was performed on patients suffering from FS fractures and indicated for surgical intervention. Patients were selected from the outpatient clinic of Nasser Institute Hospital. Patients were categorized into two groups according to the intended material to be used for the FS obliteration; group I (Autogenous Fat group) consisted of 4 patients where the FS was obliterated with freshly harvested autogenous abdominal fat, while group II (HA group) consisted of 5 patients where the FS was obliterated with HA cement. In 3 out of 5 patients of the HA group, the obliterating HA cement was mixed with simvastatin as an osteoinductive material. The healing process and associated postoperative complications to patients of both groups were monitored, recorded and compared.

### Surgical procedures for FS obliteration

Standard bicoronal flaps were the favored access in all the cases with an exception of one patient in each group where access to the frontal bone and sinus is carried out through extensive facial laceration. All surgeries were performed with the same team of surgeons; the bicoronal flap was done via a conventional skin flap which is then dissected anteriorly in the sub-galeal plane to the level of the supraorbital rims to adequately expose the frontal bone together with preservation of both the supratrochlear and the supraorbital nerves. A high-speed oscillating saw was then used to expel the anterior table to be stored in normal saline. Then remnants of the FS mucosa are meticulously removed with diamond drill or cutting bur. The NFD was then visualized, fascia was harvested for closing the duct and to ensure its proper sealing, fibrin glue was added to the fascia. Posterior fractures with huge intracranial involvements are cranialized and dural tears are repaired if necessary with excluding of these patients from the current study (Fig. 1).

### Group I: (Autogenous fat group)

Abdominal fat is harvested by means of a 4 cm transverse, midline incision below the umbilicus, care was taken to limit the dissection superficial to the abdominal muscular fascia. Sufficient amount of fat is gained and used to pack the sinus and then the wound is closed in a layered fashion (Fig. 2).

### Group II: (HA group)

The HA cement (*Stryker Biotech Europe, Montreux, Switzerland*) (*BoneSource group*) was acquired by mixing into a paste 5-g units of sterile HA powder with nearly 0.3 mL of sterile water per gram of powder to obtain a 'damp and paste like' mixture. In 3 patients of this group the acquired paste was mixed with simvastatin as an osteoinductive material, where the simvastatin powder was dissolved in 97% ethanol. Then, the solution was applied by a dropper to the HA cement so that a 0.1mg simvastatin was added for each 14mg OH cement, afterwards ethanol was left to evaporate completely (The entire operation was done under totally sterile condition).

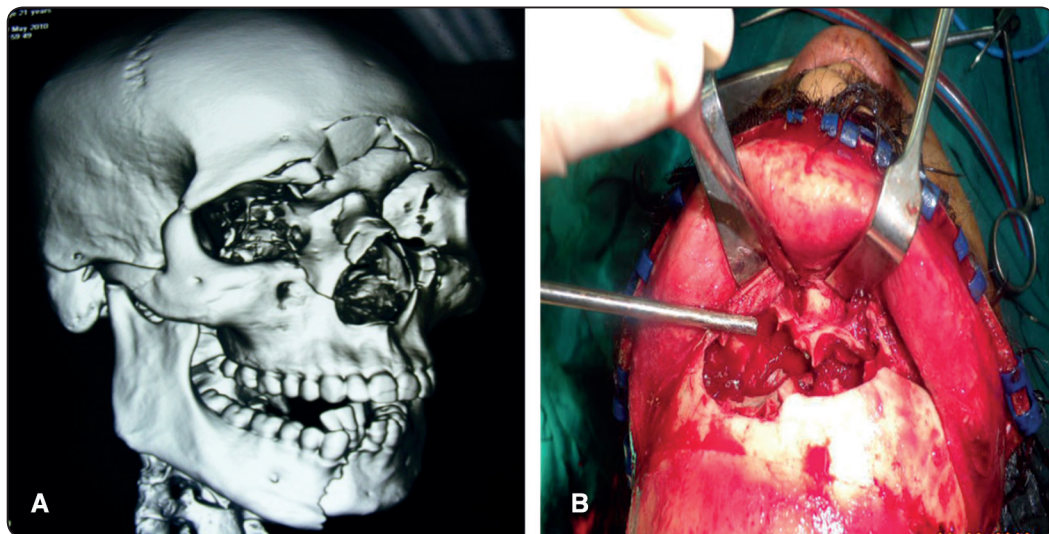


Fig. 1 (A): Preoperative 3d CT scan showing frontal bone fracture (B): access to the FS via bicoronal flap

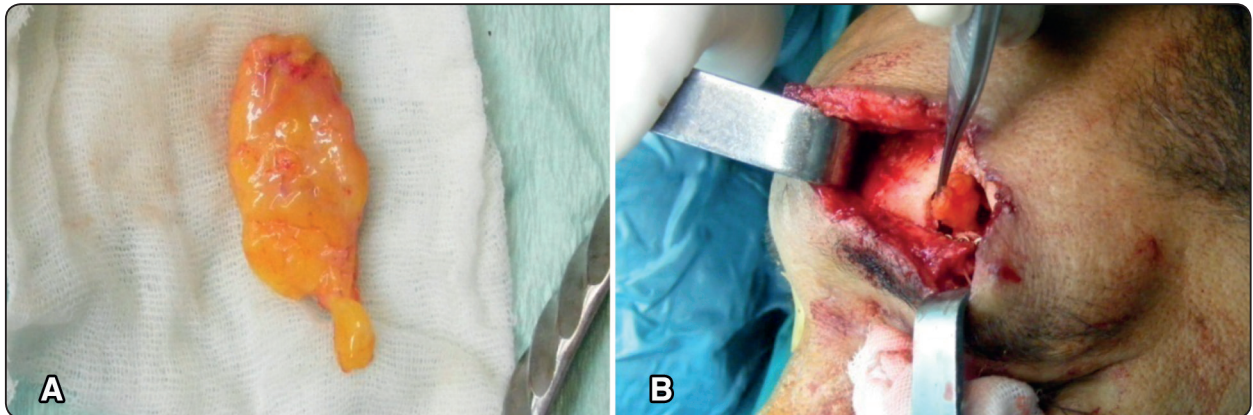


Fig. 2 (A): Autogenous abdominal fat (B): frontal sinus obliteration with fat via existing laceration

After the mixture was obtained, silastic sheets were cut and set against the periorbital allowing for proper contouring of the orbital roof by providing an even surface for the cement to dry against and so avoiding adhesion of the HA cement against the eye, which may prompt fibrosis later on, then the sinus was packed with dry gauze to keep the cavity dry. The empty frontal sinuses were gradually filled while leaving the material to dry for 10 to 15 minutes.

In both groups, the coronal flaps were replaced after periosteal suturing, a suction drain was put for 24 hours, and irregularities in the forehead and the supraorbital region were checked. Skin sutures and staples are expelled after 10-14 days. The frontal table was replaced and reconstructed as ideal as possible and rigidly fixed with miniplates and screws if it was appropriate, when it is missing

or insufficient, either a titanium mesh in group I or the viscous HA cement itself in group II was used to contour the space previously occupied by the anterior table (Fig. 3).

### Follow-up

Postoperative assessment was done both clinically and radiographically. The clinical assessment included the healing process and any associated complications as headache/chronic pain, sinusitis and hypoesthesia related to the frontal region were recorded at 1 week, 1, 3 and 6 months. The radiographic assessment using CT was done twice; at 1 week and 6 months postoperatively. Statistical analysis of the data was done using SAS statistical software (SAS Institute Inc, Cary, NC). A t-test with a *P*-value of less than 0.05 denotes clinical significance.

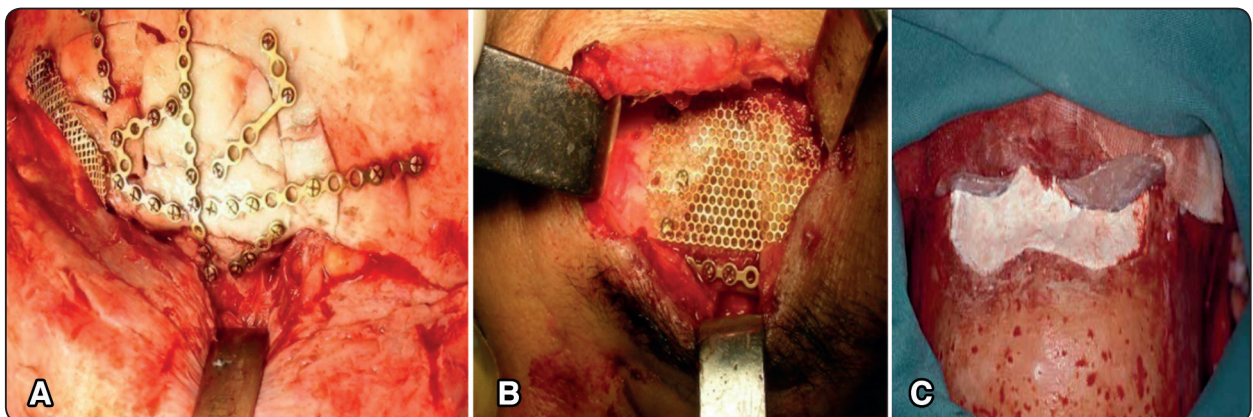


Fig. (3) Anterior table reconstruction with: (A): miniplates (B) titanium mesh (C): HA cement

## RESULTS

The fat obliteration group included 3 men and 1 woman, with a mean age of 47.5 years. While all the victims of the HA cement group were men with a mean age of 42.6. All the patients suffered from road traffic accident except 1 patient of group II where a work accident was the responsible of his injury. Injury of the NFD was found in 1 patient of group I and 2 patients of group II. Moderate displacement of the anterior table was observed in patients of both groups with average dislocations between 2mm and 5mm with the exception of 1 patient of each group where severe displacement with dislocations of more than 5mm was observed.

Regarding the postoperative complications; they were mostly short-term; moderate swelling and pain in nearly all of our patients, the degree of postoperative complications that occurred in the 2 groups was very comparable with no statistical significance between the 2 groups ( $P = 0.7236$ ).

One patient in group I experienced persistent discomfort in the frontal area after the obliteration. The discomfort was related to the miniplates used for fixation of the anterior table and, thus, the plates were removed, there were abdominal wound complications in one patient of group I with acute postoperative infection requiring wet-to-dry dressing changes. Postoperative hematoma was observed in only 1 patient of group II and it was resolved with conservative, non surgical management.

Except for the fore-mentioned complications, there were no significant symptoms; none of the patients suffer from persistent pain or persistent neuralgia. No significant esthetic deformities were reported by the patients. No hair loss was recorded.

The CT radiologic evaluation at 1 week and 6 months postoperative recorded the FS obliterations and the rate of bone replacement for the obliterating

materials over time, It was found that successful FS obliteration with no volume loss were recorded in all the patients except one patient in group I who had insufficient FS obliteration. For this patient FS re-obliterations were done (**Figure 4**). In group II there were no statistical significance in the amount of bone formation between the patients who received local simvastatin and those who do not receive this osteoinductive material ( $P = 0.482$ ).

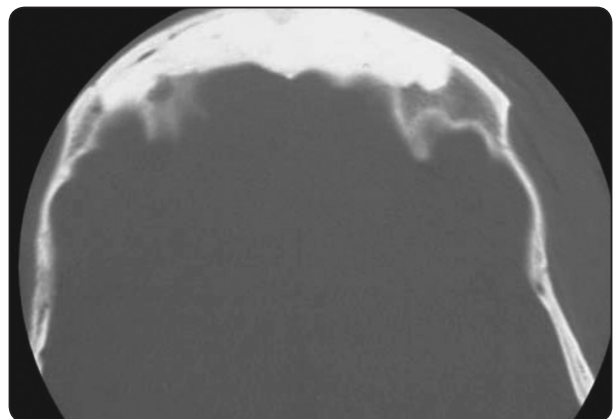


Fig. (4) Axial CT scan of a patient in group II showing FS obliteration after 6 months

## DISCUSSION

The best treatment of FS fractures is controversial. This is due to the fact that sequelae may take numerous years to happen and involve intra cranial structures with serious consequences. The objective of treatment, on the other hand, are well known: Surgery, if indicated should create a "safe" sinus and restoring sinus function or remove the sinus either by obliteration or cranialization, as well as recover good aesthetics <sup>(2)</sup>. Basic principles for successful sinus obliteration include: Careful removal of all visible mucosa as well as expulsion of the inner cortex of the sinus wall, permanent occlusion of the NF duct utilizing material that forms a strong barrier between the obliterated sinus and the nasal cavity <sup>(13)</sup>.

The cosmetic result was satisfactory in all the patients managed with the bicoronal flap; it is usually esthetic and faultless. On the other hand using a pre-existing laceration was much faster but with less esthetic results accomplished. While the use of tissue glue with the fascia and then waiting for the glue to dry for obliterating the NF duct before placing the FS obliterating material might be the corner stone for ensuring perfect duct occlusion.

Ideal material for effective obliteration of the FS should be accessible at any time and in any amount, easy to handle, economical, should not cause a foreign-body reaction, maintain a stable size and shape over time, easily contoured, allow future diagnostic radiography, and be non carcinogenic, non allergic, and eliminate disease transmission and donor morbidity<sup>(14)</sup>. As evidenced by the data, HA cement has shown promising results in many of the criteria listed above<sup>(9)</sup>.

Our results confirm the high success rate of FS with abdominal fat obliteration with minimum postoperative complications as first presented in Argentina by **Bergara and Itoiz**<sup>(15)</sup>, they hypothesized that a part of the implanted fat would progress toward becoming vascularized and could resist postoperative infections, while the portion of the graft that did not survive would be gradually replaced with fibrous tissue. Later, FS obliteration with abdominal fat was popularized by **Goodale and Montgomery**<sup>(16)</sup>; their study obtained a near 100% survival of the fat graft following an atraumatic harvesting technique with immediate grafting before drying of the graft.

Also in the same context, **Calcaterra and Strahan**<sup>(17)</sup> reported the high success rate of fat obliteration to the FS, they declared that 23 of 24 patients with fat obliteration (after clearing the sinus of mucosa and plugging the NF duct with fascia) were cured from chronic sinusitis, with no known instance of recurrence, **Hardy and Montgomery**<sup>(18)</sup> also experienced low postoperative complication rate after use of fat in FS obliteration similar

to what we had, they reported autogenous fat graft complications in FS surgery in a group of 250 patients. 208 of those patients required FS obliteration with abdominal fat including 25 for traumatic causes. Only 13 (6.3%) experienced complications associated with the abdominal wound (abscess, hematoma and seroma) and 5 patients (2.4%) had acute FS wound infection associated with fat necrosis.

Unlike our results, **R. Weber et al.**<sup>(19)</sup> had experienced bad results with the fat obliteration of the FS with clinical failure rates of up to 10% and long term resorption rates of up to 80%, as evaluated by magnetic resonance imaging. **Costantino et al.**<sup>(14)</sup> first reported the use of HA cement in FS obliteration in an experimental model. These studies demonstrated the osteoconductive properties of the material, its ability to resist mucosal ingrowth, and its gradual substitution by local bone without loss of HA cement volume, The data gathered during this experimental work formed the foundation for subsequent human clinical trials showing the efficacy and the safety of this compound, in addition, the HA cement has a few points of interest as an alloplast for craniofacial augmentation. HA naturally makes up 60% to 70% of bone substance and, unlike numerous other alloplastic materials available today, HA do not trigger an inflammatory or foreign body response because of their high biocompatibility. Their osteoconductibility combined with the absence of adverse soft tissue response, significantly decreases the risk of rejection, also it has been shown that, over time, the HA cement is replaced by bone without volume loss<sup>(14)</sup>.

A great advantage of the HA cement, and dissimilar to autologous materials that require the FS table to remain intact, this material is ideal when there are deficits from serious injury<sup>(20)</sup>; an item we utilized in replacing the anterior table with the HA cement only, when the table deemed insufficient and the postoperative cosmetic contours of the frontal region were noted to be good and accepted by the patient.

**Burstein et al.** <sup>(21)</sup>, in their study attributed the successful utilization of the HA cement to the formation of a periosteal envelope, the watertight closure of the wound, and delayed closed drainage of the surgical field, believing that these techniques maximize the ability of the HA cement to dry and solidify.

In agreement with the perfect outcomes we achieved with HA cement, **Costantino and Friedman** <sup>(14)</sup> used 6 cats and surgically created small cranial defects. These defects were then reconstructed utilizing HA cement. The cats were sacrificed at 6 and 12 months. The average depth of new bone ingrowth after 6 months was 7.3 mm and 10.8 mm after 12 months. The difference was statistically significant, indicating that bone growth happened over time. These animal studies demonstrated the absence of foreign body reaction, infection or fibrous encapsulation.

On the other hand, and unlike the results we got, reports of HA cement use in transtemporal surgery and repair of suboccipital craniotomy have demonstrated resorption, resulting in failure to totally close bony defects <sup>(22)</sup>. This, however, was related to hematoma formation; a consequent study of 21 patients who had received postoperative drains after cranial defect repair revealed no complications of HA cement resorption, even when the cement was in direct contact with a CSF <sup>(23)</sup>. Also **Shindo et al.** <sup>(24)</sup> placed HA cement with and without a collagen membrane to contain the cement underneath the periosteum of the supraorbital ridges of dogs. They found no significant decline in the height of the implanted material regardless of the utilization of the collagen membrane.

Despite the success of the HA cement in FS obliteration, the issue of cost in utilizing this substance cannot be disregarded. **Fattahi et al.** <sup>(25)</sup> have published an article questioning the cost-effectiveness of HA cement in FS obliteration compared with fat. As newer bioengineering

technology rises, one would expect that the overall cost of HA cement would decrease.

Good amount of bone formation results usually obtained when alloplastic materials as an osteoconductive bone substitute is used with an osteoinductive material that will induce bone formation; thus several studies have been carried out to investigate the effect of the osteoinductive statins on bone healing and have found positive outcomes <sup>(26)</sup>.

**Nyan et al.** <sup>(27)</sup> introduced a hypothesis assuming that combining an ideal dose of simvastatin with a gradually biodegradable bone substitute may lead to achieving the best anabolic effect of simvastatin together with eliminating the associated inflammatory reaction. The dose of simvastatin utilized in the present study was based on studies performed by **Nyan et al.** <sup>(27)</sup> in 2009 and **Rojabani et al.** <sup>(28)</sup> in 2011, in which they utilized 0.1mg simvastatin for each 14mg bone substitute. In the present investigation, the simvastatin powder was dissolved in ethanol in order to hydrolyse it into simvastatin acid that is the medically active form of simvastatin <sup>(29)</sup>.

The results of our study supported Nyan's hypothesis that mentioned a non significant amount of bone formation when the simvastatin was held on HA carrier, on the other hand, Nyan declared that when the simvastatin was held on a- or b- Tricalcium phosphate carriers, there were a significant amount of bone formation with them <sup>(27)</sup>. These outcomes were in line with the known different rate of degradability of the three carriers. It is obvious to observe that, inspite of the great variety of simvastatin doses and carriers that were utilized in various investigations that assessed the effect of locally applied simvastatin on formation of bone in critical sized bone defects, it is very evident that the local effect of simvastatin is dose and carrier dependent, and what is thought to be the ideal dose and carrier have not yet been defined.

## CONCLUSION

HA is a promising, effective and safe osteoconductive material with a comparable outcomes to the abdominal fat in obliterating the FS yet with minimal morbidity, excellent postoperative forehead contour and less operating time (no graft harvesting). However simvastatin does not seem to add a significant value to the HA cement when added to it. On the other hand, autogenous abdominal fat appears to be more cost effective compared with the HA cement.

## LIMITATIONS

A problem, which we experienced, was the relative rareness of FS fractures, which lead to carry this research on a small population. Consequently and in order to reach more facts and decision parameters concerning the treatment of such fractures with these materials, further researches with increased case number and follow-up period are required. Additionally, further studies are needed to monitor the simvastatin impact on bone formation in the FS when combined with other carrier other than HA cement.

## REFERENCES

- Strong EB. Frontal sinus fractures: current concepts. *Craniofacial Trauma Reconstruction*. 2009;2:161–75.
- Gonty AA, Marciani RD, Adornato DC. Management of frontal sinus fractures: a review of 33 cases. *J Oral Maxillofac Surg* 1999;57:372–379.
- Xie C, Mehendale N, Barrett D, et al: 30-Year retrospective review of frontal sinus fractures: The Charity Hospital Experience. *J Craniomaxillofacial Trauma* 6:7, 2000.
- Bergara AR. The obliteration of the sinus in the treatment of frontal chronic sinusitis. *Trans Second Pan-Am Congr Otorhinolaryng Bronchoesophagol* 1950;1:35–45.
- Tato JM, Sibbald DW, Bergaglio OE. Surgical treatment of the frontal sinus by the external route. *Laryngoscope* 1954; 64:504–521.
- Goodale R L, Montgomery WW. Experiences with the osteoplastic anterior wall approach to the frontal sinus. *Arch Otolaryngol* 1958;68:271–283.
- Eppley BL. Alloplastic implantation. *Plast Reconstr Surg* 1999;104:1761–1783.
- Cohen MS, Costantino PD, Friedman CD. Biology of implants used in head and neck surgery. *Facial PlastSurgClin North Am.* 1999;7:17-33.
- Snyderman CH, Scioscia K, Carrau RL, Weissman JL. Current concepts in the surgical management of frontal sinus disease. *OtolaryngolClin North Am.* 2001; 34:179-191.
- Mundy G, Garrett R, Harris S, et al. Stimulation of bone formation in vitro and in rodents by statins. *Science.* 1999;286: 1946–1949.
- Bellosta S, Ferri N, Bernini F, et al. Non-lipid-related effects of statins. *Ann Med.* 2000;32:164–176.
- Gutierrez GE, Lalka D, Garrett IR, et al. Transdermal application of lovastatin to rats causes profound increases in bone formation and plasma concentrations. *Osteoporos Int.* 2006;17:1033–1042.
- Weber R, Draf W, Kahle G, Kind M. Obliteration of the frontal sinus: state of the art and reflections on new materials. *Rhinology* 1999;37:1–15.
- Costantino PD, Friedman CD, Jones K, Chow LC, Sisson GA. Experimental hydroxyapatite cement cranioplasty. *PlastReconstr Surg.* 1992;90:174-185.
- Bergara AR, Itoiz AO: Present state of the surgical treatment of chronic frontal sinusitis. *Arch Otolaryngol* 1955; 61:616.
- R. L. Goodale and W.W.Montgomery, “Anterior osteoplastic frontal sinus operation. Five years’ experience,” *The Annals of Otology, Rhinology, & Laryngology* 1961 vol. 70, pp. 860–880.
- Calcaterra TC, Strahan RW. Osteoplastic flap technique for disease of the frontal sinus. *SurgGynecolObstet* 1971;132:505–510.
- Hardy JM, Montgomery WW: Osteoplastic frontal sinusotomy: An analysis of 250 operations. *Ann Otol Rhinol Laryngol* 1976 ;85: 523.
- R. Weber, W. Draf, R. Keerl et al., “Osteoplastic frontal sinus surgery with fat obliteration: technique and long-term results using magnetic resonance imaging in 82 operations,” *Laryngoscope* 2000 ; vol. 110, no. 6, pp. 1037–1044.
- Bent JP III, Spears RA, Kuhn FA, Stewart SM. Combined endoscopic intranasal and external frontal sinusotomy. *Am J Rhinol.* 1997;11:349-354.



21. Burstein FD, Cohen SR, Hudgins R, Boydston W, Simms C. The use of hydroxyapatite cement in secondary craniofacial reconstruction. *Plast Reconstr Surg.* 1999;104:1270-1275.
22. Kveton JF, Friedman CD, Costantino PD. Indications for hydroxyapatite cement reconstruction in lateral skull base surgery. *Am J Otol.* 1995;16:465-469.
23. Baker SB, Weinzweig J, Kirschner RE, Bartlett SP. Applications of a new carbonated calcium phosphate bone cement: early experience in pediatric and adult craniofacial reconstruction. *Plast Reconstr Surg.* 2002;109:1789-1796.
24. Shindo ML, Costantino PD, Friedman CD, Chow LC. Facial skeletal augmentation using hydroxyapatite cement. *Arch Otolaryngol Head Neck Surg.* 1993;119: 185-190.
25. Fattahi T, Johnson C, Steinberg B. Comparison of 2 preferred methods used for frontal sinus obliteration. *J Oral Maxillofac Surg.* 2005;63:487-491.
26. Ayukawa Y, Okamura A, Koyano K. Simvastatin promotes osteogenesis around titanium implants. A histological and histometrical study in rats. *Clin Oral Implants Res.* 2004;15:346-350.
27. Nyan M, Sato D, Kihara H, et al. Effects of the combination with alpha-tricalcium phosphate and simvastatin on bone regeneration. *Clin Oral Implants Res.* 2009;20: 280-287.
28. Rojbani H, Nyan M, Ohya K, et al. Evaluation of the osteoconductivity of a-tricalcium phosphate, b-tricalcium phosphate, and hydroxyapatite combined with or without simvastatin in rat calvarial defect. *J Biomed Mater Res A.* 2011;98:488-498.
29. Yoshinari M, Hayakawa T, Matsuzaka K, et al. Oxygen plasma surface modification enhances immobilization of simvastatin acid. *Biomed Res.* 2006;27:29-36.