

LONG-TERM ESTHETIC RESULTS OF A MODIFIED TECHNIQUE OF BILATERAL CLEFT LIP REPAIR

Hassan Abdelghany *

ABSTRACT

Purpose: To evaluate long-term esthetic results in the bilateral cleft lip repair by a modified technique characterized by prolabial self-elongation and orbicularis oris muscle reconstruction in one stage, using anthropometric measurements.

Patients and Methods: Fourteen patients (8 were males and 6 were females) had their bilateral cleft lip and nasal deformity repaired simultaneously by modified technique characterized by prolabial self-elongation and orbicularis oris muscle reconstruction in one stage, during the period from 1999 to 2002. Direct and indirect anthropometry were applied to all patients to evaluate the long term esthetic results.

Results: The long term esthetic results were satisfactory in all patients. There were no acute complications requiring re-surgery. In most patients, nasal length, nasal tip projection, columellar length, and upper lip shape were appropriate. Nasal tip protrusion, nasal width, upper lip height, and vermilion-mucosal height were within normal limit. The measurements were observed to be symmetrical; left and right measurement data were not significantly different.

Conclusions: This modified technique is proved to be a valuable technique on the long term basis in repair of bilateral complete cleft lip which has its important impact on esthetic results.

INTRODUCTION

The cleft lip as well as cleft palate deformity presents a massive and complicated surgical challenge. It's one among the foremost common inherent facial malformations. Patients born with a cleft deformity face vital long life communicative and aesthetic challenges. Every child borne with cleft might experience a lot of problems such as feeding, speech, and hearing, as well

psychological stresses and issues with social well-being secondary to their aesthetic deformity. A child with a repaired bilateral cleft lip has a characteristic look whose origins are both intrinsic to the malformation and iatrogenic. The philtrum is bowed, wide, undimpled, overly long, often asymmetric, and lacking a white ridge. If the prolabial vermilion-mucosais preserved, the free margins of the lateral labial component droop like swags, flanking a thin median tubercle that

* Lecturer of Oral and Maxillofacial Surgery, Faculty of Oral and Dental Medicine, Cairo University.

is covered by insufficient vermilion and chapped mucosa that is called whistling lip deformity. ⁽¹⁾ In profile, the upper lip is flat or convex, whereas the lower lip everts that is called cleft lip lower lip deformity. ⁽²⁾

Cleft lip is a subject that full of controversies and multiple protocols regarding treatment. ⁽³⁾ Bilateral cleft lip is taken into account to be the foremost challengeable cleft lip to repair. Since the earliest reported cleft lip repair in 390 bc, cleft surgeons have continuing to try to improve and perfect this procedure. Management requires multidisciplinary care attributable to the complexity of these clefts on midface growth, dentition, Eustachian tube function, and lip and nasal esthetic. Repair needs planning, however can be performed consistently to reduce variability of outcomes.

There has been an extensive evolution in the approach to bilateral cleft lip reconstruction. Millard stated that the white roll and dry vermilion in the central prolabial segment is insufficient. ⁽⁴⁾ Therefore, he tried to rectify the lack of tissue by using the lateral lip segments. This resulted in a tightened upper lip in patients. Manchester believed that there is enough white. ^(5,6) However, whistle lip deformity might occur in cases where there is a lack of tissue and the surgical team does not consider the nose. Mulliken emphasized symmetry, muscle union, proper prolabial size, and configuration in bilateral cleft lip surgery. ^(1,7,8) He attempted to form the median tubercle and mucocutaneous ridge from lateral lip tissue. The prolabial flap was designed by keeping 3-4mm width between Cupid's bow and 2mm of height from the columella-labial junction, removing the vermilion included in the prolabium. An infra-nasal incision was also made in primary rhinoplasty. ^(1,4,7) This is the best option to evaluate treatment and decide whether to modify or abandon an operative technique. The complexity of clefts has resulted in a wide range of individual treatments, and freedom exists on how best to treat a case.

Outcome studies pertaining to the multiple outcome measures, such as facial appearance, facial growth, occlusion, patient satisfaction, and psychosocial development, are essential. Unfortunately, this level of published evidence is lacking for this patient population. ⁽⁹⁾ In an average professional career of 25 to 30 years, a surgeon will follow a relatively small number of these children to adulthood. What is needed is a convenient, objective, and rapid way to evaluate nasolabial symmetry and proportions throughout the growing years. Although clumsy, a panel can be convened to assess the photographs, using a rating scale. ⁽¹⁰⁾ Other methodologies are direct anthropometry and computer-aided photogrammetry (indirect anthropometry). There is great potential for laser scanning or a similar advanced technology to assess results. ^(11,12) This technology will likely incorporate the soft-tissue landmarks used in medical anthropometry, so until it becomes available, anthropometry can be done the old-fashioned way, by handheld Vernier caliper. ⁽¹³⁻¹⁵⁾

We still do not possess definitive and concise operative procedures for all cleft patients. However, there are many options for documentation of results which can be chosen, whichever seems optimal.

The aim of the present study was to assess the long-term esthetic results in the bilateral cleft lip repair by a modified technique characterized by prolabial self-elongation and orbicularis oris muscle reconstruction in one stage, using anthropometric measurements.

PATIENTS AND METHODS

This study enrolled fourteen patients with non-syndromic bilateral cleft lip (BCL) with or without cleft palate who underwent bilateral cleft lip surgery by the author with a modified technique characterized by prolabial self-elongation and orbicularis oris muscle reconstruction in one stage

between 1999 and 2002. Review of the esthetic results was performed for all cases 11-13 years postoperatively. This study was performed in accordance with the Declaration of Helsinki. Oral and written informed consent was obtained from the guardians of all patients.

Surgical procedure

1) Design:

After traditional preparation of surgical field, key landmarks were identified and marked with methylene blue. The prolabial markings include Point 1: is located at the base of the columella. Point 3: is placed at the Cupid's bow on the mucocutaneous line (3 to 5 mm from the midline). A line from point 1 to point 3 is drawn. Point 2: is medial to point 1 at the same level. The distance from point 1 to point 2 (i.e., x) represents the difference in length of the prolabium minus the length from point 1 to point 3. The horizontal length from point 1 to point 2 will then increase the length of the prolabial portion of the lip. The line from point 1 to point 3 is at the mucocutaneous junction, and the line from point 3 to point 3' on each side is on the vermilion mucosa. The vermilion ridge at this position is preserved to constitute the middle part of the Cupid's bow. The lateral lip markings include Point 7: is marked on the mucocutaneous line at the location where the vermilion starts losing its width. Point 4: is placed slightly medial to the alar base. The distance from point 4 to point 7 should be equal to the height of the upper lip. An arc is drawn inferiorly and medially from point 4 with (x) as the radius. Point 6: is on the line drawn from point 4 to point 7. An arc is drawn from point 6 superiorly and medially with the same radius. Point 5: is at the junction of the two arcs. When it is certain that the points are in correct position, they are marked with a 25-gauge needle inserted through the skin. Lines from point 4 to point 5, point 5 to 6, and point 6 to point 7 are drawn subsequently.

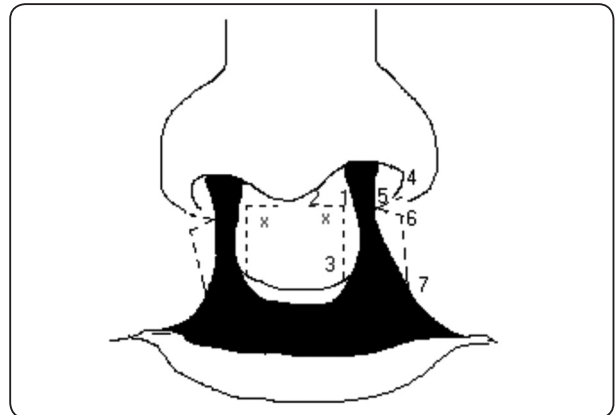


Fig. (1) Prolabial and lateral lip marking and design of the surgical flap

2) Prolabial and lateral lip flap elevation:

After the marking was completed, 1% lidocaine with epinephrine 1:100,000 were injected sparingly into the buccal sulcus, the base of the ala, columella, the prolabium, and the lateral lip elements. A 25 to 27-gauge needle is used, and the total solution injected should not exceed 1.0 to 1.5ml so as not to distort the lip tissues. Twelve to 15 minutes were allowed for the epinephrine to have its vasoconstrictive effect before making the incisions. An incision was made laterally in the labial sulcus to liberate the alar base and the cheek from the maxilla. To control bleeding, the lip was fixed firmly against a wooden tongue depressor as the lines 1-2 and 1-3 were incised vertically from skin to the periosteum of the premaxilla. The vermilion border was incised from point 3 - 3' on the other side; the curved incision should be on the mucosal side, and a little mucosa was left attached to the prolabial flap. The prolabial flap was freed with a No. 15 scalpel blade superficial to the periosteum and raised superiorly until the base of the columella. An extended flap was thus formed that is based on the columellar base, with a triangular gap on its upper part. The prolabial mucosa lateral to line 1 - 3 is preserved and freed generously from the premaxilla by careful dissection. With finger pressure used for fixation and homeostasis, lines 4 - 5, 5 - 6, and 6 - 7 were

incised through skin to the subcutaneous tissues and muscles on the lateral lip segment. This forms the superiorly based lip flap. The mucosa of the lateral lip was not incised; an inferiorly based lip flap was formed, with a concave triangle on its upper part.

3) Orbicularis Oris muscle and nasal lining repair

The muscles in the lateral lip element were freed from the skin and mucosa carefully; the extent of the dissection was near the nasolabial groove. The abnormal insertion of the orbicularis oris muscle was freed from the lateral alar crus, and the muscle bundles were flattened by stretching and rotated horizontally toward the middle line to contact or overlap with the muscle on the opposite side. Medial and lateral nasal segments were approximated using 5/0 vicryl sutures for subsequent reconstruction of the nasal floor. After complete hemostasis, the mucosa of the lateral segment was sutured to the prolabial mucosa with 4/0 vicryl suture, started from the nasal floor downward. The sutured mucosa formed the upper middle two thirds of the upper lip mucosa. The orbicularis oris muscle bundles were brought to the midline and sutured without tension to restore its continuity with 4/0 vicryl interrupted sutures.

4) Skin repair

The prolabial flap was repositioned, and the triangular flap in the lateral lip segment was inserted into the triangular gap formed by stretching of the prolabium. Point 5 was sutured to point 2, and point 7 was sutured to point 3 with 4/0 vicryl sutures. The remaining skin wound was sutured using 6/0 vicryl sutures. The vermilion was carefully trimmed, the submucosal tissues in the lateral lip segment were overlapped and approximated under the prolabium, and the mucosal flap of the prolabium was placed in position. The vermilion flap was denuded of epithelium and sutured to the prolabial mucosa with 4-0 vicryl sutures. Infants were extubated only after they were awake and ventilating adequately on 100% oxygen. At the end of the operation, the infants were

wrapped in a warm blanket and transferred to the recovery room.

5) Postoperative care

When the operation was finished, the suture lines were covered lightly with an antibiotic ointment, and a small gauze dressing was taped in place for 24 hours. The parents of the child were informed the postoperative instructions that keep their child safe.

Outcome assessments

The patients were followed up immediately for assessment of the surgical results. Any postoperative complications were recorded. The patients had adequate follow-up with clinical unretouched photographs taken 1 week, 3 months, 6 months, and 18 months postoperatively. The photographic records included frontal, profile, and subnasal views for all patients. The quality of the operative result was evaluated in terms of whether or not the lip needed a subsequent revision or if the initial repair was judged to be satisfactory.⁽¹⁶⁾ The patients were clinically assessed for function of upper lip. Moreover, the subjective impression of the parents was taken into consideration as suggested by Thomson and Delpero.⁽¹⁷⁾

For long-term follow-up, the author reevaluate the esthetic results 11 to 13 years postoperatively. Direct and indirect anthropometry (photogrammetry) were applied to all patients.

Direct anthropometry⁽¹⁸⁾

3 types of anthropometric measurements on the nose were adopted: (1) subnasale-pronasale (sn-prn), (2) alare-olare (al-al), and (3) subnasale-columella (sn-c) were measured by applying a sliding Vernier caliper (E-Base Measuring Tools, Taiwan). On the upper lip, 3 types, namely, (1) subnasale-labiale superius (sn-ls), (2) labiale superius-stomion (ls-sto), and (3) subnasale-stomion (sn-sto;) were measured, and the growth of the lip and the nose was examined

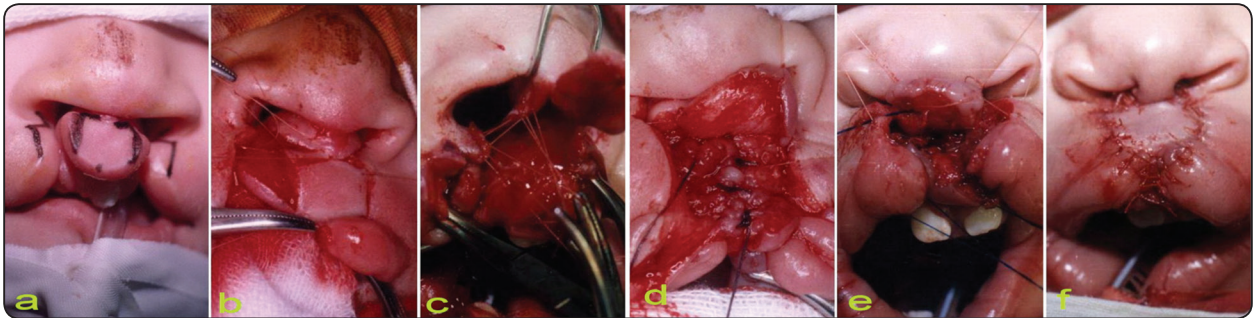


Fig. (2) Surgical procedure; a: Marking of the flap, b: after incision and dissection, c: construction of the nasal floor, d: bridging of the orbicularis muscle, e: approximation of lateral lip and prolabial flaps, f: final suturing

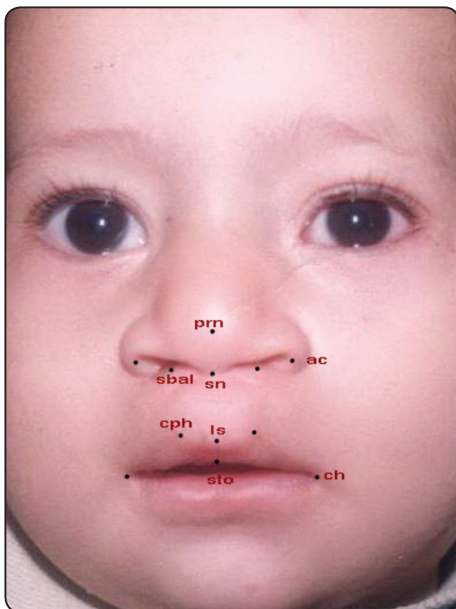


Fig. (3) Anthropometry of the frontal view; prn: pronasale, sn: subnasale, ls:labiale superius,sto: stomion, ac: alar. Nasal: nasal tip projection (sn–prn, subnasale-pronasale), nasal width (ac–ac, alare-alare), and columellar length (sn–c, subnasale-columella). Labial: cutaneous lip height (sn–ls, subnasale–labiale superius), vermilion-mucosal height (ls–sto, labiale superius–stomion), and total upper lip height (sn–sto, subnasale-stomion). Upper lip symmetry: sbal–cph distance, Horizontal lip length: sto–ch distance, Cupid's bow symmetry: ch–cph–ls angle, Alar symmetry: ac–sn distance.

Indirect anthropometry (photogrammetry)

The patients were evaluated through the frontal views. The symmetry of the upper lip, horizontal length of the lip, Cupid's bow, and alar rim.⁽¹⁸⁻²¹⁾ According to recorded measures the patients were classified into 4 categories;⁽²²⁾ Category I; No refinements of surgical revisions considered. Category II, Minor revisions (primary closure) were desirable; Category III, Muscular structure revisions or major alternative procedures were need; Category IV Repair failed or totally reoperation will be necessary.

Subnasal views from below in each of the patients are also shown. Each of the patients' lips is viewed

from below to show the most critical aspect of their lip-nose development and the effect of time on the collumella length as well as the final appearance of the scars. A more accurate assessment would be made by also examining preoperative and lateral views in each case.

RESULTS

Bilateral cleft lip surgery was performed in fourteen cases between 1999 and 2002. Ten cases were with complete cleft of the primary and secondary palates and 4 cases were with complete cleft of the primary palate solely. Of those patients,

eight were males and six were females. Their ages at time of surgical repair ranged from three months to eighteen months (mean: ten and half months). Immediate surgical results of repair of all cases were satisfactory as regard skin, muscle and mucous membrane union. Bridging and reunion of the orbicularis muscles justifies creation of fine perform of the lip. The parents were happy with the outcomes of surgery in all cases. The postoperative lip forms were satisfactorily improved in all patients. There were no serious postoperative complications. There were no acute complications requiring re-surgery, such as wound dehiscence, hematoma, and infection.

Regarding long term follow up, most of the patients showed adequate growth of the nasal tip protrusion. The nasal width showed no apparent signs of growth retardation. The columellar lengths were nearly near to the traditional values. The upper lip height and vermilion-mucosal height showed close to the normal growth. Cutaneous lip heights were satisfactory in most of the cases

and the lip scars are comparatively unnoticeable. In some patients, the lip scars are slightly apparent on ordinary viewing. The symmetry of the lip and nose and were well maintained but the natural shape of the philtrum was affected. The upper lip showed satisfactory Cupid's bow form. The vermilion and tubercle were adequate, alongside acceptable nasal tip protrusion, columella, and nostril shape and size are observed. Two patients are shown in more detail.

According to aesthetic classification, ⁽²²⁾ nine patients were classified into category I while five patients into category II; and no patients were classified into categories III and IV. The symmetries of the upper lip, horizontal length of the lip, Cupid's bow, and alar rim were showed to be acceptable; left and right measurement weren't considerably totally different. Secondary lip operations were planned in four patients. The main aim of the revision were philtral widened scar excision and lateral vermilion bulge correction. The foremost tough cases were those with an asymmetric bilateral complete cleft lip having a deviated premaxilla.

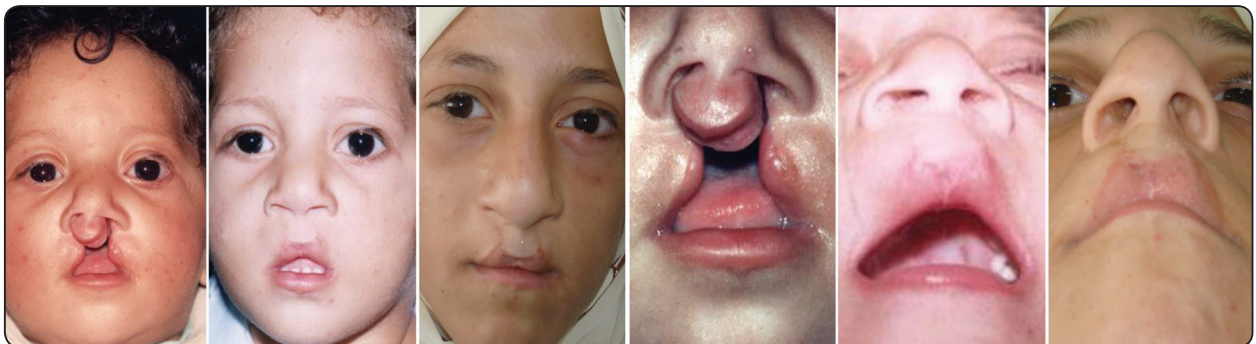

Fig. (4) Frontal and subnasal views of the case no. 3, preoperatively, 6 months, and 13 years postoperatively

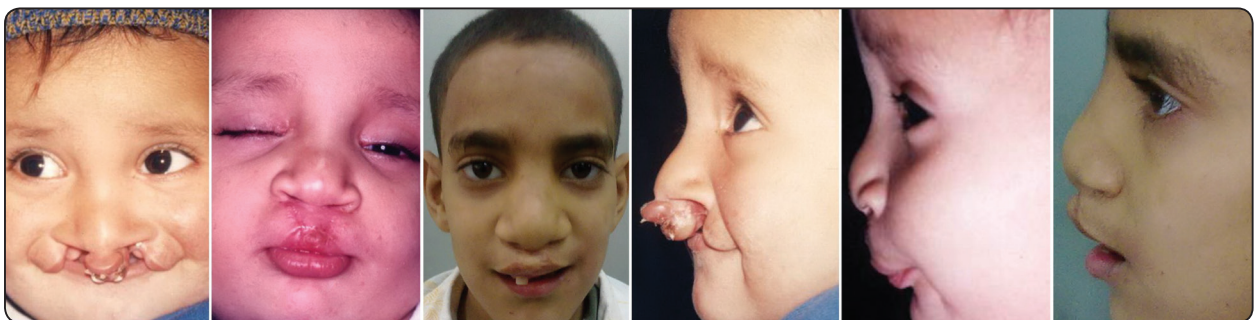

Fig. (5) Frontal and profile view of the case no. 9, preoperatively, 6 months, and 12 years postoperatively

DISCUSSION

The improvement of multidisciplinary care for children with cleft has acquired prominence, and assessment of long-term outcomes of various treatment protocols has become a lot of value as a result of its standard that the definitive outcome of treatment in patients with a cleft lip or palate cannot be established till the facial development is finished. For bilateral cleft lip reconstruction many techniques have been reported, every one of them has its disadvantages. The modified technique for bilateral cleft lip repair used in this study in younger age group of patients showed good satisfactory long term results regarding esthetic and function.

McComb's rule be followed in publishing photographs in support of a replacement methodology of cleft lip reconstruction. It shows ten consecutive patients with follow-up of ten or more years.⁽²³⁾ Though admirable, this rule is delusive, especially if applied to the reconstruction of bilateral cleft lip, as less than ten percent of cleft lips are bilateral, thus even a high-volume surgeon may see solely a few such new patients annually.

According to Farkas,⁽²⁰⁾ direct anthropometric measurement by traditional instruments (e.g., sliding and spreading calipers) during an examination are reliable and cheap to perform, and there is an intensive normative information for them. Respecting the very fact, that nearly 90% of the growth is completed by the age of eight to ten years and observant that no vital delay has been noted to this point, no indication of a dramatic cessation of growth throughout the final 10% of additional growth could be found. However this technique has some limitations to its use including time-consuming nature of performing multiple direct measurements during an examination and patient compliance should be maintained, as well, requiring subjects with patience stay still. Additionally, there is no likelihood to own archive of those huge information. Anthropometry using two-dimensional

(2D) photos, such as photogrammetry would seem to carry obvious charm over direct mensuration of a moving subject.^(24,25) The merits of 2D imaging are speedy acquisition, archival capabilities, simplicity, low cost, and noninvasiveness. For validation of our results we have a tendency to use each techniques particularly that each one of our patients were older than eleven years.

Few studies were concerned about lateral views anthropometric analyses of bilateral cleft lip repair. They show an obtuse columellar-labial angle; but, they lack follow-up assessment of this point.^(26,27) In a very tiny sample, Rottgers and his colleagues⁽²⁸⁾ presumed that the patients would have an obtuse angle in childhood however that it might be improved by adolescence. They conjointly presupposed that the columellar-labial angle would be larger in patients with reconstructed bilateral complete cleft lip compared with those with a reconstructed bilateral incomplete cleft lip. What is more, they hypothesized that a very wide columellar-labial angle was resulted of the primary construction of the columella by apposition, elevation, and fixation of the middle crura without expansion of the related skin. Our result certify this opinion, the nasolabial angles of all patients almost were close to the normal. It has been assumed that the length of the primarily constructed columella correlated with the columellar-labial angle.

Repair of bilateral cleft lip typically related to many complicating factors like the protruding premaxilla, tissue deficiency of the prolabium, short columella.⁽²⁹⁾

Debate continues regarding the employment of the prolabium for reconstruction of the upper two thirds or the total length of the upper lip. Some authors used the prolabium to reconstruct solely the center and upper portions of the lip, whereas the lower portion was reconstructed with flaps from the lateral lip components.⁽³⁰⁾ Others have ascertained that prolabium should be used to form the complete vertical dimension or height of the central portion

of the reconstructed lip, and therefore the white roll of the prolabium should be preserved to make the central portion of the created Cupid's bow. ⁽³¹⁾ The modified technique of this study has a very characteristic feature that is the prolabium is elongated by itself, not by sacrificing the width of the lateral segment to gain length. Although the prolabium of the unrepaired cleft can appear minute, however it has shocking ability to stretch. This resulted in, tightness of the upper lip and whistle deformity are prevented. On long term follow up the prolabium keep its satisfactory length which give more natural appearance of the child.

A shortened columella is much perpetually related to complete bilateral clefts. The elongation of the foreshortened columella by anatomic repositioning of the lower lateral cartilage is a cornerstone of the modern techniques of primary bilateral cleft lip rhinoplasty, like the Cutting technique. ^(32,33) The columella is elongated instantly to some extent with this technique, and additionally prolabial lengthening is achieved by a prolabial flap pedicled on the columellar base, which consider an advantages of this technique. The triangular flap from the lateral lip tissues fill the triangular space created at the prolabial tissue flap after its incision and stretching it downward. This provide good length of the prolabium without affecting the collumellar length. One of the most advantages of technique used in this study is that the columella is elongated to some degree primarily, and on the long term follow-up, satisfactory length of the columella was maintained which give the nose more natural appearance and enhancing its projection. However in some cases the columella is still needs to be lengthened further.

Another important controversy associated with bilateral cleft lip repair is primarily repairing of the orbicularis oris muscle. Although the whole muscle-to-muscle anastomosis beneath the entire prolabium may possibly give improved lip function, it has not been proven that the tightness so created might

not cause retrusion of the upper jawbone. Thus, this primary reconstruction was varied by many authors. Some author stated that repositioning of the muscle under the prolabial skin and creation of a functioning muscle structure were the main aim of lip reconstruction. ⁽³⁴⁾ Others assumed that it is not necessary to create a muscle bridge underneath the prolabium for reconstruction of an adequately functioning lip and it is quite enough to insert muscle at the edges of the reconstructed philtrum without trying to join portions of the muscle at midline, ⁽³⁵⁾ or intentionally removed the step of muscle repair across the premaxilla so as to avoid increased undue tension. ⁽³⁶⁾ On the opposite hand, there was opinion conjointly raised concern regarding the chance that muscle repair would possibly end with maxillary retrusion, and conjointly selected not to repair muscle in his bilateral cleft lip operation. ⁽³¹⁾ In the present study, the orbicularis oris muscle layer was closed in all cases. It is our belief that if the integrity of the orbicularis oris muscle is not restored scars contracture and lip irregularities may occur, the movement of the upper lip will be restricted, and development and growth of the upper lip may be subsequently disturbed. This is supported by observation of the growth of these cases on the long term follow up. There was no growth retardation despite presence of good functioning upper lip.

Generally, the technique utilized in this study has many advantages because the symmetry and natural shape of Cupid's bow were obtained in most of the patients. The width of philtrum was similar to normal children. Full vermilion of the lips, moderate-size vermilion tubercles and good dynamic and static shape were obtained without whistle deformities. Normal width of nasal base and nostril symmetry were gained. The columella was elongated. Satisfactory contour of the nasal tip was achieved. However this technique also has few limitations; as it is not an ideal method to eliminate the cleft stigmata from the patient's face.

CONCLUSION

This modified technique is of important value in complete bilateral cleft lip repair for both esthetic and function, especially in cases with small prolabium, not only on short term but also on the long term follow up of esthetic results.

REFERENCES

- 1- Mulliken J.B.: Principles and techniques of bilateral complete cleft lip repair. *PlastReconstrSurg.* 75: pp.477-487, 1985.
- 2- Pensler, J. M., and Mulliken, J. B. The cleft lip lower-lip deformity. *Plast. Reconstr. Surg.* 82: 602, 1988
- 3- Dixon et al., 2011. Dixon M.J., Marazita M.L., Beaty T.H., and Murray J.C.: Cleft lip and palate: synthesizing genetic and environmental influences. *Nat Rev Genet.* 12: pp. 167-178, 2011.
- 4- Millard D.R.: Bilateral cleft lip and a primary forked flap: a preliminary report. *PlastReconstrSurg.* 39: pp.59-65, 1967.
- 5- Manchester W.M.: The repair of the bilateral cleft lip and palate. *Br J Surg.* 52: pp. 878-882, 1965.
- 6- Manchester W.M.: The repair of double cleft as part of an integrated program. *PlastReconstrSurg.* 45: pp.207-216, 1970.
- 7- Mulliken J.B., Burvin R., and Farkas L.G.: Repair of bilateral complete cleft lip: intraoperative nasolabial anthropometry. *PlastReconstrSurg.* 107: pp. 307-314, 2001.
- 8- Mulliken J.B., Wu J.K., and Padwa B.L.: Repair of bilateral cleft lip: review, revisions, and reflections. *J CraniofacSurg.* 14: pp. 609-620, 2003.
- 9- Shaw W.C., Asher-McDade C., Brattstrom V., et al: A six-center international study of treatment outcome in patients with clefts of the lip and palate. Part 5. General discussion and conclusions. *Cleft Palate Craniofac J.* 29: pp. 413-418, 1992.
- 10- Tobiasen, J. M., and Hiebert, J. M. Facial impairment scales for clefts. *Plast. Reconstr. Surg.* 93: 31, 1994.
- 11- Aung, S. C., Ngim, R. C. K., and Lee, S. T. Evaluation of the laser scanner as a surface measuring tool and its accuracy compared with direct facial anthropometric measurements. *Br. J. Plast. Surg.* 48: 551, 1995.
- 12- Bush, K., and Antonyshyn, O. Three-dimensional facial anthropometry using a laser surface scanner: Validation of the technique. *Plast. Reconstr. Surg.* 98: 226, 1996.
- 13- Mulliken, J. B. Bilateral complete cleft lip and nasal deformity: An anthropometric analysis of staged to synchronous repair. *Plast. Reconstr. Surg.* 96: 9, 1995.
- 14- Farkas, L. G., and Lindsay, W. K. Morphology of the adult face following repair of bilateral cleft lip and palate in childhood. *Plast. Reconstr. Surg.* 47: 25, 1971.
- 15- Farkas, L. G., Hajnis, K., and Posnick, J. C. Anthropometric and anthroposcopic findings of the nasal and facial region in cleft patients before and after primary lip and palate repair. *Cleft Palate Craniofac. J.* 30: 1, 1993.
- 16- Weatherley-White RCA, Kuehn DP, Mirrett P, Gilman JI, Weatherley-White CC. Early repair and breast-feeding for infants with cleft lip. *Plast Reconstr Surg.* 79:879-887, 1987.
- 17- Thomson HG, Delpero W. Clinical evaluation of microform cleft lip surgery. *Plast Reconstr Surg.* 75: 800-804, 1985.
- 18- Kim SK, Kim MH, Kwon YS, Lee KC. Long-term results in the bilateral cleft lip repair by Mulliken's method. *J Craniofac Surg. Sep; 20(5):1455-61, 2009.*
- 19- Farkas L.G., Bryson W., and Klotz J.: Is photogrammetry of the face reliable? *Plast ReconstrSurg.* 66: pp. 346-355, 1980.
- 20- Farkas LG. *Anthropometry of the Head and Face.* New York: Raven Press, 1994.
- 21- Kohout M.P., Aljaro L.M., Farkas L.G., and Mulliken J.B.: Photogrammetric comparison of two methods for synchronous repair of bilateral cleft lip and nasal deformity. *Plast ReconstrSurg.* 102: pp. 1339-1349, 1998.
- 22- Baek RM, Myung Y, Park I, Pak CS, Kim BK, Lâm VN, Jeong JH. A new all-purpose bilateral cleft lip repair: Bilateral cheiloplasty suitable for most conditions. *J Plast ReconstrAesthet Surg. Apr; 71(4):537-545, 2018.*
- 23- Lehman, J. A., Jr. Tulip flap for reconstruction of the central tubercle in cleft lip (Discussion). *Plast. Reconstr. Surg.* 101: 1349, 1998.
- 24- Grayson B, Cutting C, Bookstein FL, Kim H, McCarthy JG. The three-dimensional cephalogram: theory, technique and clinical application. *Am J OrthodDentofacialOrthop.*94:327-337, 1988.
- 25- Al-Omari I, Millett DT, Ayoub AF. Methods of assessment of cleft-related facial deformity: a review. *Cleft Palate Craniofac J.* 42:145-156, 2005
- 26- Miyamoto J, Miyamoto S, Nagasao T, Nakajima T, Kishi K. Anthropometric evaluation of bilateral cleft lip nose with cone beam computed tomography in early childhood: Estimation of nasal tip collapse. *J PlastReconstrAesthet Surg.* 65:169-174, 2012.

- 27- Chang CS, Liao YF, Wallace CG, et al. Long-term comparison of the results of four techniques used for bilateral cleft nose repair: A single surgeon's experience. *PlastReconstr Surg.* 134:926e-936e, 2014.
- 28- Rottgers SA, Lim SY, Hall AM, Zurakowski D, Mulliken JB. Longitudinal Photogrammetric Analysis of the Columellar-Labial Angle following Primary Repair of Bilateral Cleft Lip and Nasal Deformity. *PlastReconstr Surg.* May;139(5):1190-1199, 2017.
- 29- Nakajima T, Yoshimura Y, Nakanishi Y, Kuwahara M, Oka T. Comprehensive treatment of bilateral cleft lip by multidisciplinary team approach. *Br J Plast Surg.* 44: 486-494, 1991.
- 30- Barsky AJ. *Principles and Practice of Plastic Surgery.* Baltimore, William & Wilkins, 1950.
- 31- Cronin TD, Cronin ED, Roper P, Millard DR Jr, McComb H. Bilateral clefts. In *Plastic Surgery, (Vol. 4).* Philadelphia, Saunders WB, 1990.
- 32- Cutting C, Grayson B, Brecht L, Santiago P, Wood R, Kwon. Presurgical columellar elongation and primary retrograde nasal reconstruction in one-stage bilateral cleft lip and nose repair. *PlastReconstr Surg.* 101(3):630-9, 1998.
- 33- Roberto L. Flores, Court B. Cutting. Cutting's Technique of Bilateral Cleft Lip Repair. Bing Shi, Brian C. Sommerlad ed. *Cleft Lip and Palate Primary Repair.* Hangzhou: Springer, 197-210, 2013.
- 34- Randall P, Whitaker LA, LaRosa D. The importance of muscle reconstruction in primary and secondary cleft lip repair. *PlastReconst Surg.* 54: 316-323, 1974.
- 35- Bardach J, Mooney M, Giedrojc-Juraha ZL. A comparative study of facial growth following cleft lip repair with or without soft tissue undermining: An experimental study in rabbits. *PlastReconst Surg.* 69: 745-754, 1982.
- 36- Manchester WM. The repair of bilateral cleft lip and palate. *Br. J Surg.* 52: 878-882, 1965.