

PIEZOELECTRIC-ALVEOLAR RIDGE SPLITTING: A SUCCESSFUL MODALITY REDUCING CRESTAL BONE LOSS AROUND DENTAL IMPLANTS AND ENHANCING IMPLANT SECONDARY STABILITY

Ahmed Elsayed Hamed Amr* *and* Amr Amin Ghanem**

ABSTRACT

Aim: This study was performed to compare two different modalities of alveolar ridge splitting performed simultaneously with dental implant placement regarding the alveolar crestal bone changes and implant stability

Subjects and methods: 12 patients were included in this study. Group 1 (6 patients, 12 implant) while Group 2 (6 patients, 10 implants). Single surgery was performed to each patient involving alveolar ridge splitting, expansion and simultaneous implant (or implants) placement. Ridge splitting in group 1 was performed using the piezoelectric surgery and in group 2 using the traditional surgical disc, while the alveolar ridge expansion and implant placement were performed using the same procedures for both groups. Marginal bone loss on the buccal and lingual aspects of the implant was evaluated 4 months after implant insertion using the CBCT. The implant stability ISQ values were measured immediately after implant insertion and 4 months after the surgery during the prosthetic steps by the Ostell.

Results: Post treatment, a higher mean percent resorption in marginal bone was recorded in traditional surgical disc group with an extremely significant difference between groups. Also, a higher mean percent increase in ISQ2 was recorded in piezo- electric surgery group with an extremely significant difference between groups.

Conclusion: Piezoelectric ridge splitting is accompanied with decreased postoperative marginal bone loss and enhanced secondary ISQ compared to traditional surgical disc splitting.

* Lecturer of Oral Medicine and Periodontology, Faculty of Dentistry, Ain Shams University

** Lecturer of Oral and Maxillofacial Surgery, Faculty of Dentistry, Ain Shams University

INTRODUCTION

Alveolar bone develops in association with teeth eruption and resorbs following teeth extraction leading to dimensional changes in alveolar ridges (Devlin & Ferguson 1991, Iekovic et al. 1998, Araujo & Lindhe 2005). In 2003 Schropp et al. reported that the bucco-lingual alveolar ridge width decreased by 50% after 1 year of dental extraction.

Implant diameter is highly critical for implant success. Each 1 mm increase in implant diameter allows the implant surface area to increase by 20-30% and consequently decreasing crestal stresses (Misch 1999).

Guided bone regeneration GBR, alveolar ridge splitting and onlay autogenous bone grafting are among the most common surgical procedures used to augment deficient alveolar ridges (Aghaloo and Moy 2007). However, many disadvantages have been associated with GBR and onlay autografts. GBR is commonly associated with barrier membrane collapse and dehiscence (Buser et al. 1990, Von Arx & Buser 2006, Rocuzzo et al. 2007), while onlay grafting may be associated with donor site morbidity and prolonged treatment time (Nkenke et al. 2002, Tessier et al. 2005).

The alveolar ridge splitting and expansion was first introduced by Simion et al. 1992 and Scipioni et al. 1994. It depends on the viscoelastic properties of alveolar bone & involves manipulation of the resorbed alveolar ridge allowing the lateral repositioning of the buccal cortical plate away from the lingual plate which permits implant placement in deficient alveolar ridges without any bone removal (Simion et al. 1992, Scipioni et al. 1994).

The area of the ridge where bony plate has been lateralized shows natural tendency to heal by bone fill like bone fracture rather than by fibrous tissue due to double cellularity and double vascularity. Literature has shown that no need for bone graft or membrane when ridge splitting is used as the healing is similar to bone fracture healing (Scipioni

et al. 1994, Scipioni et al. 1997, Coatoam & Mariotti 2003, Fischer et al. 2008)

Shorter treatment period, no need for donor sites and the possibility of simultaneous implant placement are among the merits of ridge splitting over autogenous block grafting (Scipioni et al. 1994, Sethi & Kaus 2000)

To allow successful splitting with simultaneous implant placement the alveolar ridge width should be 3 mm or more with at least 1 mm trabecular bone between the cortical plates (Misch 2004, Suh et al. 2005, Khairnar et al. 2014).

The splitting can be performed on the residual alveolar ridge traditionally using the chisel and mallet, the surgical disc, ultra-fine fissure burs and recently using the piezoelectric surgical devices while the expansion is performed by the osteotomes, chisels, bone spreaders and the engine driven expanders (Suh et al. 2005, Blus & Szmukler-Moncler 2006, Mazzocco et al. 2011).

The piezo electric surgery has many advantages including selective cutting of the bone without affecting the soft tissues, greater visibility during operation and cutting by cavitation effect thus avoiding excessive heat which may affect the healing (Holtzclaw et al. 2010 and Sohn et al. 2010).

The literature showed that dental implants placed simultaneously with alveolar ridge splitting were associated with marginal bone loss by time (Strietzel et al. 2002, Jensen et al. 2009, Kolerman 2014, Gehrke et al. 2016).

Taking into consideration the decreased bone trauma applied to the alveolar ridge when using the piezoelectric surgery, this study was performed to evaluate primarily the crestal bone loss around dental implants placed simultaneously with alveolar ridge splitting performed using the piezoelectric surgical device versus the alveolar ridge splitting performed using the traditional surgical disc. Also, evaluation of the effect of the two different splitting modalities on the implant stability had been investigated.

AIM OF THE STUDY

This study was performed to compare two different modalities of alveolar ridge splitting performed simultaneously with dental implant placement regarding the alveolar crestal bone changes (primary objective) and implant stability (secondary objective)

SUBJECTS AND METHODS

A total of 12 patients with age range 30-45 Y was included in this study. They received a total of 22 dental implants. Group 1 (6 patients, 12 implant) while Group 2 (6 patients, 10 implants).

All the patients included in the study were free from any systemic diseases as evidenced by Burket's oral medicine health history questionnaire (Glick et al., 2008) and suffering from missing one or two mandibular premolars or molars with sufficient alveolar ridge height (at least 15 mm from the inferior alveolar canal or mental foramen) and insufficient alveolar ridge buccolingual (BL) width that interfere with conventional straight forward implant placement. The minimum BL width included in the study was 4 mm to facilitate ridge splitting and expansion.

All the patients were informed about the full details of the surgical procedure performed in the study and all the treatment alternatives available were discussed then an informed consent was taken from each participant. Patients with residual infections in the edentulous areas, vulnerable groups, smokers and patients with poor oral hygiene were excluded from this study.

Cone beam computed tomographic examination (CBCT) was performed twice for every patient in this study. The 3D images were generated by the I-CAT Vision TM software (Imaging Sciences International, Hatfield, Pa). The first CBCT was performed for initial diagnosis and preoperative measurement of alveolar ridge dimensions, while the second one was performed 4 months after the

surgery for evaluation of alveolar ridge dimensional changes around the dental implant.

Treatment protocol: Preoperative analysis included detailed patient history, clinical examination, clinical photographs and the CBCT to evaluate the initial alveolar ridge morphology. Professional periodontal treatment and oral hygiene instructions were provided to all patients two weeks before the surgical procedure. Single surgery was performed to each patient involving alveolar ridge splitting, expansion and simultaneous implant (or implants) placement.

All surgeries were performed under local anaesthesia (*Aticaine hydrochloride 4% with 1/100000 epinephrine, septanest SP, Septodont*) in an outpatient setting by the same operator. All patients were premedicated one hour before the surgical procedure with amoxicillin 875mg /clavulanic acid 125 mg orally (*Hibiotic 1gm tablets/ Amoun Pharmaceuticals*) and dexamethasone phosphate 8 mg I.M. injection (*Epidron ampoule 2ml; Eipico*)

Alveolar Ridge splitting in group 1 was performed using the piezoelectric surgery and in group 2 using the traditional surgical disc, while the alveolar ridge expansion and implant placement were performed using the same surgical kits & procedures for both groups (**fig 1, fig 2**).

Surgical steps: Full thickness mucoperiosteal flap was reflected buccally and lingually at the edentulous area using one paracrestal incision and two vertical buccal incisions. One crestal horizontal osteotomy and two vertical buccal osteotomies were then applied for ridge splitting.

For group 1, the crestal and vertical osteotomies were performed using the ultrasonic piezoelectric device (*Variosurg, NSK*). The crestal osteotomy was performed using the *variosurg SG4* tip (*variosurg osteoflat scalpel*) to depth of 8 mm then the vertical buccal osteotomies were performed 8mm coronal meeting the crestal one. In group 2, the surgical disc (*Surgident; Korea*) was used to create

the crestal and vertical osteotomies. A small chisel (*Surgident; Korea*) about 1.5mm thickness was used to complete the depth of the crestal osteotomy after the disc.

Following splitting, the same ridge expanders (*Surgident; Korea*) were used to expand the ridge in both groups to the depth of 8 mm. Initially none cutting guiding drill was used to locate the future implant position in the edentulous area followed by sequential use of non-cutting expanders series to reach the final expander size. This was followed by using the implant kit (*Interactive system; Implant Direct; Sybron Dental Specialties*) cutting drills to prepare the apical portion of the implant recipient site (5mm apical to the expanded part).

All the implants used in this study were the same size (3.5mm x 11.5mm) and were placed 1.5mm subcrestally with sufficient primary stability exceeding 30 NCM using the torque wrench. Periosteal releasing incisions were made at the base of the flap to allow tension free adaptation of the wound edges. Polypropylene 4/0 interrupted sutures (blue monofilament, Assut sutures) were performed followed by prescribing the postoperative medications. The sutures were removed two weeks later.

The patients were instructed not to wear any removable prosthesis for the healing period and to return for follow up every 2 weeks for the first month then once per month till the prosthetic steps (4 months following implant insertion).

Evaluation of the marginal bone changes (Figure 3): The initial distance from the apex of the implant to the buccal alveolar crest (ABC1) or the lingual alveolar crest (ALC1) just after implant insertion was 13mm in all cases since all the implants were 11.5mm in length and placed subcrestally by 1.5mm. Four months after implant insertion, ABC2 and ALC2 were measured for all implants using the second CBCT. Crestal bone loss was evaluated on the buccal and lingual aspects of the implant by calculating the difference between ABC1&ABC2 and the difference between ALC1 & ALC2 respectively.

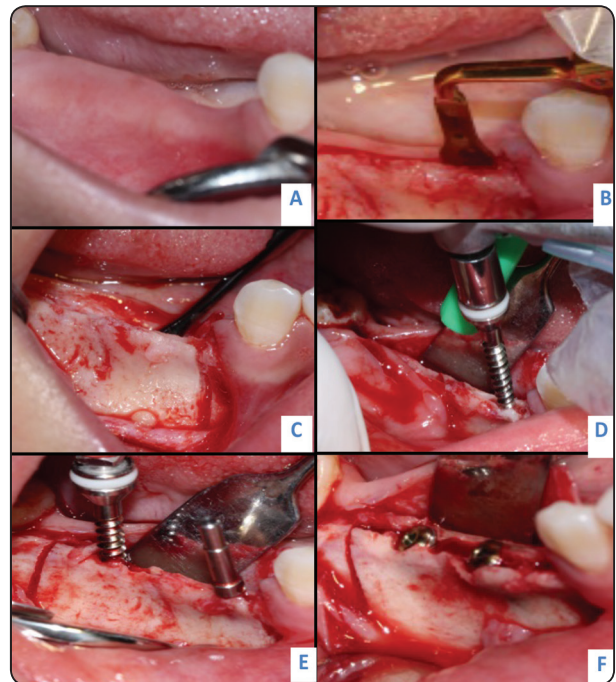


Fig. 1 (A-F) Group 1. Piezoelectric group. **A:** Edentulous narrow ridge. **B:** Piezo-electric crestal split. **C:** after performing the mesial vertical osteotomy. **D:** engine-drive bone expanders. **E:** paralleling pin to check parallelism. **F:** implants subcrestally by 1.5mm

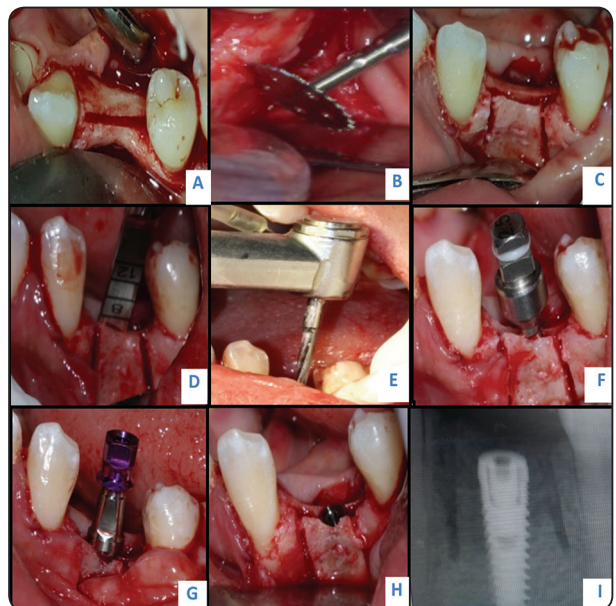


Fig. 2 (A-I) Group 2. Surgical disc group. **A:** Crestal osteotomy. **B:** Surgical disc vertical osteotomy. **C:** Crestal and vertical osteotomies should be connected together. **D:** chisel used to complete the osteotomy to the desired depth. **E:** Non-cutting locator drill of the expander kit. **F:** Engine-driven expanders. **G,H:** Implant inserted subcrestally by 1.5mm. **I:** Periapical radiograph.

Evaluation of implant stability ISQ: The implant stability was measured by the Ostell Mentor (integration diagnostics AB, Goteberg, Sweden) for the magnetic resonance frequency measurements. The smart peg was placed into each implant and tightened to approximately 5 Ncm. The Transducer probe was aimed at the small magnet at the top of the smart peg at a distance of 2-3mm and held stable during the pulsing until the ostell displayed the ISQ (implant stability quotient) value. The ISQ values were measured immediately after implant insertion (ISQ 1- Baseline) and 4 months after the surgery during the prosthetic steps (ISQ 2- Follow up). The ISQ was measured for each implant buccally, lingually, mesially and distally and the mean value was calculated for each implant.

RESULTS

Statistical analysis was then performed using a commercially available software program (SPSS 18; SPSS, Chicago, IL, USA). Values were presented as mean and standard deviation (SD). Data were explored for normality using Kolmogorov-Smirnov test of normality. The results of Kolmogorov-Smirnov test indicated that most of data were normally distributed (parametric data), so paired (dependent) t test was used to compare pre and post treatment values. Independent t test was used to compare both groups. The Pearson correlation coefficient is used to measure the strength of a linear association between two variables. The level of significance was set at P < 0.05.

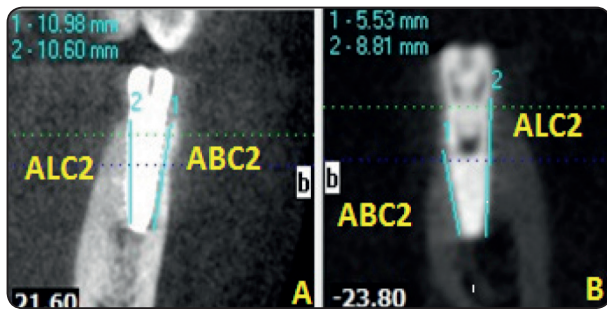


Fig. (3) A group 1, B group 2. Evaluation of crestal bone loss by CBCT by measuring ABC2 and ALC2.

Both groups recorded the same (ABC1) and (ALC1). Four months after splitting, a higher mean value was recorded in Piezo electric surgery groups (10.84±0.4; 10.76±0.4 for ABC2 and ALC2 respectively) with an extremely significant difference (p=0.00) (Table 1, Fig.4). Both groups recorded the same primary implant stability. Four months after splitting, a higher mean value was recorded in Piezo electric surgery groups (64.3±1.4) with an extremely significant difference (p=0.00), (Table 1, Fig.5).

TABLE (1) Comparison of Apex to buccal crest (ABC), apex to lingual crest (ALC) and implant stability (ISQ) in both groups (independent t test)

	Groups	Mean	Std. Dev.	Std. Error Mean	Difference				t	P
					Mean	Std Error	C.I. lower	C.I. lower		
ABC 1	Piezo electric	13.0	0.0	0.0	---	--	--	--	0	1 ns
	Disc	13.0	0.0	0.0						
ABC 2	Piezo electric	10.84	0.4	0.1	2.38	0.27	1.80	2.95	8.89	0*
	Disc	8.47	0.8	0.2						
ALC 1	Piezo electric	13.0	0.0	0.0	---	----	---	----	0	1 ns
	Disc	13.0	0.0	0.0						
ALC 2	Piezo electric	10.76	0.4	0.1	2.21	0.25	1.68	2.75	8.88	0*
	Disc	8.55	0.7	0.2						
ISQ 1	Piezo electric	58.1	1.0	0.3	-0.02	0.40	-0.85	0.82	-0.04	0.967 ns
	Disc	58.1	0.9	0.3						
ISQ 2	Piezo electric	64.3	1.4	0.4	4.00	0.50	2.96	5.04	8.01	0*
	Disc	60.3	1.0	0.3						

Significance level p<0.05, * significant, ns=non-significant

C.I.=95% confidence interval

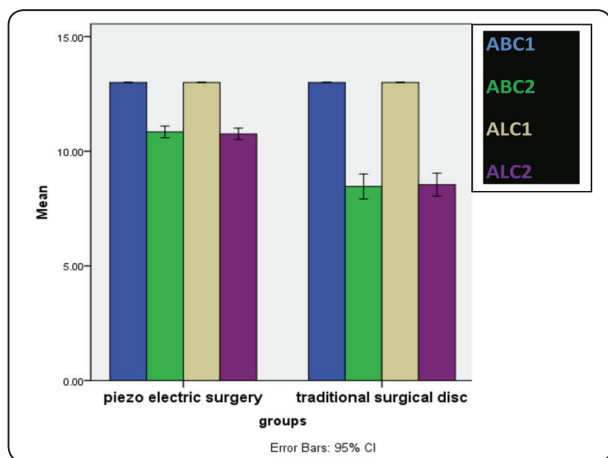


Fig. (4) Column chart showing pre and post mean values of ABC and ALC in both groups

In both groups, Apex to buccal crest (ABC) and apex to lingual crest (ALC) significantly decreased four months after splitting, a greater decrease was

noted in traditional surgical disc group (table 2, Fig. 4). In both groups, secondary implant stability was significantly higher than primary implant stability (p=0.00). A greater increase was noted in piezo electric surgery group (table 2, Fig.5).

Four months after splitting, a higher mean percent decrease in Apex to buccal crest (ABC) and apex to lingual crest (ALC) was recorded in traditional surgical disc group (-34.87±5.84; -34.26±5.41 for ABC and ALC respectively) with an extremely significant difference (p=0.00) between groups. Also, a higher mean percent increase in implant stability (ISQ) was recorded in Piezo electric surgery group (10.62±1.44) with an extremely significant difference (p=0.00) between groups. Strong positive correlation was reported between ABC2 and ISQ2, ALC2 and ISQ2 in both groups.

TABLE (2) Comparison of pre and post treatment Apex to buccal crest (ABC), apex to lingual crest (ALC) and implant stability (ISQ) within the same group (paired t test)

		Mean	Std. Dev.	Std. Error Mean	Paired Difference					t	P
					Mean	Std. Dev.	Std Error	C.I. lower	C.I. lower		
Piezo electric surgery	ABC 1	13.00	0.00	0.00	2.16	0.41	0.12	1.90	2.41	18.42	0.00*
	ABC 2	10.84	0.41	0.12							
	ALC 1	13.00	0.00	0.00	2.24	0.39	0.11	1.99	2.49	19.92	0.00*
	ALC 2	10.76	0.39	0.11							
	ISQ 1	58.08	1.00	0.29	-6.17	0.83	0.24	-6.70	-5.64	-25.59	0.00*
	ISQ 2	64.25	1.36	0.39							
Surgical disc	ABC 1	13.00	0.00	0.00	4.53	0.76	0.24	3.99	5.08	18.87	0.00*
	ABC 2	8.47	0.76	0.24							
	ALC 1	13.00	0.00	0.00	4.45	0.70	0.22	3.95	4.96	20.02	0.00*
	ALC 2	8.55	0.70	0.22							
	ISQ 1	58.10	0.88	0.28	-2.15	0.58	0.18	-2.56	-1.74	-11.73	0.00*
	ISQ 2	60.25	0.98	0.31							

Significance level p<0.05, * significant, ns=non-significant C.I.=95% confidence interval

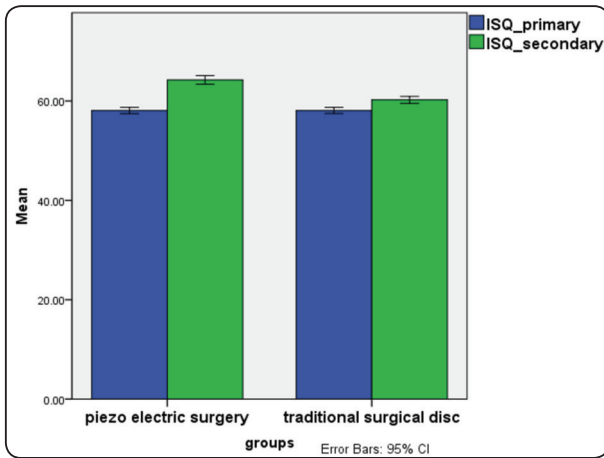


Fig. (5) Column chart showing pre and post mean values of implant stability ISQ in both groups

DISCUSSION

Alveolar ridge splitting and expansion is a successful technique. It involves inducing green stick fracture and lateralization of the buccal cortical plate of the alveolar ridge allowing dental implant placement in atrophic alveolar ridges (Simion et al. 1992, Scipioni et al. 1994, Duncan & Westwood 1997, Elnayef et al. 2015, Bassetti et al. 2016, Mestas et al. 2016).

Implant insertion simultaneously with ridge splitting allows decreased number of surgeries and surgical trauma for the patient but may be associated with some difficulties met by the operator in ideal positioning of the implant and obtaining sufficient primary stability, and may be associated with future crestal bone loss (Geherke et al. 2016).

In our study, the ridge splitting osteotomies was performed using the piezoelectric device in group 1 (test group) owing to its precise atraumatic cutting, reduced heat generation, reduced fracture risks and decreased postoperative necrosis (Horton et al. 1975, Aro et al. 1981, Vercellotti et al. 2001a, b) suggested that this may have positive effect on the crestal bone after implant insertion.

For ridge expansion, the engine driven ridge expanders were selected to be used instead of using

the conventional osteotomes or chisel and mallet since proved to be a successful alternative in the literature (Beolchini et al. 2014, 2015, Ella et al. 2014 and Tang et al. 2015).

Percussion and tests for mobility with the help of radiographs are classically used to evaluate the stability of dental implants and the osseointegration but usually these methods lack sensitivity and standardization and are affected by the clinician variables (Meredith et al. 1997a, b, Scipioni et al. 1997, Fischer et al. 2008).

The resonance frequency analysis (RFA) using the ostell allows the clinical evaluation of the implant stability quotient (ISQ) values and has been successfully used during the last decade (Meredith et al. 1997a,b and Da silva netro et al. 2014).

In our study, The primary and secondary implant stability (ISQ1, ISQ2) had been evaluated using the Ostell™ being rapid, standardized method and easily accepted by the patients .

During patient selection, strict inclusion and exclusion criteria were used to minimize the variables that may have an effect on the result. All patients have mandibular deficient ridge with one or two missing teeth with 1 mm at least trabecular bone present between the buccal and lingual plates to allow bone to spread adequately on either side of the ridge and maintain adequate blood supply.

Regarding the statistical results of our study, both groups recorded the same (ABC1) and (ALC1) Since implants with the same length 13 mm were used in all cases and all were placed subcrestally by 1.5 mm. Also, no significant differences were found between the two groups in the mean primary ISQ values.

Both groups showed significant decrease in ABC and ALC after 4months of implant insertion which was in accordance to previous studies that reported marginal bone loss around implants placed simultaneously with ridge splitting related to the trauma from splitting and remodeling process

(Strietzel et al. 2002, Jensen et al. 2009 and Rossi et al. 2014).

Significant Greater decrease in both ABC and ALC was noted in the surgical disc group (group 2) after 4 months of splitting compared to the piezoelectric group which indicates less crestal resorption in the piezoelectric surgery group after splitting. These may be explained by the atraumatic cutting with reduced heat generation obtained by the piezoelectric surgery (Holtzclaw et al. 2010 , Sohn et al. 2010).

Regarding the implant secondary stability ISQ2, higher mean values were recorded in the piezo group with an extremely significant difference between groups. This can be explained by previous studies that showed that the RFA is affected by the part of the implant exposed above bone level (Gupta et al. 2011).

Strong positive correlation was reported between ABC2 and ISQ2, ALC2 and ISQ2 in both groups. This is in accordance to previous studies that shown that stability increased when bone-implant contact surface area increased (Balleri et al. 2002, Calandriello et al. 2003 and Turkyilmaz et al. 2007).

CONCLUSION

Implants placed simultaneously with piezoelectric-alveolar ridge splitting exhibits decreased marginal bone loss and greater secondary ISQ when compared to Implants placed simultaneously with surgical disc- alveolar ridge splitting.

REFERENCES

- Aghaloo TL, Moy PK. Which hard tissue augmentation techniques are the most successful in furnishing bony support for implant placement. *Int J Oral Maxillofac Implants*; 22(suppl): 49-70. 2007.
- Araujo MG, Lindhe J. Dimensional ridge alterations following tooth extraction. An experimental study in the dog. *J Clin Periodontol*; 32:212-218. 2005.
- Aro H, Kallioniemi H, Aho AJ, Kellokumgo –Lehtinen P. Ultrasonic device in bone cutting : a histologic and

scanning electron microscopical study . *Acta Orthop Scand* .:52:5-10.1981

- Balleri P, Cozzolino A, Ghelli L, Momichioli G, Varriale A. Stability measurements of osseointegrated implants using Osstell in partially edentulous jaws after one year of loading: a pilot study. *Clin Implant Dent Relat Res*; 4:128–132. 2002.
- Bassetti, M.A., Bassetti, R.G. & Bosshardt, D.D. The alveolar ridge splitting/expansion technique: a systematic review. *Clinical Oral Implants Research*, 27: 310–324.2016.
- Beolchini M, Lang NP, Ricci E, Bengazi F, Triana BG & Botticelli D. Influence on alveolar resorption of the buccal bony plate width in the edentulous ridge expansion. *Clin Oral Implants Res*; 26: 109–114.2015.
- Beolchini M, Lang NP, Vigano P, Bengazi F, Triana BG & Botticelli D. The edentulous ridge expansion technique an experimental study in the dog. *Clin Oral Implants Res*; 25: 1207–1211.2014
- Blus C, Szmukler-Moncler S. Split-crest and immediate implant placement with ultra-sonic bone surgery: a 3-year life-table analysis with 230 treated sites. *Clin Oral Implants Res*; 17:700–707. 2006.
- Buser D, Braegger U, Lang NP, Nyman S. Regeneration and enlargement of jaw bone using guided tissue regeneration. *Clin Oral Implants Res* ; 1: 22–32.1990.
- Calandriello R, Tomatis M, Vallone R, Rangert B, Gottlow J. Immediate occlusal loading of single lower molars using Branemark System Wide-Platform TiUnite implants: an interim report of a prospective open-ended clinical multicenter study. *Clin Implant Dent Relat Res*; 5(Suppl 1): 74–80. 2003.
- Coatoam GW, Mariotti A. The segmental ridge-split procedure. *J Periodontol*; 74:757–770. 2003.
- Da Silva Neto UT, Joly JC, Gehrke SA. Clinical analysis of the stability of dental implants after preparation of the site by conventional drilling or piezosurgery. *Br J Oral Maxillofac Surg* ; 52:149–153. 2014.
- Devlin H, Ferguson MJ. Alveolar ridge resorption and mandibular atrophy. A review of the role of local and systemic factor. *Br Dent J*; 170: 101-104.1991
- Duncan JM, Westwood RM. Ridge widening for thin maxilla: A clinical report. *Int J Oral Maxillofac Implants*; 12(2):224-227.1997.
- Ella, B., Laurentjoye, M., Sedarat, C., Coutant, J.C., Masson, E. & Rouas, A. Mandibular ridge expansion

- using a horizontal bone-splitting technique and synthetic bone substitute: an alternative to bone block grafting? *International Journal of Oral Maxillofacial Implants*; 29: 135–140.2014.
- Elnayef B, Monje, A, Lin, GH, Gargallo-Albiol, J, Chan, HL, Wang, HL & Hernandez-Alfaro F. Alveolar ridge split on horizontal bone augmentation: a systematic review. *International Journal of Oral Maxillofacial Implants* ; 30: 596–606. 2015.
 - Favero G & Botticelli, D. Bone-healing pattern at the surface of titanium implants: an experimental study in the dog. *Clinical Oral Implants Research*; 25: 124–131.2014.
 - Fischer K, Stenberg T, Hedin M, Sennerby L. Five-year results from a randomized, controlled trial on early and delayed loading of implants supporting full-arch prosthesis in the edentulous maxilla. *Clin Oral Implants Res*; 19:433–441.2008.
 - Gehrke SA, Fernandez SA, Rosetti PHO. Stability and crestal bone behavior following simultaneous placement of multiple dental implants (Two or More) with the bone splitting technique: A Clinical and Radiographic Evaluation. *Clin Implant Dent Relat Res* .00:1-8, 2016.
 - Glick M, Greenberg MS, Ship JA: Introduction to Oral Medicine and Oral Diagnosis: Evaluation of the dental patient. In *Burket's oral medicine*. eleventh ed, Greenberg MS, Glick M, Ship JA.. Bc decker inc. Hamilton, pp 1-16. 2008
 - Gupta RK, Padmanabhan TV. Resonance frequency analysis. *Indian journal of dental research*. 22:567.2011
 - Holtzclaw DJ, Toscano NJ, Rosen PS. Reconstruction of posterior mandibular alveolar ridge deficiencies with the piezoelectric hinge-assisted ridge split technique: a retrospective observational report. *J Periodontol*; 81(11):1580-1586.2010.
 - Horton JE, Tarpley TM, Wood LD. The healing of surgical defects in alveolar bone produced with ultrasonic instrumentation, chisel and rotary bur. *Oral Surg Oral Med Oral Pathol*. 39:536-46. 1975
 - Jensen OT, Cullum DR, Baer D. Marginal bone stability using 3 different flap approaches for alveolar split expansion for dental implants: a 1-year clinical study. *J Oral Maxillofac Surg*; 67:1921–1930.2009.
 - Khairnar MS, Khairnar D, Bakshi K. Modified ridge splitting and bone expansion osteotomy for placement of dental implant in esthetic zone. *Contemp Clin Dent*; 5(1):110-114.2014.
 - Kolerman, R., Nissan, J. and Tal, H. Combined Osteotome-Induced Ridge Expansion and Guided Bone Regeneration Simultaneous with Implant Placement: A Biometric Study. *Clinical Implant Dentistry and Related Research*, 16, 691-704.2014.
 - Lekovic V, Camargo PM, Klokkevold PR, Weinlaender M, Kenney EB, Dimitrijevic B, Nedic M. Preservation of alveolar bone in extraction sockets using bioabsorbable membranes. *J Periodontol*; 69: 1044-1049.1998
 - Mazzocco F, Nart J, Cheung WS, Griffin TJ. Prospective evaluation of the use of motorized ridge expanders in guided bone regeneration for future implant sites. *Int J Periodontics Restorative Dent*; 31(5): 547-554.2011
 - Meredith N, Book K, Friberg B, Jemt T, Sennerby L. Resonance frequency measurements of implant stability in vivo. A cross-sectional and longitudinal study of resonance frequency measurements on implants in the edentulous and partially dentate maxilla. *Clin Oral Implants Res*; 8:226–233.1997 a
 - Meredith N, Shagaldi F, Alleyne D, Sennerby L, Cawley P. The application of resonance frequency measurements to study the stability of titanium implants during healing in the rabbit tibia. *Clin Oral Implants*; 8:234–243.1997 b
 - Mestas G, AlarcoAn M, Chambrone L. Long-Term Survival Rates of Titanium Implants Placed in Expanded Alveolar Ridges Using Split Crest Procedures: A Systematic Review. *Int J Oral Maxillofac Implants*; 31(3):591- 599.2016.
 - Misch CE – *Contemporary Implant Dentistry*; Second Edition Mosby Inc. 1999.
 - Misch CM. Implant site development using ridge splitting techniques. *Oral Maxillo fac Surg Clin North Am*; 16:65–74. 2004.
 - Nkenke E, Radespiel-Troger M, Wiltfang J, Schultze-Mosgau S, Winkler. Morbidity of harvesting retromolar bone grafts: A prospective study. *Clin Oral Implants Res*; 13: 514-521 .2002.
 - Rocuzzo M, Ramieri G, Bunino M, Berrone S. Autogenous bone graft alone or associated with titanium mesh for vertical alveolar ridge augmentation: A controlled clinical trial. *Clin Oral Implants Res*;18: 286–294.2007.
 - Rossi F, Lang NP, De Santis E, Morelli F,Favero G& Botticelli D.Bone healing pattern at the surface of titanium implants : an experimental study in the dog . *Clinical Implants Oral Research* ; 25:124-131.2014.

- Schropp L, Wenzel A, Kostopoulos L, Karring T. Bone healing and soft tissue contour changes following single-tooth extraction: A clinical and radiographic 12-month prospective study. *Int J Periodontics Restorative Dent*;23:313-323.2003.
- Scipioni A, Bruschi GB, Giargia M, Berglundh T, Lindhe J. Healing at implants with and without primary bone contact. An experimental study in dogs. *Clin Oral Implants Res*; 8:39-47.1997.
- Scipioni A, Bruschi GB, Calesini G. The edentulous ridge expansion technique: a five-year study. *Int J Periodontics Restorative Dent*; 14:451-459.1994.
- Sethi, A. & Kaus, T. Maxillary ridge expansion with simultaneous implant placement: 5- year results of an ongoing clinical study. *International Journal of Oral Maxillofacial Implants* 15: 491-499.2000.
- Simion M, Baldoni M, Zaffe D. Jawbone enlargement using immediate implant placement associate with a split crest technique and guide tissue regeneration. *Int J Periodontics Restorative Dent*; 12(6):462-473.1992
- Sohn DS, Lee HJ, Heo JU, Moon JW, Park IS, Romanos GE. Immediate and Delayed Lateral Ridge Expansion Technique in the Atrophic Posterior Mandibular Ridge. *J Oral Maxillofac Surg*; 68(9): 2283-2290.2010.
- Strietzel FP, Nowak M, Kuchler I, Friedmann A. Periimplant alveolar bone loss with respect to bone quality after use of the osteotome technique: results of a retrospective study. *Clin Oral Implants Res*; 13:508-513.2002
- Suh JJ, Shelemay A, Choi SH, Chai JK. Alveolar ridge splitting: a new microsaw technique. *Int J Periodontics Restorative Dent*; 25:165-171.2005.
- Tang, Y.L., Yuan, J., Song, Y.L., Ma, W., Chao, X. & Li, D.H. Ridge expansion alone or in combination with guided bone regeneration to facilitate implant placement in narrow alveolar ridges: a retrospective study. *Clinical Oral Implants Research* 26: 204-211.2015.
- Tessier P, Kawamoto H, Posnick J, Raulo Y, Tulasne JF, Wolfe SA. Complications of harvesting autogenous bone grafts: A group experience of 20.000 cases. *Plast Reconstr Surg*; 116:72S-73S.2005.
- Turkyilmaz I, Teözüm TF, Tümer C. Bone density assessments of oral implant sites using computerized tomography. *J Oral Rehabil*; 34:267-272.2007.
- Vercellotti T, Crovace A, Palermo A, Molfetta A. The piezoelectric osteotomy in orthopedics: Clinical and histological evaluations (pilot study in animals). *Mediterr J Surg Med.* ; 9:89-96.2001 a
- Vercellotti T, De Paoli S, Nevins M. The piezoelectric bony window osteotomy and sinus membrane elevation: introduction of a new technique for simplification of the sinus augmentation procedure. *Int J Periodontics Restorative Dent.*;21:561-7. 2001 b
- Von Arx T, Buser D. Horizontal ridge augmentation using autogenous block grafts and the guided bone regeneration technique with collagen membranes: A clinical study with 42 patients. *Clin Oral Implants Res*;17: 359-366.2006.