



AN EVALUATION OF KNOWLEDGE AND PREFERENCE OF PROSTHODONTIC, ORTHODONTIC OR INTEGRATED TREATMENT OPTIONS FOR PEG SHAPED MAXILLARY LATERAL INCISORS AMONG GENERAL PRACTITIONERS IN KINGDOM OF SAUDI ARABIA-A SURVEY

Ahmed Alassiry *

ABSTRACT

Background and objective: The requirement for dental specialties and the number of specialists in each country depends mainly on the complex oral health care needs of the society. Missing lateral incisor or Peg shaped lateral incisor is such a condition. The aim of this study was to assess the awareness of general practitioners regarding needs of prosthodontic, orthodontic, or integrated treatment approach for management of peg shaped lateral incisor through a self-represented survey.

Methodology: A Cross-sectional study was planned to conduct a survey using questionnaire containing 16 questions which were mailed and distributed to random sample of 292 general dental surgeons who voluntarily took part in the study.

Results: Results were self-descriptive due to simple form of questionnaire. Most important goal for the treatment according to 80.7% responders was improvement in esthetics. According to responders, malocclusion was the most important factor (41.6%) which influences the treatment plan. 73.9 % responders told that they prefer to refer the patient to specialist when patients are reported with malocclusion and highly esthetic demand. Almost 40% responders do the diagnostic wax up in such cases. 43.2% responders decided to plan prosthetic treatment after completion of orthodontic treatment and for that full coverage crown was the most preferred choice for rehabilitation. 90.1% of responders believed that combination of both orthodontic and prosthodontic approach was best to achieve the perfect treatment outcome.

Conclusion: Pre restorative orthodontic treatment is best for management of peg lateral incisor. Multidisciplinary approach towards the complex dental treatment is always better for the best treatment outcome. Referral system is also developed by such means.

KEY WORDS: Peg shaped, Lateral incisors.

* Assistant Professor, Department of Preventive Dental Sciences, Faculty of Dentistry, Najran University, Saudi Arabia

INTRODUCTION

Misshaped tooth is caused by the anomalies in the tooth formation process during initiation or proliferation of tooth bud. This is generally considered to be inherited dominant condition with lots of variation in expression. When there is late disturbance during differentiation process, most commonly the size of tooth is affected.

A peg lateral can be defined as an undersized, tapered, maxillary lateral incisor. Other anomalies can also be associated with it like over retained deciduous teeth or canine transposition etc. The peg-shaped lateral incisor is one that has an incisal mesiodistal width of the tooth crown shorter than the cervical width. This can lead to aesthetic, function and periodontal problems for the patient.

Whenever there is malformed maxillary lateral incisor, the individual also has midline diastema which results due to distal migration of central incisor. Due the reduced size of lateral incisors, formation of other diastema is also more likely to take place. Normally, such patients exhibit an otherwise normal dentition.

Prevalence of peg shaped lateral incisor has been much more than the prevalence of any other developmental disturbance in the oral cavity. The prevalence of peg-shaped maxillary permanent lateral incisors varies by race, population type, and sex. The prevalence rates were higher among Mongoloid people, orthodontic patients, and women. Although the prevalence of unilateral and bilateral lateral incisors was the same, the left side was twice as common as the right side. Subjects with unilateral peg-shaped maxillary permanent lateral incisors might have a 55% chance of having lateral incisor hypodontia on the contralateral side.^[1]

It has always been a challenge for prosthodontists and orthodontists to treat a young patient with anterior spaces and/or presence of peg shaped lateral incisor. To resolve this problem, generally speaking there are two principal approaches. First approach aims at maintenance of spaces for future

auto transplantation or restoring with prosthodontic approach if extraction is planned. The alternative way is to close the spaces orthodontically and then restoration of peg lateral by prosthetic means i.e. alteration of shape to simulate central incisor.

Each of these approaches has its own advantages and disadvantages and the prevailing conditions also influence the type of treatment plan or approach. Decisions to choose an approach are based on several factors such as type of existing occlusion, space conditions, width of lateral incisor and its root length, the shape and shade of canine, position of canine etc. Apart from this the type of treatment should also be selected based on esthetic and functional requirements, need for extractions and potential for coordinating prosthodontic and orthodontic treatment.^[1-3]

The development of acid-etch technique and new adhesive systems has been a boon to the restorative dentistry. And it provides us with an alternative of adopting integrated approach for management of space closure and restoration of peg lateral in a most satisfactory manner. Because the results rarely are satisfactory when a single approach i.e. prosthodontic or orthodontic alone is adopted.

OBJECTIVES:

The Aims and Objectives of this study are to conduct a survey using questionnaire to evaluate the knowledge and awareness of Saudi general practitioners regarding needs of prosthodontic, orthodontic, or integrated treatment approach for management of peg shaped lateral incisor.

METHODOLOGY:

A Cross-sectional study was planned to conduct a survey using questionnaire containing 16 questions which were mailed and distributed through the Saudi dental society data base to random. Those are not general practitioners excluded from this study and 292 general dental surgeons who voluntarily took part in the study.

Pattern of questionnaire was as mentioned below and the response to the survey was recorded and analyzed electronically.

Q1. Please specify your gender

- a. Male
- b. Female

Q2. How many years have you been practicing general dentistry / specialty?

- a. < 5 years
- b. 5-10 years
- c. > 10 years

Q3. How confident do you feel in treatment planning and treatment of peg lateral?

- a. Need orthodontist
- b. Need prosthodontist
- c. Need services of both
- d. I am confident alone

Q4. What is the most important goal in your opinion in treatment of peg lateral?

- a. Correction of tooth size
- b. Improve esthetics
- c. Correction of occlusion
- d. Correction of tooth position

Q5. What is the most important factor that influences your treatment plan?

- a. Malocclusion
- b. Size of tooth
- c. Treatment facilities
- d. Malocclusion

Q6. In what percentage of these cases is a diagnostic wax up/simulation has been done?

- a. Less than 5%
- b. 5 to 25%
- c. 26 to 50%
- d. More than 51%

Q7. If orthodontic treatment is included then, when do you decide the final treatment plan for restorative/prosthodontic part?

- a. Before orthodontic treatment begins
- b. Early in orthodontic treatment
- c. Towards the end of orthodontic treatment
- d. After orthodontic treatment.

Q8. If restorative or prosthodontic treatment is involved, which of the following restorations would you prefer in such cases?

- a. Composite build up
- b. Porcelain veneers
- c. Full coverage crown

Q9. When restorative/permanent crown treatment is involved, when do you prefer to complete it?

- a. Before orthodontic treatment
- b. Early in orthodontic treatment
- c. Towards the end of orthodontic treatment
- d. After orthodontic treatment

Q10. If peg lateral is planned to be extracted, in order to achieve an optimal esthetic and function which option treatment would you prefer?

- a. Canine replacing lateral incisor and recontoured as lateral incisor
- b. Fixed partial denture
- c. Single tooth implant

Q11. If the peg lateral is decided to be extracted and a single tooth implant is decided as final restoration, then what is the most important factor in your opinion that will influence the time of placement of implant?

- a. Age
- b. Completion of orthodontic treatment
- c. Space available
- d. Width and height of the bone

Q12. After completion of treatment the involving peg lateral, how satisfied are you with the final result in the completion cases involving restorations of laterals and orthodontic treatment?

- a. Satisfied with orthodontics alone
- b. Satisfied with Prosthodontics alone
- c. Satisfied with combination therapy

Q13. What area represents the biggest source of dissatisfaction regarding final results when treatment is done orthodontically and prosthodontic means?

- a. Final tooth position
- b. Size of restoration
- c. Shade of the restoration
- d. Long treatment time

Q14. What difficulties did you face during communication with specialists?

- a. They did not respond properly/delayed response
- b. Specialists not available in the same place
- c. Lack of multidisciplinary specialists at the same place
- d. I did not face any difficulty

RESULTS

Data record and analysis was done electronically and results of the questionnaire were self-explanatory. Starting with the 1st question, 50.5% were females who took part tin survey. 60% of total responders were fresh who were in practice since less than 5 years. 42% responders were in need of services of both orthodontist and prosthodontist for the management of peg lateral incisors. (Table 1 & Figure 1)

TABLE (1) Need of a consultant

How confident do you feel in treatment planning and treatment of peg lateral?		
Answer Options	Response Percent	Response Count
Need orthodontist	5.7%	12
Need prosthodontist	26.8%	56
Need services of both	42.6%	89
I am confident alone	24.9%	52
<i>answered question</i>		209
<i>skipped question</i>		83

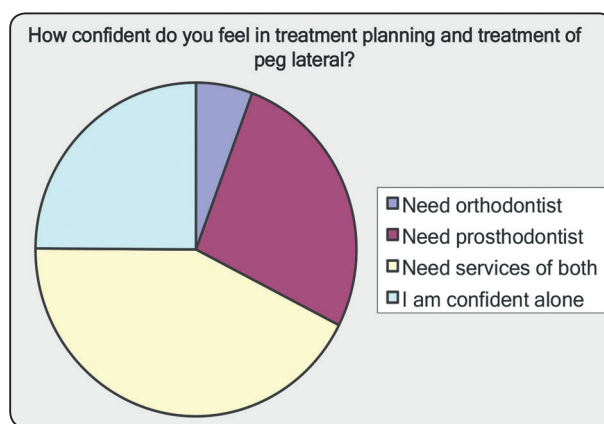


Fig. (1) Need of a consultant

Most important goal for the treatment according to 80.7% responders was improvement in esthetics. (Table 2 & Figure 2)

TABLE (2) Most important goal of the management of peg lateral

What is the most important goal in your opinion in treatment of peg lateral?		
Answer Options	Response Percent	Response Count
Correction of tooth size	9.7%	20
Improve esthetics	80.7%	167
Correction of occlusion	8.7%	18
Correction of tooth position	1.0%	2

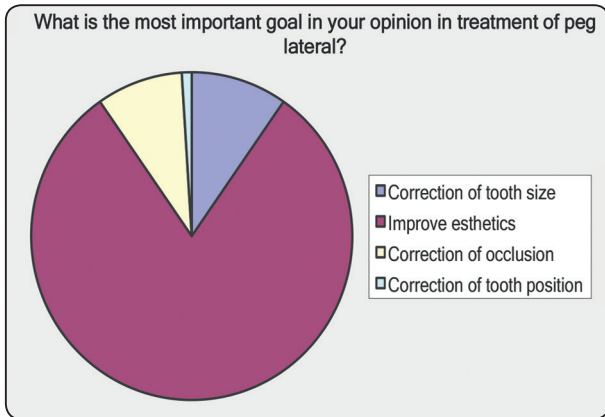


Fig. (2) Most important goal of treatment

According to responders, malocclusion was the most important factor (41.6%) which influences the treatment plan. 73.9 % responders told that they prefer to refer the patient to specialist when patients are reported with malocclusion and highly esthetic demand. (Table 3 and 4)

TABLE (3) Most important factor that influence the treatment plan

What is the most important factor that influences your treatment plan?		
Answer Options	Response Percent	Response Count
Malocclusion	41.6%	87
Size of tooth	39.2%	82
Treatment facilities	14.8%	31
Treatment time	4.3%	9

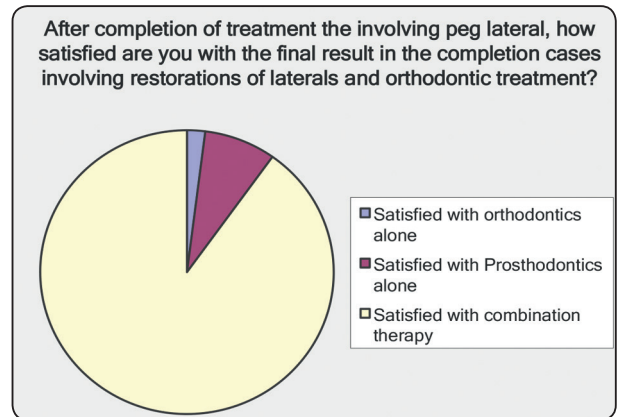


Fig. (3) Presentation of best approach for the treatment of peg lateral incisor.

TABLE (4) Preference to refer the case to the specialist.

When do you prefer to refer the case to specialist?

Answer Options	Response Percent	Response Count
Patients with high esthetic demand	4.3%	9
Patients presenting with malocclusion	21.7%	45
Patients with esthetic demand coupled with malocclusion	73.9%	153

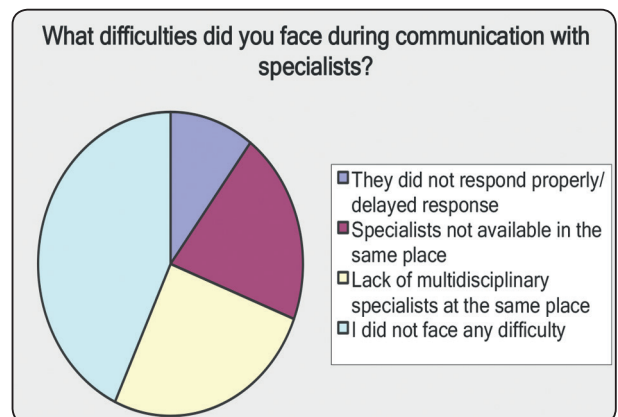


Fig. (4) Difficulties in communication with the specialist

Almost 40% responders do the diagnostic wax up in such cases. 43.2% responders decided to plan prosthetic treatment after completion of orthodontic treatment and for that full coverage crown was the most preferred choice for rehabilitation in regard question 6,7 and 8.

Single tooth implant was the choice of the treatment when peg lateral tooth was planned extraction in search of maximum esthetic outcome and for that width and height of the bone was the most important factor to be considered according to responders. 90.1% of responders believed that combination of both orthodontic and prosthodontic approach was best to achieve the perfect treatment outcome. (Figure 3)

Long treatment time was the biggest factor of dissatisfaction after interdisciplinary approach for the management of peg lateral incisor. 43.1% of responders didn't find any difficulty in communication with the specialist. (Figure 4)

DISCUSSION

Maxillary lateral incisor agenesis is the most common congenitally missing permanent tooth condition in the maxillary anterior region (esthetic zone), representing approximately 20% of all dental anomalies. [1-4]. The susceptibility of maxillary lateral incisors to dental agenesis has been associated with their anatomical position in the maxillary arch and also the fact that they are the last teeth to develop in their respective classes [4]. One of the most challenging problems in dentistry is the treatment option for replacement of one or more maxillary lateral incisors that have been lost as a result of traumatic injuries or congenitally missing or which are having abnormal structure i.e. peg lateral incisor. [5,6]. Age, location, space limitations, alveolar ridge deficiencies, uneven gingival margins, occlusion, and periodontal factors often necessitate an interdisciplinary approach [7, 8]. Thus the management of misshaped maxillary lateral incisor

needs multiple dental specialties like Orthodontics, Oral surgery, Periodontics and Prosthodontics. In our study, management of peg lateral incisor was the focused goal. According to the results of previous similar studies, generally the treatment options include space maintenance or later incisor rehabilitation with prostheses, extraction followed by dental implants, or orthodontic space closure with camouflaging the maxillary canine to resemble the appearance of a lateral incisor [2,3]. In our study we tried to assess the knowledge of the general dentist to manage the patient with peg lateral incisor depends upon functional and esthetic demand of patient. As concluded by Abu Hussein M et al, when space opening is indicated, both orthodontist and prosthodontist perform a key role in determining and establishing space requirements which is similar to our findings [5,6]. The restorative approaches can be divided into two categories (single tooth implant, and tooth supported restorations) where dental implants are the most commonly used to rehabilitate congenitally missing maxillary lateral incisors once skeletal maturity has been reached which is similar to our survey finding. [6,7] When dental implants are contra-indicated, there are mainly three available options: removable partial denture, resin bonded bridge which is a minimally invasive option for rehabilitation of congenitally missing lateral incisor, and full coverage fixed partial denture [7,8].

Legislation regulating dental practice permits general dentists to perform a broad range of complex procedures that are also performed by dental specialists. A general dentist's decision to perform treatment or to refer a patient to a specialist depends on the competence of the general dentist, patients' expectation, the available specialists in the same dental office, the accessibility of specialized dental treatment in the region, the time involved, cost of treatment, motivation of the patient, etc. [9-12] Pre-restorative orthodontic alignment has distinct advantages especially in patients with malaligned dentition seeking prosthetic rehabilitation.

Exodontia is not a popular treatment option anymore unless the clinician has to deal with teeth that are grossly infected or mutilated. Even malformed teeth are being retained and restored for an optimal esthetic result. As stated by Spalding PM, Cohen BD A, thorough discussion of the pre-restorative orthodontics, visualization of the end result through a diagnostic wax-up and agreeing upon a sequential comprehensive treatment plan, are all necessary steps in the diagnostic work-up of these cases. ^[13] Similar to that conclusion, in our study also, almost 40% responders preferred to do diagnostic wax up for the proper treatment planning.

The benefits of pre-restorative alignment have been well documented. ^[14-16] It is advantageous especially in patients with mal-aligned dentition seeking prosthetic rehabilitation. A common orthodontic-restorative problem is a peg-shaped or malformed maxillary lateral incisor. In some patients, the best choice for treating a peg-shaped lateral incisor is to restore the malformed tooth to its correct dimension. If sufficient space exists, a composite restoration may be placed before orthodontic treatment. However, in most situations, there is insufficient space to restore the malformed lateral incisors. Therefore, orthodontics is often necessary to create space to build-up peg-shaped lateral incisors. Sadowsky SJ and Zitzmann NU et al stated that full cast crowns were the choice of restoration as a final restoration for peg lateral incisors after orthodontic treatment ^[17,18] The results were similar to our study in which most responders preferred rehabilitation treatment after orthodontic treatment that too with full cast crowns.

It is clear that when esthetic expectations are more and the malocclusion is severe in patients with peg lateral incisors, multidisciplinary approach is always recommended. In the present study, implant restoration is the treatment of choice among general dentists when extraction of peg shaped lateral incisor is planned to achieve optimal aesthetic and function. 78.6% general dentists preferred to restore

extracted peg shaped lateral with single tooth implant. Reasons are obvious. Dental implants are designed to last a lifetime, unlike other tooth replacement options such as dentures and bridges. This advantage has to do with the implant's ability to naturally fuse with the existing jawbone through a process called osseointegration at the same time dental implants allow for the oral health to be restored as closely as possible to its natural state and function. With traditional tooth replacement options like bridges and partial dentures, the surrounding teeth are often utilized as anchors, resulting to the possibility of the adjacent teeth being compromised. On the other hand, dental implants do not depend on the adjacent natural teeth, thus avoiding the possibility of the surrounding structures being compromised and damaged. Implant at the same time are easier to take care of their health.

Communication with the specialist has a key role in treatment plan. Previous studies has been done to assess the communication level between general dentists and orthodontist for the management of complex cases. ^[19] By any communication way, involvement of orthodontist and prosthodontist in the management of peg lateral incisor gives the excellent treatment outcome with great satisfaction both to the patient and clinician. Now a days, team approach is the widely accepted theory for the complex treatment. Our study objective was one of the examples of such multidisciplinary approach to various dental treatments.

CONCLUSION

Management of Peg lateral incisor with multidisciplinary approach with the help of orthodontist and prosthodontist has the best treatment outcome. A joint clinic of different specialty e.g. orthodontic, prosthodontic, oral surgery and pedodontic will guide general practional for multidisplanary approach and minimize the time required for such case treatment decision. The referral system to the specialist is needed to be improved in developing countries.

REFERENCES

1. Hua F, He H, Ngan P, Bouzid W. Prevalence of peg shaped maxillary lateral incisors: A meta analysis. *Americal journal of Ortodontics and dentofacialorthopaedics*. 2013(1) 97-109
2. Abu-Hussein M, Abdulgani A, Watted N, Zahalka M (2015) Congenitally Missing Lateral Incisor with Orthodontics, Bone Grafting and Single-Tooth Implant: A Case Report. *J Dent Med Sci* 14: 124-130.
3. Abdulgani A, Kontoes N, Chlorokostas G, Abu-Hussein M (2015) Interdisciplinary Management Of Maxillary Lateral Incisors Agenesis With Mini Implant Prostheses: A Case Report. *J Dent Med Sci* 14: 36-42
4. Abusalih A, Ismail H, Abdulgani A, Chlorokostas G, Abu-Hussein M (2016) Interdisciplinary Management of Congenitally Agenesis Maxillary Lateral Incisors: Orthodontic/Prosthodontic Perspectives. *J Dent Med Sci* 15: 90-99.
5. Abu-Hussein M, Watted N, Abdulgani A, Borbély B (2015) Modern Treatment for Congenitally Missing Teeth: A Multidisciplinary Approach; *International Journal of Maxillofacial Research* 1: 179-190
6. Abu-Hussein M, Chlorokostas G, Watted N, Abdulgani A, Jabareen A (2016) Pre-Prosthetic Orthodontic Implant for Management of Congenitally Unerupted Lateral Incisors – A Case Report. *J Dent Med Sci* 15: 99-104
7. Abu-Hussein M, Watted N, Hegedus V, Péter B (2015) Congenitally Missing Upper Laterals. *Clinical Considerations: Orthodontic Space Closure* 1: 1-6
8. Rendon J (2005) Effect of congenitally missing lateral incisors on the eruption and impaction of the maxillary canine: Saint Louis University.
9. Ghiabi E, Matthews DC. Periodontal practice and referral profile of general dentists in Nova Scotia, Canada. *J Can Dent Assoc* 2012;78:c55.
10. Small BW. Decision-making in full-arch restorative dentistry: part 2. *Gen Dent* 2010;58:10–3.
11. Maupome G, Schrader S, Mannan S, Garetto L, Eggertsson H. Diagnostic thinking and information used in clinical decision-making: a qualitative study of expert and student dental clinicians. *BMC Oral Health* 2010; 10:11.
12. Lee JH, Bennett DE, Richards PS, Inglehart MR. Periodontal referral patterns of general dentists: lessons for dental education. *J Dent Educ* 2009;73:199–210.
13. Spalding PM, Cohen BD. Orthodontic adjunctive treatment in fixed prosthodontics. *Dent Clin North Am*. 1992; 36(3):607-629.
14. Kokich V, Spear F. Guidelines for managing the orthodontic/restorative patient. *SeminOrthod*. 1997;3:3-20.
15. Schmitz J, Coffano R, Bruschi A. Restorative and orthodontic treatment of maxillary peg incisors: a clinical report. *J Prosthet Dent*. 2001;85:330-334.
16. Chaushu S, Becker A, Zalkind M. Prosthetic considerations in the restoration of orthodontically treated maxillary lateral incisors to replace missing central incisors: a clinical report. *J Prosthet Dent*. 2001;85(4):335-341.
17. Sadowsky SJ. An overview of treatment considerations for esthetic restorations: a review of the literature. *J Prosthet Dent*. 2006;96(6):433-442.
18. Zitzmann NU, Galindo ML, Hagmann E, Marinello CP. Clinical evaluation of ProceraAllCeram crowns in the anterior and posterior regions. *Int J Prosthodont*. 2007; 20(3):239-241.
19. Bibona K. Examination of the communication practices and preferences between orthodontists and general dentists. 2014