

TOOTH LOSS FOLLOWING SURGICAL EXTRUSION OF CROWN-ROOT FRACTURED TEETH: A 6-YEARS SURVIVAL ANALYSIS

Ahmed Elkhadem* and Hany Saber*

ABSTRACT

Aim: This study aimed to show the adverse effect of surgical extrusion technique in the management of crown-root fractures regarding tooth loss over a six-year follow-up period.

Methods: Twenty patients with a crown-root fracture in maxillary incisors were selected from an outpatient clinic in pediatric dentistry department- Cairo University. Twelve males and eight females with age range from 11-14 years participated in this study. Surgical extrusion was performed combined with endodontic treatment. Patients were recalled every year following surgical extrusion to assess the risk of tooth loss.

Results: Twenty patients participated in this study with mean age of 131 months. Only 17 patients completed a follow-up period of at least one year. Overall, five teeth were lost over a follow-up period of six years constituting 29% (95% CI 13 to 53%) of the study population.

Conclusion: Surgical tooth extrusion could be considered as a treatment option for crown-root fractures. Nevertheless, tooth loss is not an uncommon adverse effect. The first two years are critical for deciding the survival of surgical extruded tooth.

INTRODUCTION

Loss of anterior maxillary teeth early in life can result in esthetic, functional and psychological complications. Trauma to anterior teeth may cause various forms of tooth fracture, one of which is crown-root fracture defined as a fracture passing through enamel, dentin and cementum. Crown-root fractures constitute a challenge as the fracture line moves subgingivally, creating difficulty during restorative procedures.

There is a general agreement that tooth-restorative interface should be placed supra-gingival to avoid encroachment on gingival biologic width, hence increase the long-term success of the treatment⁽³²⁾. Setting the margin of the restoration sub-gingival frequently leads to chronic gingivitis, the loss of clinical attachment, bony pockets and gingival recessions^(21, 29).

Four treatment possibilities have been proposed to treat crown-root fracture; tooth extraction, intentional replantation, surgical crown lengthening

* Lecturer in Pediatric Dentistry, Faculty of Dentistry, Cairo University.

and root extrusion. Tooth removal seems to be the easiest choice, yet it requires prosthetic treatment or implant therapy which has their limitation in young age⁽¹⁵⁾. Surgical crown lengthening can be successfully used in the posterior region, where esthetics is not a significant concern⁽¹⁸⁾. The surgical approach requires osseous and gingival contouring. Side effects of such a technique in the anterior region includes; lowering gingival papilla and exposing cemento-enamel junction which causes hypersensitivity and produces compromised esthetics⁽⁵⁾.

Root extrusion was first reported in the seventies^(19, 20) as a treatment modality for treatment of root fractures and non-restorable teeth. It was classified into two techniques; orthodontic and surgical extrusion. Orthodontic extrusion applied and extrusive force via orthodontic appliances to move the root in a cervical direction to expose the fracture line^(6, 9). Surgical root extrusion became more popular in the late seventies⁽⁴²⁾ and early eighties^(23, 37). Kahnberg⁽²²⁾ described a simple surgical technique involving intra-alveolar transplantation. A carefully extruded root, stabilised by inter-dental suturing and surgical dressing, required endodontic therapy and a porcelain crown. This was considered a satisfactory alternative to orthodontic extrusion of the fractured root⁽¹⁵⁾. This study aims to evaluate the six years survival of surgical extruded teeth

Aim of the study

This study aimed to show the adverse effect of surgical extrusion technique in the management of crown-root fractures regarding tooth loss over a six-year follow-up period.

PARTICIPANTS AND METHODS

Study design: A posttreatment survival analysis using Kaplan-Meier estimate was used for a period up to 6 years follow-up. Survival analysis in clinical

trials involve following patients for a long time with a primary event of interest like death, relapse or adverse drug effect.⁽³⁸⁾

All parents signed a written and informed consent permitting their children to take part in the study. Participants were eligible for the study when they present with an incisor tooth suffering complicated or uncomplicated crown-fracture. Vital and necrotic pulps were selected with no predilection. Roots undergoing external or internal root resorption that are evident on a standard periapical film were excluded from the study. Patients were recruited from the outpatient clinic of Pediatric Dentistry Department, Faculty of Oral and Dental Medicine, Cairo University.

All patients were recruited from the outpatient clinic, pediatric dentistry department, or referred from the outpatient clinic- oral and maxillofacial department, Cairo University. Twenty-seven patients were screened; four couldn't commit to long-term follow-up, while 3 showed evident progressive root resorption. Twenty patients enrolled in the trial. Three patients dropped out directly after the surgical extrusion procedures, while 17 continued the follow-up period.






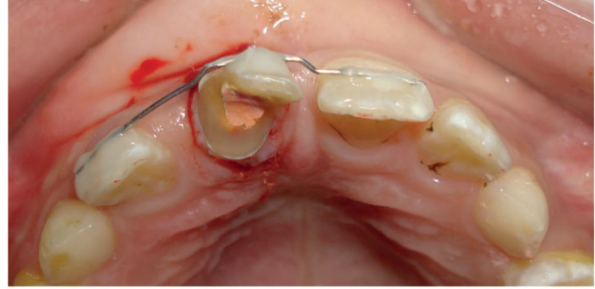
Crown-root fracture was diagnosed with visual inspection of the fractured tooth fragment, periodontal probe to measure the extent of the fracture and radiographically using a periapical film with bisecting angle technique.

After diagnosing the case as crown-root fracture, the patient was enrolled in the study. Clinical examination included percussion test, probing depth using William's graduated periodontal probe. Percussion test with high pitched metallic sound in comparison with neighbouring will presumably indicate the presence of ankylosis (Campbell, Casas et al. 2005). Also, pain on percussion would mean a periapical pathosis. Meanwhile, the digital radiographic examination was performed using bisecting angle technique.

Crown-root fractures are classified according to the direction of fracture line into four types ⁽²⁶⁾. Type A (Oblique; fracture below marginal bone buccal), B (Oblique; fracture margin below marginal bone palatal, C (transverse; fracture margin running bucco-lingual with minimal crown left) and D (lateral; fracture margin below marginal bone mesial or distal).

Surgical extrusion was performed by an anterior extraction forceps. Rotational extraction movement was done with no labial or lingual movements to avoid crushing the periodontal cells against the alveolar bone. The tooth was extruded until the sub-gingival placed fracture margin becomes apparent at least 1 mm supra-gingival.

TABLE (1) Pre-operative and procedural steps for patient number (7)

Pre-operative	Procedural steps
 <p data-bbox="289 1144 628 1172">Extra-oral photograph: Facial view</p>	 <p data-bbox="788 1110 1378 1172">Surgical extrusion using maxillary incisor forceps with rotational movement</p>
 <p data-bbox="289 1591 628 1619">Intra-oral photograph: Frontal view</p>	 <p data-bbox="782 1560 1378 1619">Frontal view: Wire (0.016" round stainless steel wire) and composite splint</p>
 <p data-bbox="289 1951 628 1979">Intra-oral photograph: Occlusal view</p>	 <p data-bbox="788 1920 1378 1979">Occlusal view: Occlusal adjustments made to tooth no. 11 to prevent premature contact during the fixation phase</p>

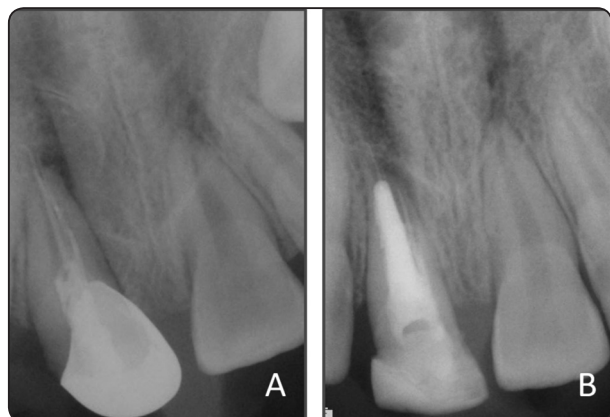


Fig. (1) Pre-operative periapical radiograph (A) and post-surgical extrusion with provisional composite restoration (B) for patient no (7). The patient presented with faulty endodontic obturation and overextension of gutta-percha together with a swaged crown. Figure (B) showed tooth with two years follow up. An apical radiolucency exists, and the patient was complaining of unbearable pain that didn't respond to analgesics nor antibiotics. The tooth was planned for extraction, and a spoon denture was delivered.

TABLE (2) Pre-operative and follow-up photographs for a patient number (7)

Pre-operative	Follow-up
 <p data-bbox="289 1289 628 1310">Extra-oral photograph: Facial view</p>	 <p data-bbox="905 1289 1244 1310">Extra-oral photograph: Facial view</p>
 <p data-bbox="289 1645 628 1666">Intra-oral photograph: Frontal view</p>	 <p data-bbox="905 1645 1244 1666">Intra-oral photograph: Frontal view</p>
 <p data-bbox="289 1989 628 2011">Intra-oral photograph: Occlusal view</p>	 <p data-bbox="905 1989 1244 2011">Intra-oral photograph: Occlusal view</p>

Splinting was performed using a wire and composite splint (semi-rigid splint). The wire diameter was 0.016-inch orthodontic stainless-steel wire. Flow-It® ALC™ flowable composite was used taking care not to extend the composite over the inter-proximal part of the wire to avoid increasing the rigidity of the splint which may lead to ankylosis. The splint was extended one tooth mesial and distal to the surgically extruded tooth.

Post-operative antibiotics and analgesics were prescribed; Amoxicillin 250 mg Cap t.d.s/7 days to prevent contamination that could lead to root resorption⁽¹⁷⁾ and Brufen 200 mg tab t.d.s/2 days.

Removal of the splint and excess composite two weeks later⁽³¹⁾. The final restoration was planned to be a full ceramic zirconia-based crown or composite restoration. Since all patients were under 18 years of age, composite restoration was performed. Patients were recalled every year following the placement of the final restoration.

RESULTS

Demographics:

Initially, twenty patients participated in the study (12 males and eight females), with a mean age of 131 months (10 years and 11 months). Three patients just performed the surgical extrusion procedures but never showed up for splint removal, so they were excluded from the study. Thus, 17 patients were followed-up to 6 years **Figure 2**. All surgical extruded teeth were maxillary incisors. The average time lapse since trauma was 13 month (Range from 0 to 72 month) **Figure 3, Table 4**.

TABLE (4) Mean Age for the participants (in months)

	N	Range	Minimum	Maximum	Mean	Std. Deviation
Age (month)	20	71	99	170	126.63	20.026

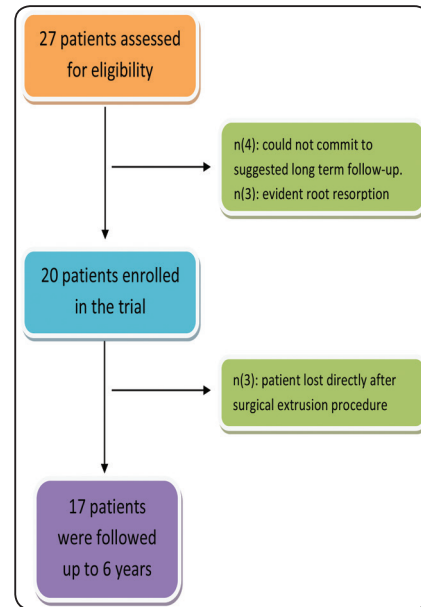


Fig. 2: Trial flow chart

The percentage of crown-root fractured teeth included in this study were; type A 38%, type B (29%), type D (33%). Transverse crown-root fractures (type C) were not present.

The causes for crown-root fractures in patients included in this study are illustrated in **Table 4**. Falls presents the primary reason of crown-root fractures followed by car and motorcycle accidents, while aggression and fights with other personnel constitute the least percentage as a causative factor.

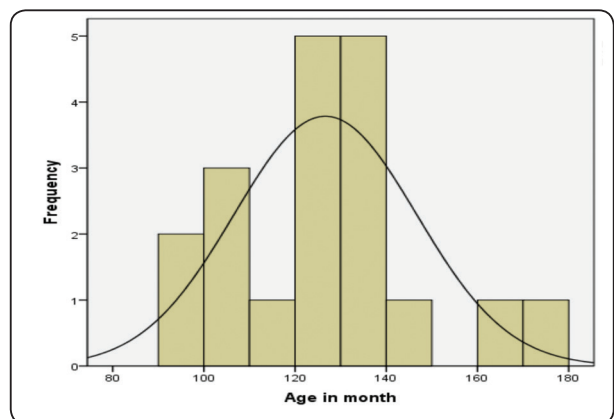


Fig. (3) Histogram showing age distribution among participants

TABLE (4) Distribution of factors causing CRF

Causative factor	Number of teeth	Percentage (%)
Fall	9	45%
Aggression	4	20%
Accident	6	30%
Can't recall	1	5%

The endodontic condition of the crown-root fractured tooth before surgical extrusion is illustrated in **Table 5**. All teeth presented with a complicated crown-root fracture. Two traumatised teeth had a previous restoration.

TABLE (5) The Endodontic condition of the crown-root fractured tooth before surgical extrusion

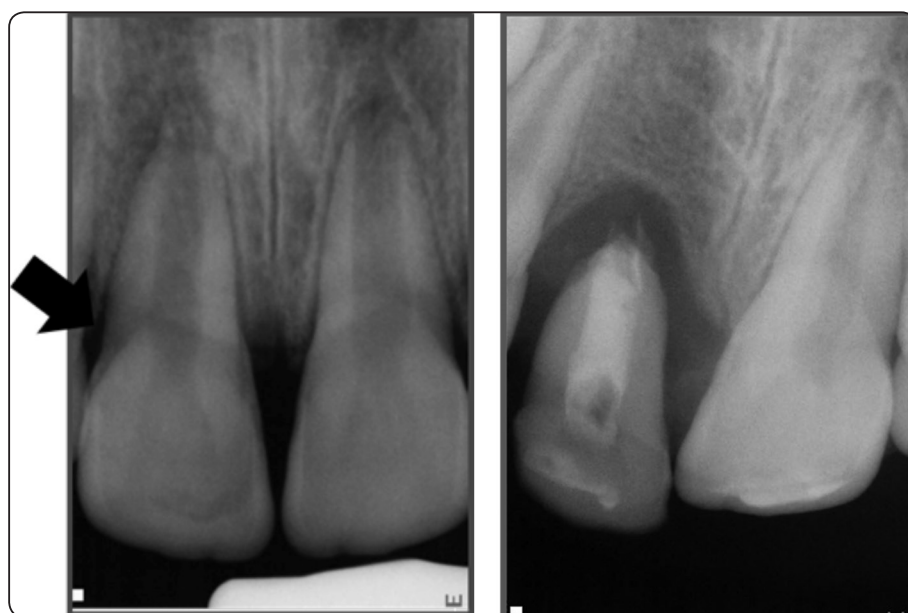Pulp condition	Number of teeth	Percentage (%)
Vital pulp	6	30%
Necrotic pulp	11	55%
Previously obturated	3	15%

Tooth loss

Five out of 17 surgical extruded teeth suffered tooth loss, with a resultant percentage of 29% (95% CI 13 to 53%). Two teeth were lost due to extensive inflammatory root resorption **Table 6**. One tooth was avulsed due to second trauma two years after surgical extrusion procedures. Two teeth were extracted due to the spontaneous pain that didn't resolve with any painkiller.

Survival analysis **Figure 4** was performed using Kaplan-Meier method. Tooth survival as an outcome means the length of time elapsed before tooth loss occurs. It shows that all teeth were lost in the first four years with nearly 30% probability. Life table **Table 7** counts for lost teeth shows that two teeth were lost in the first year, two teeth were lost in the second year while one tooth was lost in the 4th year.

Figure 4: Plots of Kaplan-Meier product limit estimates of survival of a group of patients, with 95% CI around each time point (shaded)



Pre-operative peri-apical radiograph of tooth no.11. Note that crown fragment is not removed yet. Arrow show extent of the fracture line

Two-month follow-up after surgical extrusion. Note the extensive root resorption despite the presence of calcium hydroxide in the root canal

Table (6) External inflammatory root resorption following surgical extrusion for patient number (3)

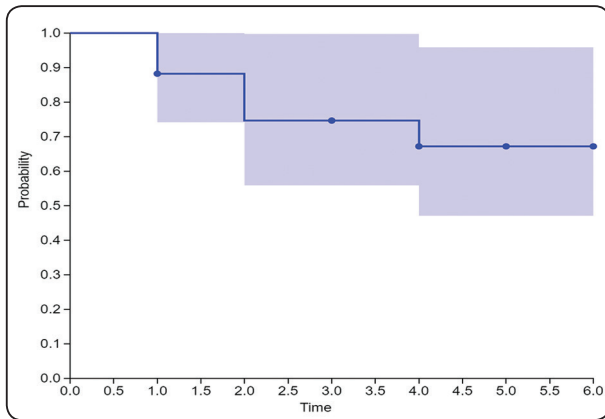


Fig. (4) Plots of Kaplan-Meier product limit estimates of survival of a group of patients, with 95% CI around each time point (shaded)

TABLE (7) Life table for surgical extruded teeth

Patient number	Patient years in follow-up	Tooth loss	Censored
1	5	0	1
2	6	0	1
3	1	1	0
4	4	0	1
5	1	1	0
6	5	0	1
7	2	1	0
8	5	0	1
9	1	0	1
10	4	0	1
11	5	0	1
12	3	0	1
13	4	1	0
14	1	0	1
15	2	1	0
16	5	0	1
17	6	0	1

DISCUSSION

Traumatic dental injuries have a substantial impact on children’s daily life (28). High levels of violence, traffic accidents and more significant participation of children in sports have contributed

to transforming traumatic dental injuries into a public health problem (27).

Traumatic injuries to teeth and their supporting structures occur most commonly in young patients and vary in severity from enamel fractures to avulsions (10, 11). Maxillary central incisors were the teeth most involved in dental trauma followed by maxillary lateral incisors (10, 16, 34, 36, 39).

“Crown-root fracture is defined as a fracture involving enamel, dentin and cementum” (40). It can be classified as either complicated or uncomplicated according to pulp exposure (43). According to the force and direction of the impact, a fracture line can start at some point of the crown and extend longitudinally through the pulp chamber extending to the subgingival area and alveolar bone crest (3).

Crown-root fracture comprises 5% of injuries affecting permanent dentition and 2% in primary dentition. It is usually the result of a direct impact in the anterior region, whereas in the posterior area they are caused by indirect trauma, mainly to the chin (25, 35). The most common etiologic factors are injuries caused by falls, bicycle and automobile accidents and foreign bodies striking the teeth (2).

Tooth with complicated crown-root fracture presents a lot of problems in respect to coronal restoration (1). The sub-gingival placed fracture margin makes it difficult to control moisture with subsequent failure of coronal restoration. Moreover, persistent gingival inflammation, loss of connective tissue attachment and unpredictable bone loss can be expected when the coronal restoration is located in the biologic width. These can be manifested clinically by gingival bleeding, periodontal pocket formation and gingival retraction (33).

Surgical tooth extrusion is not a new technique in the treatment of crown-root fractures. Kahnberg (23) was the first to introduce the concept of intra-alveolar transplantation, but it was a difficult technique as he placed autologous bone transplants

under the extruded root. Three years later, a more straightforward procedure was done without autologous bone transplants was done three years later ⁽²²⁾ and was found to be successful as well.

Discussion of Methods:

Surgical extrusion was performed using extraction forceps with careful rotational extraction movement. Since the root of maxillary central incisor is cone-shaped ⁽⁴⁾, rotational extraction movement would only tear the periodontal ligaments attached to the alveolar bone without damaging the periodontal cells that cover the root surface. No buccal or lingual movements were utilised to avoid crushing the periodontal cells against the alveolar bony socket. This technique was much simpler than that used by Tegsjö ^(41, 42) where a surgical extrusion was performed with a crown remover placed at the apical part of the tooth and apply an average of 16 blows to loosen the root.

Unlike previous studies ^(23, 41, 42), no bone transplants were placed underneath the extruded root for stabilisation. None of those above studies has objectively assessed the quality of the newly formed bone apical to the extruded tooth ⁽¹⁴⁾. A blood clot is expected to fill the space apical to the root with the further organisation into the new bone with time.

Discussion of Materials:

Unlike some previous cases series and reports ^(8, 22, 25) which utilised a suture splint after surgical extrusion, wire and composite splint were used in this study simulating the ⁽²⁴⁾. We think using such a splint would decrease the amount of unwanted tooth movement during removal of excess tooth structure after surgical extrusion to allow for occlusal adjustment. Moreover, the required materials for wire-composite splints are cheap and usually available in dental offices ⁽⁷⁾.

In this study, 0.016" wire and composite was used, which is considered a semi-rigid splint which

is appropriate for splinting teeth with dislocation injuries ⁽⁷⁾. Flexible and semi-rigid splints allow for some physiologic movement of the injured tooth, thus aid in proper periodontal healing. It was shown that extended splinting periods with rigid immobilisation could increase the risk of healing complications like ankylosis ⁽³⁰⁾. The flowable composite was easier than packed composite during application, and it decreased the bulk of the material surrounding the wire. Thus the semi-rigidity of the splint was not affected.

Penicillin was administered to all patients to prevent infection and facilitate healing of bone and root ⁽⁴¹⁾

Discussion of Results:

Demographics:

In this study, male to female ratio presented with crown-root fracture was 1.5:1. Boys showed a higher incidence of crown-root fractures than females which may be attributed to increased behavioural violence in males ⁽²⁷⁾. All treated teeth presented with complicated crown-root fracture, i.e. crown-root fracture with pulp exposure.

The most common cause of crown-root fracture was: falls (45%), followed by motorcycle accidents (30%), then aggression with peers (20%). The frequent incidence of traumatic dental injuries due to traffic accidents is 2.4% (Faus-Damia, Alegre-Domingo et al. 2011). Although the sample size in this study is small to draw prevalence, still the high incidence (12 times more than average values) of crown-root fracture due to motorcycle accidents draws attention to the decreased safety measures on the Egyptian roads, and the irresponsible attitude of both the passengers and motorcycle riders.

According to (Malmgren, Malmgren et al. 1991) classification, there was no noticeable difference in the occurrence of Type A, B, and D crown-root fractures in this study. There was no case of type C fracture (transverse; fracture margin running bucco-

lingual with minimal crown left), as it more likely presents cervical root fracture. A modified classification for crown-root fractures would be proposed including only three categories; oblique labial (fracture below gingival margin labial), oblique palatal (fracture below gingival margin palatal) and lateral (fracture margin below gingival margin mesial or distal).

The mean time calculated for the whole surgical extrusion procedure starting from the surgical extrusion process till the finish of splint placement and occlusal adjustment was 21 minutes. There was a learning curve in the process. The first surgical extrusion operation took 27 minutes, while the 20th operation took 13.5 minutes. The short operation time can be considered an advantage that favours the selection of surgical over orthodontic extrusion as a treatment option of crown-root fracture.

Tooth survival following surgical extrusion:

The results of this study showed that five teeth were lost after surgical extrusion (5/17) constituting nearly 30% of the cases. One tooth was lost due to the second trauma with subsequent tooth avulsion. The magnitude of surgical extrusion done to this tooth was 8mm which might explain the tooth avulsion once the splint debonded in response to a blow on the face.

Two teeth were lost after being subjected to extensive root resorption. These teeth presented initially with necrotic pulp. On the second visit, it was difficult to isolate the root canal, so calcium hydroxide was placed followed by surgical extrusion procedures. The purpose of calcium hydroxide treatment is to achieve arrest of inflammatory root resorption and healing of the adjacent periodontal ligament ⁽¹²⁾. Despite the placement of calcium hydroxide in the root canal, extensive root resorption continued with subsequent root shortening. A discussion of these two cases was made in person with Prof. Jens Ove Andreasen, and he commented: "It is a strange case because calcium

hydroxide is known to stop external inflammatory root resorption". A previous case series showed tooth loss (1/20) due to extensive marginal bone loss, increased tooth mobility and subsequent extraction ⁽⁸⁾.

Another unusual finding was the extraction of two teeth due to continuous pain arising from the surgical extruded tooth. This pain was not related to specific stimuli like biting or heat and cold influences. Although two previous systematic reviews ^(13,14) estimating the effectiveness of surgical extrusion, none of the included reports had similar findings of spontaneous pain that doesn't respond to any medication.

Trial limitations:

There are some limitations regarding this study. Randomization was non-applicable due to the absence of another treatment modality to be compared with like orthodontic extrusion. Neither the operator nor the patients were blinded.

CONCLUSIONS

Surgical tooth extrusion could be considered as a treatment option for crown-root fractures. Nevertheless, tooth loss is not an uncommon adverse effect. The first two years are critical for deciding the survival of surgical extruded tooth.

ACKNOWLEDGEMENT

Dr Mariam Roshdi, assistant lecturer on Prosthodontic department, Cairo University, for her help in patient follow up and post-operative patient care

REFERENCES

1. Andreasen J. Traumatic Injuries of the Teeth. Copenhagen: Munksgaard, 1981.
2. Andreasen JO. Etiology and pathogenesis of traumatic dental injuries. A clinical study of 1,298 cases. Scand J Dent Res 78: 329-342, 1970.

3. Andreasen JO AF. Textbook and color atlas of traumatic injuries to teeth. Copenhagen: Munksgaard, 1994.
4. Ash MM, and Stanley JN. Wheeler's Dental Anatomy, Physiology, and Occlusion. 2003.
5. Baker IM. Esthetic extrusion of a nonrestorable tooth. *J Clin Orthod* 24: 323-325, 1990.
6. Benenati FW, and Simon JH. Orthodontic root extrusion: its rationale and uses. *Gen Dent* 34: 285-289, 1986.
7. Berthold C, Thaler A, and Petschelt A. Rigidity of commonly used dental trauma splints. *Dent Traumatol* 25: 248-255, 2009.
8. Caliskan MK, Turkun M, and Gomel M. Surgical extrusion of crown-root-fractured teeth: a clinical review. *Int Endod J* 32: 146-151, 1999.
9. Carvalho CV, Bauer FP, Romito GA, Pannuti CM, and De Micheli G. Orthodontic extrusion with or without circumferential supracrestal fiberotomy and root planing. *Int J Periodontics Restorative Dent* 26: 87-93, 2006.
10. Castro JC, Poi WR, Manfrin TM, and Zina LG. Analysis of the crown fractures and crown-root fractures due to dental trauma assisted by the Integrated Clinic from 1992 to 2002. *Dent Traumatol* 21: 121-126, 2005.
11. Cavalleri G, and Zerman N. Traumatic crown fractures in permanent incisors with immature roots: a follow-up study. *Endod Dent Traumatol* 11: 294-296, 1995.
12. Cvek M. Prognosis of luxated non-vital maxillary incisors treated with calcium hydroxide and filled with gutta-percha. A retrospective clinical study. *Endod Dent Traumatol* 8: 45-55, 1992.
13. Das B, and Muthu MS. Surgical extrusion as a treatment option for crown-root fracture in permanent anterior teeth: a systematic review. *Dent Traumatol* 29: 423-431, 2013.
14. Elkhadem A, Mickan S, and Richards D. Adverse events of surgical extrusion in treatment for crown-root and cervical root fractures: a systematic review of case series/reports. *Dent Traumatol* 30: 1-14, 2014.
15. Emerich-Poplatek K, Sawicki L, Bodal M, and Adamowicz-Klepalska B. Forced eruption after crown/root fracture with a simple and aesthetic method using the fractured crown. *Dent Traumatol* 21: 165-169, 2005.
16. Fakhruddin KS, Lawrence HP, Kenny DJ, and Locker D. Etiology and environment of dental injuries in 12- to 14-year-old Ontario schoolchildren. *Dent Traumatol* 24: 305-308, 2008.
17. Fariniuk LF, Ferreira EL, Soresini GC, Cavali AE, and Baratto Filho F. Intentional replantation with 180 degrees rotation of a crown-root fracture: a case report. *Dent Traumatol* 19: 321-325, 2003.
18. Fournier A. Orthodontic management of subgingivally fractured teeth. *J Clin Orthod* 15: 502-503, 1981.
19. Heithersay GS. Combined endodontic-orthodontic treatment of transverse root fractures in the region of the alveolar crest. *Oral Surg Oral Med Oral Pathol* 36: 404-415, 1973.
20. Ingber JS. Forced eruption: part II. A method of treating nonrestorable teeth--Periodontal and restorative considerations. *J Periodontol* 47: 203-216, 1976.
21. Ivey DW, Calhoun RL, Kemp WB, Dorfman HS, and Wheless JE. Orthodontic extrusion: its use in restorative dentistry. *J Prosthet Dent* 43: 401-407, 1980.
22. Kahnberg KE. Intraalveolar transplantation of teeth with crown-root fractures. *J Oral Maxillofac Surg* 43: 38-42, 1985.
23. Kahnberg KE, Warfvinge J, and Birgersson B. Intraalveolar transplantation. (I). The use of autologous bone transplants in the periapical region. *Int J Oral Surg* 11: 372-379, 1982.
24. Kim DS, Shin DR, Choi GW, Park SH, Lee JW, and Kim SY. Management of complicated crown-root fractures using intentional replantation: two case reports. *Dent Traumatol* 2011.
25. Kirzioglu Z, and Karayilmaz H. Surgical extrusion of a crown-root fractured immature permanent incisor: 36 month follow-up. *Dent Traumatol* 23: 380-385, 2007.
26. Malmgren O, Malmgren B, and Frykholm A. Rapid orthodontic extrusion of crown root and cervical root fractured teeth. *Endod Dent Traumatol* 7: 49-54, 1991.
27. Marcenes W, al Beiruti N, Tayfour D, and Issa S. Epidemiology of traumatic injuries to the permanent incisors of 9-12-year-old schoolchildren in Damascus, Syria. *Endod Dent Traumatol* 15: 117-123, 1999.
28. Marcenes W, Alessi ON, and Traebert J. Causes and prevalence of traumatic injuries to the permanent incisors of school children aged 12 years in Jaragua do Sul, Brazil. *Int Dent J* 50: 87-92, 2000.
29. Oesterle LJ, and Wood LW. Raising the root. A look at orthodontic extrusion. *J Am Dent Assoc* 122: 193-198, 1991.

30. Oikarinen K. Functional fixation for traumatically luxated teeth. *Endod Dent Traumatol* 3: 224-228, 1987.
31. Oikarinen K. Tooth splinting: a review of the literature and consideration of the versatility of a wire-composite splint. *Endod Dent Traumatol* 6: 237-250, 1990.
32. Padbury A, Jr., Eber R, and Wang HL. Interactions between the gingiva and the margin of restorations. *J Clin Periodontol* 30: 379-385, 2003.
33. Planciunas L, Puriene A, and Mackeviciene G. Surgical lengthening of the clinical tooth crown. *Stomatologija* 8: 88-95, 2006.
34. Rajab LD. Traumatic dental injuries in children presenting for treatment at the Department of Pediatric Dentistry, Faculty of Dentistry, University of Jordan, 1997-2000. *Dent Traumatol* 19: 6-11, 2003.
35. Rauschenberger CR, and Hovland EJ. Clinical management of crown fractures. *Dent Clin North Am* 39: 25-51, 1995.
36. Rocha MJ, and Cardoso M. Traumatized permanent teeth in Brazilian children assisted at the Federal University of Santa Catarina, Brazil. *Dent Traumatol* 17: 245-249, 2001.
37. Simon JH. Root extrusion. Rationale and techniques. *Dent Clin North Am* 28: 909-921, 1984.
38. Singh R, and Mukhopadhyay K. Survival analysis in clinical trials: Basics and must know areas. *Perspect Clin Res* 2: 145-148, 2011.
39. Soriano EP, Caldas Ade F, Jr., Diniz De Carvalho MV, and Amorim Filho Hde A. Prevalence and risk factors related to traumatic dental injuries in Brazilian schoolchildren. *Dent Traumatol* 23: 232-240, 2007.
40. Spinass E, and Altana M. A new classification for crown fractures of teeth. *J Clin Pediatr Dent* 26: 225-231, 2002.
41. Tegsjö U, Valerius-Olsson H, Frykholm A, and Olgart K. Clinical evaluation of intra-alveolar transplantation of teeth with cervical root fractures. *Swed Dent J* 11: 235-250, 1987.
42. Tegsjö U, Valerius-Olsson H, and Olgart K. Intra-alveolar transplantation of teeth with cervical root fractures. *Swed Dent J* 2: 73-82, 1978.
43. WHO. Application of the international classification of disease to dentistry and stomatology, ICD-DA. Geneva: World health organization, 1992.