



## IMPACTED MAXILLARY CANINE RELATIONSHIP TO LATERAL INCISOR: A RETROSPECTIVE CBCT ANALYSIS

Hatem Saifeldin\*, Mostafa S. Ashmawy\*\*, Hany S. Eid\*\*\* and Wael M. Aboelmaaty\*\*\*\*

### ABSTRACT

**Aim of the study:** to assess the relation between impacted canine angle, follicle thickness and proximity to lateral incisor using CBCT.

**Patients and methods:** The total impactions examined were two hundred impacted canines. Two observers with a clinical experience of 17 years viewed the images twice separated by two weeks interval. Measurement of the angle between the midline and long axis of impacted canine and follicle thickness was performed using cone beam computed tomography (CBCT). Regarding canine approximation to lateral incisor, a score was given for each impacted canine.

**Results:** There was a statistically significant inverse (negative) correlation between approximation to lateral incisor scores and canine inclination angle. There was a statistically significant inverse (negative) correlation between approximation to lateral incisor scores and follicle thickness. There was no statistically significant correlation between canine inclination angle and follicle thickness.

**Conclusion:** Practitioners should be aware of relevant diagnostic criteria to detect lateral incisor resorption. Timely detection and prompt preventive measures will lead to avoiding the severe complications due to impacted canines

**KEYWORDS:** Impacted canine, Lateral incisor, Root resorption, Follicle thickness, CBCT

### INTRODUCTION

Diagnosis and treatment planning of impacted maxillary permanent canines represent a challenge to the dental practitioner.<sup>1, 2</sup> The prevalence of

permanent maxillary canine impaction or ectopic eruption in the general population is 1–2%.<sup>2</sup> The complications due to impaction are related most often to resorption of the roots of the lateral incisors which are of considerable significance

\* Lecturer of Orthodontics, Orthodontics Department, Faculty of Dentistry, Ain-Shams University.

\*\* Lecturer of Oral Radiology, Oral Radiology Department, Faculty of Dentistry, Ain-Shams University.

\*\*\* Associate Professor of Orthodontics, Faculty of Dentistry, Misr University for Sciences and Technology.

\*\*\*\* Lecturer of Oral Radiology and Diagnosis, Faculty of Dentistry, Mansoura University.

for the aesthetic appearance and functional life of the dentition. The resorption as complication may be foreseen and measures should be taken for its prevention. Resorption and pathology are more likely in females, in age groups greater than 14 years, and in cases where the angulation of the canine to the midline is more than  $25^{\circ}$ .<sup>3</sup> The most likely cause of root resorption is inherent pressure due to migration of the displaced canine.

Lateral cephalometric and occlusal radiographs have been used for determining the impacted canine position for decades.<sup>4, 5</sup> These two dimensional (2D) radiographic techniques are inferior to three dimensional (3D) techniques as computed tomography (CT) and cone beam computed tomography (CBCT).<sup>6, 7</sup> CT scanning increased detection of root resorption by 50%. The sensitivity of intra-oral films was low when diagnosing resorption, and was reported in 0.71% of children in earlier studies.<sup>8</sup>

The aim of this study is to assess the relation between impacted canine angle, follicle thickness and proximity to lateral incisor using CBCT.

## PATIENTS AND METHODS

In the present study we selected patients from the database at the Oral Radiology Department, Faculty of Dentistry, Ain Shams University. We searched the database for patients seeking orthodontic or surgical treatment of impacted maxillary canine from June 2015 to December 2017. We excluded cases who had missing lateral incisor, another impaction associated with canine impaction, presence of supernumerary teeth or images acquired using a field of view not covering the entire impacted canine. Then one hundred and forty two patients were selected who had unilateral or bilateral impacted maxillary canines, the age

range was from 12 to 23 years. The total impactions examined were two hundred impacted canines. All images were acquired using i-CAT next generation (Imaging sciences international, Hatfeild, PA). All the cases selected for this study were exposed using the same exposure parameters; 120 kVp, 5 mA, 0.2 mm voxel size and limited field of view (FOV) to the maxillary arch.

**DICOM** (Digital Imaging and Communication in Medicine) files were exported to another workstation implying third party software for image viewing and analysis; On Demand software (Cybermed, Seoul, South Korea). The images were viewed in a dimmed light room on a computer monitor 17 inch HD LED (Dell Inc., Berkshire, UK). Two observers with a clinical experience of 17 years viewed the images twice separated by two weeks interval, observers agreed on a specific protocol for viewing and reconstructing the images. First, an axial section was adjusted to pass through the crowns of the maxillary canine teeth in their middle one third **Fig (1)**, then a reconstructed panoramic curve was drawn manually in order to pass through the center of the maxillary arch buccolingually. The angle between the midline and the long axis of impacted canine was measured using the "measure angle tool" **Fig (2)**. Then cross sectional images were created for examination of each impacted canine separately and measuring the follicle thickness using the "measure tool" **Fig (3A)**. Two measurements were done for each follicle on the buccal and palatal aspects and the average was recorded. Approximation of the canine to the lateral incisor was determined, a score was given for each canine as follows: (1) if the space between the impacted canine and lateral incisor is 0.5 mm or more, (2) for canine touching the lateral **Fig (3B)** and (3) for canine causing resorption of the lateral incisor **Fig (4)**.

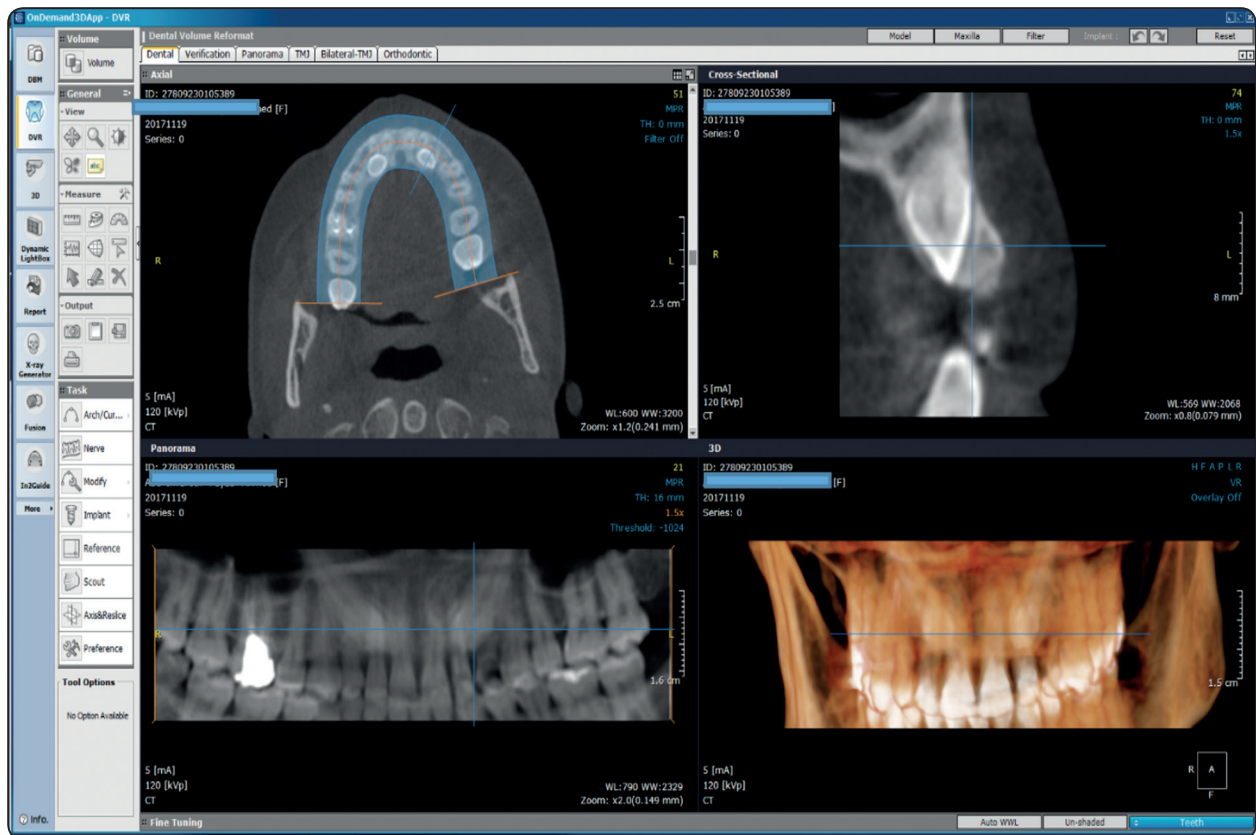


Fig. (1): Drawing the reconstructed panoramic curve and aligning the cross sectional images.

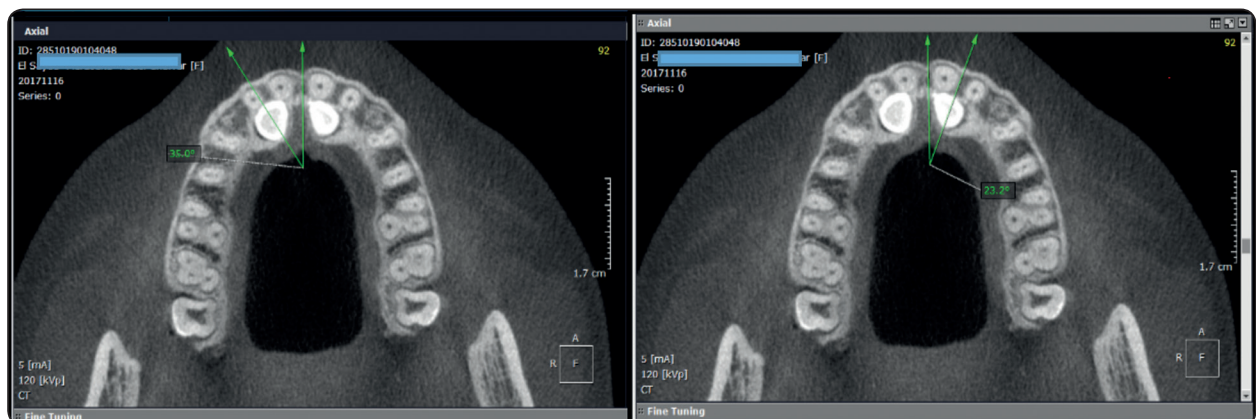


Fig. (2): Axial images showing the measurement of the angle of canine inclination for each side

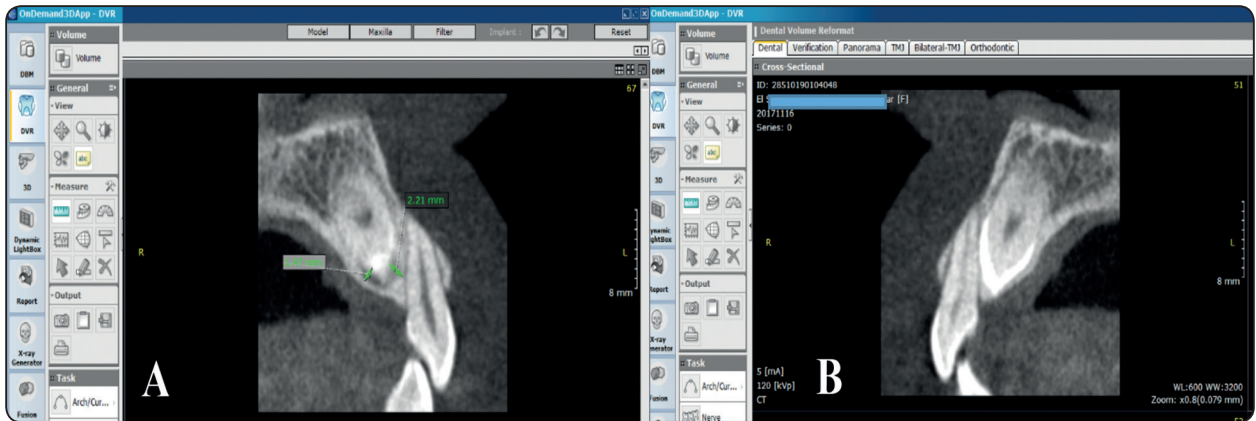


Fig. (3): Reconstructed cross sectional images showing (A) the follicle thickness measurement and (B) approximation of the impacted canine to the lateral incisor

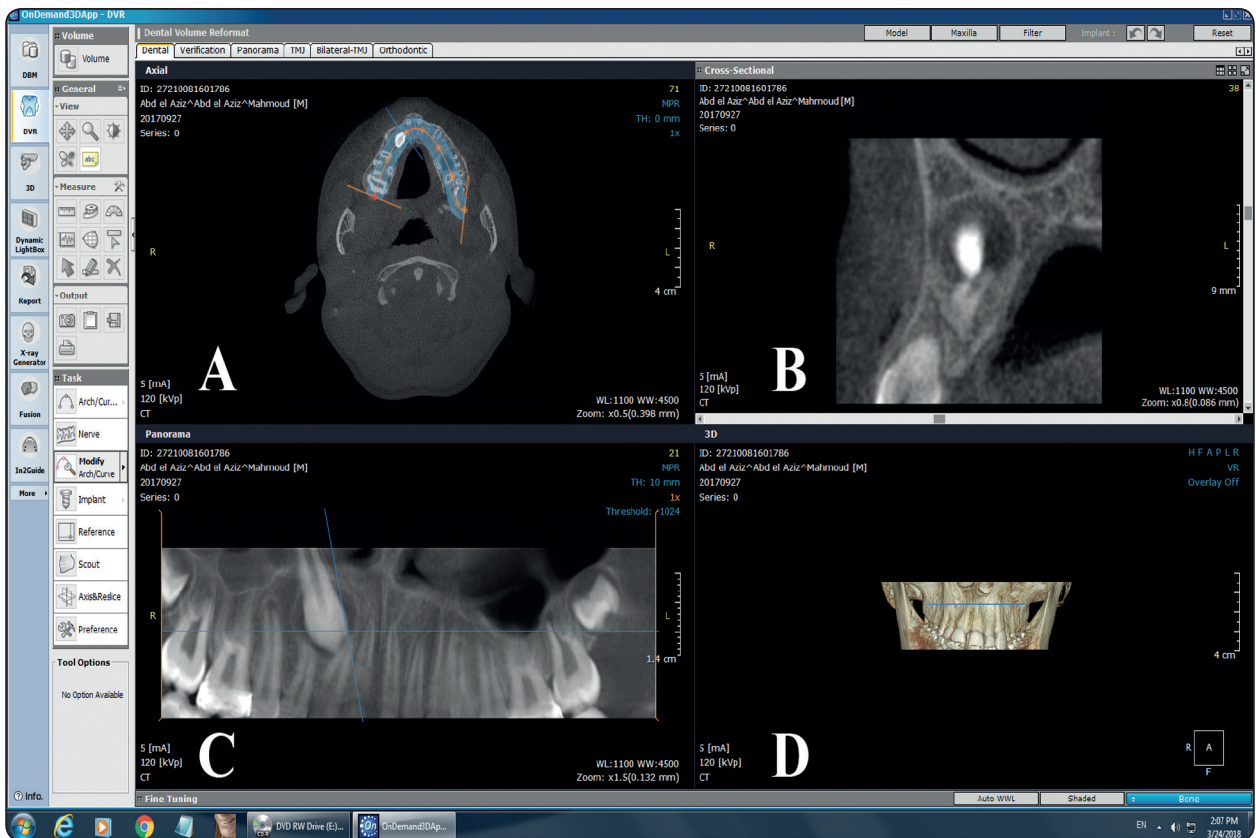


Fig. (4): (A) Axial image showing the panoramic curve (B) Reconstructed cross sectional images showing the resorption of lateral incisor root (C) Reconstructed panoramic image showing the alignment of the cross section direction (D) 3D image of the maxilla



**RESULTS**

Numerical data were explored for normality by checking the data distribution and using Kolmogorov-Smirnov and Shapiro-Wilk tests. Inclination angle data showed normal (parametric) distribution while follicle thickness data showed non-normal (non-parametric) distribution. Data were presented as mean, median, standard deviation (SD), minimum, maximum and 95% Confidence Interval (95% CI) for the mean values. Qualitative data were presented as frequencies (n) and percentages (%). Spearman’s correlation coefficient was used to determine the correlation between different variables. Intra – and inter-observer agreements were assessed using Cronbach’s alpha reliability coefficient and Intra-Class Correlation Coefficient (ICC).

The significance level was set at  $P \leq 0.05$ . Statistical analysis was performed with IBM® SPS® Statistics Version 20 for Windows.

The present study was conducted on 142 subjects; the mean  $\pm$  standard deviation values for age were  $14.2 \pm 2.4$  with a minimum of 12 and a maximum of 23 years old. There was very good intra-observer agreement with Cronbach’s alpha values of 0.872, 0.915 and 0.948 for inclination angle, follicle thickness and approximation to lateral incisor scores, respectively. There was very good inter-observer agreement with Cronbach’s alpha values of 0.819, 0.902 and 0.911 for inclination angle, follicle thickness and approximation to lateral incisor scores, respectively.

There was a statistically significant inverse (negative) correlation between approximation to lateral incisor scores and canine inclination angle i.e. an increase in approximation to lateral incisor scores is associated with a decrease in canine inclination angle and vice versa **Table (1)**. There was a statistically significant inverse (negative) correlation between approximation to lateral incisor scores and follicle thickness i.e. an increase in approximation to lateral incisor scores

is associated with a decrease in follicle thickness and vice versa **Table (1)**. There was no statistically significant correlation between canine inclination angle and follicle thickness.

TABLE (1): Results of Spearman’s correlation coefficient for the correlation between different variables

Variables	Correlation coefficient	P-value
Approximation score and canine inclination angle	-0.311	0.002*
Approximation score and follicle thickness	-0.275	0.006*
Canine inclination angle and follicle thickness	-0.173	0.085

\*: Significant at  $P \leq 0.05$

**DISCUSSION**

This study was comprised of two hundred impacted canines with seven resorbed incisor roots. The impaction of upper canines is the second most common impaction after that of wisdom teeth. Possible sequelae of impacted canines include cyst formation, internal resorption of the impacted tooth, external resorption of impacted or neighbouring teeth, ankylosis, infection and migration of neighbouring teeth with loss of arch length.<sup>1</sup>

CBCT has made a shift in the way we can diagnose canine impactions and their complications. Kurok et al. compared treatment plans compiled with and without information from a CT investigation for impacted canines, disclosed that the evidence obtained from the CT investigation resulted in changes in the treatment plans 43% of the time.<sup>9</sup>

In this study we investigated three parameters of the impacted canine and their relation to the root of the lateral incisor. The angle between the midline and the long axis of impacted canine was measured for each canine; our results showed that

as the canine angulation to the midline decreases, the possibility increases for proximity to lateral incisor. All the cases of lateral root resorption showed an angle of 27 degree or less. These finding correlates with those by McSherry<sup>10</sup> and Pitt et al.<sup>11</sup>. As the canine lies closer to the lateral incisor, the poorer the prognosis for root resorption. Horizontal overlap of the adjacent incisor was associated with more root resorption of the lateral incisor. This is in accordance with several previous studies.<sup>12-14</sup>

In many studies, there appears to be no association between enlarged canine follicles and lateral root resorption.<sup>15-17</sup> This was in contrast with our study. The incidence of enlarged follicles in our study was 21% this was similar to Ericson and Kurol<sup>3</sup> who reported an incidence of enlarged follicle in 23%. They also compared the resorption group to a control group with ectopically positioned canines that did not develop incisor root resorption and found that the incidence of follicular enlargement was not significantly different to the resorption group from which they concluded that follicular enlargement was not a factor in the etiology<sup>3</sup>. The results of our study suggests that such follicle may prevent direct tooth contact between canine enamel and incisor root cementum.

The results of the present study indicate that lateral incisor root resorption associated with impacted canine is related to the angle of the impacted canine to the midline well as lateral incisor root approximation. The presence of impacted canine enlarged tooth follicle may be a factor that reduces the incidence of lateral incisor root resorption. To confirm these results, further studies are warranted on with longer follow-up.

## CONCLUSION

Incidence of maxillary canine impaction is 1-2%, therefore a common encounter for dental professionals. Practitioners should be aware of relevant diagnostic criteria to detect lateral

incisor resorption. Timely detection and prompt preventive measures will lead to avoiding the severe complications due to impacted canines and preserving the morphological and functional integrity of the incisors.

## REFERENCES

1. Bishara SE. Impacted maxillary canines: a review. *Am J Orthod Dentofacial Orthop* 1992;101(2):159-71.
2. Bedoya MM, Park JH. A review of the diagnosis and management of impacted maxillary canines. *J Am Dent Assoc* 2009;140(12):1485-93.
3. Ericson S, Kurol J. Incisor resorption caused by maxillary cuspids. A radiographic study. *Angle Orthod* 1987;57(4):332-46.
4. An S, Wang J, Li J, Cheng Q, Jiang CM, Wang YT, Huang YF, Yu WJ, Gou YC, Xiao L. Comparison of methods for localization of impacted maxillary canines by panoramic radiographs. *Dentomaxillofac Radiol* 2013;42(8):20130129.
5. Haney E, Gansky SA, Lee JS, Johnson E, Maki K, Miller AJ, Huang JC. Comparative analysis of traditional radiographs and cone-beam computed tomography volumetric images in the diagnosis and treatment planning of maxillary impacted canines. *Am J Orthod Dentofacial Orthop* 2010;137(5):590-7.
6. Walker L, Enciso R, Mah J. Three-dimensional localization of maxillary canines with cone-beam computed tomography. *Am J Orthod Dentofacial Orthop* 2005;128(4):418-23.
7. Nakajima A, Sameshima GT, Arai Y, Homme Y, Shimizu N, Dougherty H, Sr. Two- and three-dimensional orthodontic imaging using limited cone beam-computed tomography. *Angle Orthod* 2005;75(6):895-903.
8. Lai CS, Bornstein MM, Mock L, Heuberger BM, Dietrich T, Katsaros C. Impacted maxillary canines and root resorptions of neighbouring teeth: a radiographic analysis using cone-beam computed tomography. *Eur J Orthod* 2013;35(4):529-38.
9. Ericson S, Kurol J. Incisor root resorptions due to ectopic maxillary canines imaged by computerized tomography: a comparative study in extracted teeth. *Angle Orthod* 2000;70(4):276-83.

10. McSherry PF. The assessment of and treatment options for the buried maxillary canine. *Dent Update* 1996;23(1):7-10.
11. Pitt S, Hamdan A, Rock P. A treatment difficulty index for unerupted maxillary canines. *Eur J Orthod* 2006;28(2):141-4.
12. Kurol J. Unusual transmigration of an impacted maxillary canine. *Am J Orthod Dentofacial Orthop* 2006;129(3):321.
13. Wriedt S, Jaklin J, Al-Nawas B, Wehrbein H. Impacted upper canines: examination and treatment proposal based on 3D versus 2D diagnosis. *J Orofac Orthop* 2012;73(1):28-40.
14. Naoumova J, Kjellberg H, Kurol J, Mohlin B. Pain, discomfort, and use of analgesics following the extraction of primary canines in children with palatally displaced canines. *Int J Paediatr Dent* 2012;22(1):17-26.
15. Hunter SB. Treatment of the unerupted maxillary canine. Part 1--Preliminary considerations and surgical methods. *Br Dent J* 1983;154(9):294-6.
16. Kau CH, Richmond S, Palomo JM, Hans MG. Three-dimensional cone beam computerized tomography in orthodontics. *J Orthod* 2005;32(4):282-93.
17. Ericson S, Kurol PJ. Resorption of incisors after ectopic eruption of maxillary canines: a CT study. *Angle Orthod* 2000;70(6):415-23.