



MANAGEMENT OF EPIDERMOID CYST

Altaib Abdalrazik Mohammed*

ABSTRACT

Epidermoid cysts has rare occurrence in oral and maxillofacial region and need special care during its management

Patients and methods : All the patients presented with epidermoid cysts in maxillofacial department faculty of oral and dental medicine, south valley university , from January 2014 to January 2017 were managed and their clinical data were collected

Results: Number of the patients presented with epidermoid cysts were 10, (seven males and three females) were 3 periorbital epidermoid cysts, 2 peri auricular, 2 sublingual, 2 labial and one submandibular cysts, there was no postoperative complication. Only one case of recurrence

Conclusion: Although epidermoid cysts are rare ,but they has clinical significance and should be considered on differential diagnosis of the soft tissue cysts, of maxillofacial region,

KEY WORDS : epidermoid, cysts, surgical management, complications

INTRODUCTION

The origin of epidermoid cyst is varied, it may originate by sequestration and implantation of epithelium between developing processes during embryonic period, or due to occlusion of pilosebaceous unit of hair or traumatic implantation of epithelium into the underlying mesenchymal and to a less extent epidermoid cyst may be due to HPV infection and eccrine duct occlusion ⁽¹⁾ .

Incidence of epidermoid cyst of maxillofacial region is rare, it may arise in intraoral or extraoral areas, it is variable in size it may be small, or reaches

size to the degree that causes facial disfigurement, or causing respiratory distress specially if it is infected⁽²⁾.

Due to clinical importance of the epidermoid cyst and the required meticulous surgical procedures for management, this descriptive work may be valuable for maxillofacial practitioner.

PATIENTS AND METHODS

From January 2014 to January 2017 all the patients presented with epidermoid cysts affecting maxillofacial region was managed in maxillofacial

* Lecturer of Oral and Maxillofacial Surgery, Faculty of Oral and Dental Medicine, South Valley University

surgery department South Valley University, we have registered the age, sex of the patient, also the chief complaints were recorded, the lesion was diagnosed with different means, as clinical examination, aspiration, radiologic examination also routine investigations were managed as complete blood picture. Liver function tests, renal function tests and hepatitis markers, all the patient were examined for their fitness by physician. Then consents for surgical management, and using clinical data for scientific work was obtained from all the patients, the lesions were sent for histopathologic examination then the patients followed for at least one year, depending on clinical examination

RESULTS

Number of the patients was 10, with age range 7-45 years three females and seven males, one cyst was at the preauricular region, (figure 1) two epidermoid cysts were localized in the floor of the mouth, (figure 2 and 3) one at sub mandibular region (figure 4), two epidermoid cysts were at the lateral margins of superior orbital ridge, (figures 5,6), two cysts were affecting the upper lip (figure 7,8), and cyst was at the post auricular region (figure 9) and the last one located at the medial margin of the inferior orbital ridge (figures 10) the, the patients presented with different complaints, according to the affected region, those patients presented with intraoral epidermoid cyst in the floor of the mouth were complaining from difficult speech, dysphagia, one of them complaining recurrent infection with dyspnea, the lesion on examination was raising the tongue, covered with smooth mucosa, with yellowish discoloration of the underlying lesion, the lesion was soft rubbery in consistency with slight tenderness, the floor of the mouth was flat in one case in the same time the cyst presented with sub

mental swelling leading to double chin appearance the patients presented with labial epidermoid cyst complained from facial disfigurement and interference and interference with speech, and these two cases examined clinically without radiology, the complaint of the patient presented with preauricular region was facial disfigurement and slight tenderness from recurrent lesion, the patients presented with periorbital lesions complained from facial disfigurements lastly the patient with submandibular epidermoid cyst complained from annoying submandibular swelling with tenderness slight tenderness, aspiration test for all the patient was yellowish cheesy material, all the patients were managed under general anaesthesia except the patients of labial lesions managed under local anaesthesia, the lesions were excised surgically, rupture of the cyst was not common, four cases (submandibular, postauricular medial canthal and labial lesions) the rupture was inevitable, and in one case (sublingual) we obliged to incise the cyst to decrease its volume and facilitate its dissection, in case of ruptured cysts we followed the lining of the cyst meticulously and excised it, there was no postoperative significant complications, the complaints of the patient were managed and there was recurrence in one case. As regard histopathologic examination (figures 11) there were seven cases of classic epidermoid cyst that is represented with well defined cystic cavity surrounded by orthokeratinized stratified squamous epithelium surrounded by connective tissue wall, with keratin flakes within the lumen while in the three periorbital cysts, the pathology was of dermoid variant where there is sebaceous and sweat glands located within the connective tissue wall in addition to the lining of orthokeratinized stratified squamous epithelium and keratin flakes .

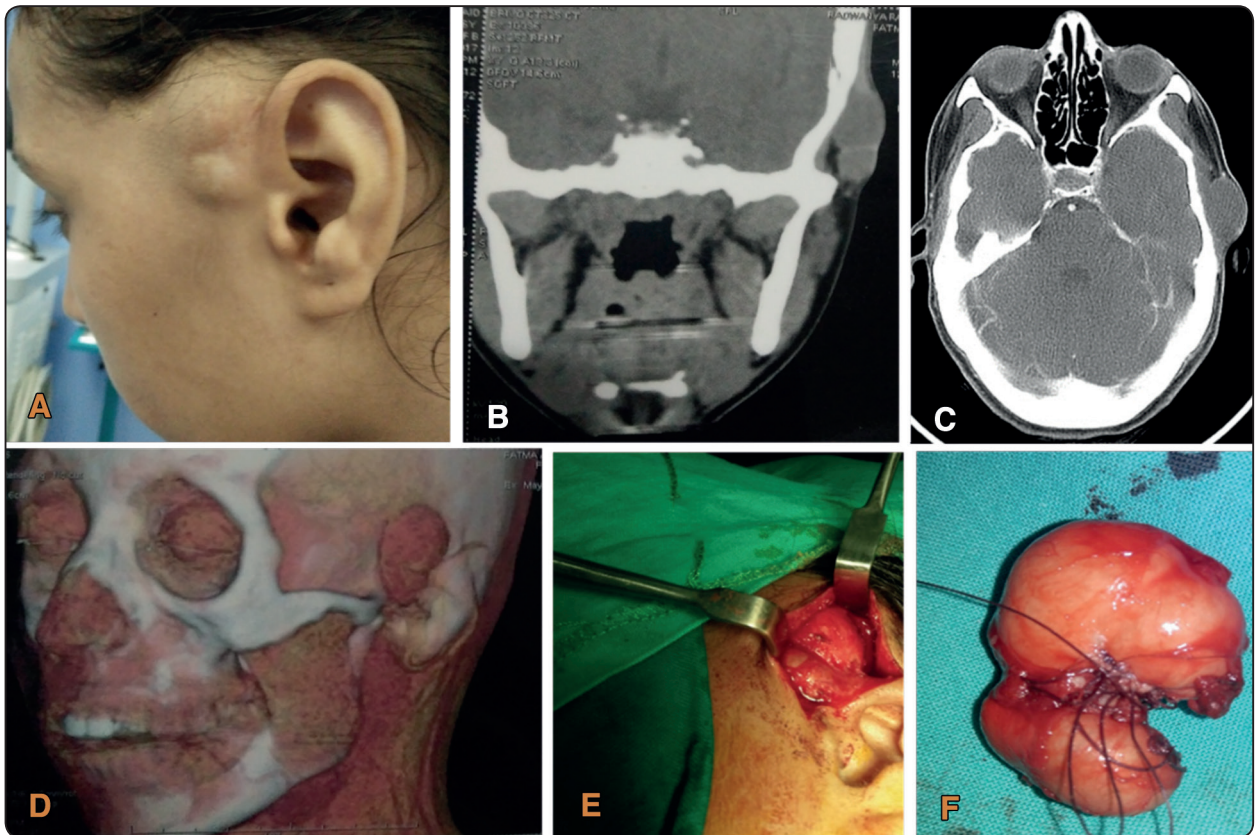


Fig. (1) A preauricular epidermal cyst (B) coronal ct showing epidermoid cyst with separating septum, (C) axial CT showing epidermoid cyst. (d)showing 3 dimensional view of the epidermoid cyst E- preauricular approach for enucleation of epidermoid cyst (F) epidermoid cyst after surgical excision.

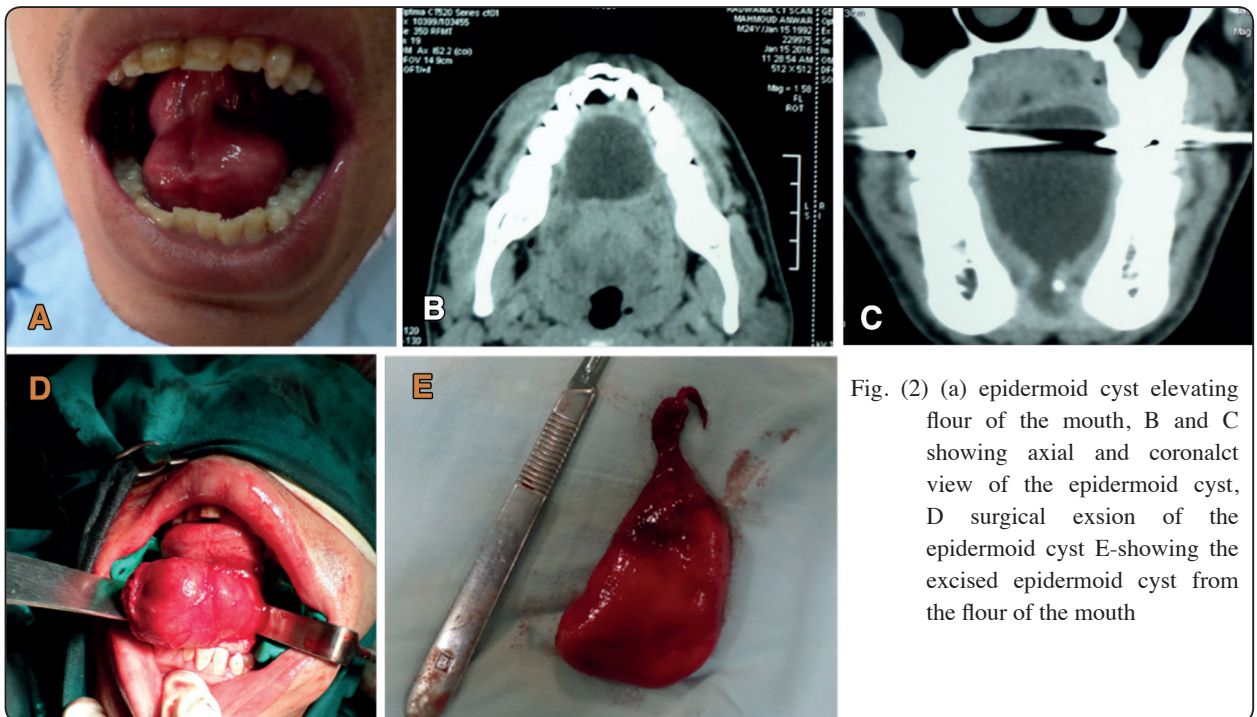


Fig. (2) (a) epidermoid cyst elevating floor of the mouth, B and C showing axial and coronal view of the epidermoid cyst, D surgical excision of the epidermoid cyst E-showing the excised epidermoid cyst from the floor of the mouth

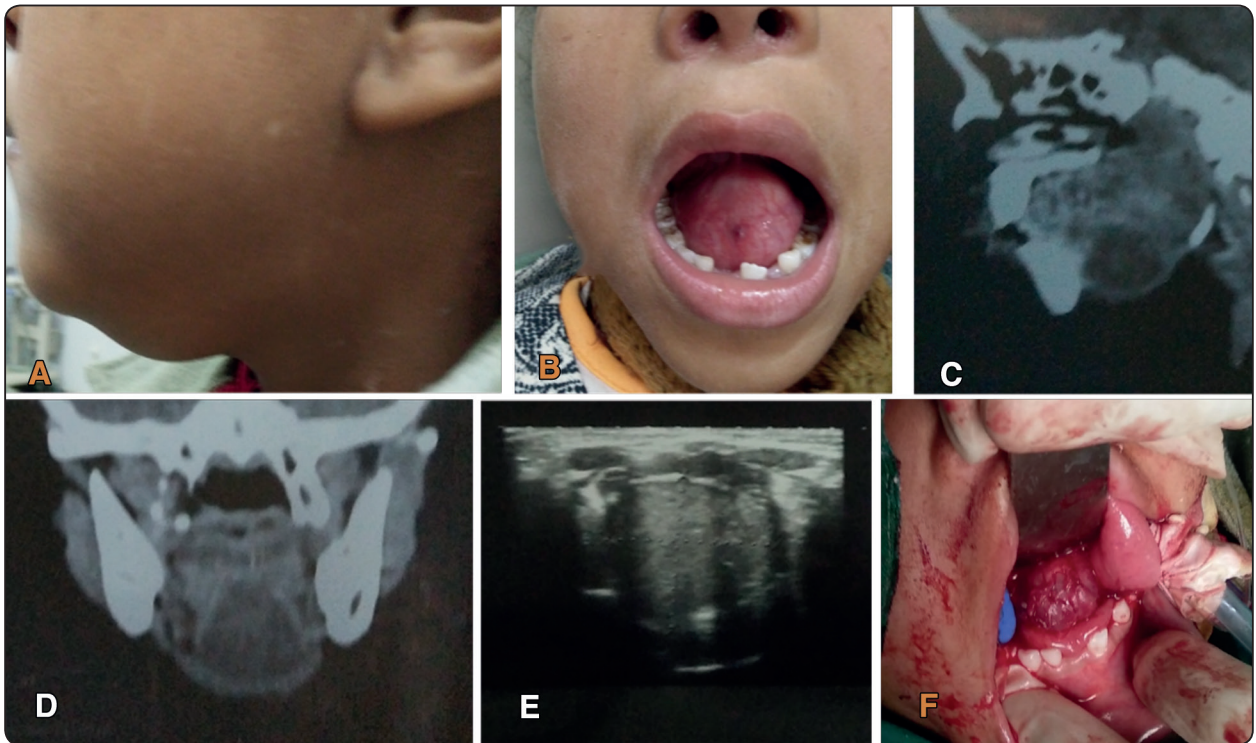


Fig. (3) Epidermoid cyst located at the floor of the mouth A- epidermoid cyst cause double chin appearance, B epidermoid cyst at the floor of the mouth, C and d - sagittal and coronal ct showing circumscribed radiolucency ,E ultrasonography showing hypoechoic circumscribed radiolucency, F defect of the floor of the mouth after excision

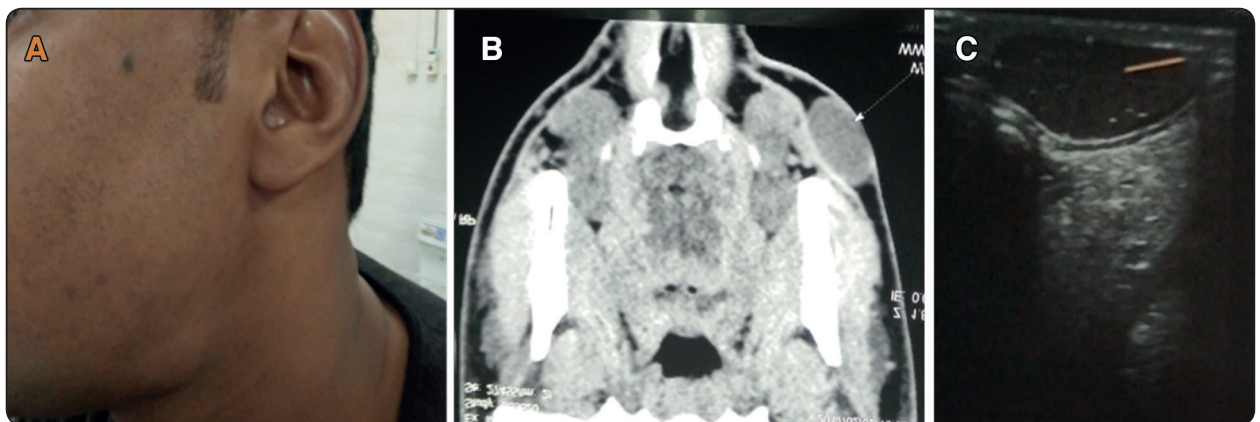


Fig. (4) Showing A-submandibular swelling due to epidermoid cyst, B- axial ct showing circumscribed epidermoid cyst, C – ultrasonography show hypo-echoic circumscribed cystic lesion

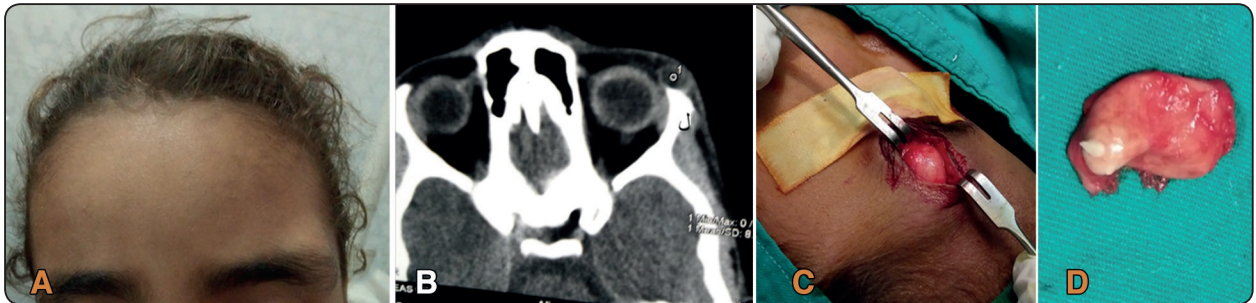


Fig. (5) A) Left site supraorbital swelling due to dermoid cyst B) axial ct showing circumscribe radulucency C) Supraorbital incision to expose the cyst D) Excised dermoid cyst

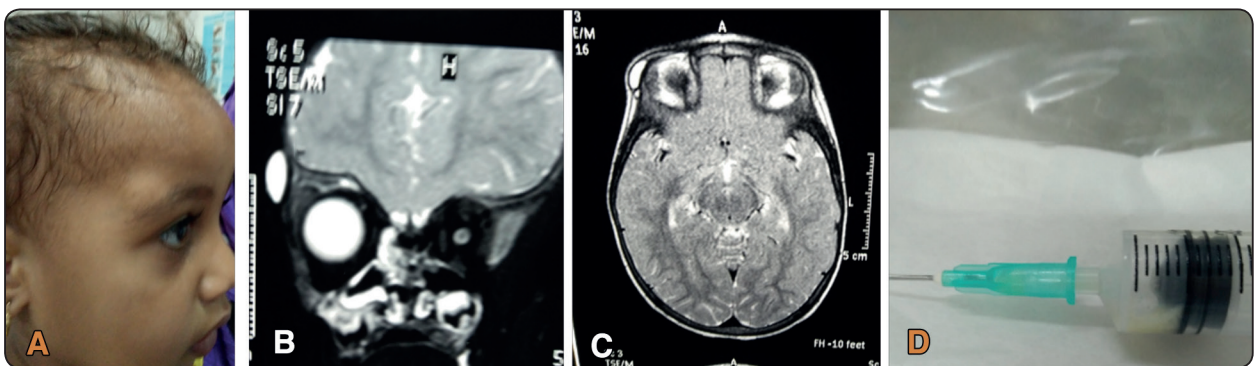


Fig. (6) a- supraorbital swelling at right site due to epidermoid cyst b- coronal MRI showing radioopaque epidermoid cyst B-axial MRI showing radioopacity of the epidermoid cyst D- aspiration of cheezy matel from the cyst

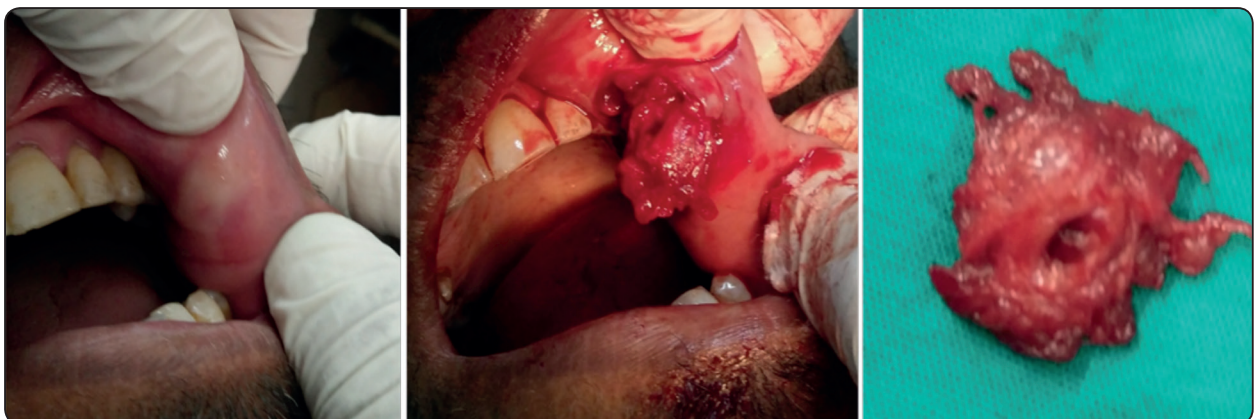


Fig. (7) show epidermoid cyst at the corner of mouth followed by its excision

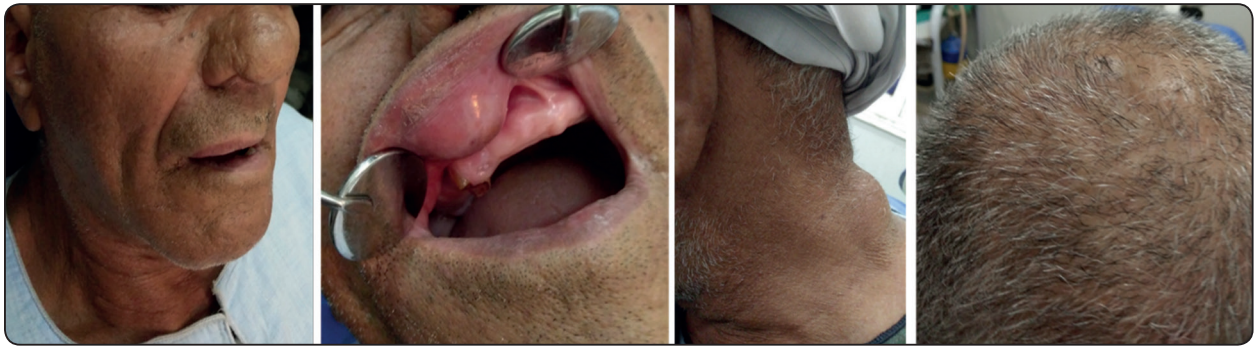

Fig. (8) Epidermoid cyst at the upper lip it is accompanied with neck and scalp epidermoid cyst

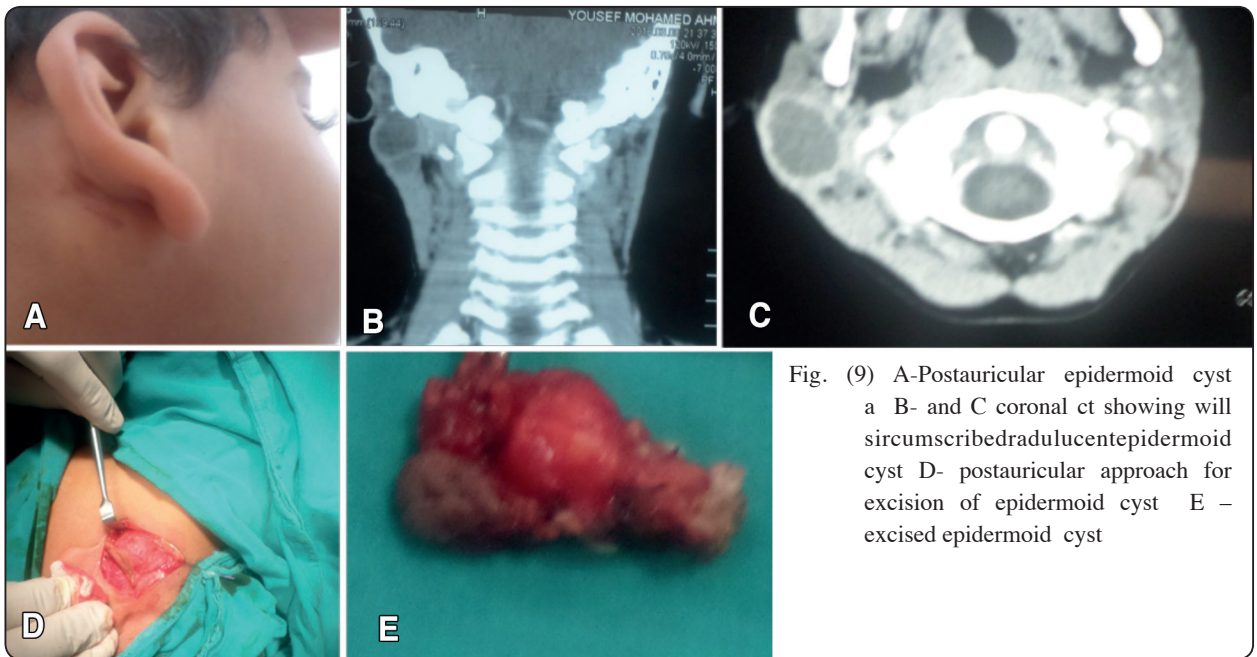


Fig. (9) A-Postauricular epidermoid cyst a B- and C coronal ct showing will circumscribed raducent epidermoid cyst D- postauricular approach for excision of epidermoid cyst E – excised epidermoid cyst

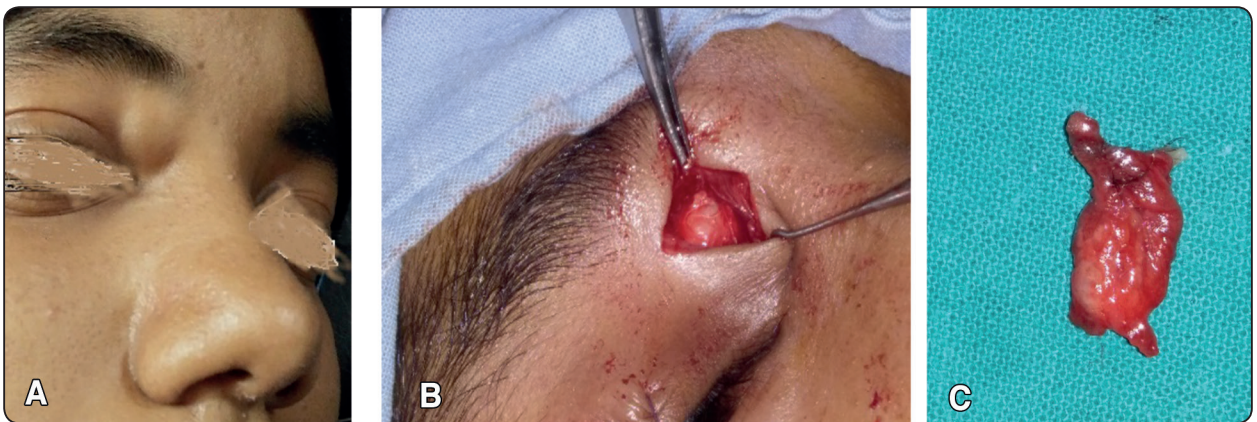


Fig. (10) Show epidermoid cyst at the medial canthus

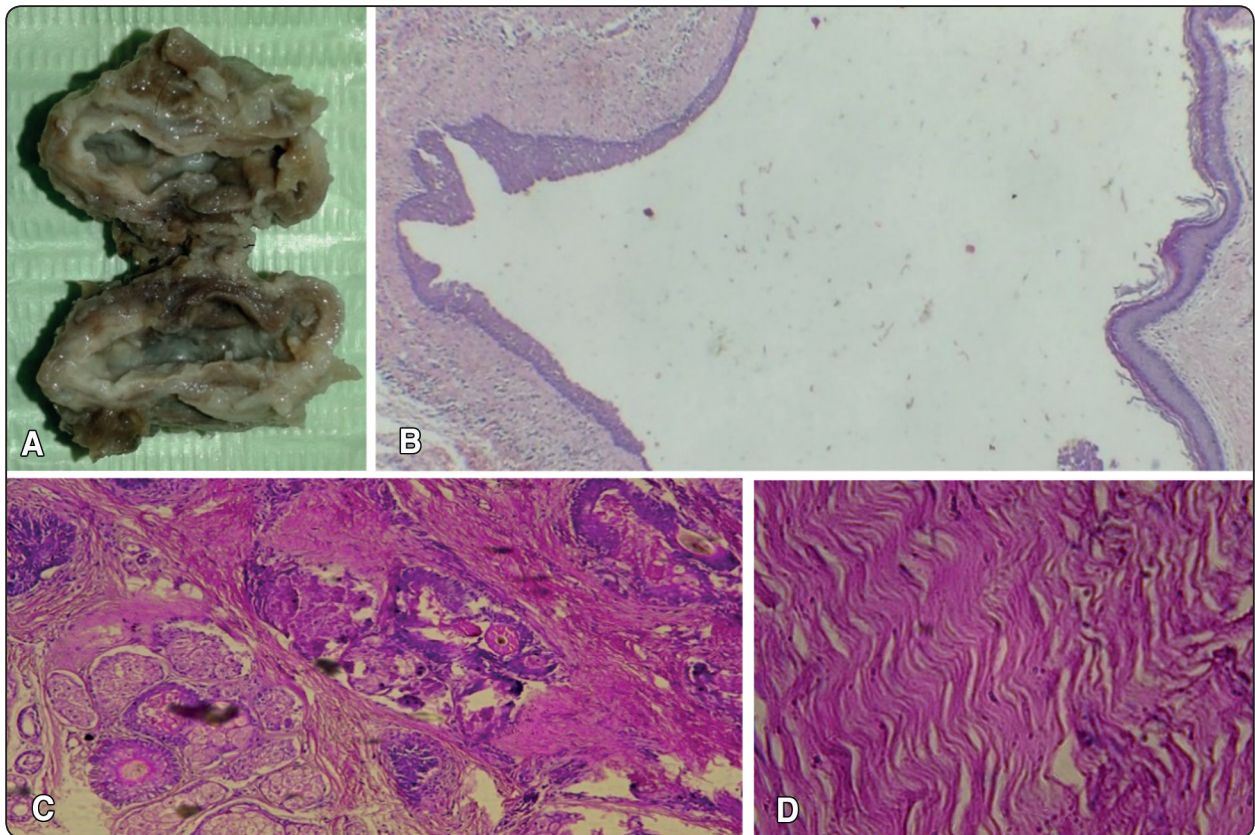


Fig. (11) A-Macroscopically the epidermoid cyst is whitish brown in colour with well defined cavity B) The hematoxylin and eosin (H & E) stained sections of the specimen showed stratified squamous ortho-keratinized as well as non-keratinized cystic epithelial lining with underlying fibro-vascular connective tissue wall. The ortho-keratinized stratified squamous epithelial lining was associated with a prominent granular cell layer C) sebaceous and sweat gland D) keratin flakes.

DISCUSSION

Although incidence of maxillofacial epidermoid cyst is rare but it represents significant lesion, because it is complicated with recurrent infection, difficult talking and eating respiratory distress, facial asymmetry, is accompanied with serious syndromes as Gardner syndrome or Boman syndrome also epidermoid cyst may arise in preauricular site near to facial nerve.^(3,4)

In our study patients presented sublingual epidermoid cysts were interfering with eating, talking with frequent episodes of recurrent infection and respiratory difficulty, while patients presented with periorbital and periauricular epidermoid cysts were complaining from facial asymmetry while la-

bial epidermoid cysts interferes with normal talking and frequent trauma

There are different theories for pathogenesis of epidermoid cysts, it may arise from entrapped epithelial cysts during fusion of embryologic processes, also it may arise from hair follicles located within the connective tissue wall^(5,6) and these findings were evidenced in our study by presence of hair follicle on pathological examination of three periorbital epidermoid cysts, also incidence of epidermoid cysts at the midline of the floor of the oral cavity throughout our study may confirm the theory of occurrence of epidermoid cyst due to entrapment of epithelial remnants during fusion of embryologic processes lastly the

epidermoid cysts may be due to accidental intrusion of epithelial cells through the underlying dermis and this is also evidenced in our study where one patient presented with labial epidermoid cysts gave history of lip biting which may introduce epithelium deeply through the dermis, the epidermoid cysts were variable in sizes and diagnosed through our study with different diagnostic means, the labial epidermoid cysts diagnosed with aspiration of its contents followed with cytology which approved the presence of keratins, ultrasound examination of sub lingual and sub mandibular cysts revealed hypoechoic non vascular turbid contents within the dermis, and this finding is in accordance to the study of⁽⁷⁾ although ultrasound examination is safe, avoiding ionizing radiation and easy mean for diagnosis however it is operator dependent, and it does not give accurate information about the anatomy of the cyst and adjacent structures and in one case magnetic resonance imaging revealed well defined sub cutaneous cystic lesion that has T2 and flair hyper intense signal intensity and hypointense signal in T1W1 seen at the lateral part of the superior orbital ridge and this finding is found through the study of Elias et al⁽⁸⁾ although MRI gives accurate information about the cyst and its adjacent structures, but it is expensive and not available, through our study computerized tomography was used for most of the cases. It is valuable means for diagnosis of the epidermoid cyst through determination of its extent and presence of cystic fluid

As regard Histopathologic examination the epidermoid cyst composed of stratified squamous epithelium with keratin flakes in its lumen, while dermoid cyst contain additional skin appendages but teratoid cyst contain mesodermal contents⁽⁹⁾

In our study most of the cysts revealed presence

of acytic wall of stratified squamous epithelium with keratin flakes within its lumen and diagnosed as epidermoid cysts, while in three cases dermoid cyst contain hair follicles inside the dermis

The effective methods for managements of the epidermoid cysts is complete surgical excision, which is frequently accompanied with cell rupture and this may be due to to adhesion of the delicate cyst wall with the surrounding tissue without separating plane

And this rupture was managed sometimes with suturing the cyst wall delicately for the cyst to keep its contour to facilitate its enucleation in one sublingual epidermoid cysts with thick wall the contents was suctioned to minimize its size and facilitate its excision in all cases meticulous care was followed to remove the wall completely, one case presented with of labial, scalp and posterior neck epidermoid cysts, presented with recurrence of labial one and this may be due to presence of cyst remnants during previous surgery and this case managed with surgical excision, the recurrence rate of epidermoid cyst after surgical excision was 20 % according to the study of Dabholker et al^(10,11)

Our study showed different locations of epidermoid cysts- as regard maxillofacial region- along with its different pathogeneses and surgical managements, multiple study is required for epidermoid cysts although it has little incidence but it has clinical significance

CONCLUSION

Epidermoid cyst must be considered in differential diagnosis of cystic lesions of maxillofacial region, and must be managed delicately to prevent its recurrence and avoid injury of surrounding vital structures

REFERENCES

- 1- Gotmar. S, Gupta. A, &, Rathod. P, AND Nainani. P
Epidermoid cyst: a case report and review of literature.
panj 23. 226-229.2016
- 2- Sabhalok, S Shetty. S. Sarve. P Setiya S, Swati R.
Bharadwaj. S Epidermoid and dermoid cysts of the head
and neck region. *PlastAesthet Res*;3:347-50 .2016.
- 3- Rastogi V, Puri N, Kaur G, Ydave L and Sharma, Unusual
Cases of Epidermoid cyst: Case Series international jour-
nal of scientific study July-September (1) (2) 72-76.2013
- 4- (Mirza S, Fadl S, Napaki S, Abualruz A. Case report of
complicated epidermoidcystfloor of the mouth: Radiology-
histopathology correlation. *Qatar Med J*12-6-2014
- 5- CORTEZZI W, and Albuquerque A: Secondary infected
epidermoid cysts in the flour of the mouth causing a life
threatening situation: report of a case :j oral maxillofac
surg 52,762-764,1994
- 6- NegoroT,Hiraishi Y, Iwagami Y,and Fujita S Epithelial
Inclusion Cyst of the Tongue Clinically Mimicking Tongue
Cancer *Int J Oral- Med Sci* 8(3):167 – 170N,2010
- 7- Kim HK1, Kim SM, Lee SH, Racadio JM, Shin MJ.-
Subcutaneous epidermal inclusion cysts: ultrasound (US) and
MR imaging findings *Skeletal Radiol.* 40(11):1415-9.2011
- 8- Elias I, Oton-Leite A.,Silva C Ribeiro-Rotta R, Batista
A, Mendonça E Epidermoid cyst: highlights on diagnosis
and magnetic resonance imaging features *Rev. odonto
ciênc.*25(2):204-207.2010
- 9- Park J, and Ko D A histopathologic study of epidermoid
cysts in Korea comparison between ruptured and unruptured
epidermal cystm, *Int J Clin Exp Pathol*6(2):242-248.2013
- 10- Dabholkar JP, Patole AD, Sheth AS, Saaj R. Congenital
cystic lesions in head and neck. *Indian J Otolaryngol Head
Neck Surg* 55:128-30.2003,.
- 11- Costa F.W, Carvalho F .S, ChaveseF.N, Almedia S, Alves
A, P ET ALL: epidermoid cysts arising in the buccal
mucosa: case report and literature review *Actastomatol
Croat.* 2015;49(1):65-73.