

## EFFECT OF TWO COMPLETE DENTURE OCCLUSAL SCHEMES ON OCCLUSION AND DISOCCLUSION TIMES

Marwa Kothayer\* and Haitham A. Elsisi\*\*

### ABSTRACT

**Purpose:** The purpose of this study was to compare the effect of two different complete denture occlusal schemes on the occlusion and disocclusion times.

**Material and methods:** Eight completely edentulous male patients were selected, for each patient, two conventional complete dentures were constructed, one of them following the lingualized concept of occlusion and the other following monoplane concept of occlusion using the conventional technique of denture construction. Computerized occlusal analysis was conducted using the T-Scan system. Occlusal parameters (OT and DT) were recorded for both dentures for each patient.

**Results:** The results showed that occlusion time, right and left disocclusion time are higher in monoplane occlusal scheme dentures than lingualized occlusal scheme dentures and the difference was statistically insignificant.

**Conclusion:** Within the limits of this study no significant difference in occlusion and disocclusion time between lingualized and monoplane occlusal scheme complete dentures were found.

### INTRODUCTION

There are many philosophies concerning the most appropriate posterior occlusal forms for conventional complete maxillary and mandibular dentures, it is assumed that the form of the occlusal surfaces and the way they arranged become critical for successful complete denture function<sup>(1)</sup>.

Complete denture occlusion is defined as “the contact between the upper and lower teeth while the mandible is stationary”. It was also defined as the static relationship between the incising or masticatory surfaces of the maxillary and mandibular teeth<sup>(2)</sup>.

Occlusal designs and their resulting functions are of concern to the dentist so that loss of the remaining

\* Lecturer, Removable Prosthodontics Department, Faculty of Dentistry, Ain Shams University, Cairo, Egypt.

\*\* Assistant professor, Removable Prosthodontics Division, Oral and Maxillofacial Surgery and Rehabilitation Department, Faculty of Dentistry, Umm Al-Qura University, Mecca, Saudi Arabia.

tissues of the mouth, which may be attributed to the occlusion, can be minimized. This is difficult to assess since living tissues change and physiologic tolerances vary. More long-term statistical investigations are necessary to compare the various occlusal designs so that more definable guidelines may evolve. Until such guidelines are available, the dentist must rely on his clinical experience and clinical judgment to select the occlusal design or designs of his choice in the treatment of complete denture patients<sup>(3)</sup>.

It was stated that the occlusal schemes of the posterior denture teeth are considered to be important factors affecting denture stability and chewing efficiency<sup>(4)</sup>.

There are many occlusal schemes for complete denture construction; spherical theory of occlusion, lineal occlusal concept, flat teeth arranged with balancing ramp, flat teeth arranged with compensating curve, centralizing concept of occlusion, organic occlusal concept, lingualized occlusal concept and monoplane occlusal concept<sup>(5)</sup>.

The lingualized concept of occlusion was considered by many investigators as the occlusal scheme of choice for complete denture wearer, as well as for those rehabilitated by overdenture prosthesis where the basic guidelines of the lingualized occlusion were first suggested<sup>(6)</sup>. This concept requires the modification of the anatomic teeth to provide a limited range of excursive balance and a lingual to lingual working side cusp contact, such a contact will direct the force to the lingual side of the ridge to enhance the lever balance of the lower denture<sup>(7)</sup>. Only the maxillary palatal cusps occlude in the mandibular central fossae and marginal ridges in the centric relation position while simultaneous contacts must exist on the working and non-working sides during lateral movements and on the anterior and posterior teeth during protrusive movements<sup>(8)</sup>.

Monoplane occlusion involves the use of cusplless teeth that are arranged anteroposteriorly

parallel with the plane of the denture foundation. In a mediolateral direction, the teeth are positioned flat with no medial or lateral inclination. In addition, the number of teeth are reduced to direct the force in the bicuspid-molar region and to prevent placing the teeth on the ridge inclination in the second molar area. Furthermore, the upper and lower anterior teeth are arranged without any vertical overlap to establish a zero degree incisal guidance. However, if a vertical overlap is needed for appearance, adequate horizontal overlap should be made to guard against anterior interference within the functional range<sup>(9)</sup>.

Recently, computerized occlusal analysis help in the assessment of occlusal equilibration. It overcomes the drawbacks of the conventional methods such as articulating paper and occlusal indicator wax. Although this conventional methods is quick and straightforward, it can't help in the assessment of contact time sequence or quantify occlusal forces. Although articulating paper has been the most commonly used method, its marks affected by patient saliva and it is subjected to fragmentation and perforation during intercuspation<sup>(10-14)</sup>.

The T-Scan system was developed by Maness et al in 1987. The latest version (T-Scan III) provides a dynamic visual evaluation of a patient's occlusion from initial tooth contact to maximum intercuspation. The system records relative force values and allows for objective quantitative evaluation of occlusal balance by recording timed occlusal contacts and by displaying numerical values for occlusion and disocclusion times<sup>(11,15-18)</sup>.

Occlusion time (OT) is the time from the first contact of occluding teeth to maximum intercuspation, and disocclusion time (DT) is the time from maximum intercuspation to complete disocclusion during lateral movement. The clinical goal is to reach maximum intercuspation in less than 0.2 second and disocclude all posterior teeth in less than 0.4 second. The shorter the OT, the less time required to contact all teeth and the fewer the

prematurities as the patient closes into maximum intercuspation, indicating occlusal contact simultaneity and equilibration<sup>(19-23)</sup>.

The aim of the study is to evaluate OT and DT for different occlusal scheme to assess occlusal equilibration.

## MATERIALS AND METHODS

Eight completely edentulous male patients were selected from the Outpatient Clinic of Removable Prosthodontics Department, Faculty of Dentistry, Ain Shams University. All participants were given detailed information about the investigation and gave written informed consent for their participation. All participants were selected according to the following criteria:

1. Free from any sign and symptoms of TMJ disorders.
2. Exhibiting normal ridge relation (Angle class I ridge classification) with adequate inter-arch space and normal tongue size.
3. Patients had healthy mucosa free from any ulceration, inflammation or infections.
4. Free from abnormal tongue behavior and size.
5. Having no parafunctional habits.
6. Motivated and cooperative patient.

For each participant, two conventional complete dentures were constructed, one of them following the lingualized concept of occlusion and the other following monoplane concept of occlusion using the conventional technique of denture construction.

For the first denture Artificial teeth set-up was done using modified anatomic cross linked acrylic resin teeth following the lingualized occlusion concept. The lingual cusps of the mandibular posterior teeth were placed medial to a line drawn from the tip of the canine to the center of the retromolar pad. The interlocking transverse ridges

of the occlusal surface were ground. Maxillary posterior teeth were arranged with their palatal cusps occluding in the modified central fossae of the mandibular posterior teeth while the buccal cusps of the maxillary posterior teeth were reduced to eliminate buccal cusps contact in centric and eccentric position. Waxing up of the trial dentures was then completed. Try-in of the waxed up dentures was carried out in the patient's mouth then the waxed denture was processed and checked in the patient's mouth as regards retention, stability and extension. The dentures were then delivered to the patient. Participants were allowed to use their conventional dentures for two weeks then were recalled for the occlusion time (OT) and disocclusion time (DT) recording procedures.

The second denture was then constructed for each participant utilizing non-anatomic teeth with flat surfaces set to a flat occlusal plane following the monoplane concept of occlusion. The posterior limit of the lower posterior teeth is the point at which the mandibular ridge begins to curve upward, with elimination of contact between the upper and lower second molars. Waxing up of the trial dentures was then completed. Try-in of the waxed up dentures was carried out in the patient's mouth then the waxed denture was processed and checked in the patient's mouth then delivered to the patient. Participants were allowed to use their conventional dentures for two weeks then were recalled for the occlusion time (OT) and disocclusion time (DT) recording procedures.

Computerized occlusal analysis was conducted using the T-Scan system (T-Scan III v8; Tekscan Inc). The system uses a 100 µm thick recording sensor (high definition generation IV sensor; Tekscan Inc) that scanned in 0.003 second increments. The size of the sensor (large or small) was chosen to suit the participant's dental arch.

For all scanning procedures, participants were asked to sit in a relaxed upright position in the dental

chair. The sensor was held consistently in the same position with respect to the teeth. It was aligned to be parallel to the occlusal plane and centered on the midline between the central incisors (Fig. 1).

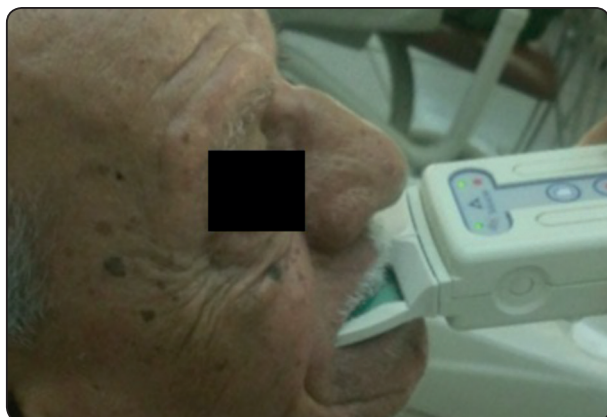

Fig. (1) Patient was sitting in a relaxed upright position in the dental chair while sensor held parallel to occlusal plane.

The system was initially used to perform computer-guided occlusal adjustment for all dentures. It was then used to record occlusal parameters, namely, OT and DT, for both dentures for each patient. For each participant, the same sensor was used throughout the adjustment and recording procedures.

Corrective occlusal adjustments were carried out for both dentures (the denture following the lingualized concept of occlusion and the denture

following monoplane concept of occlusion) for each patient using the center of force (COF) concept for each participant before occlusal parameter recording. Each participant was asked to firmly occlude into the sensor with their dentures until maximum intercuspation occurred, holding their teeth together for 1 to 3 seconds, and then asked to disocclude and reintersusate into the sensor once again. Premature contacts were then specifically adjusted based on the overloaded contact locations displayed and demarcated within the system's 2D (Fig. 2) and 3D (Fig. 3) force/view panes (through color coding and force values). The corrective adjustment was then repeated for each denture until premature contact was eliminated and better force distribution was achieved in each denture.

Occlusal parameters (OT and DT) were recorded for both dentures for each patient. The patient was asked to close on sensor in centric occlusion holding their teeth together for 1 to 3 seconds then start right eccentric movement until disoccluding their teeth. The patient was then asked to close on sensor in centric occlusion holding their teeth together for 1 to 3 seconds then start left eccentric movement until disoccluding their teeth. This was repeated 4 times for the right excursion (DT-right) and 4 times for the left excursion (DT-left). Mean OT, DT-right, and DT-left were then calculated by taking the averages of the recordings.

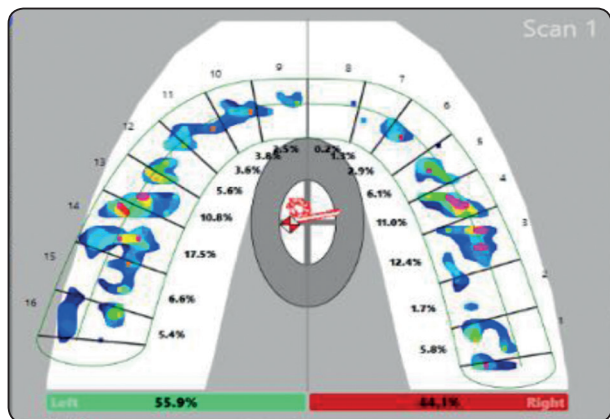


Fig. (2) 2D force/view shows unequal force distribution between right (44.1%) and left (55.9%) sides.

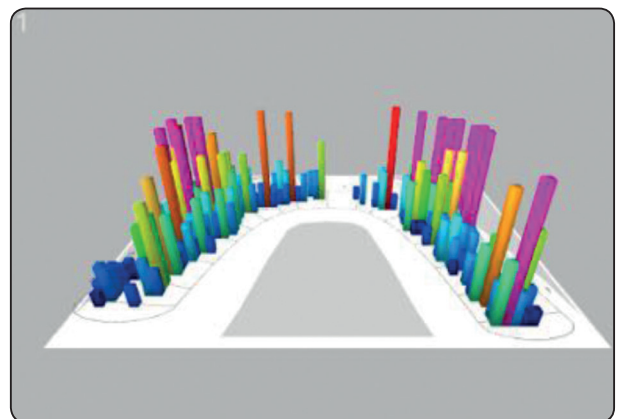


Fig. (3) 3D force/view shows premature contacts at particular areas.

Data were collected, tabulated and statistically analyzed to compare between both occlusal schemes for each patient.

## RESULTS

The results are based on a computerized occlusal analysis conducted for a total of eight patients using the T-Scan system. It was then used to record occlusal parameters, namely, OT and DT, for both dentures for each patient.

Numerical data were explored for normality by checking the data distribution, calculating the mean and median values, evaluating histograms and normality curves and using Kolmogorov-Smirnov and Shapiro-Wilk tests. Data were presented by mean and standard deviation (Std. deviation). Paired T test used for comparison between groups and the significance level was set at  $P \leq 0.05$ . Statistical analysis was performed with IBM® SPSS® Statistics Version 20 for Windows.

The results showed that occlusion time, right and left disocclusion time are higher in monoplane occlusal scheme dentures than lingualized occlusal scheme dentures and the difference was statistically insignificant (Table 1).

## DISCUSSION

Patients were selected free from any sign and symptoms of TMJ disorders as TMD was reported to significantly prolong occlusion and disocclusion time<sup>(21)</sup>.

Also patients exhibiting normal ridge relation (Angle class I ridge classification) were selected as with an Angle Class II or Class III occlusion, the contact points move posteriorly or anteriorly making the T-scan readings confusing<sup>(24)</sup>.

The abnormal tongue behavior or size was exclusive factor during the patients selection, as that may affect the dentures stability and subsequent the t-scan results<sup>(25)</sup>.

In lingualized occlusion concept setting up of teeth was done with no buccal contact in working side excursions to reduce lateral movement of lower denture by placing occlusal forces more lingual to the center of mandibular denture<sup>(26,27)</sup>.

In monoplane occlusion concept, cusplless teeth are arranged anteroposteriorly parallel with the plane of the denture foundation and with no medial or lateral inclination to enhance denture stability, the upper and lower anterior teeth are arranged without any vertical overlap to establish a zero degree incisal guidance<sup>(9)</sup>.

TABLE (1) Occlusion and disocclusion times in lingualized and momoplane complete denture occlusal schemes.

Occlusion parameter		Mean	Std. Deviation	P value
OT	Lingualized	0.27600	0.032090	0.357
	Monoplane	0.30200	0.049700	
DT- Right	Lingualized	0.34	0.0480	0.357
	Monoplane	0.38	0.034	
DT- Left	Lingualized	0.346	0.024	0.27
	Monoplane	0.398	0.013	

The T-Scan system (T-Scan III v8; Tekscan Inc) was used in this study as it was reported that occlusion and disocclusion time were precisely recorded by T Scan III system and a study comparing the sensitivity of various occlusal indicators found T-scan to be the only indicator not affected by saliva<sup>(28,29)</sup>.

Occlusion time and disocclusion time represent the time lag obtained from occlusal contact recordings from the first premature contact to maximum intercuspation and from maximum intercuspation to complete disocclusion during lateral movement. As a result, shorter durations indicate stable occlusal balance of dentures on their residual ridges and the absence of premature contacts<sup>(10)</sup>.

For all occlusal adjustment and recording procedures, participants were asked to sit in a relaxed upright position in the dental chair as an increasingly significant relationship between the sagittal plane head-neck posture and initial occlusal contacts has been reported for those over the age of 30<sup>(30)</sup>.

As claimed by many authors balanced occlusal concept increase denture stability and so reduce the OT in centric occlusion, the occlusion time is higher in monoplane occlusal scheme dentures than the lingualized occlusal scheme dentures but the difference was insignificant<sup>(31)</sup>. Also due to the instability of complete dentures following the monoplane occlusal scheme there is excessive friction between the occluding teeth that may be the cause of increased DT in monoplane occlusal scheme during right and left lateral movement<sup>(32)</sup>.

## REFERENCES

1. Sutton AF, McCord JF. A randomized clinical trial comparing anatomic, lingualized, and zero-degree posterior occlusal forms for complete dentures. *J Prosthet Dent* 2007; 97:292-298.
2. Academy of Prosthodontics. The glossary of prosthetic terms: Ninth Edition. *J prosthet Dent* 2017; 117: e 63.
3. Beck HO. Occlusion as related to complete removable prosthodontics. *J Prosthet Dent* 1972; 27:246-262.
4. Zarb GA, Bolender CL, Carlsson GE. Boucher's prosthodontic treatment for edentulous patient. Eleventh Edition. *Occlusion for the edentulous patient*. Saint Louis: Mosby Co, 1997:262-278.
5. Kaddah AF. *Occlusion in prosthodontics. Concepts of occlusion*. Cairo: Dar El-Ethad for printing, 1988: 336-375.
6. Ohguri T, Kawano F, Ichikawa T, Matsumoto N. Influence of occlusal scheme on the pressure distribution under complete denture. *Int J Prosthodont* 1999; 12: 353-358.
7. Pound E. Utilizing speech to simplify a personalized denture service. *J Prosthet Dent* 1970; 24: 586-600.
8. Basso MF, Nogueira SS, Arioli-Filho JN. Comparison of the occlusal vertical dimension after processing complete dentures made with lingualized balanced occlusion and conventional balanced occlusion. *J prosthet Dent* 2006; 96: 200-204.
9. Jones PM. The monoplane occlusion for complete dentures. *J Am Dent Assoc* 1972; 85: 94-100.
10. Okuma K, Hirano S, Hayakawa I. Occlusal pressure pattern analysis of complete dentures for evaluation of occlusal adjustment. *J Med Dent Sci*. 2004; 51:197-203.
11. Koos B, Godt A, Schille C, Göz G. Precision of an instrumentation-based method of analysing occlusion and its resulting distribution of forces in the dental arch. *J Orofac Orthop* 2010; 71:403-410.
12. Qadeer S, Kerstein R, Kim RJY, Huh JB, Shin SW. Relationship between articulation paper mark size and percentage of force measured with computerized occlusal analysis. *J Adv Prosthodont* 2012; 47:7-12.
13. Kerstein RB. Articulating paper mark misconceptions and computerized occlusal analysis technology. *Dent Implantol Update* 2008; 19:41-6.
14. Gazit E, Fitzig S, Lieberman MA. Reproducibility of occlusal marking techniques. *J Prosthet Dent* 1986; 55:505-509.
15. Maness WL, Benjamin M, Podoloff R, Bobick A, Golden RF. Computerized occlusal analysis: a new technology. *Quintessence Int* 1987; 18:287-292.
16. Martins MJS, Caramelo FJ, Ramalho da Fonseca JA, Nicolau PMG. In vitro study on the sensibility and

- reproducibility of the new T-Scan III HD system. *Rev Port Estomatol Med Dent Cir Maxilofac* 2014; 55:14-22.
17. Kerstein RB, Thumati P, Padmaja S. Force finishing and centering to balance a removable complete denture prosthesis using the T-Scan III computerized occlusal analysis system. *J Indian Prosthodont Soc* 2013; 13: 184-188.
  18. Throckmorton GS, Rasmussen J, Carlsson R. Calibration of T-Scan sensors for recording bite forces in denture patients. *J Oral Rehabil* 2009; 36: 636-643.
  19. Sierpiska T, Golebiewska M, Kuc J, Lapuc M. The influence of the occlusal vertical dimension on masticatory activities and hyoid bone position in complete denture wearers. *Adv Med Sci* 2009; 54:104-108.
  20. Gümüş, HÖ, Kılınc H\_I, Tuna SH, Ozcan N. Computerized analysis of occlusal contacts in bruxism patients treated with occlusal splint therapy. *J Adv Prosthodont* 2013; 5:256-261.
  21. Haralur SB. Digital evaluation of functional occlusion parameters and their association with temporomandibular disorders. *J Clin Diagn Res* 2013; 7: 1772-1775.
  22. Kerstein RB, Grundset K. Obtaining bilateral simultaneous occlusal contacts with computer analyzed and guided occlusal adjustments. *Quintessence Int* 2001; 32:7-18.
  23. Kerstein RB, Wright N. Electromyographic and computer analyses of patients suffering from chronic myofascial pain-dysfunction syndrome: before and after treatment with immediate complete anterior guidance development. *J Prosthet Dent* 1991; 66:677-686.
  24. Olivieri F, Kang KH, Hirayama H, Maness WL. New method for analyzing complete denture occlusion using the center of force concept: A clinical report. *J Prosthet Dent* 1998; 80: 519-523.
  25. Basker RM, Watson CJ. Tongue control of upper complete dentures: a clinical hint. *Br Dent J* 1991; 170: 449-450.
  26. Shirani M, Mosharraf R, Shirany M. Comparisons of Patient Satisfaction Levels with Complete Dentures of Different Occlusions: A Randomized Clinical Trial. *J Prosthodont* 2014; 23: 259-266.
  27. Becker CM, Swoope CC, Guckers AD. Lingualized occlusion for removable prosthodontics. *J Prosthet Dent* 1977; 38: 601-608.
  28. Garrido Garcia VC, Garcia Cartagena A, Gonzalez Sequeros O. Evaluation of occlusal contacts in maximum intercuspation using the T-Scan system. *J oral rehab* 1997; 12: 899-903.
  29. Saraçoğlu A, Ozpinar B. In vivo and in vitro evaluation of occlusal indicator sensitivity. *J Prosthet Dent* 2002; 88: 522-526.
  30. Makofsky HW, Sexton TR, Diamond DZ, Sexton MT. The effect of head posture on muscle contact position using the T-Scan system of occlusal analysis. *Cranio* 1991; 9: 316-321.
  31. Kumar M, D'Souza CD. Comparative Evaluation of Two Techniques in Achieving Balanced Occlusion in Complete Dentures. *Med J Armed Forces India* 2010; 66: 362-366.
  32. Williamson RA, Williamson AE, Bowley J, Toothaker R: Maximizing mandibular prosthesis stability utilizing linear occlusion, occlusal plane selection, and centric recording. *J Prosthodont* 2004; 13: 55- 61.