

PERIOTEST MEASUREMENT OF TOOTH- IMPLANT RETAINED BILATERAL MANDIBULAR DISTAL EXTENSION REMOVABLE PROSTHESIS WITH ERA ATTACHMENTS

Nancy N El Sherbini* , Ahmed N El Sherbini** and Neidermeier W.***

ABSTRACT

Aim: The aim of this study was to measure the stability of natural tooth and implant using periotest, in bilateral distal extension base, using ERA-ERA connection on one side and RPI-ERA on the other side.

Material and Methods: Ten patients with mandibular bilateral distal extension arches, with second premolar as last standing tooth, were selected for this study. Every patient received one implant placed distally at the region of the second molar bilaterally. The patients received removable prosthesis retained on one side by RPI while the other side received ERA attachment. Both implants were retained to the prosthesis using ERA attachment. Patients were evaluated for tooth and implant stability using Periotest at time of prosthesis insertion, after one month, three months and six months after insertion. The study was a split mouth design.

Results: Periotest measurements significantly decreased (increase in stability) with presence of ERA attachments on natural tooth and implants more than when the RPI was used on the natural tooth.

Conclusion: It can be concluded that the ERA attachments was more preservative for natural teeth periodontium than RPI clasp retainer. In addition, the stability of implant improved gradually by time.

INTRODUCTION

Mandibular distal extension cases have a smaller area of support compared with the distal extension area of the maxilla. In addition, mandibular bilateral distal extension RPD is supported by two different structures, the edentulous ridges and abutment teeth. These two different structures have different

resiliency responses to loading.^{1,2}

Distal-extension removable partial dentures inherit biomechanical problems. The movements in different directions due to the alveolar ridge shape and soft tissue resiliency can lead to damaging forces on the supporting structures.^{2,4}

* Lecturer Removable Prosthodontics, Faculty of Dentistry, Cairo University

** Lecturer Removable Prosthodontics, Faculty of Dentistry, MSA University.

*** Professor Prosthetic Department, Faculty of Dentistry, University of Cologne.

Different techniques and designs have been proposed to solve the problems associated with distal extension cases and to minimize the harmful effects of the prosthesis on the supporting structures. Implant supported removable partial denture aims to provide better mechanical and biological properties to the stomatognathic system.³⁻⁵

The insertion of posterior implant support for removable partial denture has an obvious improvement over the conventional distal extension base in increasing denture stability and patient comfort.⁶⁻¹⁰

Placing two implants as terminal abutments in distal extension bases, converts it to tooth-implant bounded base, where tooth-implant bases have an improved support, stability, and retention more than in distal extension bases. This could be seen as a cost effective alternative compared with implant-retained fixed prosthetic options¹¹⁻¹⁵

Attachment retained removable partial denture is an alternative treatment providing better support, esthetics and maintaining health of the supporting structures. Many types of resilient attachments were used in implant-retained removable partial dentures. One of the resilient attachments usually used in implant that improved the functions of removable partial dentures is the resilient attachment (ERA). Prostheses with ERA attachments displayed great stress distribution on the supporting structures¹⁶.

The stability of natural tooth and implant was examined by different devices for evaluation and assessment of the health of the supporting structures. Periotest has been thoroughly studied and advocated as a method to determine tooth and implant stability. The periotest measuring procedure is through electromechanically monitored tapping head with pressure sensitive tip which records the duration of contact with the tooth or implant¹⁷⁻¹⁹

The Periotest measurements on implants are made 2 mm above the cervical gingiva in order

to eliminate the moment effect. In tissue level implants, this hit point will be almost at the same distance from the implant neck for all the implants included in this study¹⁷.

The aim of this study was to measure the stability of natural tooth and implant using periotest, in tooth-implant retained removable partial prosthesis in bilateral distal extension base, using ERA-ERA connection on one side and RPI-ERA on the other side in a split mouth design.

MATERIALS AND METHODS

Ten patients with mandibular bilateral distal extension bases with second premolars as last standing tooth opposing maxillary full dentate were selected for this study from the Outpatient Clinic of the Prosthodontics Department, Faculty of Dentistry, Cairo University.

Patients were selected according to the following criteria; patients with age average of 35-40 years, with angle class I maxillo-mandibular relationship, sufficient inter-arch space ≥ 12 mm, and adequate buccolingual width with firm attached mucosa, good physical and psychological condition to tolerate conventional implant surgical protocol.

Exclusion criteria: Patients with systemic diseases which have direct influence on metabolism, wound healing or osteointegration, such as, Diabetes mellitus and irradiation were excluded. The implants placed in irradiated bone showed significantly lower success rates, risk of osteoradionecrosis, obliteration of fine vasculature and progressive fibrosis. Smoking is a significant factor that may lead to implant failure, so smokers were excluded. Patients with para-functional habits as bruxism and clenching were excluded to avoid undue stresses especially for horizontal type of stresses that may affect the desired implant success. Also, patients with TMJ disorders were excluded.

Temporary acrylic removable partial denture was fabricated for all patients until the definitive one was constructed.

Patients' partial dentures were duplicated to form radiographic stents to insert implants at the proposed sites.

Every patient received two implants placed distally at the region of the second molar tooth to form bounded base between second premolar anteriorly and implant posteriorly bilaterally. Screw type, root form implants (Zimmer Dental, Carlsbad, CA, USA) were placed using a standard one stage protocol.

Preparation of the abutment 45 was done , wax pattern of crown with ERA attachment(Sterngold Dental, LLC, 23 Frank Mossberg Drive, Attleboro, MA,USA) and mesial occlusal rest was built up, the female ERA part was attached to the distal side of the abutment with the help of Bredent milling machine(Bredent, Senden, Germany) and aligned parallel to the path of insertion and then casting was done. Crown with the female part was tried in the patient's mouth and then cemented.

After osseointegration period, healing collars were removed from the implants. A closed impression technique was made to the implants, the crown on abutment 45 with ERA attachment on the ERA-ERA side, and the unprepared abutment 35

on the RPI-ERA side, with an occluso-mesial rest seat preparation. Using a refractory duplicate of the master cast, wax pattern of the metal frame work was made to carry housing of the ERA attachments and a bracing arm joined to the mesial occlusal rest. While, on the RPI-ERA side, wax pattern of the RPI assembly was made with a mesh-work base attached to it with a place for the ERA housing in the area corresponding to the implant site, then casting of the wax pattern of the framework of both sides as one unit was done.

On the master cast, the casted frame work was placed, with the ERA attachment abutments screwed to analogues on both sides with housing and processing cap embedded in the housing. Waxing up of the prostheses on both sides, setting up of teeth, and processing was done. After processing, the processing caps were replaced with the retentive nylon caps. ERA attachments were screwed to the implants on both sides and then the prostheses were inserted (Fig 1-2).

The patients were instructed to preserve strict oral hygiene with special care around implants.

Each patient was evaluated at the time of prosthetic loading and recalled after one month, three months and finally after six months to investigate the stability of natural abutments and implants using periotest.

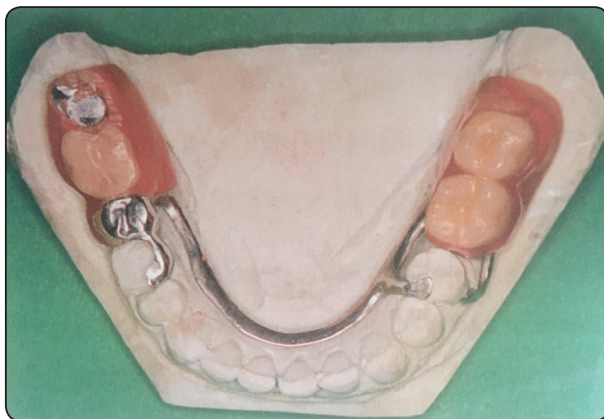


Fig. (1) Frame work placed on master cast

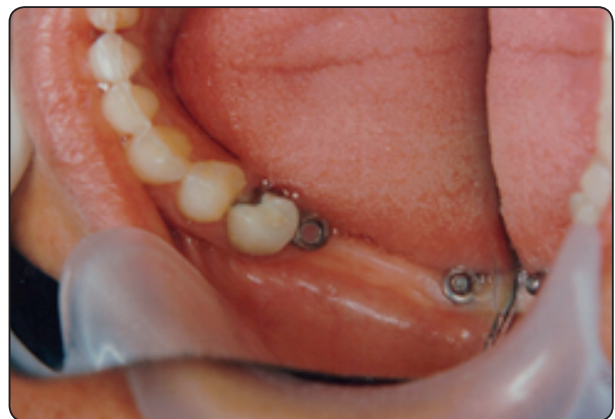

Fig. (2) Crown with ERA attachment

Periotest measurements (Medizintechnik Gulden, Modautal, Germany) are based on the impact hammer method in which impact force is used as excitation force.

Data were analysed using SPSS 17 (SPSS Inc, Chicago, IL, USA). Two way ANOVA test and Bonferroni's post-hoc test were used. Results are presented in Table 1 and Figure 3.

RESULTS

The obtained data and their statistical analysis were tabulated in (Table 1) graphically illustrated in (Fig. 3) and explained through the following

Tooth Stability:

a) Effect of retainer type on tooth stability on either side within each interval.

On the day of insertion the teeth showed good stability on the RPI-ERA side (-2.3 ± 1.13) and on the ERA-ERA side (-2.9 ± 1.27), there was statistically non significant difference between both sides.

One month after insertion stability showed slight decrease on both sides, also the difference between the two values was statistically non-significant.

Three months after insertion the RPI-ERA side showed (-1.9 ± 0.41) while the ERA-ERA side showed (-3.8 ± 1.35) the difference between the two values was statistically significant with $P < 0.01$.

Sixth months after insertion tooth stability on the RPI-ERA was ($+0.9 \pm 0.043$) while that on the ERA-ERA side was (-4 ± 1.03) there was statistically significant decrease in tooth stability on the RPI side compared to the ERA-ERA $P < 0.001$.

b) Effect of time on tooth stability for each retainer along the whole follow up intervals.

For the RPI-ERA side, teeth stability showed

statistically non significant difference along the first the time intervals (0, 1 & 3) months. For the difference between 3 and 6 months intervals there was statistically significant decrease in tooth stability $P < 0.001$.

For the ERA-ERA side, the teeth maintained their proper stability through the whole follow up periods (0, 1, 3 & 6) months without any significant change $P > 0.05$.

Implant stability:

a) Effect of retainer type on implant stability on either side within each interval.

On the day of insertion the implant showed good stability on the RPI-ERA side (-3.9 ± 1.24) and on the ERA-ERA side (-3.6 ± 1.85), there was statistically non significant difference between both sides.

One month after insertion implant stability was (-4.2 ± 1.51) on the RPI-ERA side while on the ERA-ERA side was (-4.9 ± 1.93). Three months after insertion the RPI-ERA side showed (-4.8 ± 1.67) while on the ERA-ERA (-5.7 ± 2.04). Sixth months after insertion implant stability on the RPI was (-5.1 ± 1.88) while that on the ERA side was (-6.3 ± 2.01). Although implant stability increased on both sides through the whole follow up period yet this increase was statistically non-significant $P > 0.05$.

b) Effect of time on implant stability for each retainer along the whole follow up intervals.

For the RPI-ERA side, implant stability showed statistically non-significant difference along the first the time intervals (0, 1, 3 & 6) months $P > 0.05$.

For the ERA-ERA side, implant stability showed statistically significant increase between the first and third follow up periods only $P < 0.05$.

TABLE (1) Shows the stability values for both tooth and implant with both retainers along the follow up periods

Periods of measurements	Tooth Abutments		Implants	
	RPI	ERA	RPI-ERA	ERA-ERA
Immediately	-2.3±1.13	-2.9±1.27	-3.9±1.24	-3.6±1.85
One month	-2.1±0.96	-3.1±1.08	-4.2±1.51	-4.9±1.93
Three months	-1.9±0.41	-3.8±1.35	-4.8±1.67	-5.7±2.04
Six months	+0.9±0.043	-4±1.03	-5.1±1.88	-6.3±2.01

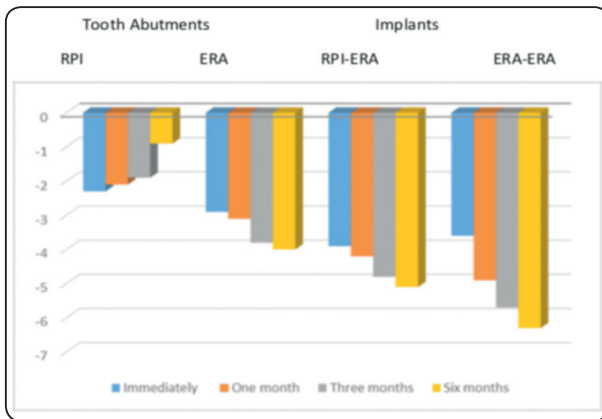


Fig. (3) Bar graph showing stability for both tooth and implant with both retainers along the follow up periods

DISCUSSION

Comparison of the results of mobility showed that there was a difference between the mean changes of both sides.

The implants showed no sign of mobility. The increase in implants stability can be attributed to the nature of bone, in which bone remodeling whether it is bone deposition or bone resorption, is induced by bone stimulation. When functional loading has been initiated, the bony structures adapt to the load by improving the quality of the bone; replacing pre-existing, necrotic and/or initially formed more primitive woven bone with mature, viable lamellar bone. This is supported by KOYAMA et al. (2011)²⁰

The healthy cuff around implant became more tightened by time also the nylon caps exerted less force with intermittent stresses that stimulate for more osseointegration hence better stability.

The position of the implant can have a significant effect on force distribution. Implants placed in the second molar location provided good support and stability.⁸⁻¹¹

Abutment tooth with RPI at proximal plate where it snugly contacts the distal surface of the abutment that may increased the chance for accumulation of food debris, saliva and microorganism with continuous push of retentive portion lingually. While Abutment tooth with ERA attachment side showed more healthy tissue response this may be due to presence of crown coverage on the abutment and the retainer placed away from the gingiva, also the presence of the non-rigid support which compensated for the difference in intrusion between implant and natural abutments, so fewer forces were transmitted to the natural abutment contributing to better stability.

Also the resiliency of the ERA attachment displayed favorable stress distribution on the supporting structures.

CONCLUSION:

From the results of the study it was concluded that ERA attachment is better than RPI clasp retainer as related to preservation of natural abutment. With the use of ERA with implant there was progressive improvement in implant stability.

REFERENCES

- Carr, AB, McGivney GP, and Brown DT: McCracken's removable partial prosthodontics. 11th ed. . 2005. St. Louis, Elsevier Mosby .pp25,26,28,287
- Carr AB, Brown DT, McCracken's removable prosthodontics. 12th ed. 2011. St. Louis: Elsevier Mosby. pp21,, 24,231
- Togano H, Hideshima M, Ohyama T. Reproducibility of interocclusal recording for mandibular removable partial denture in bilateral 1 distal extension cases. J Med Dent Sci. 2003 ;50:53-61.
- Lee, HE Wu JH, C.H. Wang CH, LAN TH, DU1 JK .Biomechanical analysis of distal extension removable partial dentures with different retainers J Dent Sci, 2008 3:133-139
- Goncalves TM, Campos CH, Goncalves GM, de Moraes M, Rodrigues Garcia RC. Mastication improvement after partial implant-supported prosthesis use. J Dent Res. 2013;92:189S-194S.
- Campos CH, Goncalves TM, Rodrigues Garcia RC. Implant retainers for free-end removable partial dentures affect mastication and nutrient intake. Clin Oral Implants Res. 2014;;25::957-961
- FU M SHEN YW, FUH LJ Clinical application of implant-supported bilateral distal extension removable partial denture - case report. J Dent Sci, 2007; 2:52-56 ,
- Ohkubo C, Kobayashi M, Suzuki Y, Hosoi T Effect of implant support on distal-extension removable partial dentures: in vivo assessment. Int J Oral & Maxillofac Implants 2008 ; 23:1095-1101
- Goncalves TM, Campos CH, Rodrigues Garcia RC. Implant retention and support for distal extension partial removable dental prostheses: Satisfaction outcomes. J Prosthet. Dent. 2014; 112:334-339.
- Jensen C, Raghoebar GM, Kerdijk W, Meijer HJA, Cune MS, Implant-supported mandibular removable partial dentures; patient-based outcome measures in relation to implant position. J Dent. 2016; 55:92-98.
- Goncalves TM, Campos CH, Garcia RC. Effects of implant-based prostheses on mastication, nutritional intake, and oral health-related quality of life in partially edentulous patients: A paired clinical trial. Int J Oral Maxillofac Implants. 2015;30:391- 396.
- Mijiritsky E. Implants in conjunction with removable partial dentures: a literature review. Implant Dent 2007;16:146-154.
- Matsudate Y, Yoda N, Nanba M, Ogawa T, Sasaki K. Load distribution on abutment tooth, implant and residual ridge with distal extension implant-supported removable partial denture. J Prosthodont Res. 2016;60:282-288
- de Freitas RF, de Carvalho Dias K, da Fonte Porto Carreiro A, Barbosa GA, Ferreira MA. Mandibular implant-supported removable partial denture with distal extension: A systematic review. J Oral Rehabil. 2012; 39:791-798.
- Sato M, Suzuki Y, Kurihara D, Shimpo H, Ohkubo C. Effect of implant support on mandibular distal extension removable partial dentures: Relationship between denture supporting area and stress distribution. J Prosthodont Res. 2013; 57:109-112.
- Shahmiri RA, Atieh MA. Mandibular Kennedy Class I implant-tooth-borne removable partial denture: a systematic review. J Oral Rehabil 2010; 37:225-234.
- Atsumi M, Park S, Wang HL .Methods used to Assess implants stability .Current status Int. J Oral Maxillofac Implants. 2007;22:743-754
- Goellner M, Schmitt J, Holst S, Petschelt A, Wichmann M, Berthold C. Correlations between tooth mobility and the Periotest method in periodontally involved teeth. Quintessence Int 2013;44:307-316
- Chakrapani S, Goutham M, Krishnamohan, T Anuparth, S Tadiboina N, Periotest values: Its reproducibility, accuracy, and variability with hormonal influence Contemporary Clin Dent ,2015; 6:12-15
- Koyama S, Sasaki H, Yokoyama M, Yamamoto M, Naoko Sato, Reisberg D and Sasaki K, Changes in bone metabolism around osseointegrated implants under loading, Implant Dent 2011; www.intechopen.com: 203-218