

## REMODELING OF THE TEMPROMANDIBULAR JOINT FOLLOWING DIFFERENT RATES OF MANDIBULAR DISTRACTION OSTEOGENESIS (AN EXPERIMENTAL STUDY)

Hala R. Ragab\* and Amel Radwan El Hak\*\*

### **ABSTRACT**

**Introduction:** patients with craniofacial deformities resulting from trauma, infection, tumors and congenital defects usually require skeletal expansion. Tradition treatment methods, involve autogenous bone grafting, which often results in problems including graft resorption, infection and donor site morbidity. Distraction osteogenesis has been adopted more and can help overcome these problems.

**Aim of the work:** the purpose of this study was to compare histologically the effect of bilateral distraction osteogenesis of the mandibular body at different rates on the integrity of the condylar cartilage in rabbits.

**Material and Methods:** This study was performed on 2 groups of twelve healthy rabbits (adult male) : (group 1 and group 2) each group (n=6 rabbits, and 12 joints). Two rabbits (4 joints) in each subgroup according to the post distraction period (1, 2, and 4 weeks). In group 1, the distraction was performed daily at rate of 1 mm for 5 days. In group 2, the distraction was performed twice daily at rate of 1.5 mm (3 mm per day) for 5 days.

**Results:** Animals in both groups (1 and 2) showed changes in condylar head, which seemed to be reversible according to the post distraction period. After the first week, condylar layers were decreased in thickness with irregular fibrous outline, bone trabeculae were decreased in number and invaded by large number of osteoclasts. After the second week, the condylar head showed evidence of regeneration of all layers including the disc. After the fourth week, the subchondral area started to be refilled with new bone with numerous osteoblast. Group 2 (3 mm per day) showed more bone and collagen formation.

**Conclusion:** this experimental study reported that distraction rates of 1 mm per day and 3 mm per day showed degenerative change in the TMJ condylar cartilage in the first post distraction week. At the second week, all the condyles showed adaptive and remodeling signs. Regeneration to the normal histological structure appeared in the fourth post distraction weeks, in group 2 (3 mm per day) more than in group 1 (1 mm per day).

\* Assistant Professor of Oral and Maxillofacial Surgery, Faculty of Dentistry, Alexandria University.

\*\* Professor of Oral Biology, Faculty of Dentistry, Alexandria University.

## INTRODUCTION

Distraction osteogenesis is the biological process of bone formation between pre-existing bone segments that are gradually drawn apart by controlled traction, which stimulates bone formation. Previous studies reported that distraction osteogenesis has the benefit of increasing bone length and the volume of surrounding soft tissues<sup>(1,2)</sup>.

Distraction osteogenesis can be applied to craniofacial reconstruction including osseous and soft tissues deficiencies, cleft lip and palate reconstruction, reconstruction of alveolar process for dental implant and a new mandibular condyle regeneration<sup>(3)</sup>.

Distraction osteogenesis passes by three periods which are: 1- Latency period: It is the period immediately following corticotomy or osteotomy to the onset of distraction, in order to allow callus formation over the cut bony surfaces, 2- Distraction period: It is the period during which gradual traction force is applied to the bony segments, 3- Consolidation period: It is the period during which the newly formed bone is allowed to mature and to gain the necessary strength (4).

There are many factors that affect the results of distraction osteogenesis on skeletal and non-skeletal tissues such as: rate and rhythm of the distraction, latency period, vector of distraction, gap distance and consolidation period and the duration of follow up (4).

One of the most complex joints in the body is the temporomandibular joint. The mandibular condylar cartilage is a primary growth center which responds to mechanical forces. It was considered that the mandible and the TMJ are considered as a functional unit, hence mechanical loading on the distracted mandibles will have an effect on the articular cartilage (5, 6). Stelnicki et al., (2001) (4) reported that the mandibular distraction osteogenesis

in transverse dimension was followed by changes: flattening, erosion and displacement of the condyle.

The long period required for bone distraction and consolidation was considered to be the main disadvantage of mandibular distraction osteogenesis. The rapid rate of distraction and reducing overall treatment time would decrease the patient discomfort during the process. The abundant blood supply of the craniofacial bones makes the use of a rapid distraction rate possible<sup>(4,7)</sup>.

This study was designed to evaluate histologically the effect of different rates of distraction osteogenesis of the mandibular body on the integrity of the temporomandibular joint in rabbits.

## MATERIALS AND METHODS

The experimental study was performed on twelve adult healthy male white New Zealand rabbits (2 to 3 kg) divided into 2 groups, group 1 and group 2. Each group (6 rabbits – 12 joints) divided into 3 subgroups according to the post distraction follow up period, (2 rabbits – 4 joints) in each subgroup.

A custom made stainless steel distraction device suitable for rabbits mandibles. The device was designed to be fixed extra orally, allowing simultaneous unidirectional bilateral distraction of the body of the mandible in anterior direction.

The animals were selected free from any disease. The animals were weighed to estimate the amount of anaesthetic solution. The animals fasted the night before the surgical operation to prevent vomiting after anesthesia.

All rabbits received general anesthesia using intramuscular ketamine (50 mg/kg) and xylazine (10mg/kg). In addition 1.0 ml of local anesthesia (2% Lidocain/epinephrine 1:100.000) was injected into the surgical site before beginning the operation to control bleeding.

The skin was shaved over inferior mandibular borders (left and right) and sterilized with Betadine.

Two skin incisions were made from the mandibular angle to the anterior region. A vertical corticotomy on both sides (buccally and lingually) was made between the premolar teeth and mental foramen using a tapered carbide fissure bur under copious irrigation using saline. Caution was taken to preserve the vascular bundle.

Titanium screws were used to fix the distraction device (Fig. 1). The periosteum and skin were sutured using 3-0 vicryl and black silk (Fig. 2).

After the surgical procedure intramuscular injection of Gentamicin (5mg/Kg) will be given daily for one week to prevent infection. Ketoprofen analgesic medication (1mg/kg) was given for three days to control postoperative pain. The animals will

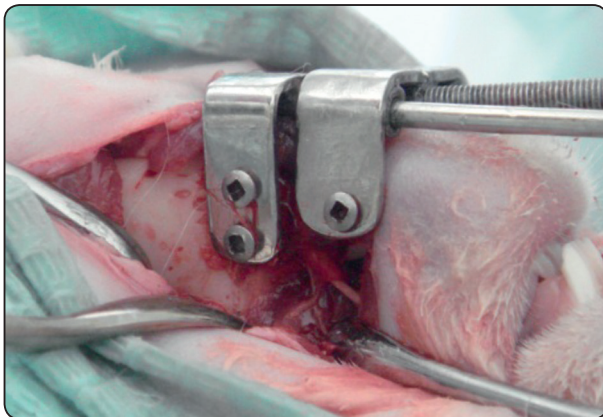


Fig. (1): Fixation of the distraction device after corticotomy of the mandibular cortex.

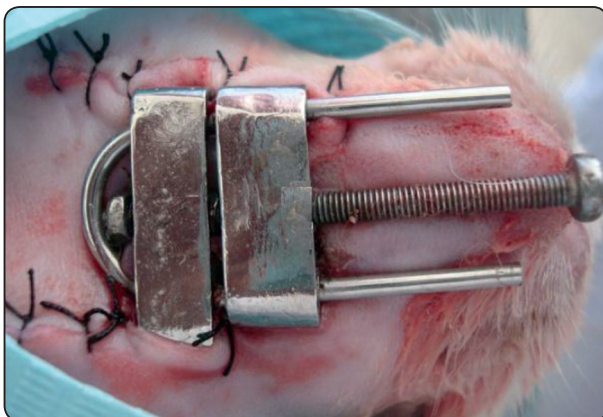


Fig. (2): Suture of the skin.

be kept under observation till complete recovery in a hygienic environment. Glucose water was given to the animals on the first postoperative day. Then the rabbits were kept on soft diet consisting of bread all the postoperative period.

Daily postoperative examination was performed to evaluate wound healing, progress of distraction, ability to eat and drink, deviation of the mandible and any arising complication including signs of infection or edema. Care of the wound was carried out daily with iodine solution and application of topical antibiotic spray.

After a latency period of 4 days, distraction was performed:

- Group 1: distraction was performed daily at a rate of 1 mm for 5 days (total elongation was 5mm).
- Group 2: distraction was performed twice daily at a rate of 1.5 mm (total 3 mm per day) for 5 days (total elongation was 15 mm).

Two animal of each group were sacrificed at the end of the 1<sup>st</sup>, 2<sup>nd</sup> and 4<sup>th</sup> post distraction weeks.

## RESULTS

All the animals tolerated the surgical procedure very well and completed the study in good health. There were no postoperative infections. The soft tissues were intact and normal in appearance in the area of surgery. The distraction devices remained stable without loosening. During distraction, the device was easily activated and there was no problem with activation of the screw, with no need for sedation of the animals.

Examining the animals at the time of sacrifice showed elongation of the mandible due to the distraction.



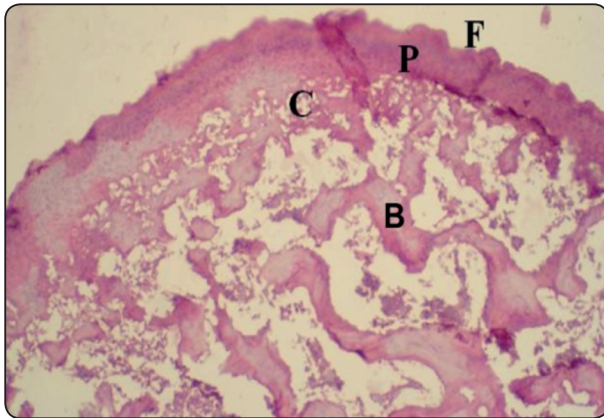
### HISTOLOGICAL EVALUATION

#### A- HEMATOXYLIN AND EOSIN STAIN

##### After the first post distraction week

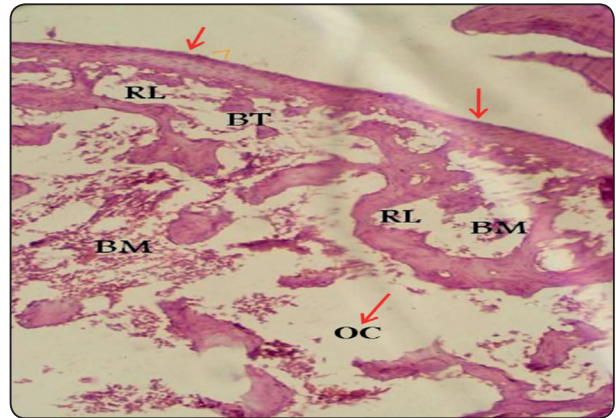
###### Group 1 (1 mm per day)

The condylar head showed various signs of degenerative changes of its structures involving all layers, including irregularities and resorption of the fibrous layer (F) leading to irregular condylar outline, proliferative layer (P) and cartilaginous layer (C). The cartilaginous layer was absent in some areas, and decreased number of bone trabeculae (B) was seen obviously.



###### Group 2 (3 mm per day)

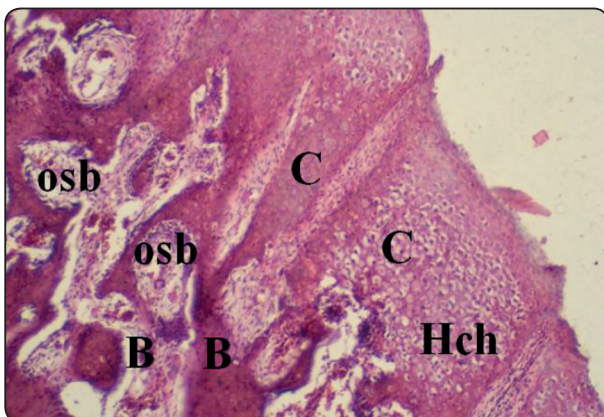
The condylar head showed various signs of atrophy and resorption involving the articulating cartilage. The condylar layers were decreased in their thickness showing generation with irregular fibrous outline, bone trabeculae were decreased in number exhibiting reversal (RL) and scalloped outline indicating osteoclasts (OC) activities and obvious bone resorption, proliferative zone was absent in some areas.



##### After the second post distraction week

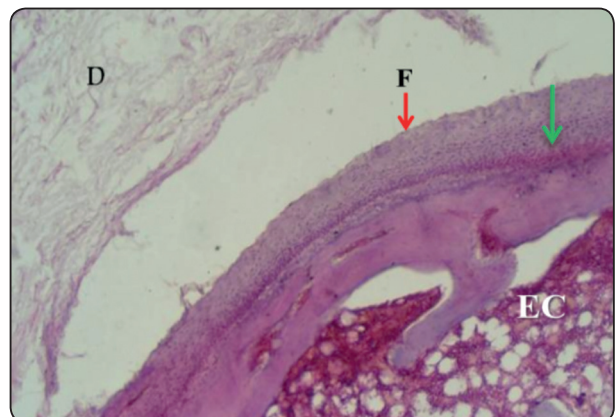
###### Group 1 (1 mm per day)

The condylar head showed evidence of regeneration in the fibrous layer nearly regular outline, with pronounced proliferative and cartilaginous layers. Endochondral ossification was enhanced and new bone trabeculae are present.



###### Group 2 (3 mm per day)

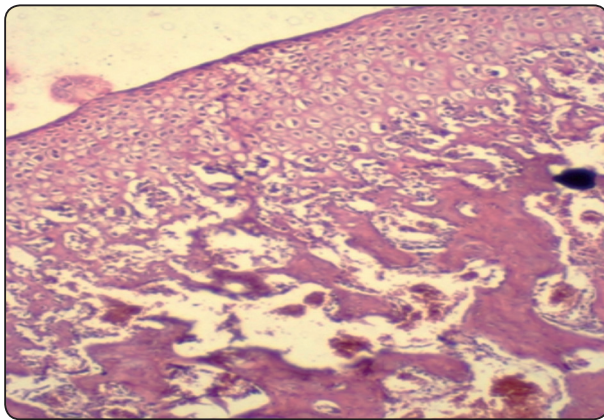
Head of the condyle showed regeneration of all layers including the disc (D), and bone hypertrophy was seen in some areas specially in proliferative zone with regular fibrous outline seen in most areas (F). endochondral ossification and large bone trabeculae are present (EC).



**After the fourth post-distraction week**

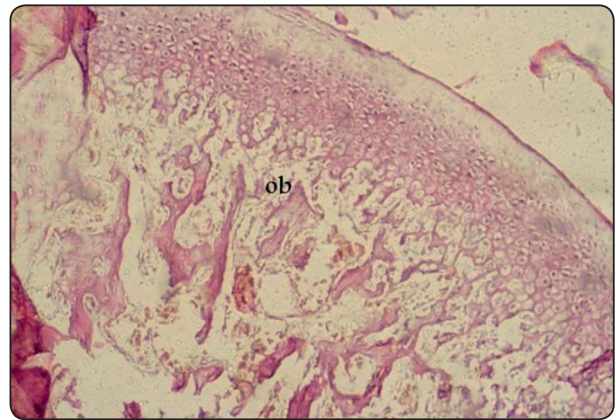
**Group 1 (1 mm per day)**

The condyle showed regeneration in all layers appearing nearly normal and nearly returned to its pre-distraction thickness.



**Group 2 (3 mm per day)**

Head of the condyle showed regeneration of all layers (fibrous, proliferative and cartilagenous) together with bone trabeculae. Osteoblastic activity was observed. The arrangement of bone trabeculae were about to be normally in appearance.

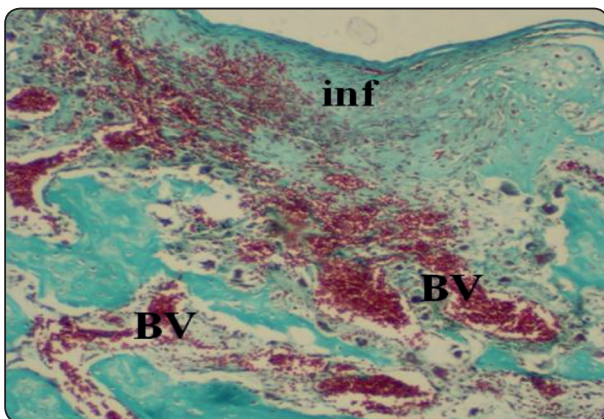


**B- Trichrome stain**

**After the first post distraction week**

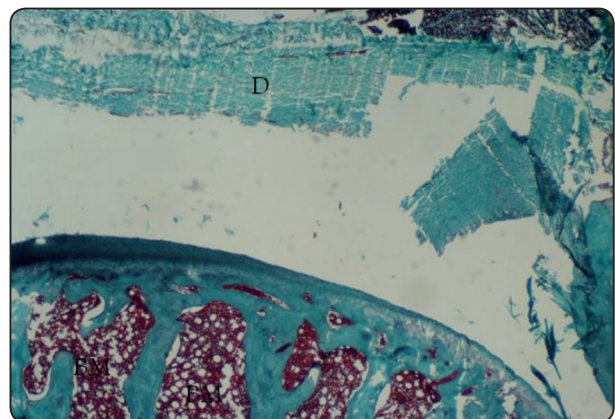
**Group 1 (1 mm per day)**

The condylar head showed degeneration in the fibrous layer, obvious resorption of proliferative layer and cartilaginous layer, the areas of degeneration and resorption were invaded by large number of inflammatory cells, with increased vascularity.



**Group 2 (3 mm per day)**

The condylar head showed resorption and atrophy of all layers including the disc with irregular fibrous outline.

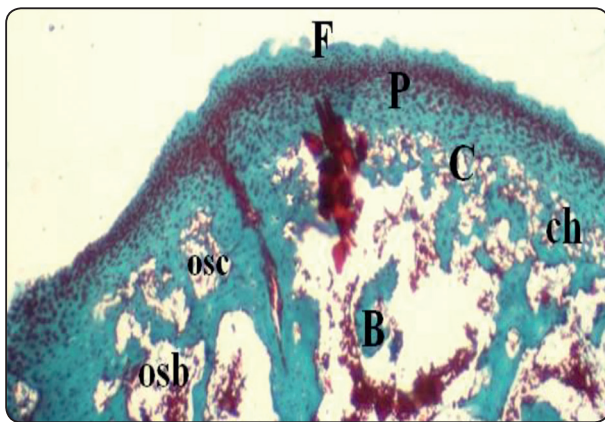




**After the second post distraction week**

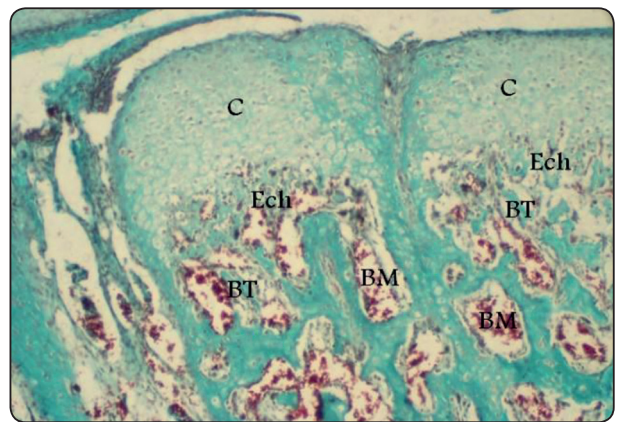
**Group 1 (1 mm per day)**

The condylar head showed irregular fibrous (F) outline in some areas with regeneration of the fibrous layer and proliferative layer (F). Hypertrophy of chondroblasts in the cartilaginous (C) layer was evident with marked endochondral ossification. New bone trabeculae (B) were developed with numerous osteoblasts traced on its surface. Reversal lines and osteoclasts were seen on bone surface in some areas.



**Group 2 (3 mm per day)**

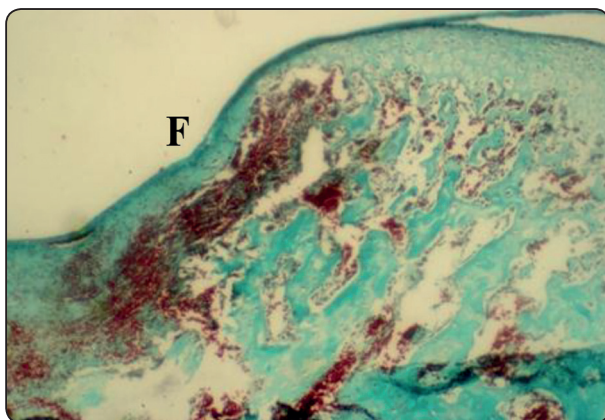
Head of the condyle showed evidence of regeneration of all layers together with bone formation, hypertrophy was seen in some areas specially in fibrous and proliferative zone. Cartilage formation (C), Bone trabeculae (BT).



**After the fourth post-distraction week**

**Group 1 (1 mm per day)**

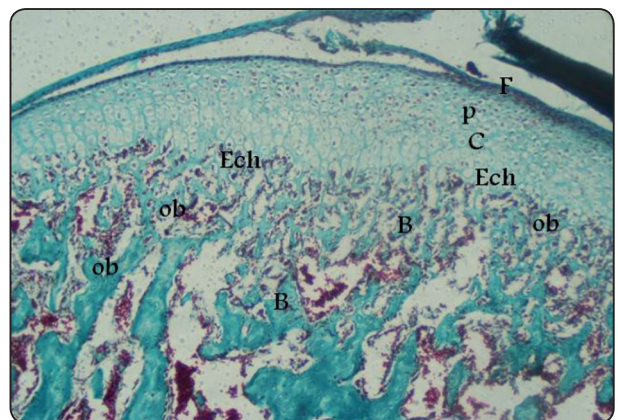
The condylar head appeared with regular outline (F). All of its layers were about to be reformed and undergoing regeneration still numerous small bone trabeculae are present.



**Group 2 (3 mm per day)**

Head of the condyle showed regeneration of all layers including disc fibers which appeared normally, endochondral ossification was enhanced and the subchondral area started to be refilled with new bone trabeculae with numerous osteoblasts traced on bone surface.

ECH: endochondral, F: fibrous layer, P: proliferative zone, B: Bone, Ob: Osteoblast



## DISCUSSION

Mandibular distraction produced unusual forces by distraction procedures and stretched masticatory muscles<sup>(8,9)</sup>.

The histological results of the present study in both groups 1 and 2 showed that in the first post-distraction week, the condylar head showed various signs of degenerative changes of its structures involving all layers, including irregularities and resorption of the fibrous layer leading to irregular condylar outline, proliferative layer. The cartilaginous layer are absent in some areas, the areas of degeneration and resorption were invaded by large number of inflammatory cells, with increased vascularity. There was decrease in bone trabeculae.

In our study, the results were in agreement with experimental data from investigations in rabbits and sheeps which have shown changes in TMJ condylar morphology and anteroposterior dimension, surface contour irregularities and the diameter of the articular cartilage was reduced in the main pressure zone<sup>(8,10)</sup>.

These results were also supported by previous studies that reported degenerative changes in the TMJ as a result of mandibular distraction, including reduction of cartilage thickness, and irregularities of articular surface contour<sup>(11-13)</sup>.

Mandibular distraction in another previous studies in a rate model revealed decreased density, and altered orientation of the condyle<sup>(14,15)</sup>. A reduction in condylar size, due to an erosive process, has also been reported by Hatcher et al (1997)<sup>(16)</sup>.

The results of our study are in contrast to other authors reports that the thickness of cartilage tissue increased in regions under elevated pressure<sup>(17)</sup>. Hyperplasia of cartilage in regions under elevated pressure has been reported in a variety of other experimental studies<sup>(18-20)</sup>. Luz et al (1991)<sup>(18)</sup> showed that indirect trauma to the rate TMJ caused thickening of the articular surface.

The degenerative changes after the second week were partially reduced by remodeling, the condylar head showed regular fibrous outline in some areas with regeneration of the fibrous layer and proliferative layer. After the fourth week, the condylar head appearing nearly normal. All of its layers were about to be reformed and regenerated to its normal histological structure appearance. The arrangement of bone trabeculae were about to be normally in appearance, that was showed in group 2 (3 mm per day) more than in group 1 (1 mm per day).

The results of this study were parallel to the results of pervious experimental study performed by Zhou et al (2005)<sup>(21)</sup> on dogs to investigate the effect of bilateral mandibular distraction osteogenesis at a rate of 1 mm per day on the condyles. They found various degrees of irregularities and erosion in fibrocartilage of the condyle and damage in fibrous layer, but the changes were reversible.

The results of this study were parallel to the results Elgazzar et al (2008)<sup>(22)</sup> who evaluated the distraction osteogenesis of the mandibular body and its effect on the condylar cartilage in rabbits using 3 mm of distraction per day, and concluded that there was degenerative stage followed by remodeling or regenerative stage.

The distraction rate is a critical factor in the determination of a desirable outcome<sup>(23-28)</sup>. In this study, there was no difference between group 1 (1 mm per day) and group 2 (3 mm per day) after the first and second post-distraction weeks. After the fourth week there were collagen formation, the arrangement of bone trabeculae were about to be normally in appearance and the regeneration to its normal histological structural appearance that evidences were noticed more in group 2 (3 mm per day) than in group 1 (1 mm per day).

## CONCLUSIONS

Distraction at rates of 1 mm per day and 3 mm per day causing degenerative changes in the TMJ condylar cartilage and articular disc in the first post-distraction week. However, most of the rabbits showed adaptive and remodeling signs in the following second and fourth weeks which reflect the adaptive capacity of the condylar cartilage and disc. The regeneration to the normal histological structural appearance was showed in group 2 (3 mm per day). The distraction at rate of 3 mm per day was considered to be preferable than at rate of 1 mm per day due to the short time required for bone distraction and consolidation. Reducing the overall treatment time would alleviate patients discomfort during the distraction processes.

## REFERENCES

- Papageorge MB, Charalabos A. Simultaneous mandibular distraction and arthroplasty in patients with temporomandibular distraction and arthroplasty in patients with temporomandibular joint ankylosis and mandibular hypoplasia. *J Oral Maxillofac Surg.* 1999;57:328.
- McCarthy JG. The role of distraction osteogenesis in the reconstruction of the mandible in unilateral craniofacial microsomia. *Clin Tech Plast Surg.* 1994;21:625-31.
- Sadakah AA, Elgazzar RF, Abdelhady AL. Intraoral distraction osteogenesis for the correction of facial deformities following temporomandibular joint ankylosis: a modified technique. *Int J Oral Maxillofac Surg.* 2006;35:399-406.
- Stelnicki EJ, Stucki-McCormick SU, Rowe N, McCarthy JG. Remodeling of the temporomandibular joint following mandibular distraction osteogenesis in the transverse dimension. *Plast Reconstr Surg.* 2001;107:647-58.
- Salo LA, Hoyland J, Ayad S, Kieley CM, Freemont A, Pirttiniemi P, et al. The expression of types X and VI collagen and fibrillin in rat mandibular condylar cartilage. Response to mastication forces. *Acta Odontol Scand.* 1996;54:295-302.
- Flygare L, Rohlin M, Akerman S. Macroscopic and microscopic findings of areas with radiologic erosions in human temporomandibular joints. *Acta Odontol Scand.* 1992;50:91.
- Copray JC, Dibbets JM, Kantoma T. The role of condylar cartilage in the development of the temporomandibular joint. *Angle Orthod.* 1988;58:369-80.
- Karaharju-Suvanto T, Peltonen J, Laitinen O, Kahri A. The effect of gradual distraction of the mandible on the sheep temporomandibular joint. *Int J Oral Maxillofac Surg.* 1996;25:152-6.
- Nakamura E, Mizuta H, Takagi K. Knee cartilage injury after tibial lengthening. Radiographic and histological studies in rabbits after 3 – 6 months. *Acta Orthop Scand.* 1996;66:306-13.
- Meyer U, Wiesmann Hp, Kruse-Lösler B, Handschel J, Stratmann U, Joos U. Strain-related bone remodeling in distraction osteogenesis of the mandible. *Plast Reconstr Surg.* 1999;103:800-7.
- McCormick SU, McCarthy JG, Grayson BH, Staffenberg D, McCormick SA. Effect of mandibular distraction on the temporomandibular joint: Part 1, Canine study. *J Craniofac Surg.* 1995;6:358-63.
- McCormick SU1, Grayson BH, McCarthy JG, Staffenberg D. Effect of mandibular distraction on the temporomandibular joint: Part 2, clinical study. *J Craniofac Surg.* 1995;6:364-7.
- Thurmuller P, Troulis MJ, Rosenberg A, Kaban LB. Changes in the condyle and disc in response to distraction osteogenesis of the minipig mandible. *J Oral Maxillofac Surg.* 2002;60:1327-33.
- Liu ZJ, King GJ, Herring SW. Alterations of morphology and microdensity in the condyle after mandible osteodistraction in the rat. *J Oral Maxillofac Surg.* 2003;61:918-27.
- Liu ZJ, King GJ, Hering SW. Why do we fail to achieve predicted lengthening in mandibular osteodistraction? Observations on condylar morphology and microdensity in growing and maturing rats. In: Davidovitch Z, Mah J, (eds). *Biological mechanisms of tooth movement and craniofacial adaption.* Bangkok: Harvard Soc. Adv. Orthodontics; 2004. P.P. 39-52.
- Hatcher DC, McEvoy AP, Mah RT, Faulkner MG. Distribution of local and general stress in the stomatognathic system. In: McNeill C (ed). *Science and practice of occlusion.* Chicago, IL: Quintessency; 1997. P. 259.
- McNamara JA, Hinton RJ, Hoffman DL. Histologic analysis of temporomandibular joint adaptations to protrusive function in young adult rhesus monkeys (*Macaca mulatta*). *Am J Orthod.* 1982;82:288-98.



18. Luz JG, Jaeger RG, de Araújo VC, de Rezende JR. the effect of indirect trauma on the rat temporomandibular joint. *Int J Oral Maxillofac Surg.* 1991;20:48-52.
19. Kiviranta I, Jurvelin J, Tammi M, Säämänen AM, Helminen HJ. Weight bearing controls glycosaminoglycan concentration and articular cartilage thickness in the knee joints of young beagle dogs. *Arthritis Rheum.* 1987; 30:801-9.
20. Ali Am, Sharawy MM. Enlargement of the rabbit mandibular condyle after experimental induction of anterior disc displacement: A histomorphometric study. *J Oral Maxillofac Surg.* 1995;53:544.
21. Zhou N, Song SH, Mai HM, Kiang FX, Wei SL, Yang YP. The effect of dog bilateral distraction osteogenesis in temporomandibular joint. *Hua Xi Kou Qiang Yi Xue Za Zhi.* 2005;23:72-4.
22. Elgazzar RF, EL-Bialy TH, Megahed E. Effect of bilateral mandibular osteodistraction on the condylar cartilage: An experimental study on rabbits. *Open Dent J.* 2008;2:103-8.
23. Troulis MJ, Perrott DH, Kaban LB. Endoscopic mandibular osteotomy, and placement and activation of a semiburied distractor. *J Oral Maxillofac Surg.* 1999;57:1110-3.
24. Alruhaumi KA. Comparison of different distraction rates in the mandible: an experimental investigation. *Int J Oral Maxillofac Surg.* 2001;30:220-7.
25. Liu ZJ, King GJ, Herring SW. Condylar mineralization following mandibular distraction in rats. *J Dent Res.* 2006;85:653-7.
26. Daif ET, Hasan SAH. Effect of distraction osteogenesis on condylar position in patients with unilateral mandibular deficiency. *Cairo Dent J* 2003;19:19-23.
27. Keestra JAJ, Barry O, de Jong L, Wahl G. Long-term effects of vertical bone augmentation: A systematic review. *J Appl Oral Sci* 2016;24:3-17.
28. Kim JW, Cho MH, Kim SJ, Kim MR. Alveolar distraction osteogenesis versus autogenous onlay bone graft for vertical augmentation of severely atrophied alveolar ridges after 12 years of long-term follow-up. *Oral Surg Oral Med Oral Pathol Oral Radiol.* 2013;116:540.