

Bacteriological and pathological studies on avian *Mannheimia hemolytica* and *Pasteurella multocida* in Beni-Suef Governorate

Samia I. Afifi¹, E. A. Mahdy², K. A. El-Nesr²

¹ *Animal Health Research Institute, Beni-Suef Branch and* ² *Department of Pathology Faculty of Veterinary Medicine, Beni-Suef University, Beni-Suef 62511, Egypt.*

Avian *Mannheimia hemolytica* and *Pasteurella multocida* were investigated in different poultry farms at Beni-Suef governorate. Bacteriological examination of 160 samples which were taken from organs of freshly dead and diseased chickens revealed isolation of 50 (31.25%) isolates of *Pasteurella*. Spp., 16 (10%) isolates were *Mannheimia hemolytica* and 34(21.25%) isolates were *Pasteurella multocida*. Experimental infection was carried out on four weeks old Balady chickens which were inoculated with isolates of *Mannheimia hemolytica* and *Pasteurella multocida* separately, mortality rate in both reached to 80%. Samples were taken from dead chickens and examined bacteriologically and histopathologically and *Pasteurella*. Spp. were reisolated from experimentally infected chickens. Antibiogram study with 10 types of chemotherapeutic agents revealed that both microorganisms were sensitive to ceftiofor, gentamycin and lincomycin + spectinomycin. The gross and microscopic pathologic lesions were variable in type and severity in field and experimentally infected cases. There was general hyperemia which most evident in veins of the abdominal viscera. Petechial haemorrhages were frequently found and widely distributed. Livers of the most acutely affected birds were swollen and had multiple small focal areas of coagulative necrosis and heterophilic infiltration. Heterophilic infiltration also occurs in lungs and certain other parenchymatous organs.

Gallibacterium was recently established as a new genus including organisms previously reported as *Pasteurella anatis*, *Actinobacillus salpingitis* and avian *Pasteurella hemolytica*-like organisms (*Mannheimia hemolytica*), (Bojesen *et al.*, 2007). The new genus Gallibacterium was separated from other genera of family Pasteurellaceae according to differences in phenotypic characterization, (Bojesen *et al.*, 2003a; Christensen *et al.*, 2003). Bojesen *et al.*, (2003b) stated that hemolytic Gallibacterium was highly prevalent in birds from production systems with moderate or low level of biosecurity, Christensen *et al.*, (2003) recoded that avian *Mannheimia hemolytica* caused salpingitis and peritonitis in layer chickens and Bojesen *et al.*, (2007) isolated 75 Gallibacterium field isolates from Mexican chicken egg layers. On the other hand *P. multocida*, the main causative organism of fowl cholera, a highly contagious disease that affects 100 wild avian species (Botzler 1991). Nakamura *et al.*, (1997) isolated *Pasteurella* Spp. from an outbreak of comb necrosis in layer breeder chickens, Sarkozy *et al.*, (2002) succeeded in inducing experimental fowl cholera in 60 healthy 10 weeks old broiler chickens and Woo and Kim

(2006) isolated *P. multocida* from two outbreaks of fowl cholera in Korea .

The clinical signs of *Mannheimia hemolytica* were including pneumonia Mwangota *et al.*, (1978), sinusitis, nasal discharge and drop in egg production Lin *et al.*, (2001), and in case of *P. multocida* it were comb necrosis and lameness Nakamura *et al.*, (1997), orofacial edema, swollen and edematous wattles and combs, and severe respiratory disorders in infected chickens Woo and Kim (2006).

Regarding to necropsy findings due to *Mannheimia hemolytica* the main lesions were nodular necrosis of the liver Addo and Mohan (1985) peritonitis, Bojesen *et al.*, (2004a) and in case of *P. multocida* were hyperemia of the trachea, edema of the lungs, increase of pleural fluid and petechial hemorrhages in liver, heart and duodenum, minute necrotic foci in the liver and bacterial clumps in the foci Takaya *et al.*, (1981). Liquefactive necrosis of epidermal epithelial cells with hyperplasia, vesicle formation in epidermis, congestion and hemorrhage with fibrinous thrombi in blood vessels of underlying dermis in comb were noted, Nakamura *et al.*, (1997).

The present work was aimed to isolate

Mannheimia hemolytica and *P. multocida* from poultry farms with a history of diarrhoea and respiratory disorders, and to study the difference in biological properties between the two microorganisms, moreover reporting the clinical signs and the pathological affections and the in vitro sensitivity of the isolated isolates to different chemotherapeutic agents

Materials and methods

Samples. A total number of 160 freshly dead and diseased chickens 2–8 weeks old showing diarrhoea, respiratory disorders and mortality rate reached to 20% were collected from different private farms at Beni-Suef Governorate. The birds were submitted to bacteriological and pathological examinations.

Isolation and identification. Isolation and identification of *Pasteurella* Spp. was carried out according to (Cruick-Shank *et al.*, 1975; Collee *et al.*, 1996; Christensen *et al.*, 2003).

The internal organs of examined birds (liver, heart, spleen, lungs and trachea as well as nasal and eye discharges) were inoculated into broth media and incubated for 18–24 h then streaked into solid media, dextrose starch agar, blood agar, MacConkeys agar and incubated at 37°C for 24 h, they were examined for hemolytic or non hemolytic activity. Differentiation of suspected colonies were done through colonial morphology hemolysis, staining reaction, cellular morphology, biochemical reactions specially carbohydrate fermentation, indol production, motility, catalase and oxidase tests.

Experimental infection.

In chickens. Thirty apparently healthy Balady chickens 4 weeks old were used, it was proved that they were free from both *Mannheimia hemolytica* and *P. multocida* through cultural and serological examination, the chickens were divided into 3 groups: group one, ten birds, was used for testing the pathogenicity of *Mannheimia hemolytica*, group two, ten birds, was used for testing the pathogenicity of *P. multocida* which was isolated from naturally infected chickens and group three, ten birds, was kept in parallel as uninfected controls. Group one and group two will be inoculated separately intravenous with 0.1 ml of overnight broth containing 3.3×10^7 colony forming units of *Mannheimia hemolytica* or *P. multocida* according to Lin *et al.*, (2001).

The mortality rate was determined in each group and dead birds were submitted for bacteriological and pathological examinations.

Infection of mice. Fifteen Swiss albino mice 15–20 g were divided into three groups: group one, five mice, was used for determination of the lethal activity of some isolates of *Mannheimia hemolytica*, group two, five mice, was used for determination of the lethal activity of some isolates of *P. multocida* and group three, five mice, was used as control, the mice were kept under observation for 2 weeks before they were inoculated. Groups one and two were injected subcutaneously with 0.2ml of 10^6 C.F.U of *Mannheimia hemolytica* or *P. multocida* obtained from diseased birds separately. Mice died within 24–48 h after injections were subjected to postmortem examination and reisolation of *Pasteurella* Spp. was carried out from infected mice Cruick-Shank *et al.*, (1975).

Antibiogram of the isolated Pasteurella Spp.

The sensitivity of the isolated *Pasteurella* Spp. to different antibacterial agents was done by disc diffusion method using dextrose starch agar medium according to Cruick-Shank *et al.*, (1975) the following discs were used, ceftiofur (30 mg), chloramphenicol (30 mg), lincomycin (15mg), and spectinomycin (200mg), amoxicillin (25mg), norfloxacin (10mg), neomycin (30mg), colistin sulphate (10mg), gentamycin (30mg), streptomycin (10 mg) and doxycyclin (30 mg).

Histopathology. Tissue specimens were taken from liver, heart, spleen, intestine, brain and lungs of diseased and experimentally infected chickens and fixed in 10% neutral buffered formalin and processed routinely for paraffin embedding techniques. Embedded tissues were sectioned at 4–6 μ m and stained with hematoxylin and eosin stain according to Bancroft and Stevens (1996).

Results

Clinical examination. Diseased chickens showed anorexia, depression, ruffled feathers, bilateral or unilateral inflammation of eye and diarrhoea.

Necropsy findings were represented by congestion of the carcasses, necrotic foci and multiple petechiae on liver and spleen, congestion and edema of the lungs and hemorrhages all over the intestine.

Bacterial examination. Out of 160 samples of chickens 50 isolates of *Pasteurella* Spp. were isolated (31.25%) 16 isolates were *Mannheimia hemolytica* and 34 isolates were *P. multocida*. (Table 1)

Regarding the biological properties of isolates of *Mannheimia hemolytica*, they were Gram-negative, non-motile, rod-shaped or

Table (1): Incidence of both *Mannheimia hemolytica* and *P. multocida*.

Number of Samples	Positive Samples		<i>Mannheimia hemolytica</i>		<i>P. multocida</i>	
	No.	%	No.	%	No.	%
160	50	31.25	16	10	34	21.25

Table (2): The in vitro sensitivity of the isolates of *Mannheimia hemolytica* and *P. multocida* to different chemotherapeutic agents.

Chemotherapeutic agents	<i>Mannheimia hemolytica</i> (16)			<i>P. multocida</i> (34)		
	Resistant	Sensitive		Resistant	Sensitive	
		No.	%		No.	%
Ceftiofur	0	16	100	0	34	100
Lincomycin+spectinomycin	4	12	75	9	25	73.53
Norfloxacin	11	5	31.25	24	10	29.41
Chloramphenical	12	4	25	31	3	8.82
Amoxicillin	16	0	0	34	0	0
Neomycin	16	0	0	34	0	0
Colistin Sulphate	14	2	12.5	29	5	14.7
Gentamycin	3	13	81.2	4	30	88.23
Streptomycin	14	2	12.5	34	0	0
Doxyeyclin	11	5	31.25	31	3	8.82

pleomorphic with cells occurring singly and in pairs, colonies on – bovine blood agar are mostly strongly B–hemolytic, urease, ornithine decarboxylase and Indole negative, oxidase and catalase positive ferment mannose, maltose, glucose, mannitol, galactose and grow on Macconcky agar, *P. multocida* isolates were Indol, catalase and oxidase positive non hemolytic and ferment mannose, glucose, galactose and mannitol, all injected mice died within 48h and showed typical lesions of *Pasteurella* Spp. In case of experimentally infected chickens the clinical signs appeared 24 to 72 h post injection, they were off food, lacrimation, fever and emaciation, the mortality rates in both reached to 80 % , the post mortem examination showed congestion of lung, liver and spleen, minute necrotic foci on the liver surface and enteritis. The microorganisms were reisolated from organs of infected birds, survived birds were able to overcome the infection, and control birds were negative for bacteriological examination.

The in vitro sensitivity of the isolated isolates of *Mannheimia hemolytica* and *P. multocida* to different chemotherapeutic agents were indicated in (Table 2).

Pathological examination.

Gross lesions. The gross lesions were variable and appeared to be more severe in field cases. The gross and microscopic lesions induced by *Mannheimia hemolytica* and those induced by *Pasteurella multocida* were similar. There was general hyperemia and was most evident in the blood vessels of the abdominal viscera.

Subepicardial and subserosal hemorrhages and also hemorrhages in the lung, abdominal fat and intestinal mucosa were found. The liver of some acutely affected birds was swollen and showed pale necrotic foci.

Microscopic examination. The blood smears, of the experimentally infected birds, stained with Leishman's stain, showed the bipolarity of the microorganisms (Fig.1).

Liver. The examined livers of both field and experimentally infected cases showed multifocal heterophilic infiltrations (Fig. 2) associated with coagulative necrosis in most cases. In subacute cases, the infiltrating neutrophils decreased in number with increased number of the infiltrating mononuclear cells (Fig. 3).

Intestine. In many cases, the intestinal lumens were filled with inflammatory exudate and the submucosa showed heterophilic infiltrations (Fig. 5).

Lungs. The lungs of the affected birds showed heterophilic infiltration of the alveolar walls, peribronchiolar, and intraluminally in the bronchioles (Fig. 7). The lesions in subacute cases, showed mononuclear cell infiltration with giant cell formation (Fig. 8).

Heart. In few cases, there were hemorrhages (Fig. 10) and heterophilic infiltration (Fig. 11) in the myocardial interstitium.

Spleen. The spleens of a few cases showed focal heterophilic infiltrations (Fig. 13) within the splenic parenchyma.

Brain. Microscopically, the examined brains showed no detectable lesions.

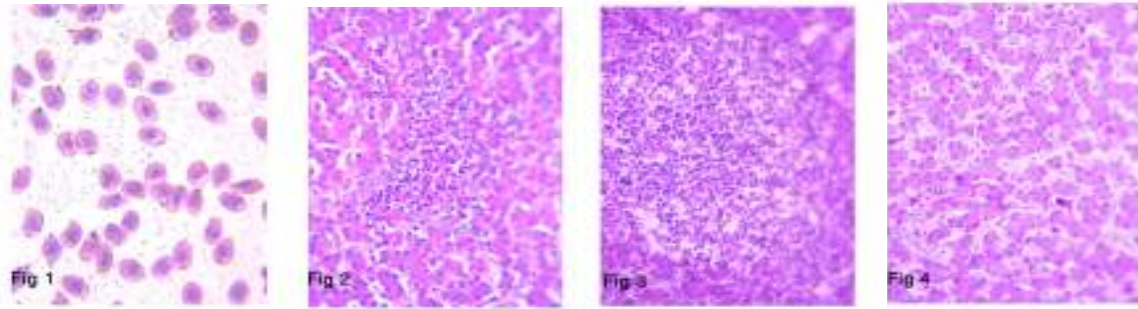


Fig.1:Avian pasteurellosis. Blood smear (notice the bipolarity) Leishman's stain (X1000)

Fig.2:Acute avian pasteurellosis. Heterophilic infiltration in chicken liver (H&E X400)

Fig.3: Subacute avian pasteurellosis. Focal mononuclear cell infiltration (H&E X400)

Fig.4:Chicken liver. Normal histological structure. (H&E X400)

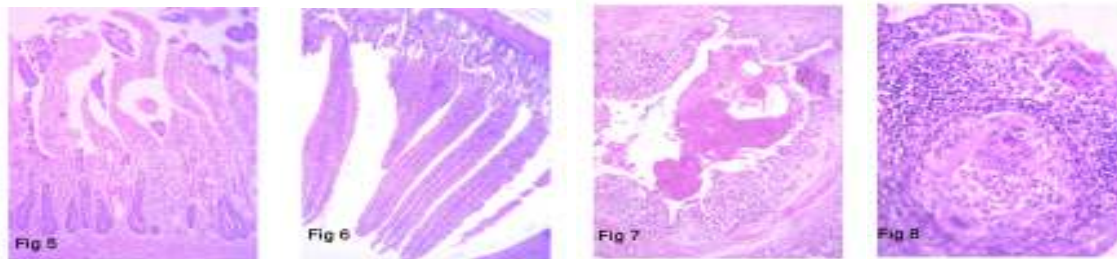


Fig.5: Intestine. Submucosal neutrophilic infiltration. The lumen is filled with inflammatory exudates (H&E X100)

Fig.6: Intestine. Normal histological structure of intestinal villi and crypts (H&E X100)

Fig.7: Lung. The bronchiolar lumen is filled with inflammatory exudates (H&E X100)

Fig.8: Lung. Chronic inflammatory reaction with giant cell formation (H&EX400)

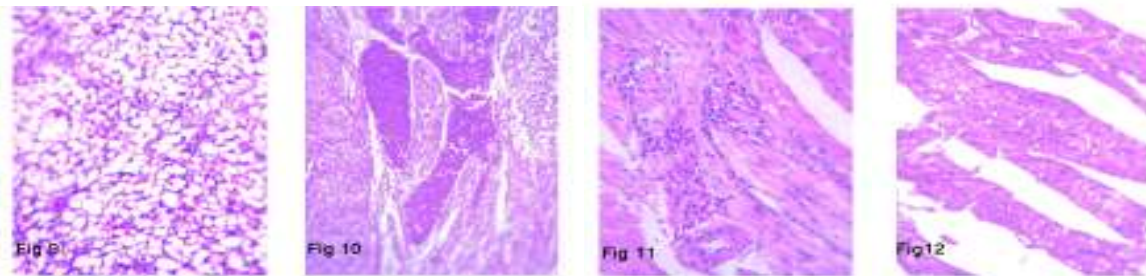


Fig.9: Control lung showed normal pulmonary tissue (H&E X400).

Fig.10: Heart. The myocardial blood vessels showed congestion and hemorrhages (H&E 200)

Fig.11: Heart. Focal heterophilic infiltrations were in between the myocardial fiber (H&E X400)

Fig.12: Heart. Normal branched and striated myocardial fiber (H7E X400)

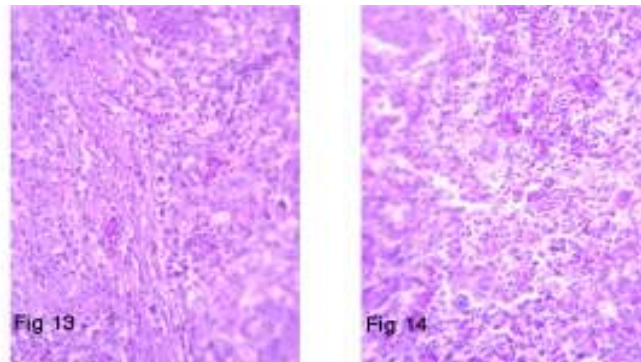


Fig.13: Spleen. Focal heterophilic infiltrations of the splenic parenchyma (H&E X400)

Fig.14: Spleen. Normal histological structure (H&E X400)

Discussion

Avian *Mannheimia hemolytica* were classified as a new genus within the family Pasteurellaceae on the basis of unique phenotypic characteristics, they mostly associated with respiratory diseases or septicemia (Christensen *et al.*, 2004; Bojesen *et al.*, 2007).

In the present study, 16 (10%) isolates of *Mannheimia hemolytica* were isolated from birds showing signs of respiratory affections and mortality rate reached to (20%) this nearly resembling the results recorded by Lin *et al.*, (1993), who recorded (30%) mortality due to *Mannheimia hemolytica* infection and differ from Show *et al.*, (1990) who recorded higher incidence and increased mortality. In case of *P. multocida* which revealed from diseased birds with higher percentages (21.25 %) this agreed with Woo and Kim (2006) who recorded 2 outbreaks of fowl cholera due to *P. multocida* in Korea.

The morphology and biochemical characters of *Mannheimia hemolytica* and *P. multocida* were somewhat differed from each others, the organisms were Gram negative, bipolar rods or coccobacilli, *Mannheimia hemolytica* were hemolytic, oxidase and catalase positive, indol negative ferment mannose, maltose, mannitol, glucose and galactose, grow well on MacConkey agar, these results agreed with Addo and Mohan (1985); Angen *et al.*, (1999); Christensen *et al.*, (2003); Blackall *et al.*, (2005). *P. multocida* differ from *Mannheimia hemolytica* in that it was non hemolytic on blood agar medium didn't grow on Macconcky agar, and indol positive results agreed with Karaivanov (1984); Collee *et al.*, (1996). Experimental infection of chickens with both of *Mannheimia hemolytica* and *P. multocida* caused morbidity and mortality reached to 80% in both cases this resembling the results recorded by Curtis and Allerhead (1981); Lin *et al.*, (2001); Bojesen *et al.*, (2004a).

The survived birds didn't harbor the infection and this agreed with Woo and Kim (2006); Byarugaba *et al.*, (2007) and disagreed with Karaivanov (1984) who studied 73 isolates of *P. multocida* 48 from acute cases of fowl cholera and 25 isolates of chronic fowl cholera. All mice dead within 48h post infection and this achieved the results recorded by Yancey *et al.*, (1987); Harper *et al.*, (2003); Chung *et al.*, (2005).

Antibiogram study with 10 types of chemotherapeutic agents revealed that both

Mannheimia hemolytica and *P. multocida* were 100% sensitive to ceftiofur, from 81– 88% were sensitive to gentamycin, 73-75% were sensitive to lincomycin + spectinomycin, from 29% to 31% were sensitive to norfloxacin and some isolates of *Mannheimia hemolytica* were sensitive to chloramphenicol and doxycycline while most isolates were resistant to colistin sulphate and streptomycin and all isolates were resistant to Amoxicillin and streptomycin this somewhat differ from Semjen *et al.*, (1981) and Sarkozy *et al.*, (2002) who showed that doxycycline and norfloxacin respectively were highly effective against *P. multocida* and agreed with Yancey *et al.*, (1987) who recorded that *P. multocida* and *Mannheimia hemolytica* from chickens were highly sensitive to ceftiofur and Lin *et al.*, (2001) who showed that both *Mannheimia hemolytica* and *P. multocida* were sensitive to ceftiofur, amoxicillin, lincomycin and spectinomycin, moderately sensitive to tetracycline, enrofloxacin and slightly sensitive to chloramphenicol.

The pathogenicity or virulence of *P. multocida* in relation to fowl cholera is complex and variable, depending on the strain, host species, and variation within the strain or host and conditions of contact between the two. The ability of *P. multocida* to invade and reproduce in the host is enhanced by the presence of a capsule that surrounds the the organism (Saif *et al.*, 2003).

Endotoxins are produced by all *P. multocida* isolates, both virulent and non virulent. They may contribute to virulence; however invasion and multiplication of a strain are necessary for the production of sufficient quantities of endotoxins in vivo to contribute the pathological processes (Saif *et al.*, 2003).

The gross lesions and clinical signs including septicemia, respiratory disorders and diarrhoea resembling the signs which were recorded by Mwangota *et al.*, (1978); Nakamara *et al.*, (1997); Lin *et al.*, (2001); Bojesen *et al.*, (2004 b); Woo and Kim (2006).

Regarding to necropsy findings due to *Mannheimia hemolytica* the main lesions were nodular necrosis of the liver Addo and Mohan (1985) peritonitis, Bojesen *et al.*, (2004a) and in case of *P. multocida* were hyperemia of the trachea, edema of the lungs, increase of pleural fluid and petechial hemorrhages in liver, heart and duodenum, minute necrotic foci in the liver and bacterial clumps in the foci Takaya *et al.*, (1981). Liquefactive necrosis of epidermal

epithelial cells with hyperplasia, vesicle formation in epidermis, congestion and hemorrhage with fibrinous thrombi of underlying dermis in comb were noted, Nakamura *et al.*, (1997). The gross and microscopic pathology caused by an atypical strain of *Pasteurella gallinarum* (Frenso strain) was compared in chickens with that caused by the American Type Culture Collection type strain. Microscopically, there was severe chronic pyogranulomatous airsacculitis, pericarditis, perihepatitis, myositis, synovitis, and granulomatous pneumonia. One bird had severe acute multifocal hepatitis Shivaprasad and Droual, (2002).

In our material, the gross and microscopic lesions induced by *Mannheimia hemolytica* and those induced by *Pasteurella multocida* were similar. There was general hyperemia and was most evident in the blood vessels of the abdominal viscera. Subepicardial and subserosal hemorrhages and also hemorrhages in the lung, abdominal fat and intestinal mucosa were found. The liver of some acutely affected birds was swollen and showed pale necrotic foci. Microscopically, there were heterophilic infiltrations involving most of the parenchymatous organs. Stress factors (e.g. massive population)

Play an important role in aggravated and increased severity of the pathological lesions in case of field cases in comparison with those in case of experimentally infected birds.

Recruitment of heterophils into the respiratory tract during infection was found to contribute considerably to the lung lesions in chickens and was found to mediate tissue damage, possibly allowing a more rapid systemic spread of *P. multocida*. However, during progression of the infection, the heterophil mediated-necrosis in chickens seemed to stimulate giant cell demarcation of infected lung tissue, which coincided with the clearance of *P. multocida* from the spleen, thus harpering further invasion. Consequently, heterophil activation plays a dual role for the outcome of *P. multocida* infection in chickens, where it initially seems to promote invasion and systemic spread but subsequently helps in limit the infection by giant cell formation and bacterial clearance Bojesen *et al.*, (2004b).

Chronic localized infections can involve the middle ear and cranial bones and have been reported to result in torticollis in turkeys. Heterophilic infiltration and fibrin were observed

in the air spaces, middle ear, and meninges. Multinucleated giant cells were often associated with necrotic masses of heterophils in air spaces Saif *et al.*, (2003). In conclusion, bacteriological examination of 160 samples of freshly dead and diseased chickens suffering from respiratory disorders and diarrhea obtained from private farms at Beni Suef Governorate revealed isolation of 16(10%) isolates of *Mannheimia hemolytica* and 34(21.25%) isolates of *P. multocida*. Experimental infection with isolated isolates of both microorganisms separately in 4 weeks old chickens produced the same characteristics lesions of *Mannheimia hemolytica* and *P. multocida* within 3 days post infection. The in vitro sensitivity tests have shown that both *Mannheimia hemolytica* and *P. multocida* were highly sensitive to ceftiofur, gentamycin and lincomycin and spectinomycin. The present study has cleared the occurrence of *Mannheimia hemolytica* and *P. multocida* in poultry farms in Beni Suef Governorate and their sensitivity for some chemotherapeutic agents.

References

- Addo P. B. and Mohan K. (1985):** A typical *P. hemolytica* type A from Poultry. *Avian Dis.* 29 (1): 214 – 217
- Angen-O.; Mutters R.; Cougant D. A.; Olsen J. E. and Bisgaard M. (1999):** Taxonomic relationships of the *P. hemolytica* complex as evaluated by DNA – DNA hybridization and 16S rRNA sequencing with proposal of *Mannheimia hemolytica* gen. nov., comb. nov., *Mannheimia granulomatis* comb. nov., *Mannheimia glucosida* SP. nov., *Mannheimia ruminalis* – SP. nov. and *Mannheimia varigena* SP. nov., *Int. Sys. Bac. Jan;* 49 Ptl: 67 – 86.
- Bancroft, D. and Stevens, A. (1996):** Theory and Practice of histological techniques. 2nd ed. Churchill Livingstone, Edinburgh, London, Melbourne
- Blackall P. J.; Christensen H.; Beckenham T. Blackall L. L.; and Bisgaard M. (2005):** Reclassification of *P. gallinarum*, *Hemophilus paragallinarum*, *P. Avium* and *P. Volantium* as *Avibacterium gallinarum* gen. nov., comb. nov., *Avibacterium Paragallinarum* – comb. nov., *Avibacterium avium* comb. nov., and *Avibacterium Volantium* – Comb. nov. – *Int Syst Evol. Mic. Jan;* 55 (Ptl): 353 -62.
- Bojesen A. M.; Christensen H.; Nielsen O. L.; Olsen J. E.; and Bisgaard M. (2003a):** Detection of *Gallibacterium* Spp. in Chickens by Fluorescent 16 S rRNA in situ hybridization. *J. Clin. Microbiol.* 41 (11): 5167 – 72.
- Bojesen A. M.; Nielsen S. S. and Bisgaard M. (2003b):** Prevalence and transmission of hemolytic *Gallibacterium* species in chicken production systems with – different biosecurity levels. *Avian Pathol.*, 32 (5): 503 – 510.
- Bojesen A. M.; Nielson O. L.; Christensen J. P. and Bisgaard M. (2004a):** In vivo studies of *Gallibacterium anatis* infection in chickens. *Avian Pathol.*, 33(2): 145– 152.
- Bojesen A. M.; Petersen K. D.; Nielson O. L.; Christensen J. P. and Bisgaard M. (2004b):** *Pasteurella multocida* infection in heterophil – depleted chickens. *Avian Dis. Sep;* 48 (3): 463 – 70.

- Bojesen – A. M.; Vazquez M. E.; Robles, F.; Gonzalez C.; Soriano E. V.; Olsen J. E. and Christensen H. (2007):** Specific identification of Gallibacterium by a P.C.R using Primers targeting the 16 s r RNA and 23 S r RNA genes. *Vet. Microbiol.*, 20; 123 (1-3): 262 - 268.
- Botzler, R.G. (1991):** Avian Cholera on orth coast California, distinctive epizootiological features *Ann Ny. Acad. Sci.*, 969: 224 – 228.
- Byarugba D. K.; Minga, U. M.; Gwakisa P. S.; Katunguk, R.; Wakishaya, E.; Bisgaard M. and Olsen J. E. (2007):** Virulence characterization of *Avibacterium paragallinarum* strains from Uganda. *Avian Pathol.*, 36 (1): 35-42.
- Christensen, H.; Bisgaard, M.; Aalback, B. and Olsen J. E. (2004):** Reclassification of Bisgaard taxon 33, with Proposal of *volucrobacter psittacida* gen. nov., sp. nov., and *volucrobacter amazonee* SP. nov. new members of The *pasteurellaceae*. *Int. J. Syst. Evol. Microbiol.*, 54: 813 – 818.
- Christensen, H.; Bisgaard, M.; BoJesen, A. M.; Matters, R. and Olsen J. E. (2003):** Genetic relationships among avian isolates classified as *P. haemolytica*, *Actinobacillus salpingitidis* or *P. anatis* with proposal of *Gallibacterium anatis* gen. nov. comb. nov and description of additional genomospecies within Gallibacterium gen. nov. *Int. J. Syst. Evol. Microbiol.*, 53(Pt): 275– 287.
- Chung, J. Y.; Wilkie, I.; Boyce, J. D. and Adler B. (2005):** Vaccination against fowl cholera with acapsular *P. multocida* A:1. *Vaccine*, 23 (21): 2751 – 2755.
- Collee, J. G.; Fraser, A. C.; Marmion, B. P. and Simmons, A. (1996):** Practical medical microbiology. 14th Ed. Charchill Livingstone. New York, Edinburgh London, Madrid Melbourne, Sanfrancisco and Tokyo.
- Cruick-Shank, R.; Duguid, J. P.; Marion, B. P. and Swain, R. H. A. (1975):** Medical Microbiology. 12th ed., Vol II. Churchill Livingstone, Edinburgh, London and New-York.
- Curtis P. E., and Allerhead G. E. (1981):** Investigation to determine whether healthy chickens and turkeys are oral carriers of *pasteurella multocida*. *Vet. Rec.*, 108 (10): 206 – 207.
- Harper, M.; Boyce, J. D.; Wilkie, I. W. and Aler, B. (2003):** Signature-tagged mutagenesis of *P. multocida* identifies mutants displaying differential virulence characteristics in mice and chickens. *Infec. Immunol.*, 71(9): 5440 –5446.
- Karaivanov L. (1984):** Biochemical tests for identifying *pasteurella multocida*. *Vet. Med. Nauki*, 21 (9): 38 – 44.
- Lin, M. Y.; Cheng, M.C.; Huang, K. J. and Tsai, W.C. (1993):** Classification, Pathogenicity and drug susceptibility of hemolytic gram – negative bacteria isolated from sick or dead chickens. *Avian Dis.*, 37 (1): 6 – 9.
- Lin, M. Y.; Lin, K. J.; Lan, Y. C.; Liaw, M. F. and Tung M. C. (2001):** Pathogenicity and drug susceptibility of the *Pasteurella anatis* isolated in chickens in Taiwan. *Avian Dis.*, 45 (3): 655 -658.
- Mwangota, A. U.; Muhammed S. I. and Thomson R.G. (1978):** Serological types of *P. hemolytica* in – Kenya. *Cornell Vet. Jan*; 68 (1): 48 – 93.
- Nakamura, K.; Shirai, J.; Imai, K.; Hihara H., and Tanimuro, N. (1997):** Outbreak of comb necrosis in breeder chickens. *Avian Dis.*, 41 (1): 252 – 256.
- Saif, Y. M.; Barnes, H. J.; Glisson, J. R.; Fadly, A. M.; Mcbougald, L. R. and Swayne, D. E. (2003):** Diseases of poultry. 11th ed. Iowa State Press. a Blacwell Publishing Company.
- Sarkozy, G.; Semjen, G.; Iacazy, P. and Horrath, E. (2002):** Treatment of experimentally induced *P. multocida* infections in broilers and turkeys comparative studies of different oral treatment regimens. *J-Vet. Med. B Infect. Dis. Vet Puplic Health*, 49 (3): 130 –134.
- Semjen, G.; Magyar, T. and Iacazy, P. (1998):** Therapeutic effecancy of doxycycline against experimental *P. multocida* infection in broiler chickens. *Acta Vet. Hung* 46 (1): 85 – 93.
- Shaw D.P., Cook D.B. Maheswaran S.K., Lindeman C.J., and Holvorson D.A (1990):** *P. hemolytica* as a Co-Pathogen in Pullets and laying hens. *Avian Dis.*, 34(4): 1005 – 1008.
- Shivaprasad, H. L and Droual, R. (2002):** Pathology of an atypical strain of *Pasteurella gallinarum* infection chickens. *Avian Pathol.*, 31(4): 399-406.
- Takaya, M.; Akiyama, K.; Taniguchi, T.; Nonomura, I. and Horiuchi T. (1981):** Fowl cholera found in imported myna birds (*Eulabes intermedia*) *Nat. Inst. Animal Health, Q (Tokyo)* .fall, 21 (3) : 129 -33.
- Woo Y.K. and Kim J.H. 2006:** Fowl Cholera outbreak in domestic poultry and epidemiological properties of *P. multocida* isolate. *J. Microbiol.*, 44 (3): 344 – 353.
- Yancey, R. J.; Kinney, M. L.; Roberts, B. J.; Good enough, K. R.; Hamel, J. C. and Ford, C. W. (1987):** Ceftiofur Sodium, a broad-spectrum cephalosporin, evaluation in vitro and in vivo in mice. *Am. J. Vet. Res.*, 48 (7): 1050 – 1053.

دراسات بكتريولوجية وباثولوجية علي ميكروب المانهيميا هيموليتيكا وميكروب الباستيريلا ملتوسيدا في الدواجن

في محافظة بني سويف

في دراسة مقارنة بين ميكروب المانهيميا هيموليتيكا وميكروب الباستيريلا ملتوسيدا المسببين لبعض المشاكل التنفسية والمعوية في الدواجن تم اخذ ١٦٠ عينة من الطيور النافقة والمريضة وأجريت الفحوص البكتريولوجية والباثولوجية لهذه العينات حيث تم عزل ٥٠ (٣١,٢٥%) معزولة بكتيرية ٣٤ (٢١,٢٥%) منها كانت لميكروب الباستيريلا ملتوسيدا و١٦ (١٠%) منها كانت لميكروب المانهيميا هيموليتيكا. وعند إجراء العدوى المعملية لعدد من الدواجن عمر ٤ أسابيع وعدد من فئران التجارب لوحظ أن تلك المعزولات أحدثت تغيرات اكلينيكية وباثولوجية تشابهت إلى حد كبير مع التغيرات المصاحبة للعدوى الطبيعية وقد تم إعادة عزل الميكروب مرة أخرى من الدواجن والفئران المصابة معمليا وبإجراء اختبار الحساسية لتلك المعزولات ضد بعض المعالجات الدوائية المتداولة بالأسواق كانت هذه المعزولات شديدة الحساسية لكل من السيفتوفور والجنتاميسين واللينكوميسين + سبيكتينوميسين وعند إجراء الفحص الهيستوباثولوجي لبعض العينات المصابة طبيعيا ومعمليا تطابقت التغيرات الهيستوباثولوجية لأنسجة الأعضاء الداخلية الناتجة عن كلتا المعزولتين ولكنها كانت اشد أثرا في حالة العدوى الطبيعية ومن خلال تلك الدراسة يتضح أن كل من ميكروب الباستيريلا ملتوسيدا وميكروب المانهيميا هيموليتيكا قد وجد بنسبة مرتفعة نسبيا في تلك المزارع التي تعاني من مشاكل تنفسية ومعوية وقد تم تحديد حساسية هذه العترات لبعض المعالجات الدوائية

