

***In vitro* characterization and pathogenesis of Egypt/Beni-Suef/01; a novel genotype of infectious bronchitis virus**

A. S. Abdel-Moneim¹, H. M. Madbouly¹, M. F. El-Kady²

¹Department of Virology, Faculty of Veterinary Medicine, Beni-Suef University, Beni-Suef, Egypt.

²Department of Poultry Diseases, Faculty of Veterinary Medicine, Beni-Suef University, Beni-Suef, Egypt

In vitro characterizations of infectious bronchitis virus (Egypt/Beni-Suef/01 strain) were studied. Heat stability at 56 °C for 5, 10, 15, 20, and 30 min, UV irradiation for 10, 15, 20, and 30 min, chloroform sensitivity, pH stability, and E/M examination were screened. Two-week-old commercial chickens were inoculated intraocularly with Egypt/Beni-Suef/01. At days 1, 3, 5, 7, 11 and 14 days post-infection, three birds were euthanatized, and virus antigens were screened using immunofluorescence. Histopathology of both trachea & kidney was also performed.

Egypt /Beni-Suef/01 was found to be sensitive to 56 °C for 5 min, UV for 10 min and chloroform but resistant to pH 3 and pH 9. It showed typical morphology of coronaviruses by E/M. The virus was found to induce mild respiratory signs and sever renal changes. Immunofluorescence staining showed viral antigen in larynx, trachea, thymus, lung, liver, spleen, renal tubules and glomeruli as well as bursa of Fabricius but not in pancreas. Marked histopathological lesions were also detected in both trachea and kidneys.

Avian infectious bronchitis virus (IBV) is a coronavirus in the new order *Nidovirales* (Cavanagh, 1997). The virus results in an acute, highly contagious respiratory disease in young chickens with potential involvement of kidney and reproductive tract (Cavanagh and Naqi, 1997). Many different genotypes of IBV have been identified throughout the world (Hopkins, 1974; Davelaar *et al.*, 1984; Karaca *et al.*, 1990; Gough *et al.*, 1992; Wang and Tsai, 1996; Qiang *et al.*, 1998; Lee *et al.*, 2001; Abdel-Moneim *et al.*, 2002 and Bayry *et al.*, 2005). Most of such isolates showed different pathogenicity to chickens.

In Egypt, IBV has been demonstrated since 1954 (Ahmed, 1954). Isolates related to Massachusetts, D3128, D274 and the novel genotype, Egypt/Beni-Suef/01 were isolated from different poultry farms (Sheble *et al.*, 1986; Elkady, 1989 and Abdel-Moneim *et al.*, 2002). Egypt/Beni-Suef/01 was isolated from an outbreak of renal and respiratory distresses among broiler farms in Egypt. It showed poor sequence homology to the commonly used H120 vaccine (Abdel-Moneim *et al.*, 2002). Although avian IBV is the most intensively studied coronavirus, the sensitivity of some strains for example Beaudette, Massachusetts, and Connecticut to chemical and physical treatments have showed different results from one report to another (von Bülow, 1967; Cowen *et al.*, 1971; Winterfield *et al.*, 1971 and Otsuki

et al., 1979). Contradictory results have been practically reported on the resistance of strains to exposure to 56°C (von Bülow, 1967; Cunningham and Spring, 1969; Winterfield *et al.*, 1971 and Otsuki *et al.*, 1979) and pH stability (Singh *et al.*, 1974; Cowen and Hitchner 1975 and Otsuki *et al.*, 1979). The present study investigates the *in vitro* characterization as well as pathogenesis of Egypt/Beni-Suef/01: a novel IBV genotype in broiler chickens.

Materials and Methods

Chickens. Commercial broiler chickens (Integrated Co., Azab, Fayoum, Egypt) were reared under strict hygienic conditions in separate rooms and used in pathogenicity test.

Embryonated chicken eggs (ECE). Specific-pathogen-free (SPF) ECE obtained from Nile SPF (Koom Oshiem, Fayoum, Egypt) were used for residual infectivity titration in physico-chemical characterization.

Viruses. The 7th passage of Egypt/Beni-Suef/01; novel genotype of IBV (AF395531) that was isolated from broiler chickens suffering from respiratory and renal distress (Abdel-Moneim *et al.*, 2002) was used in this study. IBV (H120) adapted to vero cells (Vaccine and Serum Research Institute, Abbasia, Egypt) was used for preparation of hyperimmune serum against IBV.

Hyperimmune serum preparation. Rabbit

polyclonal anti-IBV serum was prepared as described (Saifuddin and Wilks, 1990). Briefly, equal volumes of 10^5 TCID₅₀/ml IBV (H120) adapted to vero cells (Vaccine and Serum Research and Production Institute, Abbasia, Egypt) was mixed with complete Freund adjuvant (BACTO Difco, USA) and 2 ml were injected intramuscularly into each of two rabbits. Three weeks later, a second booster of H120 (vero adapted) dose and Freund incomplete adjuvant (BACTO Difco, USA) was injected. Three weeks following the booster immunization, blood samples were taken and serum was collected, and stored at -20°C until used.

Virus titration. Egypt/Beni-Seuf/01 was titrated as described by (Villegas and Purchase, 1989). Virus titers were expressed as 50% embryo infectious doses (EID₅₀) and calculated as described by (Reed and Muench, 1938).

Physicochemical characterization.

Heat stability. It was performed according to (Cowen *et al.*, 1987). A ten fold dilution of Egypt/ Beni-Seuf/01 virus was exposed to 56°C for 5, 10, 15, 20, and 30 min. in water bath. Residual infectivity was assessed by titration of the treated fluid after each treatment in SPF ECE.

pH stability. It was performed by the method of (Otsuki *et al.*, 1979). Ten fold serial dilution of the IBV infective allantoic fluid was done in Tris pH 9.0, citrate buffer pH3.0 and phosphate buffer saline (PBS) pH 7.3. The diluted virus was incubated at 4°C for 180 min. The virus viability was assayed by titration of the treated fluid after in SPF ECE.

UV stability. It was performed according to (Petck *et al.*, 1973). Ten fold serial dilution of the IBV infective allantoic fluid was done in sterile PBS pH 7.3 in sterile Petri dishes. Dishes were irradiated by U.V. 60 watt lamp placed 10 cm below such lamp. The isolate was irradiated for 10, 15, 20, and 30 min. and then virus infectivity was evaluated by titration in SPF ECE.

Chloroform susceptibility. The chloroform-susceptibility test was done according to (Feldman and Wang, 1961). IBV infective allantoic fluid was reacted with 4.8% reagent-grade chloroform (v/v) for 10 min at 4°C . The reactants were then centrifuged ($31\times g$ for 5 min). The topmost clear layer was recovered and titrated in SPF ECE.

Electron microscopy. The EM examination

was conducted according to the method adopted by (Cowen, *et al.*, 1987). Virus containing allantoic fluid was centrifuged at $1,000\times g$ for 15 min to clarify the virus suspension. The supernatant fluid concentrated by centrifugation at $40,000\times g$ for 2 h, and the resultant virus pellet was resuspended in 1 ml of distilled water. A copper grid coated with carbon film was floated on the surface of the virus suspension. After approximately 30 sec., the grid was transferred onto filter paper and left to air dry. The grid was transferred to a solution of 5% uranyl acetate for an additional 30 sec., and then allowed to air dry. The negatively stained preparation was then examined at 60 KV acceleration (Zeiss EM10, Germany). The appropriate virus size was estimated using the standard equation $O=IM$, where M is the magnification power, I is the image height, and O is the object height (Bueche, 1982).

Virus Pathogenicity. Sixty 2-week-old chickens were used. Thirty chickens were infected by intraocular instillation of 10^5 EID₅₀ /100ul of Egypt/Beni-Seuf/01 according to (Albassam *et al.*, 1986) while the other birds were kept as control uninfected group. Clinical signs and gross post-mortem lesions were recorded. Microscopic examination of tracheae and kidneys was also, performed at 1, 3, 5, 7, 11, and 14 days post infection.

Indirect immunofluorescent antibody technique (IFA). It was performed according to (Grist *et al.*, 1979). Briefly, immunofluorescent staining was performed by incubating deparaffinized slides with rabbit anti-IBV antibodies (1:5) for 1 h and subsequently with FITC-conjugated goat antirabbit antibody (1:1000) for 1 h. Both primary and secondary antibodies were diluted in PBS. Slides were rinsed three times with PBS after each step Slides then mounted using glycerol/PBS (without allowing the slides to dry) and examined under fluorescent microscopy. Antigen detection using IFA was monitored at 1, 3, 5, 7, 11, and 14 days post infection in larynx, trachea, lung, thymus, liver, spleen, pancreas, kidney, and bursa.

Results


Physicochemical characterization. Egypt/ Beni-Seuf /01 was found to be sensitive to heating at 56°C for 5min., UV irradiation within 10min., and to chloroform treatment. Egypt/Beni-Seuf /01 was found to be resistant to the both pH 3 and pH 9 (Table 1).

Table (1): Results of the different physicochemical treatments on Egypt /Beni-Seuf/01.

No.	Treatment	Log ₁₀ titers before treatment	Log ₁₀ titers after treatment	Log ₁₀ Reduction in infectivity titers
1	56°C for 5min.	7.5	2.5	5
2	56°C for 10min.	7.5	2.31	5.19
3	56°C for 15min.	7.5	2	5.5
4	56°C for 20min.	7.5	1.79	5.71
5	56°C for 30min.	7.5	1.7	5.8
6	UV for 10 min	7.5	3	4.5
7	UV for 15 min	7.5	2.7	4.8
8	UV for 20 min	7.5	2.3	5.2
9	UV for 30 min	7.5	2.05	5.45
10	Chloroform	7.5	1.9	5.6
11	PH 3	7.5	6.26	1.24
12	PH 9	7.5	6.26	1.24

Electron microscopy. Negatively stained virions preparation of Egypt\Beni-Seuf/01 particles showed to be pleomorphic or round with widely spaced club-shaped surface projections (Fig. 1) with an average diameter of 160 nm, consistent with coronaviruses.

Fig.1 Electron microscopic picture showing negatively stained preparation of Egypt/Beni-Seuf/01 (100,000x) illustrating pleomorphic particles with widely spaced, club-shaped surface projections.



Pathogenicity of Egypt/Beni-Seuf/01 to 2-week-old chickens.

Signs. Infection of 2-week-old chickens resulted in conjunctivitis at 3-day post-infection (P.I), slight rales appeared after 5 day P.I, while nasal discharge appeared at 7 day P.I. Signs were not so severe and no mortalities were observed.

Gross post-mortum (P/M). No gross lesions were detected at 1day P.I. At 3 day P.I, petechial haemorrhages appeared on the larynx. Kidney, lung, and thymus were congested while the air sacs were turbid. At 5, 7 11, and 14 day P.I, similar lesions were detected including, sever petechial haemorrhages on the larynx and thymus, congestion of the spleen, lung, trachea as well as liver especially over its lower border. Very sever congestion of the kidneys in comparison to kidneys of control uninfected birds were detected all over the experiment.

Microscopic findings.

Trachea.The microscopic findings of the trachea included oedema and mild lymphocytic infiltration that appeared after one day of infection. At 3, 5, 7, 11, and 14 day P.I, similar findings were observed that included loss of cilia, degenerative changes of the tracheal mucosa, irregular loss of epithelium, desquamation of the sloughed epithelium in the tracheal lumen and lymphocytic infiltration that ranged from focal aggregation to diffuse massive infiltration (Fig.3) whereas tracheal of control uninfected birds showed normal tracheal architecture (Fig.2).

Kidney. Renal tubules showed hydropic degeneration, cloudy swelling, and coagulative necrosis as well as hyaline casts that appeared at 3 day P.I and persisted along the time of the experiment in all examined samples. Focal lymphocyte infiltration appeared at 1 day P.I till 14 day P.I. (end of the experiment). Hypercellularity of the renal glomeruli 5, 7, 11 day P.I. (Fig.4) Microscopic examination of the ureter revealed, mucous degeneration and desquamation of the epithelium into the lumen of the ureter together with lymphocytic infiltration in the L.propria at 3, 5, 7, and 11 day P.I. Fibroblastic proliferation of the L.propria of the ureter appeared at 11, and 14 day P.I. The most prominent lesions were observed in the renal blood vessels and included congestion, massive haemorrhages, (Fig.5) haemosiderosis and hyalinosis that were observed at 3, 5, 7, 11, and 14 days P.I. Fibroblastic proliferation of the T.media, and proliferation of the T. intima were observed in some samples 14 day P.I (Fig.6). Kidney of control uninfected birds

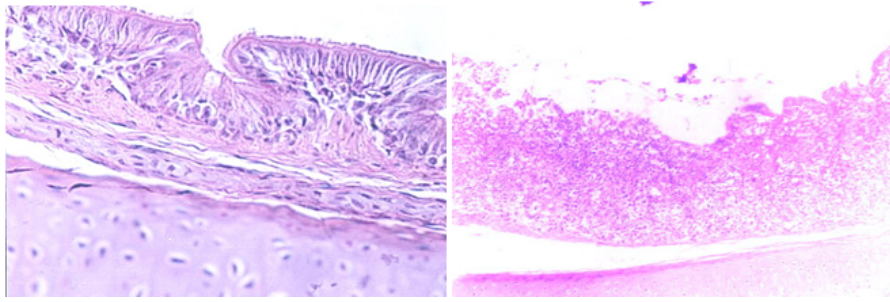


Fig. (2): Tracheal sections; **Right:** Normal tracheal (40 x) **Left:** 5 d P.I with showed diffuse lymphocyte infiltration, degeneration and sloughing of the epithelium stained with H & E (20 x).

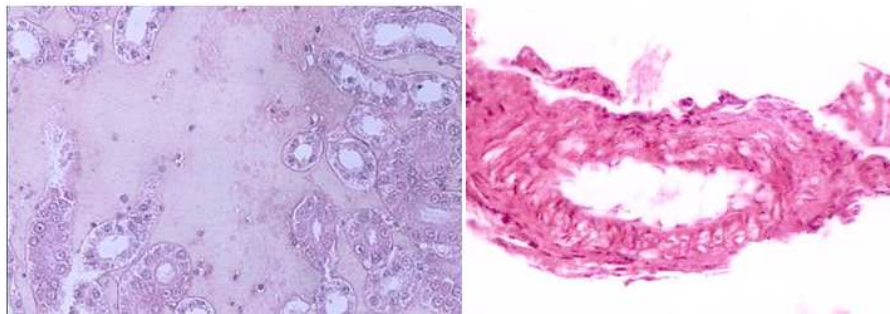


Fig.(3): Kidney sections ; **Right:** 5 d P.I with Egypt/Beni-Seuf/01, showed massive renal haemorrhages, and degeneration of renal tubular epithelium (40 x), **Left:** 14 d P.I showed proliferation of the T.intema, hyalinosis, and fibroblastic proliferation stained with H & E (40 x).



Fig.4 Paraffin section of kidney 5d P.I with Egypt/Beni-Seuf/01 showed: intracytoplasmic fluorescence in renal tubules (right) 20 x and in glomular tuft (left) 40x.

showed normal architecture Detection of virus antigens in different organs using IFA. IBV virus antigens were detected in the larynx, trachea, kidney and bursa from the first day post infection till the 14th day P.I. Antigens were also detected in the liver, spleen, and lung from the 3rd day P.I. and forwards. Thymus was found to harbour the IBV antigens from the 5th P.I. and forwards. The virus antigens were found in a regular pattern in the larynx, trachea, thymus, lung, spleen, liver (from the 7th P.I. and forwards), and kidney but found in an irregular manner in bursa. No IBV virus antigens were detected in

the pancreas (Table 2). IBV was detected not only in renal tubules but also in the renal glomeruli (Fig.4)

Discussion

Physicochemical characterization beside its value to be a method of virus identification, it gives information about the proper mean of virus eradication. In the present investigation, Egypt/Beni-Seuf/01 (7th passage) was examined for its sensitivity to various treatments. We used the 7th passage as it produced consistent embryo lesion based on the results of egg pathogenicity test (Abdel-Moneim, 2003). The results of the different treatments are summarized in (Table 1).

Table 2. Detection of IBV antigens in different tissues of chickens experimentally infected with Egypt/Beni-Seuf/01 using indirect fluorescent antibody technique.

Days Infection	Bird No	Larynx	Trachea	Thymus	Lung	Liver	Spleen	Pancreas	Kidney	Bursa
1	1	-	-		-	-	-	-	-	-
	2	+	+	ND	-	-	-	-	-	+
	3	+	-	ND	-	-	-	-	+	-
3	1	+	+	-	-	-	+	-	-	-
	2	+	+	-	-	+	+	-	+	+
	3	+	+	-	+	-	-	-	+	+
5	1	+	+	+	+	-	+	-	+	-
	2	+	+	+	+	-	+	-	+	-
	3	+	+	-	+	-	+	-	+	+
7	1	-	-	+	+	+	+	-	+	-
	2	+	+	+	-	+	-	-	+	-
	3	+	+	-	+	+	+	-	+	-
11	1	+	+	+	+	+	+	-	+	+
	2	+	+	+	+	+	-	-	+	-
	3	+	+	+	+	-	+	-	+	-
14	1	-	-	+	+	+	-	-	+	+
	2	+	+	+	+	+	+	-	+	-
	3	+	+	+	+	-	+	-	+	+

ND: Not Done, +: Positive, -: Negative

Reduction of the virus infectivity titration more than 2 log₁₀ EID₅₀ was considered sensitive to such treatment (Otsuki *et al.*, 1979). Accordingly, Egypt/Beni-Seuf/01 was found to be sensitive to heating at 56 °C for 5 min., UV irradiation within 10 min., and to chloroform treatment but it was resistant to the both pH 3 and pH 9 as reduction of the infectivity titer was less than 2 log 10. Our finding is in agreement with many other investigators (Hamre and Procknow, 1966; von Bülow, 1967; Otsuki *et al.*, 1979 and Cowen *et al.*, 1987) and disagreed with (Hofstad, 1956) who reported virus insensitivity to heating at 56 °C for 5 min. Egypt/Beni-Seuf/01 virus was found to display characteristic coronavirus ultrastructure as determined by E/M examination that revealed pleomorphic structures with average diameter of 160 nm and widely spaced cub shaped peplomers (Fig.1). Experimental infection of Egypt/Beni-Seuf/01 to 2-wk-old chickens resulted in mild clinical signs, petechial haemorrhages on larynx and thymus, congestion of spleen, lung, trachea as well as liver

especially over its lower border. Very severe congestion of the kidneys in comparison to kidneys of control uninfected birds were detected all over the experiment. No mortality was detected in experimentally infected chickens, although such isolate produced considerable mortality in naturally affected birds (Abdel-Moneim, 2003). This may be clarified by the finding of (Nakamura *et al.*, 1992) who made a combined intranasal inoculation of different IBV strains and *E. coli*, high mortalities in young chickens were resulted but neither infection alone was lethal. This fact rendered some investigators simulate natural outbreak of the disease in the field by inducing experimental infection with mixture of IBV and *E. coli* as the development of generalized *E. coli* infection, is a common consequence to the damage of the respiratory tract by IBV (Smith *et al.*, 1985 and Cook *et al.*, 1986). The microscopic findings in tracheal sections appeared similar to those recorded by (Purcell *et al.*, 1976 and Toro *et al.*, 1988) including: loss of cilia, degenerative changes of

the tracheal mucosa, irregular loss of epithelium, desquamation of the sloughed epithelium in the tracheal lumen and lymphocytic infiltration that ranged from focal aggregation to diffuse massive infiltration whereas tracheal of control uninfected birds showed normal tracheal architecture.

The microscopic findings of the renal tubules match the general findings recorded with nephrogenic IBV strains (Purcell *et al.*, 1976 and Albassam *et al.*, 1986) but the most prominent lesions were observed in the renal blood vessels. It included congestion, massive haemorrhages, haemosiderosis and hyalinosis that were observed at 3, 5, 7, 11, and 14 days P.I. as well as fibroblastic proliferation of the T.media, and proliferation of the T.intema that were observed in some samples at 14 day P.I.

IBV antigens were detected in the larynx, trachea, thymus, lung, spleen, liver, kidney and bursa of Fabricius. An interesting finding was the presence of IB viral antigen not only in renal tubules, but also in glomerular tuft epithelium (Fig.4). No IBV virus antigens were detected in the pancreas. The presence of viral antigens in larynx, trachea, thymus, lung, spleen, liver, bursa and kidney are in agreement with findings of (Cumming, 1969). Regarding liver, thymus and spleen, although, Kapczynski *et al.* (2002) as well as Ambali and Jones, (1990) could not detect IBV antigens or mRNA in them, Cumming, (1969) successfully isolated IBV from such tissues.

Egypt/Beni-Suef/01 was found to be sensitive to heat, UV and chloroform but resistant to pH 3 and pH 9. It showed typical morphology of coronaviruses by E/M. The virus was found to induce mild respiratory signs but sever renal changes and marked histopathological lesions esp. in trachea and kidneys. Egypt/Beni-Suef /01 infection constitutes real challenge to poultry production in Egypt, a fact that necessitates increased effort to develop homologous IBV vaccine.

References

- Abdel-Moneim, A. S. (2003):** Physico-chemical, molecular, and biological characterization of a novel genotype of infectious bronchitis virus in Egypt. Ph.D. Thesis Fac. Vet. Med. Cairo Univ., Beni-Seuf, Egypt.
- Abdel-Moneim, A. S.; Madbouly, H. M.; Gelb Jr, J. and Ladman, B. S. (2002):** Isolation and identification of Egypt/Beni-Seuf/01 a novel genotype of infectious bronchitis virus. *Vet. Med. J. Giza, Egypt*, 50:1065-1078.
- Ahmed, H. N. (1954):** Incidence and treatment of some infectious viral respiratory diseases of poultry in Egypt. Ph.D. Thesis Fac. Vet. Med. Cairo Univ., Egypt.
- Albassam, M. A.; Winterfield, R. W. and Thacker, H. L. (1986):** Comparison of the ephropathogenicity of four strains of infectious bronchitis virus. *Avian Dis.*, 30: 468-476.
- Ambali, A. G. and Jones, R. C. (1990):** Early pathogenesis in chickens with an enterotropic strain of infectious bronchitis virus. *Avian Dis.*, 34: 809-817.
- Bayry J.; Goudar, M. S.; Nighot, P. K.; Kshirsagar, S. G.; Ladman, B. S.; Gelb Jr, J.; Ghalsasi, G. R. and Kolte, G.N. (2005):** Emergence of a nephropathogenic avian infectious bronchitis virus with a novel genotype in India. *J. Clin. Microbiol.*, 43:916-918.
- Bueche, F. (1982):** Principles of physics 4th ed. Kosaido Printing LTD. Tokyo. Japan, pp. 588-620.
- Cavanagh, D. (1997):** *Nidovirales*: A new order comprising *Coronaviridae* and *Arteriviridae*. *Arch. Virol.*, 142:629-633.
- Cavanagh, D. and Naqi, S. A. (1997):** Infectious bronchitis. In: *Diseases of poultry*, 10th ed. B.W.Calnek, H.J.Barnes, C.W.Beard, W.M.Reid, and H.W.Yoder, eds. Iowa State Univ.Press, Ames, IA., pp.511-526.
- Cook, J. K. A.; Smith, H. W. and Huggins, M. B. (1986):** Infectious bronchitis immunity. Its study in chickens experimentally infected with mixtures of infectious bronchitis virus and *Escherichia coli*. *J. Gen. Virol.*, 67: 1427-1434.
- Cowen, B.S. and Hitchner, S. B. (1975):** pH stability studies with avian infectious bronchitis virus (coronavirus) strains. *J. Virol.*, 15: 430-432.
- Cowen, B. S.; Wideman Jr., R. F.; Braune, M. O. and Owen, R. L. (1987):** An infectious bronchitis virus isolate from chicken experiencing a urolithiasis outbreak. I. In vitro characterization. *Avian Dis.*, 31: 878-883.
- Cowen, B. S.; Hitchner, S. B. and Ubertine, T. (1971):** Characterization of a new infectious bronchitis virus isolate. II Some chemical and physical properties of Clark 333. *Avian Dis.*, 15: 527-532.
- Cumming, R.B. (1969):** The control of avian infectious bronchitis/nephrosis in Australia. *Aust. Vet. J.*, 45:200-203.
- Cunningham, C.H. and Spring, M. P. (1969):** Some studies of infectious bronchitis virus in cell culture. *Avian Dis.*, 9: 182-193.
- Davelaar, F. G.; Kouwenhoven, B. and Burger, A. G. (1984):** Occurrence and significance of infectious bronchitis virus variant strains in egg and broiler production in the Netherlands. *Vet. Quarterly*, 6: 114-120.
- El-Kady, M. F. (1989):** Studies on the epidemiology and means of control of infectious bronchitis disease in chickens in Egypt. Ph.D. Thesis Fac. Vet. Med. Cairo Univ., Egypt.
- Hamre, D. and Procknow, J. J. (1966):** A new virus isolated from the human respiratory tract. *Proc. Soc. Exp. Biol.*, 121: 190-193.
- Hofstad, M.S. (1956):** Stability of avian infectious bronchitis virus at 56°C. *Cornell Vet.*, 46:122-128.
- Feldman, H.A. and Wang, S. S. (1961):** Sensitivity of various viruses to chloroform. *Proc. Soc. Exp. Biol. Med.*, 106:736-740.
- Gough, R. E.; Randall, C. J.; Dagless, M.; Alexandar, D. J.; Cox, W.J. and Pearson, D. (1992):** A new strain of infectious bronchitis virus infecting domestic fowl in Great Britain. *Vet. Rec.*, 130: 493-494.
- Grist, N. R.; Bell, E. J.; Follett, E. A. C. and Urquhart, G. E. D. (1979):** *Diagnostic Methods in Clinical Virology*, 3rd ed. Blackwell Scientific

- Publications, Osney Mead, Oxford, OX2 0EL, pp.31-43.
- Hopkins, S.R. (1974):** Serological comparison of infectious bronchitis virus using plaque purified isolates. *Avian Dis.*, 18: 231-239.
- Kapczynski, D. R.; Sellers, H. S.; Rowl, G.N. and Jackwood, M.W. (2002):** Detection of in ovo-inoculated infectious bronchitis virus by immunohistochemistry and in situ hybridization with a riboprobe in epithelial cells of the lung and cloacal bursa. *Avian Dis.*, 46:679-685.
- Karaca, K.; Naqi, S. A.; Palukaitis, P. and Lucio, B. (1990):** Serological and molecular characterization of three enteric isolates of infectious bronchitis virus of chickens. *Avian Dis.*, 34: 899-904.
- Lee, C. W.; Hilt, D. A. and Jackwood, M.W. (2001):** Identification and analysis of the Georgia 98 serotype a new serotype of infectious bronchitis virus. *Avian Dis.*, 45: 164-172.
- Nakamura, K.; Cook, J. K.; Frazier, J. A. and Narita, M. (1992):** *Escherichia coli* multiplication and lesions in the respiratory tract of chickens inoculated with infectious bronchitis virus and /or *E.coli*. *Avian Dis.*, 36: 881-890.
- Otsuki, K.; Yamamoto, H. and Tsubokura, M. (1979):** Studies on avian infectious bronchitis virus (IBV). I. Resistance of IBV to chemical and physical treatments. *Arch. Virol.*, 60: 25-32.
- Petek, N. D.; Aprile, P. N. and Cancellotti, E. (1973):** Biological and physicochemical properties of infectious bursal disease virus (IBDV). *Avian Pathol.*, 2:135-152.
- Purcell, D. A.; Tham, V. L. and Surman, P. G. (1976):** The histopathology of infectious bronchitis in fowls infected with a nephrotropic T strain of virus. *Aust. Vet. J.*, 52: 85-91.
- Qiang, Z. G.; Wei, Y. W.; Shang, S. L.; Lin, W. B.; Quan, W. H.; Hong, Z. J. Kun, W. Y. (1998):** Infectious bronchitis virus strains (H95 variant) isolated from chickens with infectious proventriculus disease. *Chin. J. Vet. Sci.*, 18: 233-236.
- Reed, L. J. and Muench, H. A. (1938):** Simple method of estimating fifty percent endpoints. *Am. J. Hyg.*, 27: 493-497.
- Saifuddin, Md., and Wilks, C. R. (1990):** Development of an avian enzyme linked immunosorbent assay to detect and quantify adenovirus in chicken tissues. *Avian Dis.*, 34:239-245.
- Sheble, A.; Sabry, M. Z.; Davelaar, F. G.; Burger, A. G.; Khafagy, A. K.; Moustafa, F. Moustafa, M. M. and Henna, M. (1986):** Present status of infectious bronchitis in Egypt. *J. Egypt. Vet. Med. Assoc.*, 4:393-411.
- Singh, V. P.; Malik, B. S. and Verma, K. C. (1974):** Physical and chemical characteristics of a local strain of infectious bronchitis virus IBV of poultry. *Ind. J. Poult. Sci.*, 9:168-171.
- Smith, H. W.; Cook, J. K. A. and Parsell, Z. E. (1985):** Experimental infection of chickens with mixtures of infectious bronchitis virus and *Escherichia coli*. *J. Gen. Virol.*, 66: 777-786.
- Toro, H.; Kaleta, E.F.; Herbst, W.; Peixoto, P. and Frese, K. (1988):** Differences in pathogenicity for young chickens among field isolates of infectious bronchitis virus. *Arch. de Medicina Veterinaria chole*, 20: 44-50.
- Villegas, P. and Purchase, H. G. (1989):** Titration of biological suspension. In :Laboratory Manual for the Isolation and Identification of Avian Pathogens. 3rd ed. Ammerican Association of Avian Pathologists. H.G.Purchase, L.H.Arp., C.H.Domermuth, and J.E.Pearson eds. Kenall\Hunt publishing company, Iowa , USA, pp.186-190.
- von Bülow, V. (1967):** Infectious bronchitis of fowls. IV characterization of a new strain of virus (IBV-10) *Zentble. Vet. Med.*, B14: 151-162.
- Wang, C.H., and Tsai, C.T. (1996):** Genetic grouping for the isolates of avian infectious bronchitis virus in Taiwan *Arch. Virol.*, 141: 1677-1688.
- Winterfield, R. W.; Fadly, A. M. and Hanly, J.E. (1971):** Characteristics of an isolate of infectious bronchitis virus from chickens in Florida. *Avian Dis.*, 15: 305.