

## IMMEDIATE FUNCTIONAL LOADING EFFECT ON SUPPORTING STRUCTURES OF IMPLANTS PLACED IN MANDIBULAR CLASS II KENNEDY CLASSIFICATION CASES. A TWO YEAR CLINICAL STUDY

Ahmed Ezzat Sabet\* and Heba khorshid\*\*

### ABSTRACT

**Background:** The Target of this study was to evaluate and analyze the changes that occur in the supporting structures of implants placed in the posterior mandibular region using the Immediate Functional Loading Protocol. The bone height of the four implant surfaces; buccal, lingual, distal and mesial were closely observed, measured and statistically analyzed.

**Materials and Methods:** Thirty implants were placed in ten patients with unmodified mandibular Kennedy Class II. For each patient, three implants were placed at the premolar/molar mandibular region. All the implants were immediately loaded following an Immediate Functional Loading Protocol. Radiographic evaluation using dental CT was carried out at intervals of 0, 12 and 24 months after implant surgery.

**Results:** Decrease in the bone level throughout the study period in the bucco-lingual surfaces however this decrease was statistically insignificant using paired t test. The same was found regarding the mesio-distal surface throughout the study period

**Conclusion:** Within the limitations of this study, it was found that immediately loaded single implants placed in the posterior mandibular area with high insertion torque is a favorable treatment option. Immediately loading protocol must be carefully done in patients with limited bucco-lingual bone width.

**KEYWORDS:** Immediate loading, Functional loading, Computed tomography

### INTRODUCTION

Long-term clinical evaluation of dental implants is crucial for gaining more information about causes of implant success and failure. One of the most important criteria is the marginal bone level

around implants.<sup>(1)</sup> Since bone-anchored prostheses are planned to be sustained in the oral environment for a lifetime,<sup>(2)</sup> a pathologic decrease in bone level could lead to loss of bone anchorage of the implant, and it is important to know what factors contribute to bone resorption.

\* Department of Fixed Prosthodontics, Faculty of Dentistry, Ain Shams University

\*\* Department of Removable Prosthodontics, Faculty of Oral and dental medicine, Cairo University

Controversy exists about several variables influencing implant success and especially marginal bone loss (MBL). The size of the implants,<sup>(3)</sup> age and gender of patients,<sup>(4)</sup> and the presence of cantilevers<sup>(5)</sup> as influencing factors are subject of debate.

In the past two decades some of the original prerequisites for successful osseointegration are being redefined to meet patients' demands to reduce treatment time and increase comfort. Immediate loading and immediate implantation concepts have been proposed to shorten treatment time and to allow the patient to quickly recover function and esthetics.<sup>(6)</sup>

Immediate loading is gaining popularity among clinicians, and the outcome of immediately loaded dental implants is being investigated more and more in clinical trials and animal studies.<sup>(7-9)</sup> Even though the results are sometimes conflicting, there is an increasing corpus of evidence to support the application of immediate loading.<sup>(6)</sup> However, most of the clinical studies on immediate loading have been performed in the totally edentulous maxilla and mandible. Few studies have investigated immediate loading of implants for single tooth replacement,<sup>(10,11)</sup> and fewer still have examined immediate loading of implants placed in fresh extraction sockets.<sup>(12,13)</sup>

## MATERIALS AND METHODS:

Ten patients were selected from the outpatient Prosthodontics clinic, Faculty of Oral and Dental Medicine, Cairo University and outpatient Prosthodontics clinic, Faculty of Dentistry, Ain Shams University. Patients were with unmodified Class II Kennedy mandibular arch showing normal maxillo-mandibular relationship (Class I Angle classification), with no parafunctional habits and free from any systemic disease. The average patients' age was 40.3 years. The opposing arch (maxilla) was completely dentulous either by a complete set of natural dentition or restored with satisfactory fixed restorations.

InterActive™ implants (Implant Direct Sybron International, CA 91301, USA) were the implants utilized in this study. For each patient, three osteotomies were prepared to receive 3 implants at the premolar/molar mandibular region over which 3-unit screw-retained fixed/detachable restorations were constructed. The insertion torque of the implants was checked by an adjustable torque wrench at 30Ncm. Resonance frequency analysis (Osstell, Gothenburg, Sweden) device was used to verify that all implants reading were higher than 60 before loading. Patients were strictly instructed to follow a soft diet protocol for the first month. (fig. 1)

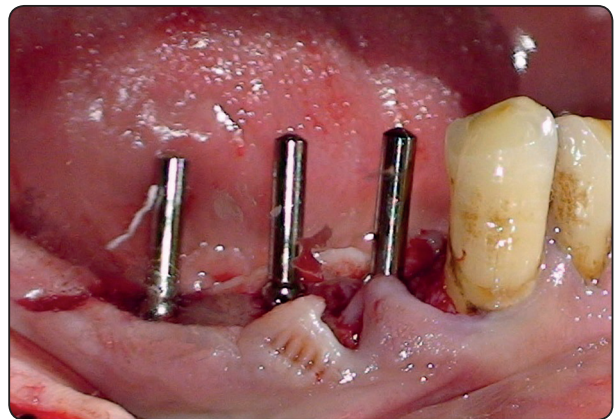


Fig. (1) Paralleling rods placed in the three osteotomies showing parallelism from a buccal view

The provisional restorations were delivered to the patients 48 hours after surgery using the Immediate Functional Loading Protocol. The acrylic resin was constructed to be in direct (full) occlusal contact with the opposing maxillary teeth where the following occlusal protocol was followed:

- Evenly distributed occlusal contacts and force (Cusp-fossa/ cusp-embrasure occlusal contacts).
- Wide freedom in centric occlusion (wide groove and flat fossa).

Slight reduction of the cusp inclination especially the buccal inclines of the mandibular buccal cusps was performed to avoid interference in lateral excursive movements of the mandible.

Six months after surgery, the final metal ceramic screw-retained restoration with an occlusal surface designed to make full occlusal contact with the opposing dentition were delivered to the Patients. (Fig 2)

**Radiographic Follow-Up**

Radiographic assessment was performed using dental Computed Tomography (CT) (General electric© Co., light speed plus 4-multislice CT machine, USA) at 0, 12 and 24 months after surgery. After obtaining the images, a computer software program (Mimics, Materialise HQ, Technologielaan 15, 3001 Leuven, Belgium) was used, whereby coronal and sagittal reformatting and panoramic views were obtained. The crestal bone heights were measured at each implant site to obtain 4 readings: mid-distal,

mid-mesial, mid-buccal and mid-lingual around each implant (Figs. 3, 4). The mean values were calculated, tabulated and statistically analyzed to compare the effect of functional loading on the four different surfaces.

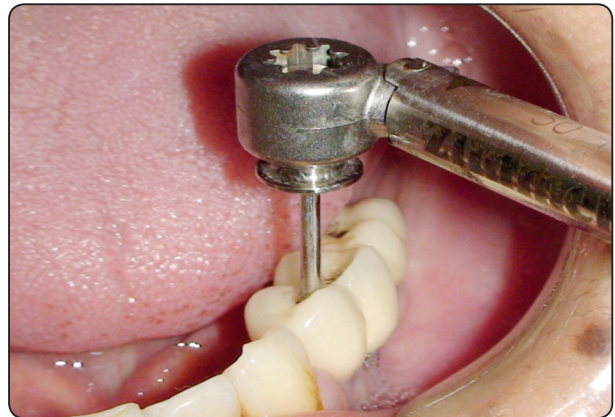


Fig. (2) Delivery of the final metal ceramic restoration

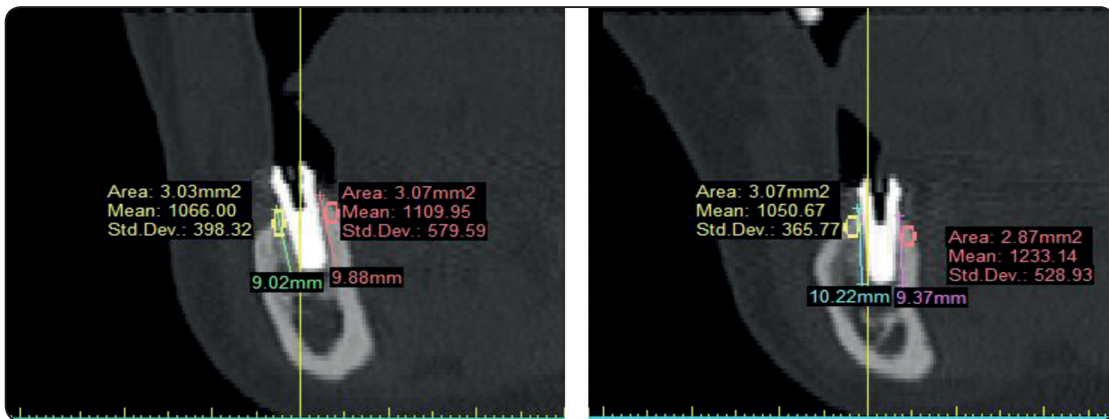


Fig. (3) Bone Height measured at the Buccal and Lingual bone

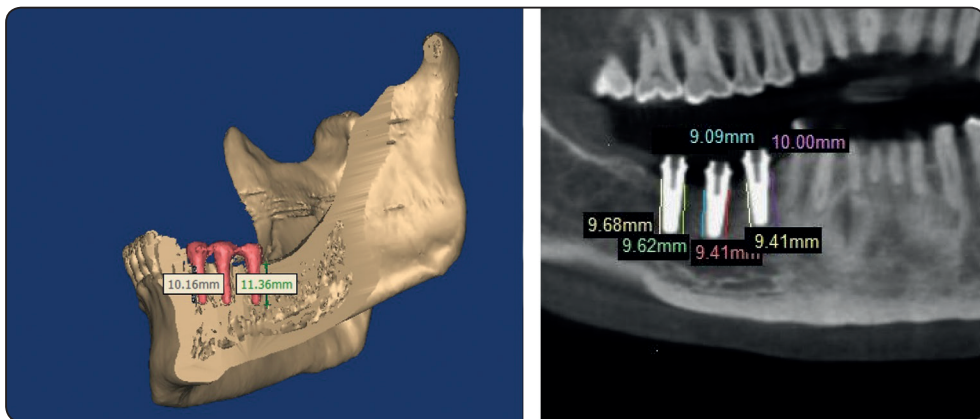


Fig 4: Bone Height measured at the mesial and distal bone

## RESULTS

The results comprised the assessment of the hard tissue reaction (Bone Height) surrounding the three implants placed in the posterior mandibular areas as a result of the immediate functional loading protocol at 0, 12 and 24 months after implant installation.

At the end of this study, all implants were considered osseointegrated. None of the subjects evidenced peri-implantitis, peri-mucositis or clinical implant mobility in any direction. No pain was as well noted on palpation, percussion or function.

### Statistical Methods

Data management and analysis were performed using Statistical Analysis Systems. To measure the effect of time and surface (buccal, lingual, mesial and distal) using the Immediate functional loading protocol on the percentage change of the bone height, Paired-t-test was used to evaluate the effect of time on the buccolingual surfaces and on the mesio-distal surfaces. Student-t-test was used to compare between the bucco-lingual surfaces and the mesio-distal surfaces. P-values  $\leq 0.05$  were considered significant.

### The Bone Height

The mean values (m) and standard deviation (S.D) measured in millimeters (mm) of the bucco-lingual and mesio-distal bone height in the immediate functional loading group at zero, twelve and twenty-four months as shown in Table (1&2).

The previous table shows that there was a decrease in the bone level throughout the study period in the bucco-lingual surfaces however this decrease was statistically insignificant using paired t test. The same was found regarding the mesiodistal surface throughout the study period.

Table 2 shows the difference in bone loss between bucco-lingual surfaces & mesio-distal surfaces. The results show greater bone loss in

the bucco lingual surface than in the mesio-distal surface after one year & after two year. However by using student -t-test, this difference was statistically significant between buccolingual surfaces and Mesiodistal surfaces from insertion to one year and from insertion to two years. However there are statistically non-significant changes from one to two year using student t-test.

TABLE (1) Mean, Standard deviation & p-value of paired -t-test of the effect of time on the bone changes around the buccolingual surfaces and the mesiodistal surfaces

BUCCO LINGUAL	At insertion		After 1 year		After 2 years	
	Mean	±SD	Mean	±SD	Mean	±SD
	11.31	0.6	9.8	0.6	9.13	0.64
p-value	<b>Versus insertion</b>					
			1.29 ns		1.007ns	
	<b>Versus 1 year</b>					
					4.3 ns	
Mesio- Distal	At insertion		After 1 year		After 2 years	
	Mean	±SD	Mean	±SD	Mean	±SD
	11.28	0.5	10.23	0.4	9.4	0.4
p-value	<b>Versus insertion</b>					
			8.24ns		1.03 ns	
	<b>Versus 1 year</b>					
					1.03nsig	

TABLE (2) Mean, difference, Standard deviation & the p-value of student -t-test for the comparison between the amount of bone changes in different intervals between bucco-lingual & mesio-distal surfaces.

	Buccolingual		Mesiodistal		p-value
	Mean diff	±Sd	Mean diff	±Sd	
Insertion-1y	1.41	0.58	1.04	0.3	0.004 sig
1y-2y	0.75	0.29	0.8	0.3	0.3ns
Insertion -2 y	2.18	0.6	1.8	0.52	0.04 sig

## DISCUSSION

This study aimed to test the effect of immediate loading on crestal bone height around implants as maintaining crestal bone around an implant has significant relevance. It is the level of crestal bone that will influence the position of the marginal soft tissue. The absence of postoperative bone resorption around the implant collar establishes a critical factor in stabilizing the papilla.<sup>(14)</sup> For inter-implant areas, this becomes important to maintain the height of the papilla. If the inter-implant bone height is lost, it will cause soft tissue changes

Surgical trauma, biologic width, and implant microdesign are thought to be the causes of crestal bone resorption around the implants; however, the precise mechanism is not still clearly understood. To achieve stable osseointegration for implant restoration, the generation of high-stress concentration in bone, which is supposed to be one of the causes of the bone loss, should be avoided.<sup>(15)</sup>

Radiography is important for routine clinical practice and in research projects evaluating dental implants. In particular, radiographic measurements of the marginal alveolar bone level change over time have been reported to be important parameters.<sup>(16)</sup> Different methods have been used to assess bone height in the implant region, from simply counting the number of threads on screw-type implants to using a computer based interactive image analysis system. Computed tomography of the jaws and the teeth are widely used as a simple and fast method of evaluating the condition of the bone around implants.<sup>(17)</sup>

It is possible to measure implant stability by means of the resonance frequency analysis, but the values were not collected in this study because its purpose was not to longitudinally assess implant stability but to be sure that the implants are stable enough to withstand immediate loading protocol

Analysis of the peri-implant bone height revealed a reduction in the bone height around the implants in all surfaces and throughout all the time periods using the immediate functional loading protocol.

This might be attributed to the fact that the interface between the implants and bone begins to remodel due to two main causes as reported by Parfitt;<sup>(18)</sup> the surgical trauma and the mechanical loading response produced by the immediate delivery of the implant prosthesis leading to the inevitable crestal bone resorption.

The values of marginal bone loss found in this study were consistent with what has been reported in other studies on immediate single tooth implants in the similar areas.<sup>(19&20)</sup>

Marginal bone loss was observed more in the bucco-lingual surfaces than mesiodistal one which may be due to thinner buccal and lingual plate of bone than mesiodistal dimension which may affect the bone ability to withstand applied stresses. This was in agreement with Goswami<sup>(21)</sup> who stated that crestal bone loss was maximum on the buccal side even under delayed loading protocol

This study evaluated survival rates up to 24 months from implant placement. This follow-up period is brief but takes into account the fact that implant failure due to mechanical overloading occurs early in the healing period.<sup>(22)</sup>

Esthetic outcome was not objectively measured in this study. Soft-tissue contours are a major factor for rating treatment success, particularly in esthetically delicate areas. We considered peri-implant marginal bone level as a determining factor for the quality of implant survival and thus as our primary outcome measure. The level of the peri-implant marginal bone has been suggested to determine the level of the peri-implant mucosa and thus the esthetic outcome.<sup>(23&24)</sup>

## CONCLUSIONS

*Within the limitations of this study, it was found that:*

- 1- Immediately loaded single implants placed in the posterior mandibular area with high insertion torque is a favorable treatment.
- 2- Immediately loading protocol must be carefully used in patient with limited bucco-lingual width

## REFERENCES

1. Esposito M, Hirsh JM, Lekholm U, Thomsen P. Biological factors contributing to failures of osseointegrated oral implants. (II). Success criteria and epidemiology. *Eur J Oral Sci.* 1998;106:527–551. Marginal Bone Loss Around Implants 556 Vol. XXXVII/No. Five/2011
2. Bryant SR, Zarb GA. Crestal bone loss proximal to oral implants in older and younger adults. *J Prosthet Dent.* 2003;89:589–597.
3. Pilliar RM, Deporter DA, Watson PA, Valiquette N. Dental implant design: effect on bone remodeling. *J Biomed Mater Res.* 1991;25:467–483.
4. Norton MR. Multiple single-tooth implant restorations in the posterior jaws: maintenance of marginal bone levels with reference to the implantabutment microgap. *Int J Oral Maxillofac Implants.* 2006;21:777–784.
5. Kunavisarut C, Lang LA, Stoner BR, Felton DA. Finite element analysis on dental implant-supported prostheses without passive fit. *J Prosthodont.* 2002;11:30–40.
6. Esposito M, Grusovin MG, Coulthard P, Worthington HV. Different loading strategies of dental implants: a Cochrane systematic review of randomized controlled clinical trials. *Eur J Oral Implantol.* 2008;1:259–276.
7. Randow K, Ericsson I, Hilner K, Petersson A, Glanz PO. Immediate functional loading of Branemark dental implants. *Clin Oral Implant Res.* 1999;10:8–15.
8. Gapski R, Wang HL, Mascarenhas P, Lang NP. Critical review of immediate implant loading. *Clin Oral Impl Res.* 2003;14:515–527.
9. Capelli M, Esposito M, Zuffetti F, Galli F, Del Fabbro M, Testori TA. 5-year report from a multicentre randomized clinical trial: immediate non-occlusal versus early loading of dental implants in partially edentulous patients. *Eur J Oral Implantol.* 2010;3:209–219.
10. Ericsson I, Nilson H, Lindh T, Nilner K, Randow K. Immediate functional loading of Branemark single tooth implants. An 18 months' clinical pilot follow-up study. *Clin Oral Implants Res.* 2000;11:26–33.
11. Degidi M, Piattelli A, Gehrke P, Felice P, Carinci F. Five-year outcome of 111 immediate nonfunctional single restorations. *J Oral Implantol.* 2006;32:277–285.
12. Barone A, Rispoli L, Vozza I, Quaranta A, Covani U. Immediate restoration of single implants placed immediately after tooth extraction. *J Periodontol.* 2006;77:1914–1920.
13. Crespi R, Cappare` P, Gherlone E, Romanos GE. Immediate versus delayed loading of dental implants placed in fresh extraction sockets in the maxillary esthetic zone: a clinical comparative study. *Int J Oral Maxillofac Implants.* 2008;23:753–758.
14. Hermann JS, Buser D, Schenk RK, et al. Crestal bone changes around titanium implants. A histometric evaluation of unloaded non-submerged and submerged implants in the canine mandible. *J Periodontol.* 2000;71:1412–1424.
15. Park Y, Lee S, Han C, Kwon J, Jung Y. The Microtomographic Evaluation of Marginal Bone Resorption of Immediately Loaded Scalloped Design Implant With Various Microthread Configurations in Canine Mandible: Pilot Study. *J Oral Implantology.* 2010;23:305-314.
16. Chaytor DV, Zarb GA, Schmitt A, Lewis DW. The longitudinal effectiveness of osseointegrated dental implants. The Toronto study: bone level changes. *Int J Periodontics Restorative Dent.* 1991;11:113–125.
17. Donatsky O. Osseointegrated dental implants with ball attachments supporting overdentures in patients with mandibular alveolar ridge atrophy. *Int J Oral Maxillofac Implants.* 1993;8:162–166.
18. Parfitt AM. The physiological and clinical significance of bone histomorphometric data. In: Reck RR ed. *Bone Histomorphometry, Techniques and Interpretation.* Boca Raton, FL: CRC Press. 1983;143-223.
19. De Rouck T, Collys K, Cosyn J. Single-tooth replacement in the anterior maxilla by means of immediate implantation and provisionalization: a review. *Int J Oral Maxillofac Implants.* 2008;23:897–904.
20. Lorenzoni M, Pertl C, Zhang K, Wimmer G, Wegscheider WA. Immediate loading of single-tooth implants in the anterior maxilla. Preliminary results after one year. *Clin Oral Impl Res.* 2003;14:180–187.
21. Goswami MM. Comparison of crestal bone loss along two implant crest module designs. *Medical journal Armed force.* 2009;65:320-321.
22. Lindeboom JA, Frenken JW, Dubois L, Frank M, Abbink I, Kroon KH. Immediate loading versus immediate provisionalization of maxillary single-tooth replacements: a prospective randomized study with BioComp Implants. *J Oral Maxillofac Surg.* 2006;64:936–942.
23. Bengazi F, Wennstrom JL, Lekholm U. Recession of the soft tissue margin at oral implants. A 2-year longitudinal prospective study. *Clin Oral Implants Res.* 1996;7:303–310.
24. Chang M, Wennstrom JL, Odman P, Andersson B. Implant supported single-tooth replacements compared to contralateral natural teeth. Crown and soft tissue dimensions. *Clin Oral Implants Res.* 1999;10:185–194.