

## EFFECT OF MICRO-OSTEOPERFORATIONS ON THE RATE OF CANINE RETRACTION; A SPLIT-MOUTH RANDOMIZED CONTROLLED CLINICAL TRIAL

Farah Y. Eid<sup>1</sup>, Walid A. El-Kenany<sup>2</sup>, Ahmed R. El-Kalza<sup>3</sup>

### **ABSTRACT:**

**INTRODUCTION:** The prolonged orthodontic treatment time is considered a major concern both for patients and clinicians. Corticotomy has been proposed as a method for acceleration of orthodontic tooth movement and was found successful. However, its popularity decreased because of its invasiveness. Micro-osteoperforations have been proposed for acceleration with minimal invasiveness. **OBJECTIVE:** The purpose of the study was to clinically evaluate the effect of micro-osteoperforations on the rate of orthodontic tooth movement as evaluated by its effect on the rate of canine retraction. **MATERIALS AND METHODS:** The study was a split-mouth randomized controlled clinical trial, with a sample size of 10 adult patients (mean age  $17.5 \pm 2.5$  years) requiring the therapeutic extraction of maxillary first premolars' followed by canine retraction. Micro-osteoperforations were randomly assigned to one side of the maxillary arch at the canine-premolar region, and the contra-lateral side served as control. Anchorage reinforcement was performed using mini-screws, and canine retraction was performed using nickel-titanium closed coil springs, delivering a force of 150 grams on each side. The rate of canine retraction was measured throughout the study period

from dental models obtained at the follow-up visits every 3 weeks. **RESULTS:** The average daily rate of canine retraction was significantly higher on the experimental side compared to that on the control side by approximately 2 times during the first 9 weeks of the study. **CONCLUSION:** Micro-osteoperforations have been found clinically successful in accelerating orthodontic tooth movement and shortening the treatment duration. However, acceleration of tooth movement has been found significant during the first 9 weeks, which represent the period of regional acceleratory phenomenon. **Keywords:** Micro-osteoperforations, canine, retraction.

### **INTRODUCTION**

One of the major concerns in orthodontics is the prolonged treatment period, which is considered a chief complaint both to patients and clinicians. Extended treatment time also poses several problems, such as the increased risk of root resorption<sup>1</sup>, dental caries<sup>2</sup>, enamel decalcifications<sup>3</sup>, as well as periodontal problems<sup>4</sup>. Accordingly, several methods aiming to accelerate orthodontic tooth movement have been proposed, including surgical and non-surgical interventions.

The suggested non-surgical methods included medications such as prostaglandins<sup>5</sup> and corticosteroids<sup>6</sup>, pulsed electro-magnetic fields<sup>7, 8</sup>, electric currents<sup>9, 10</sup>, low-frequency mechanical vibration<sup>11</sup>, as well as low-level laser therapy<sup>12, 13</sup>. Surgical methods included

1. Instructor at Orthodontic Department, Faculty of Dentistry, Alexandria University.

2. Professor at Orthodontic Department, Faculty of Dentistry, Alexandria University.

3. Lecturer at Orthodontic Department, Faculty of Dentistry, Alexandria University

periodontal and dentoalveolar distraction<sup>14, 15</sup>, corticotomy<sup>16</sup>, piezocision<sup>17</sup> and piezopuncture<sup>18</sup>, corticision<sup>19</sup>, and more recently micro-osteoperforations<sup>20,22</sup>.

Surgical techniques have been found clinically successful in several studies, however, their invasiveness has been considered a major drawback as some of them required flap reflection, such as corticotomy. Reported side effects included post-operative bleeding, pain and swelling, in addition to poor patient acceptance<sup>23</sup>. Consequently, less invasive methods have been tried clinically and experimentally, with the most recent method being micro-osteoperforations.

Micro-osteoperforations involve shallow perforations of the buccal cortical plate surrounding the tooth that requires orthodontic tooth movement, with no flap reflection. These cortical perforations can be performed using a surgical bur<sup>21</sup>, a mini-implant with an automated implant driver<sup>22</sup>, or a special calibrated device for this purpose called PROPEL<sup>20</sup>.

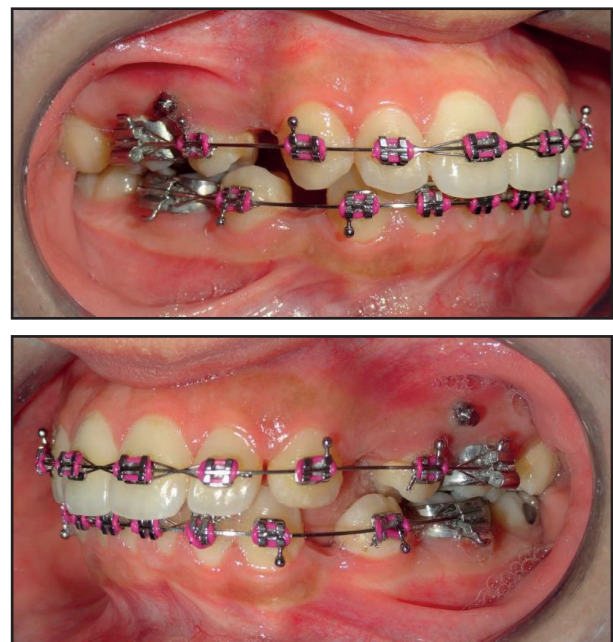
Micro-osteoperforations have been tried clinically by Alikhani et al<sup>20</sup>, where they evaluated its effect on the rate of maxillary canine retraction. The study found that micro-osteoperforations significantly increased the rate of canine retraction by 2.3-fold. However, Alikhani's study evaluated the effect of micro-osteoperforations over a period of 28 days only. Since 28 days may not be enough for evaluation, a longer study period was needed to study the effect of micro-osteoperforations on the rate of orthodontic tooth movement. The purpose of this study was to evaluate the effect of micro-osteoperforations on the rate of maxillary canine retraction over a longer period of time.

## **MATERIALS AND METHODS**

The study was a split-mouth randomized controlled clinical trial, where 10 adult patients requiring the therapeutic extraction of maxillary

first premolars with subsequent canine retraction were recruited for the sample, with an age range between 15 and 20 years. Ethical approval was obtained from the Ethics Review Committee of the Faculty of Dentistry, Alexandria University, Alexandria, Egypt. All patients had to fulfill the following criteria: healthy systemic condition with no chronic diseases, no previous orthodontic treatment, adequate oral hygiene, and a healthy periodontium. All patients were informed of the procedure and signed an informed consent.

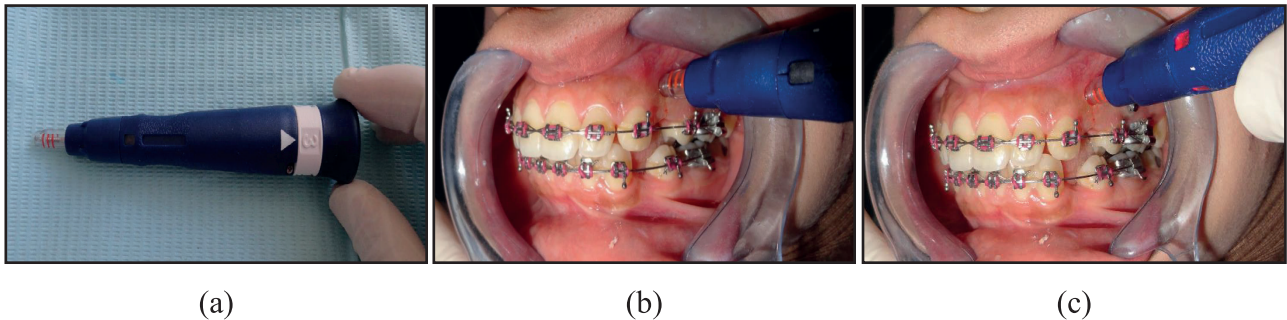
Maxillary and mandibular fixed appliances were secured (straight wire Roth appliance, 0.022×0.028 inch slot), followed by patient referral for maxillary first premolars' extraction. Leveling and alignment stage was then started, and was considered complete when a 0.016×0.022 inch stainless steel arch wire could be placed passively in all the maxillary teeth before the onset of retraction. Mini-screws (HUBIT Orthodontics, Korea) were then bilaterally placed between maxillary 2<sup>nd</sup> premolars and 1<sup>st</sup> molars for anchorage reinforcement (**Figure 1**).



**Figure 1:** Leveling and alignment stage completed, and maximum anchorage prepared.

Micro-osteoperforations were randomly assigned (Computer-aided randomization) to the patients' right or left sides. Micro-osteoperforations were performed using PROPEL device (PROPEL Orthodontics, Ossining, NY), which is a hand-held disposable device, with an

adjustable length, and a light signal that turns on upon achieving the desired depth during the procedure. Three perforations were performed distal to the maxillary canine. Each perforation was 1.5 mm wide, and 2 to 3 mm deep (**Figure 2**).



**Figure 2:** a. PROPEL device with the perforation depth adjusted at the desirable 3 mm. b: Perforations drilled through the gingiva in a clockwise direction. c: The adjusted perforation depth has been reached as indicated by the red light emitted from the device.

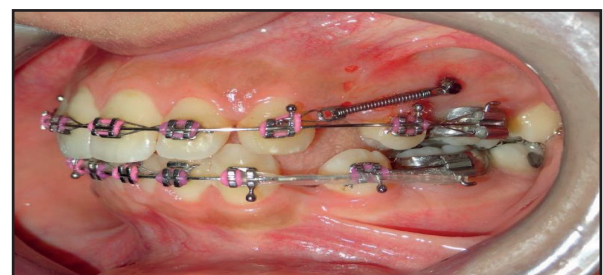
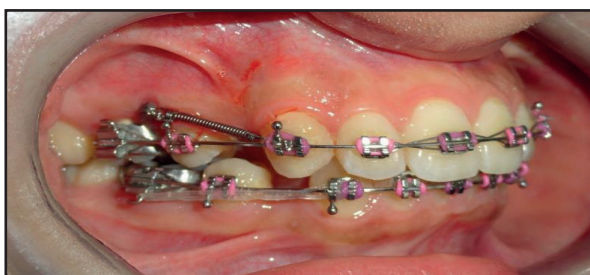
Canine retraction was then started using nickel-titanium closed-coil springs (Ormco NiTi closed coil spring) bilaterally, delivering a force of 150 grams per side, as measured by the force gauge (Morelli force gauge). Closed-coil springs were stretched bilaterally from the mini-screw head to the canine bracket hook (**Figure 3**).

Follow up visits were scheduled every three weeks, where the force magnitude was checked using the same force gauge to maintain the force magnitude at 150 grams throughout the study period. Alginate impressions for the construction of dental models, as well as intra-oral photographs

were regularly taken at each visit.

Dental models were scanned using Sirona inEos X5 CAD/CAM lab scanner producing 3D digital images of the dental models. This was followed by processing the STL files using Quick Ceph software for calibration and cast analysis. Finally measurements were recorded using AutoCAD version 2013 (**Figure 4**).

Several landmarks were identified on the dental cast to evaluate the rate of canine retraction, including the mid-palatal raphe, the most medial points on the third right and left rugae, and the cusp tips of the right and left maxillary canines. Perpendicular lines were drawn from the medial points of the right and left third rugae, and the cusp tips of the right and left maxillary canines to the mid-palatal raphe. The antero-posterior measurements were carried out between the canine lines and the third rugae lines bilaterally, to assess the rate of canine retraction (**Figure 4**).



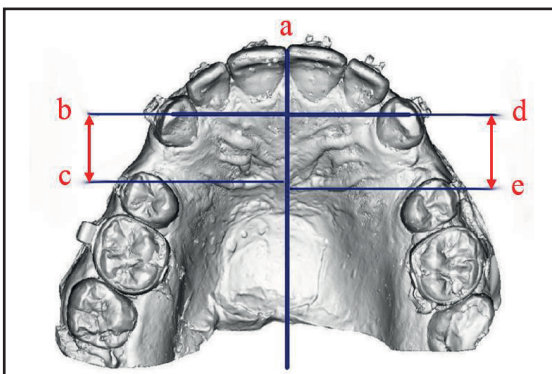
(a)

(b)



(c)

**Figure 3:** a, b: NiTi closed-coil springs bilaterally attached between the mini-screw head and canine bracket hook. c. Morelli force gauge for force adjustment every 3 weeks.



**Figure 4:** 3D scanned image of the dental model using Quick Ceph software. Measurement of canine retraction rate was performed on the scanned image of the dental model using AutoCAD. a: Mid-palatal raphe. b, d: cusp tips of the right and left maxillary canines respectively. c, e: lines corresponding to the medial ends of the right and left third rugae respectively.

## STATISTICAL ANALYSIS

All the data was collected, tabulated, and subjected to statistical analysis which was performed using IBM SPSS software package version 20.0 (Armonk, NY: IBM Corp.)

## RESULTS

Ten subjects were recruited for the study (mean age  $17.5 \pm 2.5$  years) from the out-patient clinic of the Orthodontic Department, Faculty of Dentistry, Alexandria University. The study design was a split-mouth randomized controlled clinical trial. The maxillary arch in each subject was randomly assigned by computer program into experimental and control groups.

Following maxillary first premolars' extraction and the onset of canine retraction, patients were clinically evaluated every 3 weeks.

During the course of the study, there were no subject drop-outs in the pre-intervention period, nor throughout the rest of the study. Also, no dropouts in the follow up dental models were recorded.

### Measurement of the rate of canine retraction

The rate of canine retraction was measured by drawing perpendicular lines from the medial points of the right and left third rugae, and the cusp tips of the right and left maxillary canines to the mid-palatal raphe. **Table (1)** shows the descriptive statistics of the total amount of maxillary canine movement on the experimental side, compared to that on the control side over the same time period. The table shows a statistically significant difference in the total amount of canine movement between both groups at the 3<sup>rd</sup>, 6<sup>th</sup> and the 9<sup>th</sup> week, with an increased tooth

movement on the experimental side compared to the control. The greatest average distance moved by the canine at the experimental side has been recorded at the 3 weeks to be  $1.55 \pm 0.16$  mm. However, starting from the 12<sup>th</sup> week, no statistically significant difference has been demonstrated in the amount canine movement between both groups (**Figure 5**).

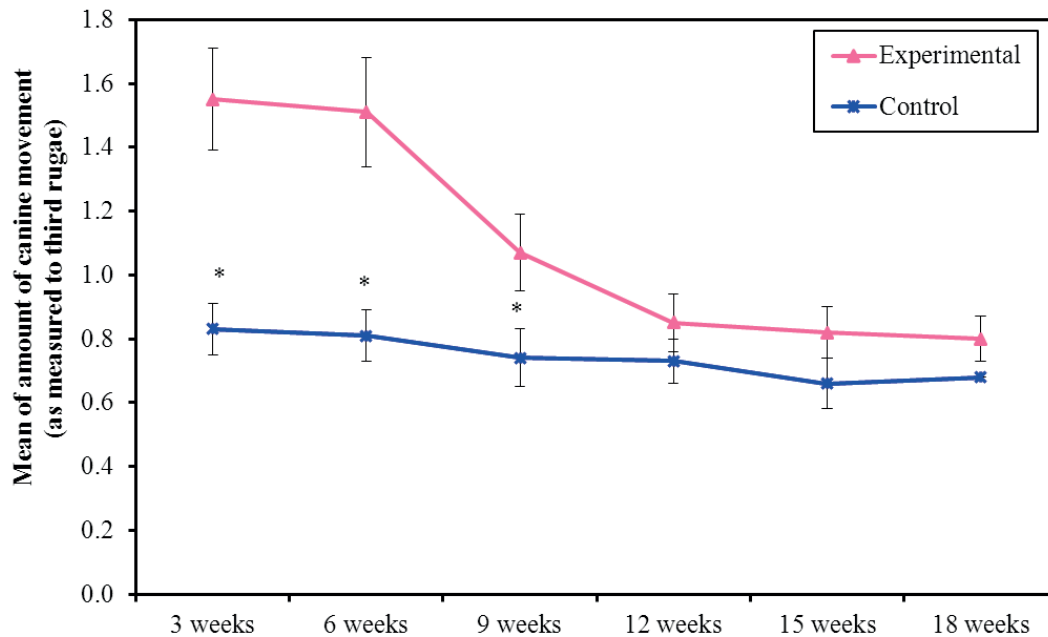
As for **table (2)**, where the mean daily rate of canine distal displacement in both the experimental and control groups has been demonstrated, the average daily rate of canine retraction was significantly higher in the experimental group in the first 9 weeks of the study. The highest rate recorded was at the third

week with a mean rate of  $0.074 \pm 0.008$  mm/day, which was significantly higher than that of the control group which was  $0.039 \pm 0.004$  mm/day at the same time period. At the 6<sup>th</sup> and 9<sup>th</sup> weeks, the mean daily rate of distal canine displacement in the study group decreased to  $0.072 \pm 0.008$  mm/day and  $0.051 \pm 0.006$  mm/day, respectively. By the 12<sup>th</sup> week of the study, the mean daily rate of tooth movement in the study group dropped to  $0.041 \pm 0.004$  mm/day, continuing at approximately the same rate till the end of the study period. However, there was no statistically significant difference between the experimental and control groups starting from week number 12, and thereafter till the end of the study period.

**Table (1):** Comparison between the descriptive statistics of the amount of maxillary canine movement between the studied groups (as measured to the third rugae)

	Amount of canine movement (as measured to third rugae)						
	3 weeks	6 weeks	9 weeks	12 weeks	15 weeks	18 weeks	Total
<b>Experimental</b>	(n = 10 )	(n = 10 )	(n = 10 )	(n = 6 )	(n = 4 )	(n = 2 )	(n = 10 )
Min. - Max.	1,3 - 1.78	1.27 - 1,7 1	0.9 - 1,2	0.73 - 0.98	0.71 - 0.89	0.75 - 0.85	3,75 - 7,42
Mean $\pm$ SD.	1,5 50,16 $\pm$	1,5 10,17 $\pm$	1,07 $\pm$ 0.12	0.85 $\pm$ 0.09	0.82 $\pm$ 0.08	0.80 $\pm$ 0.07	5,23 $\pm$ 1,26
Median	1.55	1,57	1,10	0.85	0.84	0.80	5,10
<b>Control</b>	(n = 10 )	(n = 10 )	(n = 10 )	(n = 6 )	(n = 4 )	(n = 2 )	(n = 10 )
Min. - Max.	0,7 - 1,0	0.7 - 0,96	0.60 - 0.89	0.67 - 0.85	0.57 - 0.75	0.68 - 0.68	2,02 - 5,2
Mean $\pm$ SD.	0,830,08 $\pm$	0.8 10,08 $\pm$	0.74 $\pm$ 0.09	0.73 $\pm$ 0.07	0.66 $\pm$ 0.08	0.68 $\pm$ 0,0	3,29 $\pm$ 1,14
Median	0.81	0.8 1	0.77	0.71	0.65	0.68	3,12
<b>t</b>	14,060*	15,732*	9,330 *	2,413			19,109*
<b>p</b>	<0,001*	<0,001*	<0,001 *	0,061			<0,001*

t, p: t and p values for Paired t-test for comparing between experimental and control groups.



**Figure 5:** Comparison between the studied groups according to amount of canine movement (as measured to third rugae)

**Table (2):** Comparison between the studied groups regarding the daily rate of canine movement (as measured to third rugae)

t, p: t and p values for Paired t-test for comparing between experimental and control groups.

	Daily rate amount of canine movement (as measured to third rugae)						
	3 weeks	6 weeks	9 weeks	12 weeks	15 weeks	18 weeks	Total
<b>Experimental</b>	(n = 10 )	(n = 10 )	(n = 10 )	(n = 6 )	(n = 4 )	(n = 2 )	(n = 10 )
Min. - Max.	0.062 - 0.085	0,06 - 0.081	0.043 - 0.057	0.035 - 0.047	0.034 - 0.042	0.036 - 0,04	0.179 - 0.353
Mean ± SD.	0.074 ±0.008	0.072 ±0.008	0.051 ±0.006	0.041 ±0.004	0.039 ±0.004	.038 ±0.003	0.249 ±0,06
Median	0.074	0.075	0.052	0.040	0,04	0.038	0.243
<b>Control</b>	(n=10 )	(n=10 )	(n=10 )	(n=6 )	(n=4 )	(n=2 )	(n=10 )
Min. - Max.	0.033 - 0.048	0.033 - 0.046	0.029 - 0.042	0.032 - 0,04	0.027 - 0.036	0.032 - 0.032	0.096 - 0.248
Mean ± SD.	0.039 ±0.004	0.038 ±0.004	0.035 ±0.004	0.035 ±0.003	0.031 ±0.004	0.032 ±0,0	0.157 ±0.054
Median	0.038	0.039	0.036	0.034	0.031	0.032	0.149
<b>T</b>	14,060 *	15,732 *	9,330 *	2,413			19,109 *
<b>P</b>	<0,001 *	<0,001 *	<0,001 *	0,061			<0,001 *

## DISCUSSION

A long treatment period is a great burden to the patient, and this usually hampers their acceptance for treatment. Consequently, in the last few decades, acceleration of orthodontic tooth movement has been an active area of research in the orthodontic field, and several surgical and non-surgical methods were suggested and studied.

Corticotomy was one of the highly recommended surgical methods that were suggested for the acceleration of orthodontic tooth movement. However, being an invasive surgical technique that is usually uncomfortable to the patient, made the search for more conservative procedures with comparable efficiency rather mandatory. Several less invasive surgical methods have been suggested over the last few decades, and the most recent addition to this search has been micro-osteoperforations. The aim of this study was to evaluate the effect of micro-osteoperforations on the rate of orthodontic tooth movement, evaluated by the effect on the canine retraction rate.

The current study design was a randomized controlled clinical trial that employed the split-mouth technique. Computer-aided randomization was used to assign the experimental and control sides in each patient. A key advantage of the split-mouth design was the elimination of the inter-subject variability, as the patient acted and his/her own control, thus decreasing the number of participants required. This study model has been adopted by several investigators to determine the effect of different interventions for acceleration of canine retraction, such as Aboul-Ela et al<sup>(16)</sup>.

According to sample size calculation, 10 patients were recruited for the study, with an age range between 15 and 20 years ( $17.5 \pm 2.5$  years on average). All the subjects included required maxillary 1st premolars extraction,

followed by canine retraction as a part of their orthodontic treatment. These inclusion criteria matched those found in previous studies evaluating the effect of corticotomy and micro-osteoperforations on the rate of canine retraction<sup>(16,20)</sup>. The current study aimed to evaluate the effect of micro-osteoperforations on the rate of maxillary canine retraction. Micro-osteoperforations were performed using PROPEL device distal to the maxillary canine. PROPEL is a hand-held disposable device, that has an adjustable length and a light signal, that turns on when the desired perforation depth is reached. The same device and application protocol has been used to perform micro-osteoperforations, in the study by Alikhani et al<sup>(20)</sup>.

In the present study, maximum molar anchorage was secured using mini-screw implants. They were used to provide skeletal anchorage during canine retraction, with the advantages of their relatively simple placement technique, as well as the elimination of reliance on patient compliance. Their placement site was between the maxillary second premolar and the first molar on the buccal side. Placement in the attached gingiva was advocated where a higher success rate was expected, in comparison to placement in the non-keratinized loose alveolar mucosa. Additionally, placement and removal techniques are simpler in the keratinized mucosa. The same mini-screw placement protocol for maximizing anchorage was adopted by several other investigators such as Alikhani et al<sup>(20)</sup> and Aboul-Ela et al<sup>(16)</sup>.

Given the results of the present study, the rate of canine retraction on the experimental side with micro-osteoperforations was found to be approximately 2-fold that on the control side in the first 9 weeks, then decreased to resemble the rate of tooth movement on the

control side thereafter, till the end of the study period. These results were relatively close to those reported in the clinical trial by Alikhani et al<sup>(20)</sup> who clinically tested the effect of micro-osteoperforation on the rate of canine retraction over 28 days, and reported that the rate of tooth movement on the experimental side was 2.3-fold that on the control side. Experimental studies evaluating micro-osteoperforations also reported tooth movement values close to those of the current study, such as that by Safavi et al<sup>(21)</sup> in dogs. The study demonstrated a statistically significant acceleration of tooth movement by 1.82-fold in the study group during the first month of the study. Throughout the remaining study period no statistically significant difference has been reported between both groups, which is quite similar to the results reported in the present study, due to the transient nature of the regional acceleratory phenomenon (RAP), as also reported by Aboul-Ela et al<sup>(16)</sup>. Moreover, Cheung et al<sup>(22)</sup> in their experimental study evaluating the effect micro-osteoperforations on tooth movement in rats, reported a 1.86-fold increase in the rate of tooth movement on the experimental side, over the 21 days study period.

Reviewing the literature, studies evaluating the effect of surgical corticotomy on the rate of tooth movement, showed comparable results to the present study applying micro-osteoperforations. For example, Aboul-Ela et al<sup>(16)</sup> reported that during the first 2 months following corticotomy surgery, the rate of tooth movement almost doubled on the corticotomy side, and decreased thereafter, reflecting the transient nature of the regional acceleratory phenomenon. Hence, from the stated data, since surgical corticotomy is considered an invasive method that involves flap reflection, in addition to the fact that quite

similar results were obtained regarding acceleration of tooth movement with the less invasive micro-osteoperforations, we can positively recommend micro-osteoperforations as a successful method for acceleration, given the great advantage of it being minimally-invasive.

## CONCLUSION

Micro-osteoperforations have been found clinically successful in accelerating orthodontic tooth movement and shortening the treatment duration. However, acceleration of tooth movement has been found significant during the first 9 weeks, which represent the period of regional acceleratory phenomenon.

### Conflict of interest:

The authors declare that they have no conflicts of interest.

## REFERENCES

1. Kurol J, Owman-Moll P, Lundgren D. Time-related root resorption after application of a controlled continuous orthodontic force. *Am J Orthod Dentofacial Orthop* 1996;110:303-10.
2. Årtun J, Brobakken BO. Prevalence of carious white spots after orthodontic treatment with multibonded appliances. *The Eur J Orthod*. 1986;8:229-34.
3. ÅRTUN J, THYLSTRUP A. Clinical and scanning electron microscopic study of surface changes of incipient caries lesions after debonding. *The Eur J Orthod Sci*. 1986;94:193-201.
4. Ristic M, Svabic MV, Sasic M, Zelic O. Clinical and microbiological effects of fixed orthodontic appliances on periodontal tissues in adolescents. *Orthod Craniofac Res*. 2007;10:187-95.



5. Leiker BJ, Nanda RS, Currier GF, Howes RI, Sinha PK. The effects of exogenous prostaglandins on orthodontic tooth movement in rats. *Am J Orthod Dentofacial Orthop.* 1995;108:380-8.
6. Ashcraft MB, Southard KA, Tolley EA. The effect of corticosteroid-induced osteoporosis on orthodontic tooth movement. *Am J Orthod Dentofacial Orthop.* 1992;102:310-9.
7. Stark TM, Sinclair PM. Effect of pulsed electromagnetic fields on orthodontic tooth movement. *Am J Orthod Dentofacial Orthop.* 1987;91:91-104.
8. Showkatbakhsh R, Jamilian A, Showkatbakhsh M. The effect of pulsed electromagnetic fields on the acceleration of tooth movement. *World J Orthod.* 2010;11:e52-e6.
9. Davidovitch Z, Finkelson MD, Steigman S, Shanfeld JL, Montgomery PC, Korostoff E. Electric currents, bone remodeling, and orthodontic tooth movement: II. Increase in rate of tooth movement and periodontal cyclic nucleotide levels by combined force and electric current. *Am J Orthod.* 1980;77:33-47.
10. Kim D-H, Park Y-G, Kang S-G. The effects of electrical current from a micro-electrical device on tooth movement. *Korean J Orthod.* 2008;38:337-46.
11. Nishimura M, Chiba M, Ohashi T, Sato M, Shimizu Y, Igarashi K, et al. Periodontal tissue activation by vibration: intermittent stimulation by resonance vibration accelerates experimental tooth movement in rats. *Am J Orthod Dentofacial Orthop.* 2008;133:572-83.
12. Doshi-Mehta G, Bhad-Patil WA. Efficacy of low-intensity laser therapy in reducing treatment time and orthodontic pain: a clinical investigation. *Am J Orthod Dentofacial Orthop.* 2012;141:289-97.
13. Cruz DR, Kohara EK, Ribeiro MS, Wetter NU. Effects of low-intensity laser therapy on the orthodontic movement velocity of human teeth: A preliminary study. *Lasers surgery Med.* 2004;35:117-20.
14. Liou EJ, Huang CS. Rapid canine retraction through distraction of the periodontal ligament. *Am J Orthod Dentofacial Orthop.* 1998;114:372-82.
15. Sukurica Y, Karaman A, Gürel HG, Dolanmaz D. Rapid canine distalization through segmental alveolar distraction osteogenesis. *Angle Orthod.* 2007;77:226-36.
16. Aboul SMBE-D, El-Beialy AR, El-Sayed KMF, Selim EMN, EL-Mangoury NH, Mostafa YA. Miniscrew implant-supported maxillary canine retraction with and without corticotomy-facilitated orthodontics. *Am J Orthod Dentofacial Orthop.* 2011;139:252-9.
17. Mittal S, Sharma R, Singla A. Piezocision assisted orthodontics: a new approach to accelerated orthodontic tooth movement. 2011;1.
18. Kim Y-S, Kim S-J, Yoon H-J, Lee PJ, Moon W, Park Y-G. Effect of piezopuncture on tooth movement and bone remodeling in dogs. *Am J Orthod Dentofacial Orthop.* 2013;144:23-31.
19. Kim S-J, Park Y-G, Kang S-G. Effects of corticision on paradental remodeling in

orthodontic tooth movement. *Angle Orthod.* 2009;79:284-91.

20. Alikhani M, Raptis M, Zoldan B, Sangsuwon C, Lee YB, Alyami B, et al. Effect of micro-osteoperforations on the rate of tooth movement. *Am J Orthod Dentofacial Orthop.* 2013;144:639-48.

21. Safavi SM, Heidarpour M, Izadi SS, Heidarpour M. Effects of flapless bur decortications on movement velocity of dogs' teeth. *Dent Res J.* 2012;9:783.

22. Cheung T, Park J, Lee D, Kim C, Olson J, Javadi S, et al. Ability of mini-implant-facilitated micro-osteoperforations to accelerate tooth movement in rats. *Am J Orthod Dentofacial Orthop.* 2016;150:958-67.

23. Cassetta M, Di Carlo S, Giansanti M, Pompa V, Pompa G, Barbato E. The impact of osteotomy technique for corticotomy-assisted orthodontic treatment (CAOT) on oral health-related quality of life. *Eur Rev Med Pharmacol Sci.* 2012;16:1735-40.



