



RESEARCH ARTICLE

Corticosteroid-Induced Osteoporosis and Osteonecrosis: The Role of Oxidative Stress

Reham H. Alattar^{1*}, Abdel Alim F. Abdel Alim², Sabry M.A. Abdelmetal² and
Sayed A. Abdel Aziz²

¹Zagazig University student's Hospital, Zagazig University, Egypt

²Pharmacology Department, Faculty of Veterinary Medicine, Zagazig University, Zagazig,
Egypt, 44511

Article History: Received: 22/06/2019 Received in revised form: 18/07/2019 Accepted: 23/07/2019

Abstract

Glucocorticoids (GCs) are mainly used in different chemotherapeutic protocols and play a major role in the normal tuning of bone remodeling. But, the use of GCs for long time associated oxidative injury have a crucial role in the development of osteoporosis (OP), osteonecrosis (ON) and apoptosis. This study intended to investigate the effects of ginseng as a natural, novel free radical scavenger that may help in alleviating the osteoporetic changes. Forty mature male New Zealand white rabbits were divided equally into control (C), steroid-administered (S) and ginseng-administered (G) and group of steroid with ginseng (S+ G). Two separate experiments were conducted, one for acute model receiving 20 mg/kg.BW injected in upper gluteal muscle once for one week and ginseng orally daily by dose 14 mg/kg.BW. The second (chronic model) where animals received 4 mg/kg.BW injection in upper gluteal muscle once weekly for six weeks and ginseng orally daily by dose 14 mg/kg.bw for six weeks. Oxidant (MDA)/antioxidant (GSH) status was determined in steroid-induced OP & ON in an acute and chronic model. The presence or absence of ON, OP and intravascular thrombi were examined histopathologically and immunohistochemically using calcitonin, caspase 3 and nuclear factor kappa-B cells (NF-κB) markers.. The biochemical study revealed a significant increase in the plasma GSH level and significant decrease in the MDA with the use of ginseng compared with steroid groups in acute and chronic experiment. The (G+S) treated group maintained their morphology compared to corticosteroid treated group, which showed marked osteoporotic changes. In conclusion, ginseng, as a natural, free radical scavenger could significantly suppress the development of osteoporetic changes.

Keywords: Osteoporosis, Osteonecrosis, Corticosteroids, Oxidative stress, Ginseng

Introduction

Glucocorticoids (GC) either natural or synthetic remain at the spearhead of immunosuppressive and anti-inflammatory therapies. They are excessively used to treat both chronic and acute inflammations. Including multiple sclerosis, inflammatory bowel disease, rheumatoid arthritis, psoriasis as well as being used in treatment of certain leukemia's and in immunosuppressive regimes following organ transplant [1]. However, the use of oral glucocorticoids for long time is conjoined with serious side effects embracing osteoporosis. Dexamethasone (Dex), as an

example for synthetic GC hormone, may inhibit the synthesis of both collagen and fibronectin, it also stimulates collagenase synthesis [2]. GCs encourage apoptosis in both bone and cartilage, leading to excessive or premature loss of osteoblast precursors, osteocytes, and articular and growth plate chondrocytes [3]. The way of GC inducing apoptotic cell death is not clear until now. In addition, in adult mice the use of prednisone increases the rate of apoptosis in both osteocytes and osteoblasts [4]. Gohel *et al.* [5] demonstrated that using corticosterone in rats leads to apoptosis.

* Corresponding author e-mail: (reham_attar2013@yahoo.com), Pharmacology Department,
Zagazig University. Zagazig, Egypt.

Protracted usage may lead to metabolic diseases and increased risk of cardiovascular diseases, the consensus is that acute toxicity with large dose of corticosteroids could be laid to oxidative stress [6]. Since a long time, ginseng (*Panax ginseng* Meyer) has been considered as the most important herbal medicine traditionally in East Asia. These days, ginseng is one of the extensively used botanical products all over the world [7]. It also has anticancer, antioxidant, antiadipogenic and antidiabetic, activities [8]. Some studies have reported that ginseng has antiosteoporotic activity [9]. Ginseng and its extracts have different pharmacological activities, which help in treatment of different human diseases, such as cardiovascular diseases, wounds, hypertension, cerebral ischemia, liver regeneration, diabetes mellitus, rheumatoid arthritis and antiangiogenesis [10]. The aim of this study was to investigate the oxidative stress role in the pathogenesis of corticosteroid-induced osteonecrosis (ON) and osteoporosis (OP) using rabbits as an experimental animal model and studying the possibility of using a natural antioxidant, ginseng, as a novel free radical scavenger to help in the management of OP and ON.

Materials and Methods

Chemicals

Depo-Medrol® (Methylprednisolone acetate suspension; 40 mg/ml) for injection (Pfizer: Pharmaceutical, Shanghai, China). Ginseng (Gensana capsule that commercially known as; panax ginseng) is an extract of roots of the genuine (100 mg), was obtained from EIPICO (Egyptian International Pharmaceutical Industries Company. A.R.E).

Animals and experimental design

Two separate experiments were conducted, one for acute model and the second for chronic model. Forty adult white male New Zealand rabbits of 2-3 months old and weighing about 1.5-2 kg were used (n=20) for each experiment. In each model experiment animals were divided into four equal groups, (n=5) and were kept in separate disinfected metal cages in a well-ventilated, well lighted and disinfected room. Rabbits received commercial pelleted ration with clean water *ad-libitum*, and were under observation all

over the period of experiments. For both experiments; Group (C) referred to control group where rabbits were kept without any medications. For the acute experiment, the duration was only one week. Group (S): (Steroid group) were injected intramuscularly once into the right gluteal muscle with 20 mg/Kg. BW of methyl prednisolone. Ginseng was given daily, orally (200 mg/kg BW (human dose)) [11], which was converted to rabbit dose according to Paget and Barned to (14 mg/kg BW) [12]. Group (S+G): (Steroid with Ginseng group) were treated with both methylprednisolone once a week and Ginseng given orally, daily. Group (G): (Ginseng group) rabbits in this group were given Ginseng alone orally once daily. In the chronic experiment; the duration extended for a period of 6 weeks. The steroidal drug was given I.M. only once per week in a dose of 4 mg/kg. Ginseng was given orally daily for the period of 6 weeks (14 mg/kg BW). Group (S): (Steroid group) were injected intramuscularly once weekly into the right gluteal muscle with 4 mg/Kg. BW of methyl prednisolone. Group (S+G): (Steroid with Ginseng group) were treated with both methylprednisolone once a week and Ginseng given orally, daily for 6 successive weeks. Group (G): (Ginseng Only group) were given Ginseng alone orally for 6 weeks. The experimental procedures were conducted according to the guidelines of Institutional Animal Care and Use Committee of Zagazig University (ZU-IACUC) under the approval number of ZU-IACUC/2/F/88/2018

Biochemical examination

Under general anesthesia with sodium pentobarbital, Virbac, blood samples were drawn from the ear vein 3, 5, 7 days after steroid administration in the acute experiment. In the chronic experiment, blood samples were drawn after six weeks. For examination of two important oxidative stress markers, reduce glutathione (GSH) that was determined according to Beutler *et al.* [13] and malondialdehyde MDA concentration was determined according to the method described by Ohkawa *et al.* [14].

Histopathological examination

Tissue specimens were collected from femur shaft and fixed in 10% buffered neutral

formalin and decalcified. Paraffin sections of 5 micron thick were prepared and stained with hematoxylin and eosin stain [15] and examined microscopically.

Immunohistochemical study

The standard immunohistochemical methods were adopted [16], the tissue sections were routinely microwave-treated to unmistakably the epitopes of antigen [17]. The demonstration of antigen in tissues by immunostaining is a two-step process. The first step is binding of the primary antibody to the related antigen the used primary antibody for calcitonine is rabbit polyclonal anticalcitonine antibody Ab11042, The primary antibody for caspase3 is anticaspase3 antibody AAb4051, and the primary antibody for NF- KB is rabbit monoclonal{E379} antiNF-KB65 antibody {Ab32536}, Abcam, Cambridge CB40FL,UK, followed by visualization of this reaction by a secondary or link antibody to which they are attached to different enzyme systems, collectively known as the universal. The primary antibody determines the specificity of the reaction; whereas, the secondary antibody, with its linked enzyme, causes amplification of the reaction, hence, increases the sensitivity of the test. The Biotin-Streptavidin (BSA) system was used to visualize the markers [18]. Diaminobenzidine (DAB) was used as chromogen since it allows a permanent preparation. Hematoxylin counterstain was done for detection of examined calcitonin marker, Caspase 3 marker and (NF- KB) marker

Statistical analysis

Statistical analysis was carried out by SPSS 16 (SPSS, Chicago, III) program for windows. Data are expressed as mean \pm SD. In

the acute model, the effect of methylprednisolone (20 mg/kg) and/or supplemented with ginseng on level of MDA and GSH for 3, 5 & 7 days was tested by two way repeated measure ANOVA (P value < 0.01). The differences between means were determined by Duncan's Multiple Range Test. In the chronic experiment, the data were analyzed by One Way ANOVA, the differences between means were determined by Duncan's Multiple Range Test and the differences were considered significant at P<0.01.

Results

Biochemical Findings

In the acute model, the steroid exposed rabbits at group (S) showed non-significant changes at their oxidant and antioxidant status at 3rd day post treatments when compared by control group, but they showed a significant increase in serum MDA with significant decrease in GSH at the 5th and 7th days (Table 1). These changes reached the peak at the day 7th after dosing. Rabbits of group (G+ S) showed significant improvement but not reach the normal values at the control group. Control group and ginseng showed no oxidative stress. However, in the chronic experiment steroid exposed rabbits at group (S) showed significant increase in serum MDA (20.28 \pm 1.44) and significant decrease in serum GSH (0.69 \pm 0.03) when compared with control group (11.26 \pm 0.57) and (1.22 \pm 0.03) respectively. In-group (S+G) showed significant decrease in MDA level (15.5 \pm 2.37) when compared by control but not reach the normal value and GSH level showed slightly improvement (0.95 \pm 0.03), group (G) showed no oxidative status.

Table (1): Effect of methylprednisolone (20 mg/kg) and/or ginseng on oxidative stress (Malondialdehyde, MDA) and antioxidant (Reduced glutathione, GSH) in rabbits (acute trial)

Groups	3 rd day		5 th day		7 th day	
	MDA (nmol/ml)	GSH (mmol/L)	MDA (nmol/ml)	GSH (mmol/L)	MDA (nmol/ml)	GSH (mmol/L)
Control	11.32 \pm 1.3 ^d	1.23 \pm 0.031 ^e	10.826 \pm 0.97 ^d	1.36 \pm 0.04 ^e	11.21 \pm 0.48 ^d	1.336 \pm 0.08 ^e
Steroid	24.53 \pm 6.76 ^b	0.71 \pm 0.041 ^e	39.775 \pm 1.72 ^a	0.369 \pm 0.036 ^e	40.01 \pm 1.81 ^a	0.373 \pm 0.04 ^e
S + G	18 \pm 2.64 ^c	0.973 \pm 0.05 ^e	19.85 \pm 1.52 ^c	0.578 \pm 0.066 ^e	20.37 \pm 1.12 ^c	0.57 \pm 0.06 ^e
Ginseng	10.98 \pm 1.62 ^d	1.27 \pm 0.09 ^e	11.1 \pm 1.192 ^d	1.36 \pm 0.103 ^e	11.37 \pm 0.94 ^d	1.345 \pm 0.08 ^e

Different letters in the same column indicate significant changes (P < 0.01). (S+G): Steroid + Ginseng group

Histopathological Findings

In the acute experiment, group (S) showed osteodystrophic changes, dilatation of Haversian canals and early osteoporotic reactions, osteocytes apoptosis and necrosis and matrix resorption, these changes have been significantly improved in group (S+G) . Figure (1; A-H).

However, In the chronic experiment, group (S) showed sever marked osteoporotic

lesions beside bone demineralization and increase the hyaluronic matrix, the bone marrow showed marked hypocellularity with apoptotic changes and these changes have been significantly improved in group (S+G) as showed in Figure (1 ; I-T).

Immunohistochemical

Calcitonin, Caspase 3 and (NF- κ B) were investigated in collected bone tissues of different rabbit groups under experimentation.

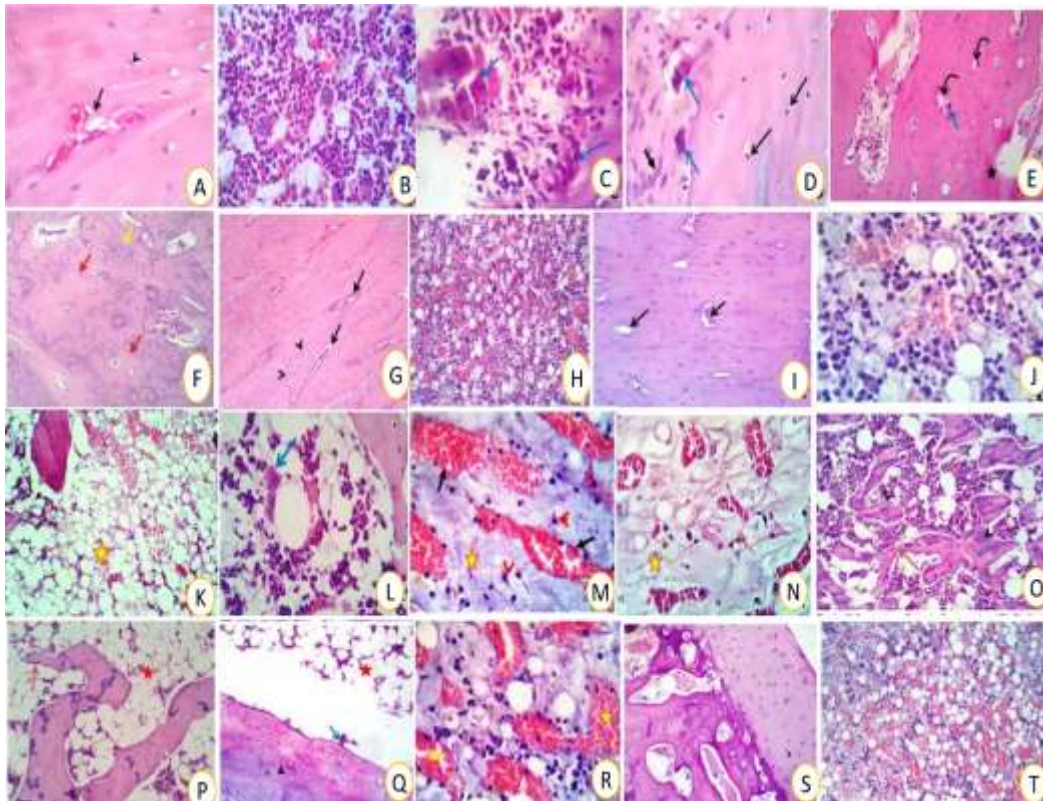


Figure 1: Histopathological effects of methylprednisolone and/or ginseng in rabbits; Photomicrograph of bone tissue (femur) in acute treated rabbits: A and B; control group showing normal lameller structures and normal osteocytes (arrow head), normal haversion canals (open arrow) and apparently normal bone marrow (B), in steroid treated group (C, D) increase activity of the osteoclasts (blue arrows) especially around the necrotic areas. Some sections showing multifocal osteoporotic lesions with bone rarefaction and cavities formation with reactive osteoclasts (blue arrows) at the affected areas, in steroid ginseng treated group (E&F) showing proliferative reaction, multifocal osteoporotic changes (curved arrows) with degenerated (open arrow) or necrotic osteocytes (star). Other sections showing early osteoporosis in different parts of the shaft with presence reactive osteoclasts (blue arrow) in addition to osteodystrophic changes (closed arrow). Ginseng group (G) showing healthy bony structures of the femur shaft with preserved nuclear and lacunar parts of the osteocytes (arrow heads), good lameller formation, normal canals and endo-osteocytic lining of the haversion canals (open arrows) beside apparently normal bone marrow (H). H&E X 400. Chronic experiment;(I:T) in control group (I &J) showing healthy lameller bony structures , osteocytes (arrow heads) and haversion canals (open arrows), in steroid group(K,L,M and N) necrotic and osteoporotic changes with activation of the endosteal osteoblasts (blue arrows) and demineralization with increase in the hyaluoronic matrix which appeared deep bluish (red arrows). The bone marrow showing hypocellularity (yellow stars) with apoptotic changes (red arrow heads) in the hemopiotic series and dilated marrow sinusoids (closed arrows), steroid and ginseng group (O,P,Q and R) The intercortical marrow spaces showing moderately dilated sinusoids (yellow stars) with hypocellular marrow cells (red star) with presence of apoptotic hemopiotic cells specially megakaryocytes series (closed arrow). Bone tissue of some sections showing osteonecrotic and osteoporotic changes with osteoclastic activity (blue arrow) and thinning of the bone trabeculae (brown arrow), ginseng group (S &T) showing healthy lameller bone structures , osteocytes and haversion canals beside apparently normal bone marrow sometime with active dilated sinusoids and capillaries.H&EX400.

Calcitonin

In the group exposed to glucocorticoids (S) group in the acute experiment showed mild activated calcitonin with few bone marrow reactive cells Figure (2; C and D). However, GC and ginseng (G+S), in both acute and chronic models; a few calcitonin positive cells with slightly resorbed bone

matrix were observed Figure 2; G and H, also (S) group in chronic showed many reactive calcitonin positive osteoclasts cells and a few positive osteoblasts (Figure 2; E and F). As in control and ginseng treated group revealed negative reactivity to the osteoclastic binding calcitonin showed in Figure (2; I and J).

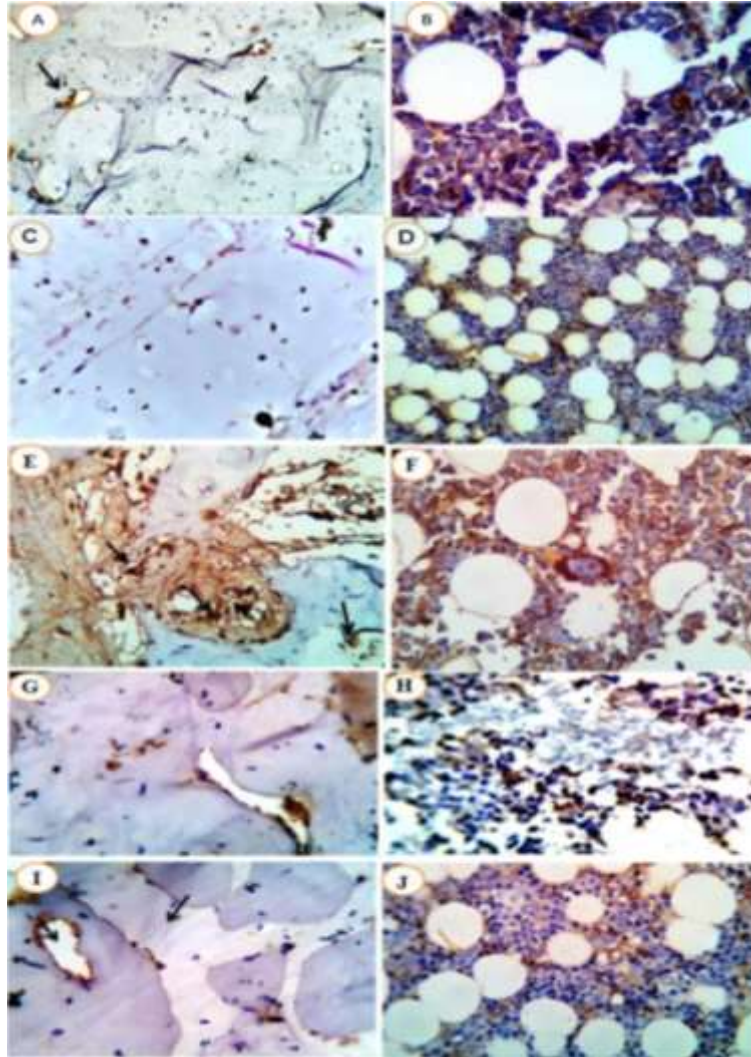


Figure .2: Detection of calcitonin in acute and chronic methylprednisolone of and /or treatment with ginseng in rabbits: Photomicrograph from shaft of long bone (femur) (A) and bone marrow (B) of normal control group showing, negative reactivity to the osteoclastic-binding calcitonin marker (A black arrows, B orange arrow). Shaft of long bone (femur) (C) and bone marrow (D) of steroid-treated rabbits (acute toxicity) showing mild osteoporotic changes, rimmed by some activated positively stained osteoblasts and osteoclast-looking cells for calcitonin. The bone marrow shows a few reactive cells (orange arrows), shaft of long bone (femur) (E) bone marrow (F) of steroid-treated rabbits (chronic toxicity) showing, many reactive calcitonin positive osteoclasts cells and a few positive osteoblasts. The bone marrow shows mild to moderate hypocellularity with many reactive hemopoietic stem cell, immature and mature series, some of them showing reactive positive stainability to calcitonin, in particular megakaryocytes, lymphocytes, monocytes and plasma cells. (E black arrow and F orange arrows), shaft of long bone (femur) (G) and bone marrow (H), of steroid-ginseng treated rabbits showing a few calcitonin positive cells, located at the margin of a slightly dilated haversian canal, with a surrounding slightly resorbed bone matrix. The bone marrow shows some of the actively cellular marrow cells, mainly monocytes and lymphocytes, positively stained for calcitonin. (Orange arrow). shaft of long bone (femur) (I) and bone marrow (J), of ginseng treated group showing negative reactivity to the osteoclastic-binding calcitonin marker (I black arrows and J orange arrow) X 400.

Apoptotic Marker Caspase 3

Group (S+G) in acute experiment showed mild osteoporotic reactions and few apoptotic changes Figure (3; E and F). The chronic experiment showed moderate number of osteocytes and positive apoptotic signals Figure (3; G&H). While group (S) in acute

experiment revealed moderately up regulation apoptotic changes (Figure 3-B), and in chronic experiment the osteoporotic reactions were severe (Figure 3-D). In control and ginseng groups, revealed normal structures free from the apoptotic marker caspase 3 (Figure 3-A).

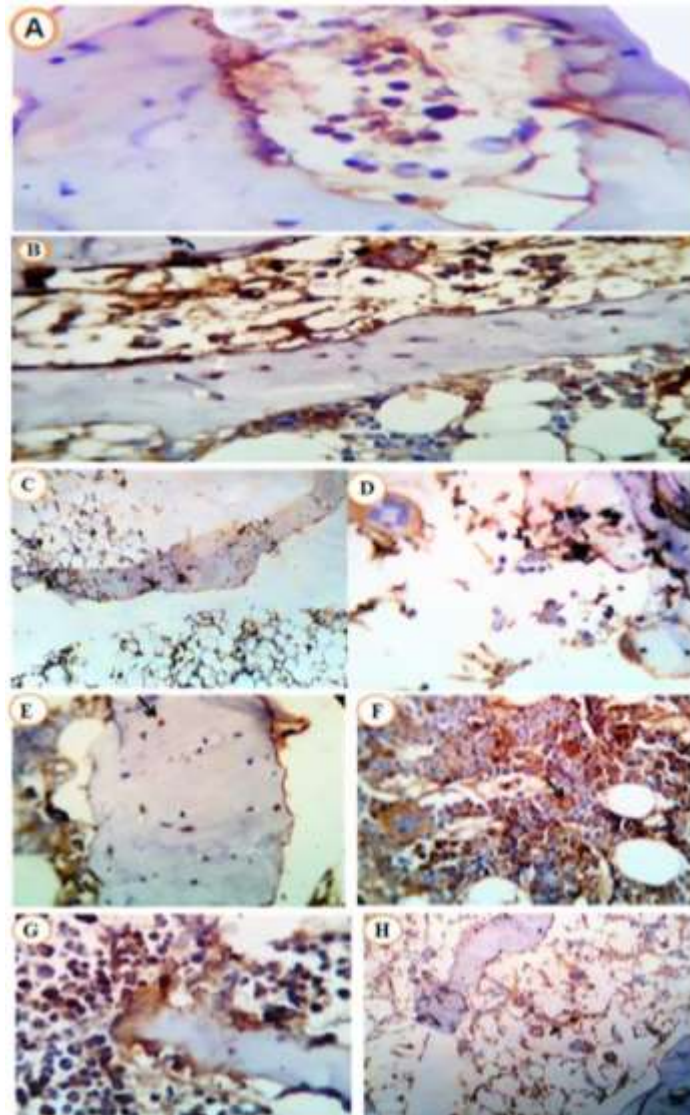


Figure 3: Demonstration of caspase acute and chronic in methylprednisolone of and /or treatment with ginseng in rabbits: Photomicrograph from shaft of long bone (femur) (A), showing apparently normal structures free from the apoptotic marker caspase 3 stainability. (B) shaft of long bone (femur) of steroid -treated rabbits (acute toxicity), showing apoptotic changes in a variable number of cells as seen by the positively stained osteocytes and bone marrow cells. (white arrows), long bone (femur)(C) and bone marrow (D) of steroid -treated rabbits (chronic toxicity) showing outstanding apoptotic caspase 3 reactivity in many of the bone cells of the lamallae and marrow cells respectively. (Orange arrows), shaft of long bone (femur) (E) and bone marrow (F) OF Steroid-Ginseng treated group. (Acute toxicity) showing, a few apoptotic changes in the bone lamellae as seen by the apoptotic marker caspase 3. Similarly, the bone marrow appeared highly reactive, normal cellular with presence of a few apoptotic cells. (Black arrows), shaft of long bone (femur) (G) and bone marrow (H)of Steroid-Ginseng treated group. (Chronic – toxicity) showing, moderate number of the osteocytes of the lamellar bone with a positive apoptotic signals as demarcated by the apoptotic marker caspase 3. The bone marrow appears either mildly or moderately hypocellular with an increased number of apoptotic cells. (Orange arrows).in Ginseng treated group, Lesions in this group are comparable to the control free one with normal lamellar bone and the corresponding bone marrow with apparently normal structures free from any apoptotic marker caspase 3 stainability. X 400.

*Nuclear Factor Kappa –Light-Chain –
Enhancer Of Activated B Cells (NF- κB)*

In (S+G) treated group of acute experiment a few to moderate positive nuclear and cytoplasmic reactivates to the NF- κB 9 (Figure 4; G-H). While in (S+ G) group of chronic experiment revealed large number of cells of both bone and bone marrow with positive nuclear and cytoplasmic reactivates to

NF- κB (Figure 4; I-J). The (S) group in acute experiment revealed strong positive reactivates (Figure 4; C-D). While in chronic experiment bone tissue revealed very strong positive reactions of both bone and bone marrow (Figure 4; E-F). The control and ginseng groups revealed normal structures free from the pro-inflammatory marker NF- κB (Figure 4; K-L).

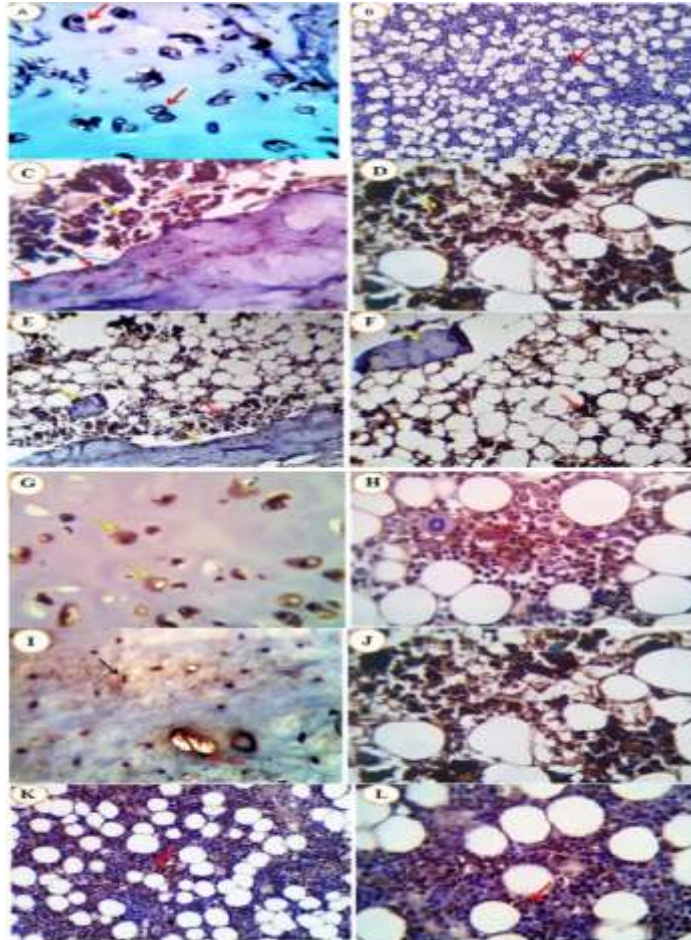


Figure 4: NF-κB (acute and chronic) Photomicrograph from cortical bone of (femur) (A) and bone marrow (B) of normal control rabbits showing apparently normal structures free from the pro-inflammatory bio-marker - NF-κB cytoplasmic and or nuclear stainability. Photomicrograph from lamellar bone (C) and bone marrow (D) of steroid -treated rabbits (acute toxicity) large number of cells showing positive nuclear and cytoplasmic reactivates to the pro-inflammatory marker NF-κB(C, D yellow arrows). Positive osteoclasts are seen (C, blue circle and red arrows), Photomicrograph from lamellar and trabecular bone (E, F) and bone marrow (E,F) of steroid -treated rabbits (chronic toxicity). large number of cells showing very positive nuclear and cytoplasmic reactivates to the pro-inflammatory marker NF-κB (E, F lamellar and trabecular bone, yellow arrows) and bone marrow cells (E, F red arrows). Photomicrograph from cortical bone (G) and bone marrow (H) of steroid -ginseng treated rabbits (acute toxicity) showing few to moderate number of cells showing positive nuclear and cytoplasmic reactivates to the pro-inflammatory marker NF-κB (G,H, yellow and red arrows). Photomicrograph from cortical bone (I) and bone marrow (J) of steroid -ginseng treated rabbits (chronic toxicity) large number of cells showing positive nuclear and cytoplasmic reactivates to the pro-inflammatory marker NF-κB (I,J, black, red and blue arrows). Photomicrograph from bone marrow (K,L) of ginseng- treated rabbits showing apparently normal structures free from the pro-inflammatory bio-marker - NF-κB cytoplasmic and or nuclear stain ability except for a few cells with non specific brownish reactivities (red arrows).X 400.

Discussion

It is extremely intriguing to mention that corticosteroids associated oxidative stress have a very important role in the development of osteoporosis, osteonecrosis and apoptosis [19] soon after administration of steroid ROS generation that make dysregulation of many physiological process [20] resulting in endothelial dysfunction and cardiovascular senescence [21]. Osteoporosis; rapid outset of fragility fractures and bone loss, is a frequent and severe complication of systemic glucocorticoid's therapy [22]. In the current study, a significant inhibition of GSH with a marked elevation of MDA, in response to methylprednisolone given at a single dose of 20 mg/kg and chronically administered for six weeks once a week of methylprednisolone 4mg/kg. In the acute experiment, group (S), which showed osteodystrophic changes, dilatation of Haversian canals and early osteoporotic reactions, osteocytes apoptosis and necrosis and matrix resorption, these changes have significantly improved in group (S+G).

In Chronic experiment, group (S) showed sever marked osteoporotic lesions beside bone demineralization and increase the hyaluronic matrix, the bone marrow showed marked hypocellularity with apoptotic changes and these changes have significantly improved in group (S+G). It has been found that corticosteroid therapy decreased the cellular antioxidant capacity by suppressing nuclear factor erythroid 2 - related factor 2 which regulates the antioxidant defense system by inducing expression of antioxidant response element-dependent genes [23]. In (S+G) group in acute toxicity showed a few to moderate positive nuclear and cytoplasmic reactivates to the NF- κ B, while in chronic toxicity revealed large number of cells of both bone and bone marrow with positive nuclear and cytoplasmic reactivates to NF- κ B. In (S) group in acute toxicity, revealed strong positive reactivates while in chronic toxicity revealed very strong positive reactivates of both bone and bone marrow. The control and ginseng groups revealed normal structures free from the pro-inflammatory marker NF- κ B.

Glucocorticoid- mediated gene activation is obviously an essential component of the apoptotic pathway; the downstream steps are a matter of debate. In this process there are two classical apoptotic pathways, Bcl-2 and caspases are involved [24]. This cell death is accompanied with mitochondrial depolarization, cleavage of nuclear chromatin, cytochrome C extraction and activation of caspase 9. Inhibitors of caspase activity blocked apoptotic cell death [25].

It is now hold that oxidants may be vital biochemical intermediates in the progression of many forms of apoptosis induced by different stimuli-oxidative stress induced apoptosis is a result of alterations of various metabolic pathways ending in the loss of ATP and calcium hemostasis, DNA damage and structural as well as functional modification of some proteins. This kind of apoptosis involves of interplay of some genes such as Bcl2, p53 and c-mye that regulate oxidative stress induced apoptosis [26]. In the current study, it has been unequivocally revealed that administration of methylprednisolone causes mild osteoporotic reactions and moderately up regulation apoptotic changes as seen by the apoptotic marker caspase 3. As well as the bone marrow appeared highly reactive with presence of apoptotic cells. The (S+G) group showed marked improvement.

For six weeks (chronic) remarkable changes are seen as the osteoporotic reaction were severe, denoted by the empty bone cavities and the thinner bone lamellae and the apoptotic caspase 3 reactivity and the (S+G) treated group showed marked improvement. Reactive oxygen or nitrogen species (ROS/RNS) can evoke cell death by necrosis or apoptosis through a mechanism that lead to or regulate apoptosis including caspase activation, receptor activation, Bcl-2 family proteins and mitochondrial dysfunction. Various protein kinases activities, including mitogen activated protein kinases; protein kinases B/C and inhibitor of 1- Kappa B kinases regulate the apoptotic program. In recent years, lipid derived mediators have protrude as potential intermediates in the pathway of apoptosis initiated by oxidants [27].

Glucocorticoids have direct and indirect effects on bone remodeling. Bone loss results from increase in expression of receptor activation of nucleic factor- $\kappa\beta$ ligand, which leads to increase in the number of bone resorbing osteoclasts. Osteocyte apoptosis induce oestolysis, which results in an early bone loss [28].

Glucocorticoids induce passionate effects on bone cell function, replication, and differentiation. The steroids enhance bone resorption throw stimulation of osteoclastogenesis by increasing the expression of RANK ligand and decreasing the expression of its decay receptor-ostotoprotegerin. Glucocorticoids also encourage the expression of collagenase 3 by posttranscriptional mechanisms. The reduce in osteoblast number is secondary to a decrease in osteoblastic cell replication and differentiation, and an increase in the apoptosis of mature osteoblasts [29].

Glucocorticoids prolong the life of mature osteoclasts and decrease the bone remodeling throw depleting the population of osteoblast. This happened by a decrease in osteoblastogenesis and an increase in the apoptosis of mature osteocytes and osteoblasts [30]. Although the pathogenesis of osteonecrosis is not completely clear, various theories demonstrate the underlying mechanisms; increased pressure in intra-osseous, osteocytes fatty degeneration, fat embolism and extra-osseous arterial occlusion, coagulation abnormalities and hyperlipidemia [31]. Osteonecrosis is defined as a clinical disease characterized by death of osteocytes and the bone marrow, followed by necrotic tissues resorption and formation new osseous tissues but weaker leading to a progressive destruction of bone architecture, subchondral fracture and collapse of joints, which occur mostly at the femoral head [32].

Strikingly, in the current inquiry, it has been unequivocally revealed that corticosteroid- induced osteonecrosis and osteoporosis were significantly quelled in response to co-administration of the classical antioxidant; ginseng. It has been proved that, by raising the antioxidant enzymes activities and reducing excessive generation of ROS.

Panax ginseng could adjust the imbalance of oxidation-reduction and blockss further injury on necrotic bone tissues, thus demonstrating a protective role on early steroid-induced osteonecrosis of rabbit femoral head [33].

In summary, the ginseng can significantly decrease the incidence of osteoporosis and osteonecrosis and improve the apoptotic changes in the steroid-treated animal models as rabbit. The oxidative stress is inhibited and the vascular endothelial dysfunction is ameliorated. The precise mechanism still requires a further *in vivo* study.

Conclusion

In conclusion, the finding of the present study showed that steroid-associated oxidative injury has a critical role in the progress of OP, ON and apoptosis. Ginseng, as a natural, free radical scavenger can significantly suppress the development of this illness.

Conflict of Interest: None of the authors have any conflict of interest to declare.

Acknowledgement

Thanks are extended to Prof. Dr. El-Sayed AL-Attar, Professor of Pathology, Faculty of Veterinary Medicine, Zagazig University., Prof. Dr. Khalifa E. Ahmed, Professor of Biochemistry, Faculty of Veterinary Medicine, Zagazig University, Prof. Dr. Mohamed M.M. Metwally, Professor of Pathology, Faculty of Veterinary Medicine, Zagazig University. The authors are also grateful to Dr. Amany I. Ahmed, Lecturer of Biochemistry, Faculty of Veterinary Medicine, Zagazig University.

References

- [1] Coutinho, A.E. and Chapman, K.E. (2011): The anti-inflammatory and immunosuppressive effects of glucocorticoids, recent developments and mechanistic insights. *Mol Cell Endocrinol*, 335 (1): 2-13.
- [2] Advani, S.; LaFrancis, D.; Bogdanovic, E.; Taxel, P.; Raisz, L.; and Kream, B.; (1997): Dexamethasone suppresses *in vivo* levels of bone collagen synthesis in neonatal mice. *Bone* 20 (1): 41-46.
- [3] Zalavras, C.; Shah, S.; Birnbaum, M.J. and Frenkel, B.; (2003): Role of apoptosis in glucocorticoid-induced osteoporosis and osteonecrosis. *Crit Rev Eukaryot Gene*

- Expr 13: 221-235.
- [4] Weinstein, R.S.; Jilka, R.L.; Parfitt, A.M. and Manolagas, S.C.; (1998): Inhibition of osteoblastogenesis and promotion of apoptosis of osteoblasts and osteocytes by glucocorticoids. Potential mechanisms of their deleterious effects on bone. *J Clin Invest*, 102: 274-282.
- [5] Gohel, A.; McCarthy, M.-B. and Gronowicz, G.; (1999): Estrogen prevents glucocorticoid-induced apoptosis in osteoblasts in vivo and in vitro. *Endocrinology* 140 (11): 5339-5347.
- [6] Buttgereit, F.; Burmester, G.-R. and Lipworth, B.J.; (2005) Optimised glucocorticoid therapy: the sharpening of an old spear. *The Lancet* 365 (9461): 801-803.
- [7] Kim, D.-H. (2012): Chemical diversity of *Panax ginseng*, *Panax quinquefolium*, and *Panax notoginseng*. *J Ginseng Res*, 36 (1): 1-15.
- [8] Kim, H.-G.; Yoo, S.-R.; Park, H.-J.; Lee, N.-H.; Shin, J.-W.; Sathyanath, R., Cho, J.-H. and Son, C.-G., 2011. Antioxidant effects of *Panax ginseng* CA Meyer in healthy subjects: a randomized, placebo-controlled clinical trial. *Food Chem Toxicol*, 49 (9): 2235-2229.
- [9] Siddiqi, M.H.; Siddiqi, M.Z.; Ahn, S.; Kang, S.; Kim, Y.-J.; Sathishkumar, N.; Yang, D.-U. and Yang, D.-C.; (2013): Ginseng saponins and the treatment of osteoporosis: mini literature review. *J Ginseng Res*, 37(3): 261-268.
- [10] Shah, Z.A.; Gilani, R.A.; Sharma, P. and Vohora, S.B.; (2005): Cerebroprotective effect of Korean ginseng tea against global and focal models of ischemia in rats. *J Ethnopharmacol*, 101(1-3): 299-307.
- [11] Kiefer, D. and Pantuso, T.; (2003): *Panax ginseng*. *Am Fam Physician*, 68(8): 1539-1542.
- [12] Paget, G. and Barnes, J. (1964): Interspecies dosage conversion scheme in evaluation of results and quantitative application in different species. *Evaluation of drug activities: pharmacometrics* 1, 160-162.
- [13] Beutler, E. and Kelly, B.M. (1963): The effect of sodium nitrite on red cell GSH. *Experientia*, 19(2): 96-97.
- [14] Ohkawa, H.; Ohishi, N. and Yagi, K (1979): Assay for lipid peroxides in animal tissues by thiobarbituric acid reaction. *Anal Biochem*, 95(2): 351-358.
- [15] Bancroft, J. D.; and Gamble, M. (2008): *Theory and practice of histological techniques*. Elsevier health sciences.
- [16] Eissa, S.; and Shoman, S. (1998): *Tumor markers*. A Hodder Arnold Publication.
- [17] Cattoretti, G.; Becker, M. H.; Key, G.; Duchrow, M.; Schlüuter, C.; Galle, J.; and Gerdes, J. (1992): Monoclonal antibodies against recombinant parts of the Ki- 67 antigen (MIB 1 and MIB 3) detect proliferating cells in microwave- processed formalin- fixed paraffin sections. *J Pathol*, 168(4): 357-363.
- [18] Hsu, S. M.; Raine, L.; and Fanger, H. X. (1981): Use of avidin-biotin-peroxidase complex (ABC) in immunoperoxidase techniques: a comparison between ABC and unlabeled antibody (PAP) procedures. *J Histochem Cytochem*, 29(4): 577-580.
- [19] Kerachian, M.A.; Harvey, E.J.; Cournoyer, D.; Chow, T.Y. and Séguin, C. (2006): Avascular necrosis of the femoral head: vascular hypotheses. *Endothelium* 13(4): 237-244.
- [20] Ogihara, T.; Asano, T.; Katagiri, H.; Sakoda, H.; Anai, M.; Shojima, N.; Ono, H.; Fujishiro, M.; Kushiyama, A. and Fukushima, Y. (2004): Oxidative stress induces insulin resistance by activating the nuclear factor- κ B pathway and disrupting normal subcellular distribution of phosphatidylinositol 3-kinase. *Diabetologia* 47(5): 794-805.
- [21] Smith, L.K. and Cidlowski, J.A. (2010): Glucocorticoid-induced apoptosis of healthy and malignant lymphocytes. *Prog Brain Res*, 182: 1-30.
- [22] Xia, X.G.; Schmidt, N.; Teismann, P.; Ferger, B. and Schulz, J.B. (2001): Dopamine mediates striatal malonate toxicity via dopamine transporter- dependent generation of reactive oxygen species and D2 but not D1 receptor activation. *J Neurochem*, 79(1): 63-70.
- [23] Chrysis, D.; Zaman, F.; Chagin, A.S.; Takigawa, M. and Sävendahl, L. (2005):

- Dexamethasone induces apoptosis in proliferative chondrocytes through activation of caspases and suppression of the Akt-phosphatidylinositol 3'-kinase signaling pathway. *Endocrinology* 146(3): 1391-1397.
- [24] Dalle Carbonare, L.; Bertoldo, F.; Valenti, M.; Zenari, S.; Zanatta, M.; Sella, S.; Giannini, S. and Cascio, V.L. (2005): Histomorphometric analysis of glucocorticoid-induced osteoporosis. *Micron* 36(7-8): 645-652.
- [25] Bouvard, B.; Audran, M.; Legrand, E. and Chappard, D. (2009): Ultrastructural characteristics of glucocorticoid-induced osteoporosis. *Osteoporos Int*, 20(6): 1089-1092.
- [26] Sinha, K.; Das, J.; Pal, P.B. and Sil, P.C. (2013): Oxidative stress: the mitochondria-dependent and mitochondria-independent pathways of apoptosis. *Arch Toxicol*, 87(7), 1157-1180.
- [27] Buehring, B.; Viswanathan, R.; Binkley, N. and Busse, W. (2013): Glucocorticoid-induced osteoporosis: an update on effects and management. *J Allergy Clin Immunol*, 132 (5): 1019-1030.
- [28] Glueck, C.J.; Freiberg, R.A.; Fontaine, R.N.; Tracy, T. and Wang, P. (2001): Hypofibrinolysis, thrombophilia, osteonecrosis. *Clin Orthop Relat Res*, 386, 19-33.
- [29] Miyaniishi, K.; Yamamoto, T.; Irida, T.; Yamashita, A.; Jingushi, S.; Noguchi, Y. and Iwamoto, Y. (2002): Bone marrow fat cell enlargement and a rise in intraosseous pressure in steroid-treated rabbits with osteonecrosis. *Bone* 30(1): 185-190.
- [30] Pietrogrande, V. (1957): Osteopatia da prolungato trattamento cortisonico. *Ortop. Traum Appar Mot* 25: 791-810.
- [31] Qiang, H.; Liu, H.; Ling, M.; Wang, K. and Zhang, C. (2015): Early steroid-induced osteonecrosis of rabbit femoral head and *Panax notoginseng* saponins: mechanism and protective effects. *Evid Based Complement Alternat Med*, 2015: 10.
- [32] Merali, S.; Binns, S.; Paulin-Levasseur, M.; Ficker, C.; Smith, M.; Baum, B.; Brovelli, E. and Arnason, J. (2003): Antifungal and anti-inflammatory activity of the genus *Echinacea*. *Pharm Biol*, 41(6): 412-420.
- [33] Wang, X.; Wu, Q.; Wan, D.; Liu, Q.; Chen, D.; Liu, Z. and Yuan, Z. (2016): Fumonisin: oxidative stress-mediated toxicity and metabolism *in vivo* and *in vitro*. *Archives of toxicology*, 90(1), 81-101.

الملخص العربي

نخر وهشاشة العظام الناشئة عن الكورتيكوستيرويدات : ودور الأجهاد التأكسدي

ريهام حسن عبدالحميد العطار^١, عبدالعليم فؤاد عبدالعليم^٢, صبري محمد علي عبدالمتعال^٢, سيد احمد عبد العزيز^٢
^١مستشفى الطلبة - جامعة الزقازيق - مصر

^٢قسم الفارماكولوجيا-كلية الطب البيطري- جامعة الزقازيق- مصر

تستخدم الجلوكوكورتيكويد في العديد من البروتوكولات العلاجية الكيميائية وتلعب دوراً هاماً في إعادة تشكيل العظام ولكن الاستخدام طويل المدى يصاحبه الإجهاد التأكسدي مما يؤدي إلى الإصابة بنخر وهشاشة العظام وموت وتدمير الخلايا. تهدف هذه الدراسة إلى دراسة تأثير الجنس كمضاد للتأكسد طبيعي في التغلب على التغيرات العظمية الناتجة من الكورتيزونات. وذلك باستخدام أربعين أرنب نيوزيلاندي أبيض ذكر بالغ يتم تقسيمها كالتالي المجموعة الأولى مجموعة ضابطة، المجموعة الثانية تم حقنها بالكورتيزون، المجموعة الثالثة تم حقنها بالكورتيزون + الجنس بالفم، (١٠) أخذت جنس بالفم فقط. تم عمل تجربتين منفصلتين، الأولى مثال للحالة الحادة: بجرعة كرتيزون ٢٠ ملجم/ كجم تم حقنها بعضلة الفخذ العليا مرة واحدة فالأسبوع لمدة أسبوع واحد مع أخذ الجنس يومياً بجرعة ١٤ ملجم/ كجم بالفم. والتجربة الثانية للحالة المزمنة: بجرعة كرتيزون ٤ ملجم/ كجم تم حقنها بعضلة الفخذ العليا مرة واحدة فالأسبوع لمدة ستة أسابيع مع أخذ الجنس يومياً لمدة ستة أسابيع بجرعة ١٤ ملجم/ كجم بالفم. وتم قياس مستويات الدم من الجلوتاثيون المختزل والمالوندهيد لقياس مدى الأجهاد التأكسدي ووجود أو عدم وجود نخر وهشاشة العظام والجلطات التي تتكون داخل الأوعية يتم فحصها (هيسيتوبولوجيكال) بالفحص المجهرى و (الايمنونوهيستوكيميائي) باستخدام كاسباس ٣، كالتيتونين، NFκβ. دراسة الكيمياء الحيوية تعكس زيادة كبيرة معنوية في مستويات الدم من الجلوتاثيون المختزل وانخفاض كبير معنوي في المالوندهيد باستخدام الجنس مقارنة بالكورتيزون في التجربة الحادة والمزمنة وبالنسبة للمجموعة التي أخذتهم معاً (الكورتيزون + الجنس) حافظت على الكثير من خصائصها بالمقارنة بمجموعة الكورتيزونات التي أصابها كثير من التغير العظمى. والخلاصة أن الجنس مضاد للتأكسد فريد له تأثير كبير في التقليل من التغيرات العظمية الناتجة عن الكورتيزونات.