

MAXILLARY SYMMETRY, MANDIBULAR SYMMETRY AND CONDYLAR POSITION IN FUNCTIONAL UNILATERAL POSTERIOR CROSS BITE PATIENTS

Ahmed M. Madian¹, Nadia M. El-Harouni²,
Essam M. Abdallah²

ABSTRACT:

Objective: To investigate mandibular symmetry, maxillary symmetry and condylar position in patients with functional unilateral posterior crossbite (FUPXB) using Multi-slice computed tomography (MSCT). **Materials and Methods:** 15 patients (mean age 13 ± 3 years) with FUPXB underwent MSCT scans. Skeletal and dental measurements were taken to assess mandibular and maxillary symmetry. Medial and Lateral Joint spaces were compared between normal and crossbite sides in those patients. **Results:** There were no statistically significant differences between crossbite and normal sides regarding skeletal and dental mandibular and maxillary measurements and regarding condylar position. **Conclusions:** patients with FUPXB showed mandibular and maxillary symmetry. Those patients revealed symmetric condylar position between normal and crossbite sides.

INTRODUCTION

Posterior crossbite is not an uncommon type of malocclusion as it has a prevalence of 7% to 23% among malocclusions in the deciduous and mixed dentitions⁽¹⁻⁹⁾. Posterior crossbite can involve 1 tooth or a group of teeth, It can be either unilateral or bilateral and either have a skeletal or

1- Assistant Lecturer, Department of Orthodontics, Faculty of Dentistry, Alexandria University.

2- Professor, Department of Orthodontics, Faculty of Dentistry, Alexandria University.

dento-alveolar origin⁽¹⁰⁾. The most common form of posterior crossbite is a unilateral presentation, with a functional shift of the mandible toward the crossbite side⁽¹¹⁾. This is known as functional unilateral posterior crossbite (FUPXB)⁽¹⁰⁾. The association between FUPXB and asymmetrical condyle position within the glenoid fossa is a subject of continuous debate and also the presence of an asymmetric condyle position within the glenoid fossa met interest in the literature. Some suggested that FUPXB may result in right to left side differences in the condyle fossa relationships which results in temporo-mandibular joint (TMJ) disc displacement and internal derangement⁽¹²⁾.

The development of computerized tomography (CT) has, to some extent, helped to reach the proper investigation of the effect of FUPXB on condyle-fossa relationships with higher accuracy^(13,14) to overcome the methodological drawbacks of previous techniques. Our purpose is to test the null hypothesis that: (1) There is no mandibular asymmetry in FUPXB patients. (2) There is no maxillary asymmetry in FUPXB patients. (3) There is no difference in the condylar position between the crossbite and normal sides in FUPXB patients.

MATERIALS AND METHODS

Subjects:

15 patients were selected from those attending the department of Orthodontics, Faculty of Dentistry, Alexandria University. [the number of patients was determined according to the equation using the Larry Connors method]. Patients included were selected by having Functional Unilateral Posterior Crossbite (FUPXB) which was diagnosed by a crossbite on one side only (unilateral), mandibular midline was shifted toward the crossbite side at the maximum intercuspal position and not in the mouth opening. The mandibular midline shift was 2 ± 1 mm. The Age range was from 10-16 years. Patients with craniofacial deformities involving condyles and/or mandible or chronic systemic diseases affecting bone or teeth or history of orthodontic treatment were excluded from the study. Full extra-oral and intra-oral examinations were done and a complete set of records including photographs and dental casts were taken. All subjects signed an informed consent before participation in the research and the ethical committee approval was granted to conduct the study.

Methods:

Axial scans with the scan field starting caudally from the lower most aspect of the mandible up to the level of the superior orbital margin so as to include the whole mandible, maxilla, TMJ and orbital bones were obtained using 8 slice GE, lightspeed (General Electric, USA) scanner. with Scan parameters: 200 mAs, 120 KVP, 0.6 s/rot, 0.625 mm slice thickness, zero interval. Patients were instructed to lie in a supine position in maximum dental intercuspation during the examination and not to move during the CT examination. The images were taken in 0.65 mm thickness and the data were transferred to workstation (GE, advantage 4.4) for manipulation of data with dedicated software for 3D.Reconstructions were then done in both soft and high resolution volumes then sent to the workstations where multiplanner and 3D reconstructions were done using dedicated dental software.

The following measurements were taken:

- (1) Maxillary Measurements: [these measurements were performed on the right and left sides on the coronal cuts to show symmetry]
 - A. Skeletal Measurements : (fig.1)(this coronal cut was showing the two palatine foraminae) Maxillary width, parallel to the lower border of the hard palate and tangent to the nasal floor, extended from the maxillary alveolar bone to the skeletal midline.
 - B. Dental Measurements :
 - Distance between the most prominent area of the buccal aspect of the first molar tooth and the dental midline.(fig.2)
 - Distance between the most prominent area of the buccal aspect of the first premolar tooth and the dental midline.(fig.3)
 - Distance between the most prominent area of the palatal aspect of the first molar tooth and the dental midline.(fig.2)
 - Distance between the most prominent area of the palatal aspect of the first premolar tooth and the dental midline.(fig.3)

(2) Mandibular Measurements : [these measurements were performed on the right and left sides to show symmetry]

A. Skeletal Measurements :(these measurements were assessed from 3D MSCT reconstruction images)

- Length of the corpus : distance between the most distal point of the condyle and pogonion.(fig.4)
- Length of the body: distance between the point Gonion and pogonion. (fig.5)
- Intercondylar distance : distance between the most lateral points of the two condyles.(fig.6)

B. Dental Measurements: (these measurements were assessed from the coronal cut)

- Distance between the most prominent area of the buccal aspect of the first premolar and the midline which was a line passing between the symphysis and tubercles.(fig.7)
- Distance between the most prominent area of the lingual aspect of the first premolar and the midline which was a line passing between the symphysis and tubercles.(fig.7)

(3) Measurements of the TMJ : [these measurements were performed on the right and left sides to show symmetry] Coronal cut : (at the level of the maximum width of the condyle)

- Medial Joint Space(MJS): perpendicular distance from the line connecting the most superior area of the fossa and the most medial superior point of the condyle to the medial wall of the glenoid fossa.(fig.8)
- Lateral Joint Space(LJS): perpendicular distance from the line connecting the most superior area of the fossa and the most lateral superior point of the condyle to the lateral wall of the glenoid fossa.(fig.8)

❖ **The measurements were taken by two examiners for interobserver reliability.**

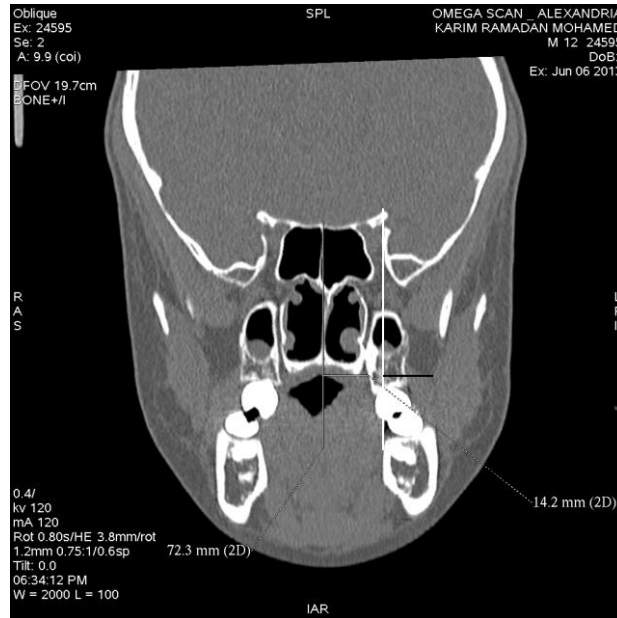


Fig. 1 Skeletal maxillary width

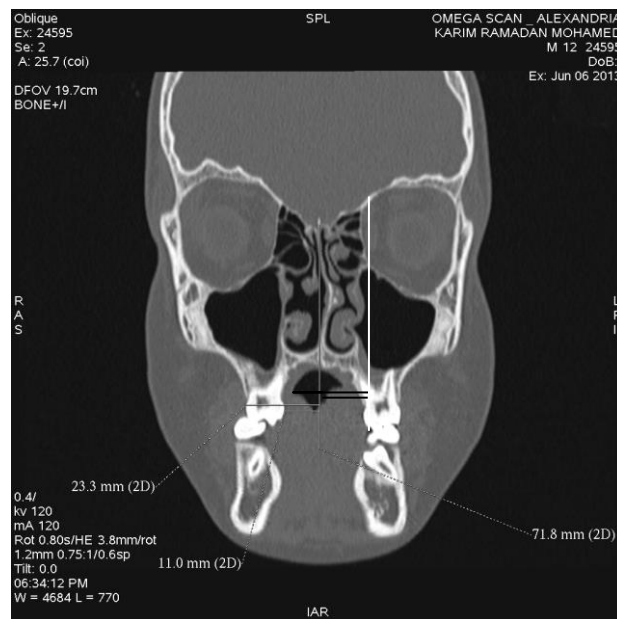


Fig. 2 Maxillary dental measurement at right first molar

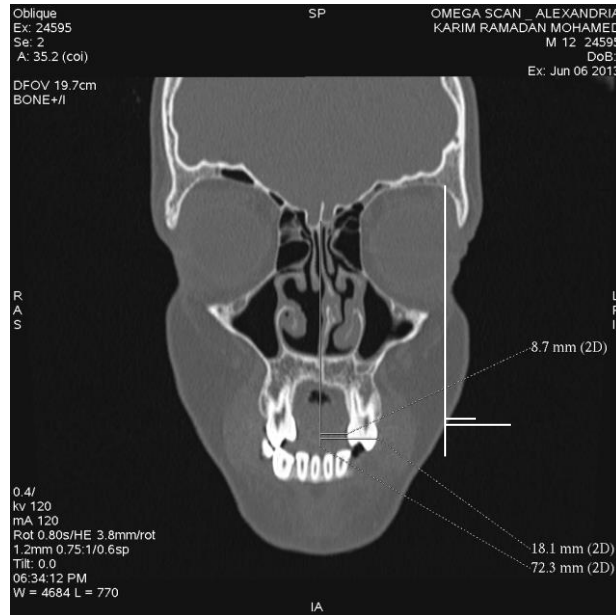


Fig. 3 Maxillary dental measurement at left first premolar

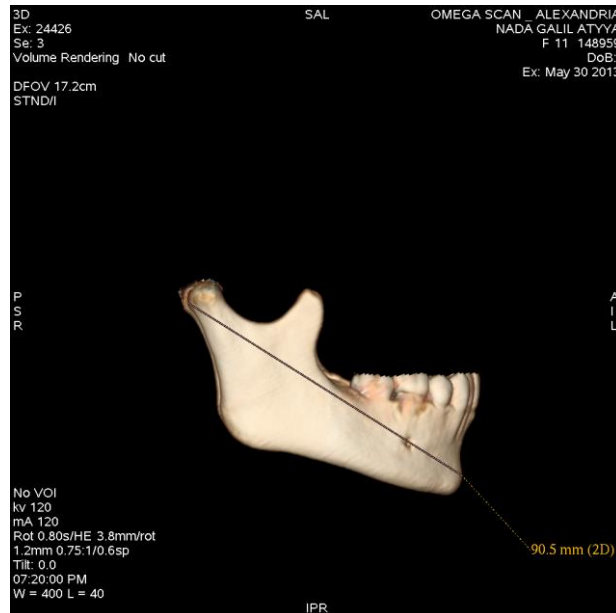

Fig. 4 Length of the corpus

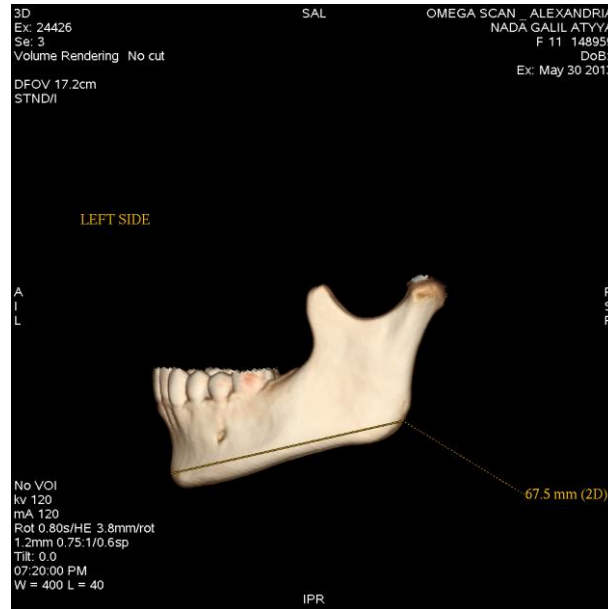


Fig. 5 Length of the body

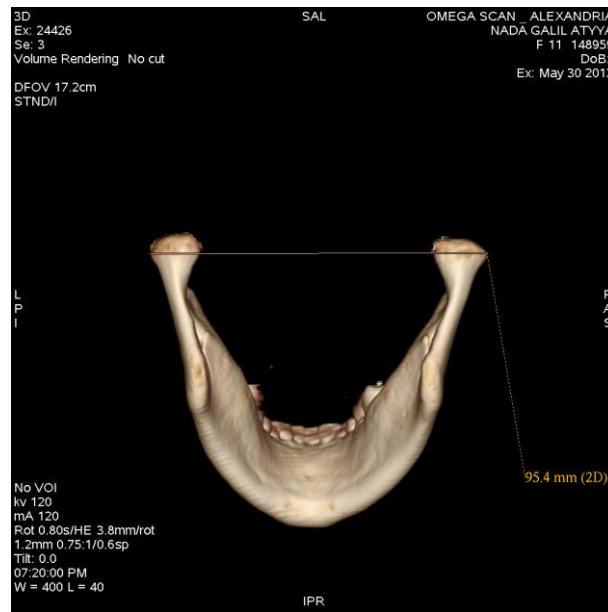

Fig. 6 Intercondylar distance

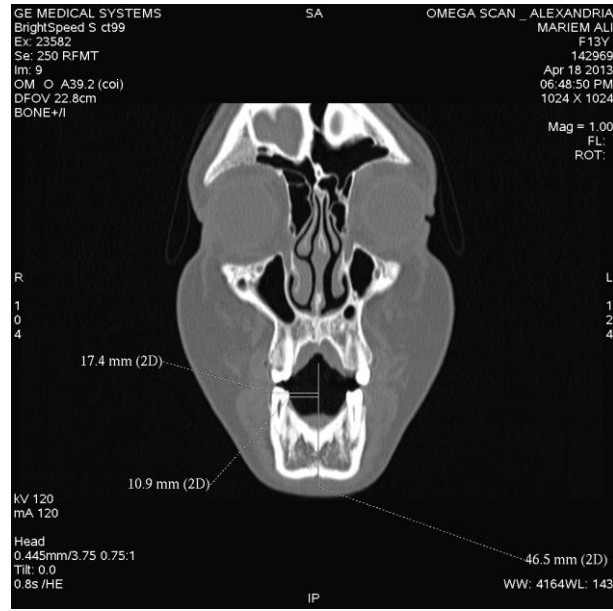


Fig. 7 Mandibular dental measurement at right first premolar

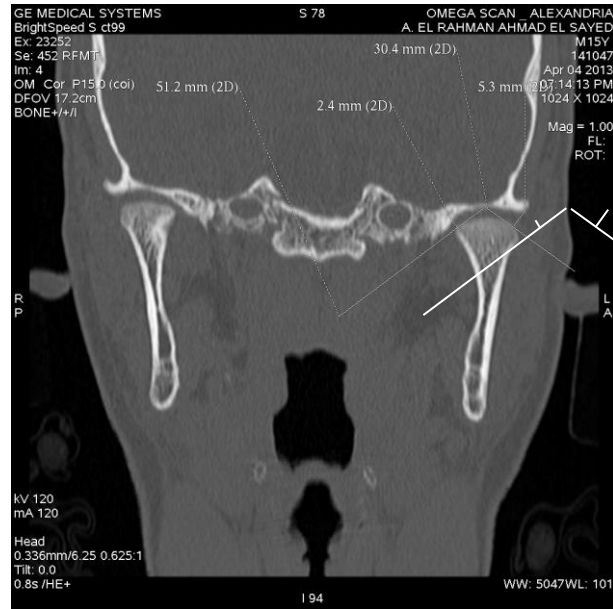


Fig. 8 Medial and lateral Joint Space

RESULTS

Mandibular symmetry (table 1) neither the total length of the mandible nor the mandibular body length showed statistically significant difference between crossbite and normal sides. Dentally, there was also no statistically significant difference between crossbite and normal sides regarding the measurements of the first mandibular premolar to the midline both buccally and lingually. **Maxillary symmetry (table 1)** The 2 sides, crossbite and normal, elicited no statistically significant difference concerning both skeletal measurements and dental measurements at the first premolar area and first molar area. **Condylar position (table 2)** Lateral and Medial Joint Spaces showed no statistically significant difference between crossbite and normal sides.

Table (1) Pre-expansion Dental and Skeletal maxillary and mandibular measurements in crossbite and normal sides

	Crossbite	Normal	P
Mandibular skeletal all mandible	101.56 ± 7.39	101.85 ± 7.41	0.457
Mandibular skeletal mandibular body	71.33 ± 7.58	71.37 ± 6.6	0.494
Mandibular dental (premolar) Buccal	19.64 ± 1.65	19.56 ± 1.52	0.32
Mandibular dental (premolar) Lingual	12.46 ± 1.31	12.31 ± 1.20	0.24
Maxillary skeletal	15.15 ± 1.34	14.55 ± 1.49	0.128
Maxillary dental (premolar) Buccal	20.45 ± 2.31	20.4 ± 1.85	0.345
Maxillary dental (premolar) Palatal	11.27 ± 1.812	11.19 ± 1.944	0.28
Maxillary dental (molar) Buccal	25.46 ± 2.569	26.63 ± 1.9	0.241
Maxillary dental (molar) Palatal	14.15 ± 2.497	15.21 ± 1.76	0.105

Table (2) Pre-expansion measurements of joint spaces in crossbite and normal sides

	Crossbite	Normal	P
Lateral joint space	2.43 ± 1.22	2.5 ± 0.83	0.424
Medial joint space	2.09 ± 0.70	1.87 ± 0.37	0.152

DISCUSSION

Mandibular symmetry several authors have attempted to find a relationship between mandibular asymmetry and crossbite¹⁵. In this study, no statistically significant differences were found between crossbite and non crossbite sides regarding the total length of the mandible nor the mandibular body. The dental arches at the molar and premolar area were also found to be symmetrical on both sides. Several studies^(16,17) agreed with the current study while others^(10,16,18,19) elicited different results. These differences may be either due to the fact that they used submental vertex (2D)^(10,16), Panoramic x.ray¹⁸ or carrying out the study on different age range¹⁶ or small sample size¹⁹. **Maxillary symmetry** in the present study, no statistically significant differences were found between crossbite and non crossbite sides regarding skeletal and dental maxillary measurements. Kecik et al¹⁰ disagreed with the present results finding different dental measurements between crossbite and normal sides. **Condylar position** It must be stated that on going through literature, the present study was the first to measure medial and lateral joint spaces from the coronal view using MSCT, where they were found to be symmetrical on both sides.

CONCLUSIONS

Patients with FUPXB are characterized by a symmetric condylar position and symmetric maxillary and mandibular skeletal and dental measurements.

REFERENCES

1. Borzabadi-Farahani A, Eslamipour F. Malocclusion and occlusal traits in an urban Iranian population: an epidemi-ological study of 11- to 14-year-old children. *Eur J Orthod* 2009;31:477-84.
2. Da Silva Filho OG, Santamaria M Jr, Capellozza Filho L. Epidemiology of posterior crossbite in the primary dentition. *J Clin Pediatr Dent* 2007;32:73-8.

3. Poveda Roda R, Bagan JV, Diaz Fernandez JM, Hernandez, Bazan S, Jimenez Soriano Y. Review of temporo-mandibular joint pathology. Part I: classification, epidemiology and risk factors. *Med Oral Patol Oral Cir Bucal* 2007;12:E292-E8.
4. Scavone H Jr, Ferreira RI, Mendes TE, Ferreira FV. Prevalence of posterior crossbite among pacifier users: a study in the deciduous dentition. *Braz Oral Res* 2007;21:153-8.
5. daCosta OO, Orenuga OO. Dentofacial anomalies related to the digit sucking habit. *Afr J Med MedSci* 2002;31:239-42.
6. Thilander B, Pena L, Infante C, Parada SS, de Mayorga C. Prevalence of malocclusion and orthodontic treatment need in children and adolescents in Bogota, Colombia: an epidemiological study related to different stages of dental development. *Eur J Orthod* 2001;23:153-67.
7. Sonnesen L, Bakke M, Solow B. Malocclusion traits and symptoms and signs of temporomandibular disorders in children with severe malocclusion. *Eur J Orthod* 1998;20: 543-59.
8. Brin I, Ben-Bassat Y, Blustein Y, Ehrlich J, Hochman N, Marmary Y, et al. Skeletal and functional effects of treatment for unilateral posterior cross-bite. *Am J Orthod Dentofacial Orthop* 1996;109:173-9.
9. Keeling SD, McGorray S, Wheeler TT, King GJ. Risk factors associated with temporomandibular joint sounds in children 6 to 12 years of age. *Am J Orthod Dentofacial Orthop* 1994;105:279-87.
10. Kecik D, Kocadereli I, Saatci I. Evaluation of the treatment changes of functional posterior crossbite in the mixed dentition. *Am J Orthod Dentofacial Orthop* 2007;131:202-15.
11. Kennedy DB, Osepchook M. Unilateral posterior crossbite with mandibular shift: a review. *J Can Dent Assoc* 2005;71:569-73.
12. Egermark I, Magnusson T, Carlsson GE. A 20-year follow up of signs and symptoms of temporomandibular disorders and malocclusions in subjects with and without orthodontic treatment in childhood. *Angle Orthod* 2003;73:109-15.

13. Ikeda K, Kawamura A. Assessment of optimal condylar position with limited cone-beam computed tomography. *Am J Orthod Dentofacial Orthop* 2009;135:495-501.
14. Rodrigues AF, Fraga MR, Vitral RW. Computed tomography evaluation of the temporomandibular joint in Class II Division 1 and Class III malocclusion patients: condylar symmetry and condyle-fossa relationship. *Am J Orthod Dentofacial Orthop* 2009;136:199-206.
15. Pinto A, Buschang P, Throckmorton G, Chen P. Morphological and positioned asymmetries of young children with functional unilateral posterior crossbite. *Am J Orthod Dentofacial Orthop*. 2001;120:513-20.
16. Lam PH, Sadowsky C, Omerza F. Mandibular asymmetry and condylar position in children with unilateral posterior crossbite. *Am J Orthod Dentofacial Orthop* 1999;115:569-75.
17. Veli I, Uysal T, Ozer T, Ucar FI, Erüz M. Mandibular asymmetry in unilateral and bilateral posterior crossbite patients using cone-beam computed tomography. *Angle Orthod*. 2011;81(6):966-74.
18. Kilic N, Kiki A, Oktay H. Condylar asymmetry in unilateral posterior crossbite patients. *Am J Orthod Dentofacial Orthop* 2008;133:382-7.
19. Kumar S, Tajr F, Gnanashanmugam, saravanan, kumar N. Effect of posterior unilateral crossbite on condylar head height. *Indian Journal of Multidisciplinary Dentistry*. 2011;1;(6):333-337.