

## Ameliorative Effect of *Moringa oleifera* Extract on Male Fertility in Paroxetine Treated Rats

Sawsan M. El-Sheikh, Mohammed M.A. Khairy, Hosny Abdel Fadil, Azza M.A. Abo-Elmaaty\*  
Pharmacology Department, Faculty of Veterinary Medicine, Zagazig University, Egypt  
Article History: Received: 6/11/2016 Received in revised form: 29/11/2016 Accepted: 15/12/2016

### Abstract

Paroxetine is one of the selective serotonin reuptake inhibitor that is used for treating major depressive disorders but it has many side effects. Therefore, this study was planned to evaluate the possible protective effect of *Moringa oleifera* extract on the fertility of male rats treated with paroxetine. A total of forty adult male albino rats were equally allocated into four groups, each of 10 rats: Rats received 0.5 mL distilled water, 400 mg/kg BW of moringa hydroalcoholic extract, 10 mg/ kg BW of paroxetine, for groups 1, 2 and 3, respectively. While, rats of group 4 received moringa hydroalcoholic extract and paroxetine simultaneously at the same previously mentioned doses. All treatments were administered orally once daily for 60 successive days. Paroxetine treated group showed a significant decrease in the serum levels of Follicle stimulating hormone (FSH), Luteinizing hormone (LH), testosterone, estrogen and testicular catalase, glutathione (GSH), glutathione peroxidase (GPX), sperm count and sperm motility. Moreover, paroxetine evoked a significant increase in sperm abnormalities, testicular DNA fragments and testicular malondialdehyde (MDA) level compared with the control group. However, the concurrent administration of moringa extract with paroxetine was ameliorating the aforementioned alterations compared with paroxetine treated group. It could be concluded that, *Moringa oleifera* extract alleviated reprotoxicity induced by paroxetine in male rats.

**Keywords:** *Moringa oleifera*, Male fertility, Paroxetine, Oxidative stress

### Introduction

Depression is one of the most serious social problems facing the developed countries that leads to increase the usage of antidepressant drugs [1]. Selective serotonin reuptake inhibitors (SSRIs) are of the antidepressant medications that are used in depression treatment [2]. Their side effects differ according to the class of antidepressant and the individual agents [3]. Paroxetine hydrochloride is one of SSRIs that has several side effects, such as sexual dysfunction including anorgasmia (difficulty achieving an orgasm), weight gain and sleep disturbance [4]. Male infertility is a common problem on which the man is unable to produce and/or deliver fully functioning sperm. A couple is considered infertile if pregnancy does not occur within one year of unprotected intercourse [5]. Some medicinal plants were used to ameliorate the side effects of the antidepressant drugs. *Moringa oleifera* is considered one of the major medicinal plants that believed to be miracle herbs because it can be used not only as food but also as medicine which can cure numerous ailments [6]. Its

extract enhanced the sexual behavior of male rats. Also, they reported that management of male sexual disorders was due to the presence of alkaloids, flavonoids, steroids, phenolics and tannins. Steroids and saponin constituents found in many plants possess fertility potentiating properties [7]. The present study was designed to evaluate the possible ameliorative effects of hydroethanolic extract of *Moringa oleifera* leaves on reprotoxicity induced by paroxetine in male rats.

### Material and methods

#### Preparation of plant extract

The dried *Moringa oleifera* leaves were grounded into fine coarse powder by hand and mortar. The leaves powder (400g) was soaked in ethanol 95% (1L): water (1L) 1:1 at 33°C for 24h. The mixture was subjected to filtration using a Whatman grade 1 filter paper, and then the solvent was evaporated using rotary evaporator until the extract was lyophilized. The extracts were stored at -4°C in a dark bottle until used [8].

### ***Animals and experimental protocol***

The current study was conducted on 40 adult male albino rats weighing  $140 \pm 10$  g obtained from Central Animal House of the Faculty of Veterinary Medicine, Zagazig University. Rats were left for one week at the experimental unit for acclimatization and then they were randomly allocated into four equal groups. Group 1, (Control): received 0.5 mL distal water, Group 2 (Moringa): received 400 mg/kg BW of moringa hydroalcoholic extract, Group 3 (Paroxetine): administered 10 mg/kg BW of paroxetine (Paroxetine (PAXI)<sup>®</sup> tablets, EVA PHAMA Egypt, each contains 20 mg paroxetine) and Group 4: received moringa hydroalcoholic extract and paroxetine simultaneously at the same previously mentioned doses. Both the drug and the extract were administered orally once daily for 60 successive days. At the end of the experimental period, 5 rats from each group were sacrificed and blood sample (2 mL) were taken from each rat in a glass tube without EDTA for separating the serum to measure some reproductive hormones. Then, the testes were taken from each sacrificed rat for spermogram analysis, determination of oxidative/antioxidant status and DNA fragmentation.

### ***Biochemical analysis***

Enzyme Linked Immunosorbent Assay (ELISA) was used to determine the serum levels of LH, FSH and testosterone according to Levine *et al.* [9]. While, estrogen was measured according to Wisdom [10].

### ***Semen analysis***

The cauda epididymis of one testis was removed and transferred to sterilized Petri dish containing 2 mL warm normal saline at  $37^{\circ}\text{C}$ , and then macerated by sterilized scissor to obtain a suspension of the epididymal content. Sperm motility in the prepared semen suspension was examined by the light microscope. At least 200 spermatozoa from each sample in the minimum of five microscopic fields were assessed to evaluate the percent of motile spermatozoa [11]. Sperm cell concentration in the semen sample was examined using hemocytometer counting chamber [12]. Regarding sperm cell abnormalities, 100 random spermatozoa were

examined for abnormalities of the sperm head and/or tail in different fields under an oil immersion lens [13].

### ***Testicular oxidative/antioxidant status and DNA fragmentation***

Half gram from testis of each sacrificed rat was homogenized in 5 mL phosphate buffer with pH 7.4 on ice using electrical homogenizer. Homogenates were centrifuged at 3000 rpm at  $4^{\circ}\text{C}$  for 15 min. The supernatants were collected and kept at  $-80^{\circ}\text{C}$  until the estimation of catalase (CAT) [14], reduced glutathione (GSH) [15], glutathione peroxidase (GPX) [16] and malondialdehyde concentration (MDA, lipid peroxidation indicator) [17]. Furthermore, the obtained homogenate was used for determining DNA fragmentation in testicular cell (apoptosis indicator) by ELISA kit (Roche Diagnostics, USA) in accordance with the manufacturer's protocol.

### ***Statistical analysis***

The variations among groups were analyzed using one-way analysis of variance (ANOVA) (SPSS version 18.0 for Windows) followed by Duncan's multiple ranges post hoc test for pairwise comparisons. The obtained results were represented as mean  $\pm$ SE for each group. Data were considered significant at  $P < 0.05$ .

## **Results**

### ***Effect of moringa and paroxetine on serum reproductive hormones.***

Administration of moringa did not reveal any significant change in serum reproductive hormones level except FSH when was compared with the control group. The FSH was the highest in moringa group ( $0.18 \pm 0.12$  mIU/mL). Oral administration of paroxetine resulted in a significant ( $p < 0.05$ ) decrease in FSH, LH, testosterone and estrogen ( $0.22 \pm 0.02$  mIU/mL,  $1.54 \pm 0.09$  mIU/mL,  $0.99 \pm 0.06$  ng/mL and  $12.38 \pm 0.48$  ng/mL, respectively) when compared with the control group. However, co-administration of moringa hydro alcoholic extract and paroxetine induced a significant ( $p < 0.05$ ) increase in the level of serum reproductive hormones (FSH, LH, testosterone and estrogen) when compared with paroxetine group (Table 1).

**Table 1: Effect of oral administration of moringa hydroalcoholic extract (400 mg/kg BW once daily for 60 successive days) on some male reproductive hormones in paroxetine treated rats (Means±SE, n=5)**

Groups	Male reproductive hormones			
	FSH <sup>1</sup> (mIU/mL)	LH <sup>2</sup> (mIU/mL)	Testosterone (ng/mL)	Estrogen (ng/mL)
Control	0.71 ±0.01 <sup>b</sup>	2.75 ±0.09 <sup>a</sup>	3.64±0.07 <sup>a</sup>	22.17±0.81 <sup>a</sup>
Moringa	0.81 ±0.12 <sup>a</sup>	2.50±0.09 <sup>a,b</sup>	3.52±0.06 <sup>a</sup>	20.54±0.68 <sup>a,b</sup>
Paroxetine	0.22±0.02 <sup>c</sup>	1.54 ±0.09 <sup>c</sup>	0.99 ±0.06 <sup>c</sup>	12.38±0.48 <sup>c</sup>
Paroxetine +Moringa	0.66±0.05 <sup>b</sup>	2.29 ±0.16 <sup>b</sup>	3.14±0.08 <sup>b</sup>	19.32±0.37 <sup>b</sup>

<sup>1</sup>FSH: follicle stimulating hormone; <sup>2</sup>LH: Luteinizing hormone

Means within the same column carrying different superscripts are significantly different at (p < 0.05).

### Effect of moringa and paroxetine on sperm cell characteristics

There was no significant change on semen analysis post moringa administration except the sperm count compared with the control group. Paroxetine administration induced a significant (p<0.05) decline in both sperm motility and count compared with the control group. In addition, a significant elevation in sperm abnormalities (62.65±0.53%) (Figure 1) and testicular DNA fragmentation (831.98±20.1 cell/g) compared with control group was observed. Concurrent administration of moringa extract with paroxetine to somewhat alleviated the altered parameters in paroxetine group (Table 2).

### Effect of moringa and paroxetine on antioxidant/oxidative status of testicular tissue.

Results of the current study showed that the administration of moringa lead to none significant changes on antioxidant/oxidative status of testicular tissue when compared with the control group. The CAT and GPX activity, GSH concentration declined (P < 0.05) in paroxetine treated group, while MDA concentration was increased significantly when compared with the control group. Co-administration of both moringa hydroalcoholic extract and paroxetine provoked a significant (p<0.05) increase in CAT and GPX activity, GSH concentration with significant decrease in MDA concentration (Table 3).

**Table 2: Effect of oral administration of moringa hydroalcoholic extract (400 mg/kg BW once daily for 60 successive days) on sperm characteristics and DNA fragmentation in paroxetine treated rat (Means±SE, n=5)**

Groups	Sperm count (Sp.cc/mL)	Sperm characteristics		
		Motility (%)	Abnormalities (%)	DNA fragment (cell/g)
Control	77.11±1.21 <sup>a</sup>	92%±1.22 <sup>a</sup>	24.39±1.38 <sup>c</sup>	138.84±2.1 <sup>b,c</sup>
Moringa	67.33±2.16 <sup>b</sup>	93%±1.22 <sup>a</sup>	23.44 ± 1.18 <sup>c</sup>	125.81±4.76 <sup>c</sup>
Paroxetine	28.95±1.48 <sup>c</sup>	67%±3.00 <sup>c</sup>	62.65± 0.53 <sup>a</sup>	831.98±20.1 <sup>a</sup>
Paroxetine +Moringa	70.48±2.14 <sup>b</sup>	85% ±2.2 <sup>b</sup>	32.74 ±0.42 <sup>b</sup>	162.53±1.4 <sup>b</sup>

Means within the same column carrying different superscripts are significantly different at (p < 0.05).

## Discussion

The current investigation revealed that a significant (p<0.05) decrease in serum level of FSH, LH, testosterone and estrogen followed oral administration of paroxetine when compared to the control. These results may be due to the direct toxic effect of paroxetine on gonads or the indirect effect on pituitary gland which is responsible for androgen secretion

and release [18]. Our results were nearly similar to that reported by Ajiboye *et al.* [19] who found that administration of paroxetine 10 mg/kg BW orally for 10 days resulted in a significant decline in reproductive hormones. On the other hand, our findings revealed that, oral administration of *Moringa oleifera* extract simultaneously with paroxetine evoked a significant increase in the level of reproductive hormones compared with paroxetine treated

group, that may be due to the powerful antioxidant effect of moringa. Kujo [20] illustrated that the presence of flavonoids in *Moringa oleifera* extract have a role in altering androgen levels. In the current study, the

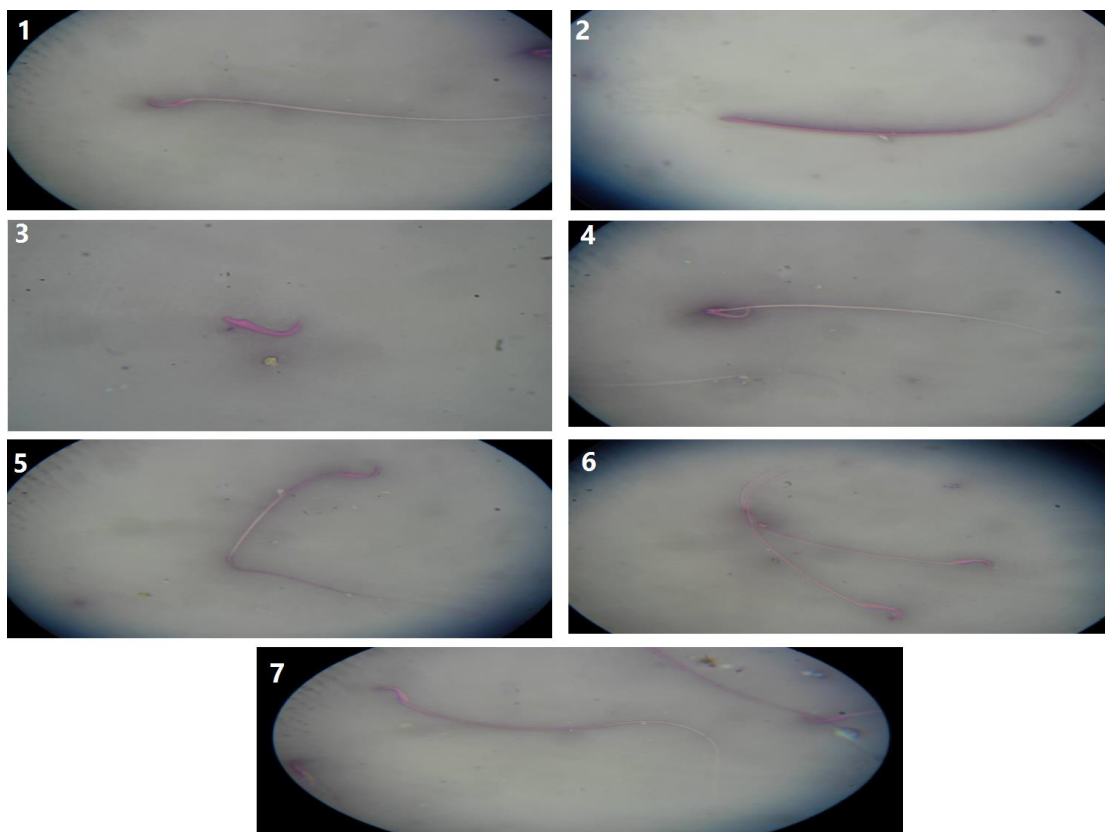
improvement of reproductive hormones was in agreement with Dafaalla *et al.* [21] who mentioned that *Moringa oleifera* extract improved the testosterone secretion and consequently its availability to gonads.

**Table 3: Effect of oral administration of moringa hydroalcoholic extract (400 mg/kg BW once daily for 60 successive days) on Antioxidant /oxidant indices in paroxetine treated rats (Means±SE, n=5)**

Groups	Antioxidant /oxidant indices			
	Catalase (mmol/g)	GPX <sup>1</sup> (ng/g)	GSH <sup>2</sup> (ng/g)	MDA <sup>3</sup> (mmol/g)
Control	75.39±0.79 <sup>a</sup>	29.23 ±1.22 <sup>a</sup>	4.72 ±0.38 <sup>a</sup>	51.39 ± 2.6 <sup>c</sup>
Moringa	73.96 ±0.7 <sup>a</sup>	27.69 ±0.67 <sup>a</sup>	5.03 ±0.35 <sup>a</sup>	48.51 ± 2.3 <sup>c</sup>
Paroxetine	34.26±1.19 <sup>c</sup>	11.82 ±1.24 <sup>c</sup>	2.13 ± 0.39 <sup>c</sup>	123.26 ±6.3 <sup>a</sup>
Paroxetine+Moringa	69.19 ±0.52 <sup>b</sup>	20.21 ±0.40 <sup>b</sup>	3.97±0.24 <sup>b</sup>	62.76 ±1.5 <sup>b</sup>

<sup>1</sup>GPX: glutathione peroxidase; <sup>2</sup>GSH: glutathione; <sup>3</sup>MDA: malondialdehyde.

Means within the same column carrying different superscripts are significantly different at (p < 0.05).



**Figure 1: A plate showing different forms of sperm abnormalities. 1: Normal sperm, 2: Detached head, 3: Detached tail, 4: Broken tail, 5: Bent tail, 6: Protoplasmic droplets, 7: Curved tail.**

The hormonal alterations induced by paroxetine administration recorded in this study (reduced the serum levels of FSH, LH, testosterone and estrogen) directly resulted in deterioration of the spermatogenesis, which was evidenced by marked reduction in sperm count and motility percentages, a significant increase of sperm abnormalities percentage

and sperm DNA fragments. These findings may be attributed to the major role of FSH, LH, testosterone and estrogen in the process of spermatogenesis. Adequate levels of FSH in male rats are crucial for the establishment of Sertoli cell population, which is directly related to sperm production [22]. Whereas, LH stimulates spermatogenesis indirectly via stimulation of Leydig cells to secret

testosterone, which acts also on Sertoli cells [23]. Furthermore, estrogen has a role in regulation of testicular steroidogenesis and spermatogenesis [24]. Our results were strengthened by Galal *et al.* [25] who found that oral administration of fluvoxamine (9 and 27 mg/ kg BW) for 8 weeks to adult male rats induced a significant decrease in sperm count and motility with significant increase in sperm abnormalities. Concurrent administration of moringa with paroxetine induced a significant increase in sperm motility, sperm count and decrease in sperm abnormalities and testicular DNA fragments when compared with paroxetine group. The ameliorative effect of *Moringa oleifera* extract on sperm parameters may be due to an increase in the antioxidant enzyme system that favors the reproductive process and also enhances spermatogenesis as mentioned by D'cruz and Mathur [26]. Our results are supported by Priyadarshani and Varma [27] who recorded that semen parameters (count, motility, morphology and sperm DNA fragment) were improved after administration of *Moringa oleifera* leaf powder (200 mg/kg BW) for 21 days. The present results clearly demonstrated the ability of paroxetine to induce oxidative stress in rat that was evidenced by the high elevation of lipid peroxidation product (MDA) and sharp decline of endogenous antioxidants GPX, GSH and catalase. These results may be attributed to generation of ROS by paroxetine treatment [28]. Our data was supported by Galal *et al.* [25] who found that oral administration of fluvoxamine (9 and 27 mg/kg BW) for 8 weeks to adult male rats induced a significant decrease of CAT activity and GSH concentration and increased the concentration of testicular MDA. Our findings revealed that administration of *Moringa oleifera* extract simultaneously with paroxetine improved the oxidative antioxidant status of testicular tissue, that could be explained by the potential role of *Moringa oleifera* via inhibiting oxidative stress due to the presence of phenolic compounds and its anti-oxidant [29]. Our results were strengthened by Nayak *et al.* [30] who reported that administration of *Moringa oleifera* leave extract (25 mg/kg BW) prior to cyclophosphamide administration, increased superoxide dismutase and catalase with

concomitant reduction in lipid peroxidation of the testicular tissue.

## Conclusion

It could be concluded that paroxetine has many side effects on sperm characters, reproductive hormones and antioxidant enzymes which may be attributed to the induction of oxidative stress. Administration of *Moringa oleifera* hydroalcoholic extract can ameliorate the reprotoxicity induced by paroxetine in adult male rats through its antioxidant properties.

## Conflict of interest

None of the authors have any conflict of interest to declare.

## Reference

- [1] Miyamoto, T.; Tsujimura, A.; Miyagawa, Y.; Koh, E.; Namiki, M. and Sengoku, K. (2011): Male Infertility and Its Causes in Human. *Adv Urol*, 2012: 1-7
- [2] Ali, M.K. and Lam, R.W. (2011): Comparative efficacy of escitalopram in the treatment of major depressive disorder. *Neuropsychiatr Dis Treat*, 7:39-49
- [3] Adler, D.A.; Gorelick, D.A.; Rummans, T.A.; Bell, C.; Greene, J.A.; Shapiro, H.L.; Blazer, D.G.; Keddy, D.; Smith, D.; Boyce, P. and Kennedy, S.H. (2000): Practice guideline for the treatment of patients with major depressive disorder (revision). *Am J Psychiatry*, 157(4 SUPPL):1-45.
- [4] James, M. Ferguson, J.M. (2001): SSRI Antidepressant Medications: Adverse Effects and Tolerability. *Prim Care Companion J Clin Psychiatry*, 3(1): 22-27.
- [5] Zeba, U.N.; Ali, M.; Biswas, S.K.; Kamrun, N.; Bashar, T. and Arslan, M.I. (2011): Study of seminal MDA level as an oxidative stress. *J Sci Foundation*, 9:85-93.
- [6] Pal, S.K.; Mukherjee, P.K. and Saha, B.P. (1995): Studies on the antiulcer activity of *Moringa oleifera* leaf extract on gastric ulcer models in rats. *Phytother Res*, 9(6): 463-465.

- [7] Zade, V.; Dabhadkar, D.; Thakare, V. and Pare, S. (2013): Evaluation of potential aphrodisiac activity of moringa oleifera seed in male albino rats. *Int J Pharm Pharmaceut Sci*, 5(4): 683-689.
- [8] Prabsattroo, T.; Wattanathorn, J.; Iamsard, S.; Muchimapura, S. and Thukhammee, W. (2012): *Moringa oleifera* Leaves Extract Attenuates Male Sexual Dysfunction. *Am. J. Neurosci*, 3 (1): 17-24.
- [9] Levine, J.E.; Norman, R.L.; Gliessman, P.M.; Oyama, T.T.; Bangsberg, D.R. and Spies, H.G. (1985): In-vivo gonadotropin-releasing hormones measurements in ovariectomized rats. *Endocrinol*, 117(2):711-721.
- [10] Wisdom, G.B. (1976): Enzyme – immunoassay. *ClinChem*, 22(8):1243-1255.
- [11] Slott, V.; Suarez, J. and Perreault, S. (1991): Rat sperm motility analysis: methodologic considerations. *Reprod Toxicol*, 5(5):449-458.
- [12] Robb, G.W.; Amann, R.P. and Killian, G.J. (1978): Daily sperm production and epididymal reserves of pubertal and adult rats. *J Reprod Fertil*, 54(1):103-107.
- [13] Filler, R. (1993): Methods for evaluation of rat epididymal sperm morphology. In: *Methods in Toxicology. Male Reprod Toxicol*, 3: 334-343
- [14] Aebi, H. (1984): Catalase in vitro. *Methods Enzymol*, 105: 121-126
- [15] Moron, M.S.; Depierre, J.W. and Mannervik, B. (1979): Levels of glutathione, glutathione reductase and glutathione-S-transferase activities in rat lung and liver. *Biochim Biophys Acta*, 582(1): 67-78.
- [16] Paglia, D.E. and Valentine W.N. (1967): Studies on the quantitative and qualitative characterization of erythrocyte glutathione peroxidase. *J Lab Clin Med*, 70(1):158-169.
- [17] Ohkawa, H.; Ohishi, N. and Yagi, K. (1979): Assay for lipid peroxidase in animal tissues by thiobarbituric acid reaction. *Anal Biochem*, 95(2):351-358.
- [18] Inass, E.G.; Hassan, M.; Fouad, G. and El-Komey, F. (2005): Toxic effects of paroxetine on sexual and reproductive functions of rats. *Egypt J Hosp Med*, 21:16-32.
- [19] Ajiboye, T.O.; Nurudeen, O.Q. and Yakubu, M.T. (2013): Aphrodisiac effect of aqueous root extract of *Lecaniodiscus cupanioides* in sexually impaired rats. *J Basic Clin Physiol Pharmacol*, 25(2):241-248.
- [20] Kujo, S. (2004): Safety and fertility enhancing role of moringa oleifera leaves. *Curr Med Chem*, 11: 1041-1064.
- [21] Dafaalla, M.M.; Hassan, A.; Idris, O F.; Abdoun, S.; Modawe, G. and Kabbashi, A.S. (2016): Effect of ethanol extract of moringa oleifera leaves on fertility hormone and sperm quality of male albino rats. *World J Pharm Res*. 5:1-11
- [22] Franca, R.L.; Silva, V.A.; Chiarini-Garcia, H.; Garcia, S.K. and Debeljuk, L. (2000): Cell proliferation and hormonal changes during postnatal development of the testes in the pig. *Biol Reprod*, 63(6):1629-1636
- [23] McLachlan, R.I.; Wreford, N.G.; Robertson, D.M. and De Kretser, D.M. (1995): Hormonal control of spermatogenesis. *Trends Endocrinol Metab*, 6(3):95-101.
- [24] Carreau, S.; Bouraima-Lelon, H. and Delalande, C. (2012): Estrogen, a female hormone involved in spermatogenesis. *Adv Med Sci*, 57(1):31-36.
- [25] Galal, A.A.; Alam, R. T. M. and Abd El-Aziz, R. M. (2016): Adverse effects of long-term administration of fluvoxamine on haematology, blood biochemistry and fertility in male albino rats: a possible effect of cessation. *Androl*, 48(9): 914-922.
- [26] D'cruz, S.C. and Mathur, P.P. (2005): Effect of piperine on the epididymis of adult male rats. *Asian J Androl*, 7(4): 363-386.
- [27] Priyadarshani, N. and Varma, M.C. (2014): Effect of *Moringa oleifera* leaf powder on sperm count, histology of

- testis and epididymis of hyperglycaemic mice *Mus musculus*. *Am Int J Res Form Appl Nat Sci*, 7(1):7-13.
- [28] Mimnaugh, E.G.; Trush, M.A.; Bhatnagar, M. and Gram, T.E. (1985): Enhancement of reactive oxygen-dependent mitochondrial membrane lipid peroxidation by the anticancer drug adriamycin. *Biochem Pharmacol*, 34(6):847-856
- [29] Fakurazi, S.; Sharifudin, S. A. and Arulselvan, P. (2012): *Moringa oleifera* Hydroethanolic Extracts Effectively Alleviate Acetaminophen-Induced Hepatotoxicity in Experimental Rats through Their Antioxidant Nature. *Molecules*, 17(7):8334-8350.
- [30] Nayak, G.; Vadinkar, A.; Nair, S.; Kalthur, S. G.; D'Souza, A. S.; Shetty, P. K.; Mutalik, S.; Shetty, M. M.; Kalthur, G. and Adiga, S. K. (2016): Sperm abnormalities induced by pre-pubertal exposure to cyclophosphamide are effectively mitigated by *Moringa oleifera* leaf extract. *Androl*, 48(2):125-136.

### الملخص العربي

#### التأثير الوقائي لخلصة المورينجا علي الخصوبة في ذكور الجرذان المعالجه بالباروكسيتين

سوسن الشيخ، محمد خيرى، حسني عبد الفضيل ، عزة ابو المعاطي

قسم الفارماكولوجيا ، كلية الطب البيطري، جامعة الزقازيق

يعتبر الباروكسيتين واحد من الأدوية التي تمنع امتصاص السيروتونين ولذلك يستخدم في علاج حالات الاكتئاب الكبرى لكنه يمتلك العديد من الآثار الجانبية. ولهذا قد تم تخطيط هذه الدراسة لتقييم التأثير الوقائي لمستخلص المورينجا ضد الآثار الجانبية للباروكسيتين. ولهذا الغرض قد تم تقسيم الجرذان (٤٠ جرد) إلى ٤ مجموعات متساوية بمعدل ١٠ جرذان للمجموعة: المجموعة الأولى: أعطيت ٥. مللي من الماء المقطر. والمجموعة الثانية: أعطيت (٤٠٠ مجم /كجم من وزن الجسم) من مستخلص نبات المورينجا. المجموعة الثالثة أعطيت ( ١٠ مجم /كجم من وزن الجسم) من الباروكسيتين. المجموعة الرابعة: أعطيت مستخلص نبات المورينجا مع الباروكسيتين في وقت واحد بنفس الجرعات السابق ذكرها. وكل هذه العلاجات كانت تؤخذ عن طريق الفم مرة واحدة يوميا لمدة ٦٠ يوم متتالية. ولقد أظهرت المجموعة المعالجه بالباروكسيتين انخفاضا ملحوظا في مستوى LH, FSH, التستستيرون, الاستروجين, حركه وعدد الحيوانات المنوية , الكاتالاز وجلوتاثيون بيروكسيداز والجلوتاثيون المختزل في أنسجة الخصية كما انه أدى إلي زيادة ملحوظة في زيادة تشوهات الحيوانات المنوية , تفتيت الحمض النووي و تركيز المالمونالدهيد في انسجه الخصية بالمقارنة بالمجموعة الضابطة. ولكن التناول المتزامن للمورينجا مع الباروكسيتين نجح في الإقلال من التغيرات السابق ذكرها بالمقارنة بمجموعه الباروكسيتين. لذلك فان الدراسة توصي باستخدام مستخلص المورينجا بالتزامن مع الباروكسيتين وذلك لما له من آثار ايجابية في التخفيف من تأثير الباروكسيتين السلبي علي الخصوبة في ذكور الجرذان.