

**SKELETAL, DENTAL AND SOFT TISSUE CHANGES  
FOLLOWING THE TREATMENT OF CLASS III MALOCCLUSION  
USING THE CLASS III SPLINT**

Dr. Nadia M. El Harouni\*

*ABSTRACT:*

*Early treatment has definite benefits for growing patients and Class III patients in particular if only to allow a normal growth pattern to be restored giving the patient a chance to escape surgery and allowing better esthetics at a younger age .*

*Ten growing Class III patients were treated using the Class III splint appliance until the anterior cross bite was transformed into a positive over jet. Pre and post treatment cephalometric radiographs were taken, then skeletal, dental and soft tissue measurements were done. Pre and post treatment measurements were compared to assess profile changes using the paired t-test.*

*Definite improvement was seen clinically in all the cases, and proved statistically to be due to both dental and skeletal effects in the form of upper incisor proclination and lower incisor retroclination, a significant increase in the SNA angle with concomitant decrease in the SNB angle.*

*The soft tissue profile was restored to a more normal profile through a decrease of lower lip thickness and an increase in its length.*

**INTRODUCTION**

Early treatment has become of highly recognized value in the recent years. The Class III patient is considered as an ideal candidate for early treatment by most clinicians as the condition is progressive and has a strong hereditary component. However, one of the reasons orthodontists

---

\* Assistant Professor Orthodontic Department, Faculty of Dentistry, Alexandria University.

are reluctant to render early orthopedic treatment in Class III patients is the inability to predict mandibular growth<sup>(1)</sup>. Patients who have received early orthopedic treatment could still require surgical treatment at the end of the growth period.

Virtues of early Class III treatment have been summarized by Ngan<sup>(2)</sup>

- 1- To prevent progressive irreversible soft tissue or bony Changes. Uncorrected anterior crossbite may lead to abnormal wear of the lower incisors, thinning of the labial alveolar plate and/or gingival recession<sup>(3)</sup>
2. To improve skeletal discrepancies and provide a more favorable environment for future growth.
3. To improve occlusal function. Class III malocclusion with an anterior crossbite is often accompanied by a functional shift.
4. To simplify phase II comprehensive treatment. In mild and moderate Class III patients, early orthodontic or orthopedic treatment may eliminate the necessity for orthognathic surgery treatment.
5. To provide more pleasing facial esthetics, thus improving the psychosocial development of a child<sup>(4)</sup>.

To this it might be added that treatment at a young age minimizes the need for extractions, eliminates the detrimental effects of malocclusion such as temporomandibular joint problems and abnormal muscle function.

Some factors might help in deciding whether to intercept a developing Class III malocclusion<sup>(2)</sup>. The positive factors include good facial esthetics, mild skeletal disharmony, no familial prognathism, presence of anteroposterior functional shift, convergent facial type, symmetric condylar growth, and growing patients with expected good cooperation. The negative factors include poor facial esthetics, severe skeletal disharmony, familial pattern established, no anteroposterior shift, divergent facial type, asymmetric condylar growth, growth complete, and poor cooperation. Turpin<sup>(5)</sup> recommends that early treatment should be considered for a patient that presents with positive characteristics. For individuals who present with negative characteristics, treatment can be delayed until growth is completed. Patients should be aware that surgery may be needed at a later date, even when an initial phase of treatment may be successful.

Skeletal Class III patients can be managed by either orthopedic, orthodontic, camouflage, or combined surgical treatment, depending on the age of the patient, the pattern of malocclusion, and its severity<sup>(6)</sup>. In a study on the components of Class III surgical patients<sup>(7)</sup> it was found that the largest group of the sample, 30.1%, was made up of a combination of an underdeveloped maxilla and overdeveloped mandible, while a normal maxilla with overdeveloped mandible made up 19.2% of the sample. However, it is well documented in the literature that skeletal characteristics of Class III patients varies among ethnic groups<sup>(7,8)</sup> therefore, treatment of Class III patients should be planned based on the individual skeletal pattern.

Very early treatment of Class III has been proposed starting at the deciduous dentition in the form of occlusal equilibration, expansion plates, chin cup therapy<sup>(9,10,11)</sup>. Also Orthopaedic maxillary protraction treatment of growing Class III patients has also been well established -with or without rapid palatal expansion- with promising success<sup>(12,13,14,15,16)</sup> although the facemask involved is reported to be very tedious to patients and patient cooperation with it is hard to achieve.

In the 1960s, Frankel modified the activator and designed the functional regulator (FR). Frankel stated that the lip pad and buccal shield in the appliance stretched the periosteum to stimulate forward growth of the maxilla.<sup>(17)</sup> However, according to studies by Ulgen and Firatli<sup>(18)</sup>, Baik and coworkers<sup>(19)</sup> FR-III treatment effects are mainly the result of backward and downward rotation of the mandible and linguoversion of the lower incisors, with little effect on maxillary growth promotion.

A Class III splint with elastics has been proposed by Franchi and Baccetti<sup>(20)</sup> as another functional treatment modality in the primary dentition. It is said to improve the maxillo-mandibular relation through maxillary advancement and mandibular retrusion while being a simple appliance that is easily manageable by the patient. Though only 2 cases were treated in that study.

Another study by El Kenany and Ismail<sup>(21)</sup> included six growing Class III cases treated with the Class III splint compared to the facemask treatment. They concluded that the improvement in profile in patients

treated with the Class III splint was only due to dental effects in the form of labial tipping of maxillary and lingual tipping of mandibular teeth. Thus they were somehow different than the previous research.

It was thus thought necessary to evaluate the skeletal and dental changes induced by the appliance and to include the soft tissue changes too.

**Material and Methods:**

Ten patients were selected according to the following criteria:

- Age range: 8-11 years
- Skeletal Class III malocclusion identified by:
  - 1) At least 3 mm mesial step molar relation.
  - 2) An anterior crossbite.
  - 3) An ANB difference of less than 1.5 to -2 degrees and Wits appraisal of less than or equal -2mm.

**Exclusion criteria:**

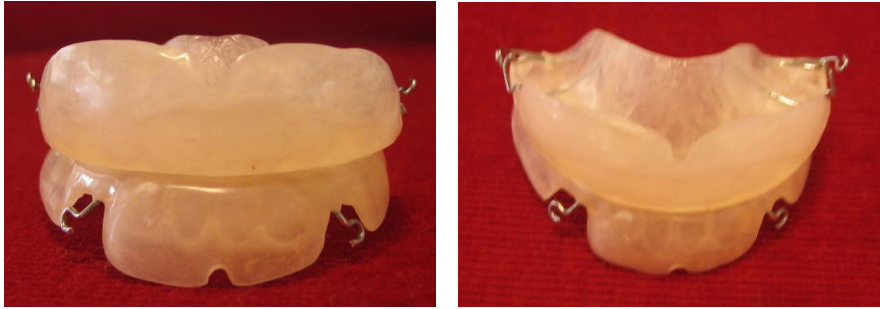- Severe craniofacial anomalies e.g. clefts.
- Functional shifts i.e. pseudo Class III.

Alginate impressions were taken for each patient and poured in stone twice as working and pretreatment models.

Class III splints were fabricated from two acrylic splints totally covering the maxillary and mandibular arches and extending up to a few millimetres short of the buccal and lingual sulci. Adams' clasps were used on the primary second molars with the possible addition of ball clasps between the canine and primary first molar for retention. Hooks were placed distal to the upper second primary molar and mesial to the lower primary canine for elastic placement. (Fig.1)

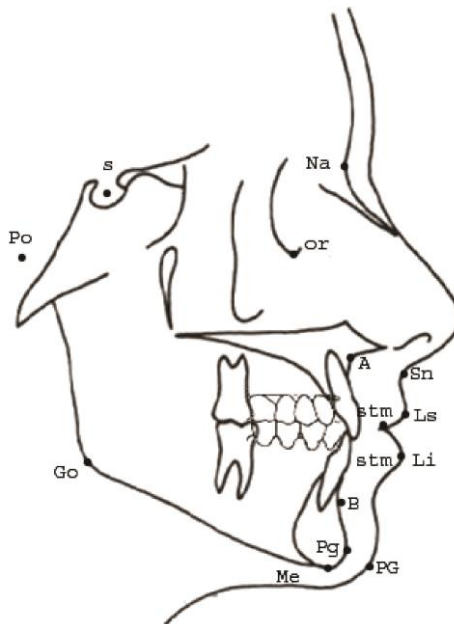
The splints were inserted and the patients were instructed on the way to insert the elastics where a force of 500gm per side was used. The force was calibrated using a force gauge and the appropriate size of elastics was chosen accordingly. Instructions on oral hygiene and appliance cleaning were also given.

The patients were instructed to wear the appliance all day long except for meals. Patients were regularly checked on monthly basis till the complete correction of the anterior crossbite was achieved.



**Fig (1):** The class III splint used in the study

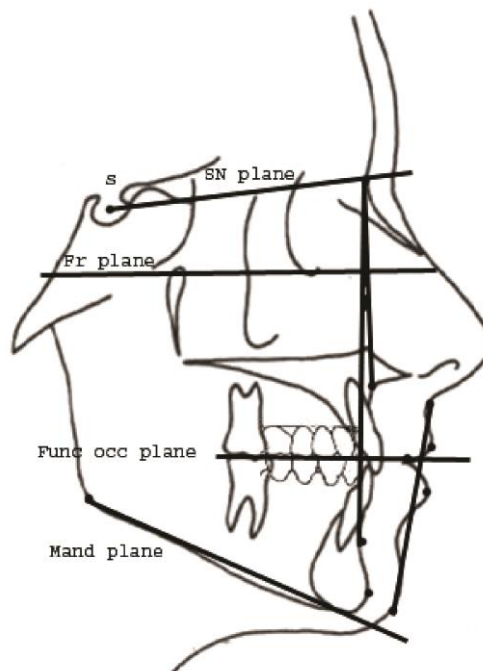
Pre and post treatment panoramic and lateral cephalometric X-rays were obtained. Lateral cephalometric X-rays were traced twice on acetate paper using a 0.5 lead pencil and skeletal and dental landmarks were identified (fig 2) then skeletal, dental and soft tissue planes were constructed (fig 3):



**Fig (2):** skeletal and soft tissue landmarks identified on the lateral cephalometric X-ray

**Soft tissue landmarks:**

- Sn: Subnasale: point located at the junction of the columella and the upper lip.
- Ls: Labiale superior: the most anterior part on the convexity of the upper lip.
- Li: Labiale inferior: the most anterior part on the convexity of the lower lip.
- Pg': Soft tissue pogonion: the most anterior part on the soft tissue chin.
- Stm<sup>s</sup>: stomion superuis: the most inferior point on the upper lip.
- Stm<sup>i</sup>: stomion inferuis: the most inferior point on the lower lip.



**Fig (3):** skeletal and soft tissue planes constructed on the lateral cephalometric X-ray.

**Skeletal and dental measurements:**

- SNA angle, SNB angle, ANB angle and SNPg angle
- Upper incisor to Frankfurt plane angle.

- Lower incisor to mandibular plane angle.
- Upper to lower incisor angle.
- Incisor overbite in mm.
- Incisor overjet in mm.
- Wits appraisal.
- Frankfurt to Mandibular plane angle.
- S-gonion/N-menton.

**Soft tissue measurements:**

- 1- Upper lip thickness. (mm) Ls to Sn-Pg'.
- 2- Lower lip thickness. (mm) Li to Sn-Pg'.
- 3- Upper lip length. (mm) Sn to Stm<sup>s</sup>
- 4- Lower lip length. (mm) Pg' to Stm<sup>i</sup>

**Reliability of landmark identification and measurements:**

All the X-rays were traced and measured by the author twice with an interval of at least one week in between to calculate the random error. The permissible error was 0.5 mm. when the difference in measurements was found to be more than 0.5 mm or 0.5° a third measurement was taken and the mean of the nearest two was used.

**Statistical analysis:**

The statistical package SPSS for windows V & O was used to perform the following:

- 1- Calculation of the mean and standard deviation of each measurement before and after treatment.
- 2- Paired T-test was applied to the variables to determine the significance of the changes after treatment.

**RESULTS**

All the patients included in this study showed marked improvement in their profiles after the anterior cross bite was resolved.

Table (1) shows that several skeletal measurements were altered to the better, namely the SNA angle which was significantly increased.

The SNB angle was also significantly decreased which caused a significant increase in the ANB difference and Wits appraisal.

The Frankfurt mandibular plane angle increased significantly although the ratio of anterior to posterior face height was not significantly altered.

**Table (1):** Descriptive statistics and Paired t-test for skeletal measurements

	<b>Pre Mean ± SD</b>	<b>Post Mean ± SD</b>	<b>Paired t test</b>	<b>P value</b>
<b>SNA</b>	78.00 ± 1.30	80.06 ± 1.31	6.99	<0.0001*
<b>SNB</b>	79.94 ± 1.65	78.00 ± 1.94	4.16	0.003*
<b>ANB</b>	-1.94 ± 0.81	1.94 ± 0.98	8.85	<0.0001*
<b>Snpg</b>	79.94 ± 1.90	79.06 ± 2.05	1.99	0.08 NS
<b>Wits</b>	-3.56 ± 2.23	2.11 ± 2.47	9.71	<0.0001*
<b>FMA</b>	29.67 ± 5.90	31.00 ± 5.41	4.00	0.004*
<b>NMe/SGo</b>	60.11 ± 5.06	59.67 ± 4.58	1.00	0.35 NS

\*: Statistically significant at  $P \leq 0.05$

NS: Not statistically significant

Table (2) illustrates a significant increase in the inclination of the upper incisors and significant retroclination of the lower incisors accompanied by a significant increase in the overjet. The overbite did not change significantly.

**Table (2):** Descriptive statistics and Paired t-test for Dental measurements

	<b>Pre Mean ± SD</b>	<b>Post Mean ± SD</b>	<b>Paired t-test</b>	<b>P value</b>
<b>1/md.plane</b>	88.33 ± 5.15	82.78 ± 5.26	8.87	<0.0001*
<b>1/Fr. plane</b>	111.89 ± 3.95	115.44 ± 2.24	4.64	0.002*
<b>1/1</b>	129.78 ± 7.58	134.89 ± 7.57	4.16	0.003*
<b>Overbite</b>	1.11 ± 1.22	1.61 ± 0.70	1.34	0.22 NS
<b>Overjet</b>	-2.17 ± 1.09	1.83 ± 0.56	8.62	<0.0001*

\*: Statistically significant at  $P \leq 0.05$

NS: Not statistically significant

The soft tissue profile changes were in the form of a significant decrease in thickness and increase in length of the lower lip.(Table 3)

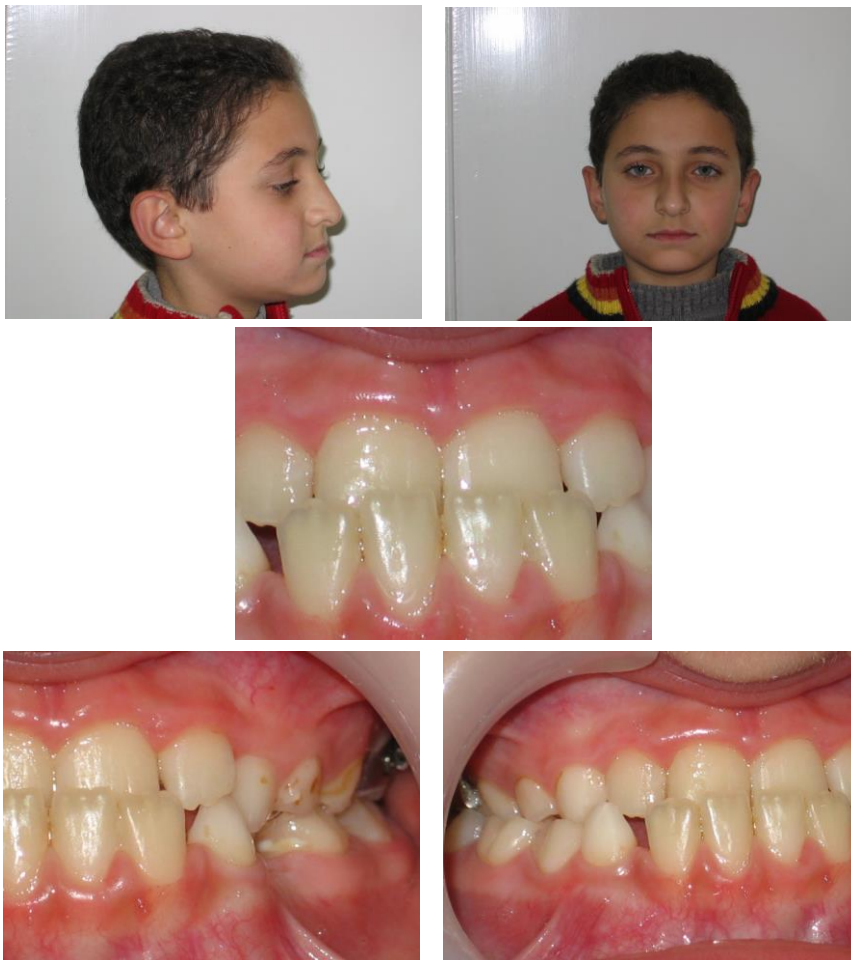

**Table (3):** Descriptive statistics and Paired t-test for Soft tissue measurements

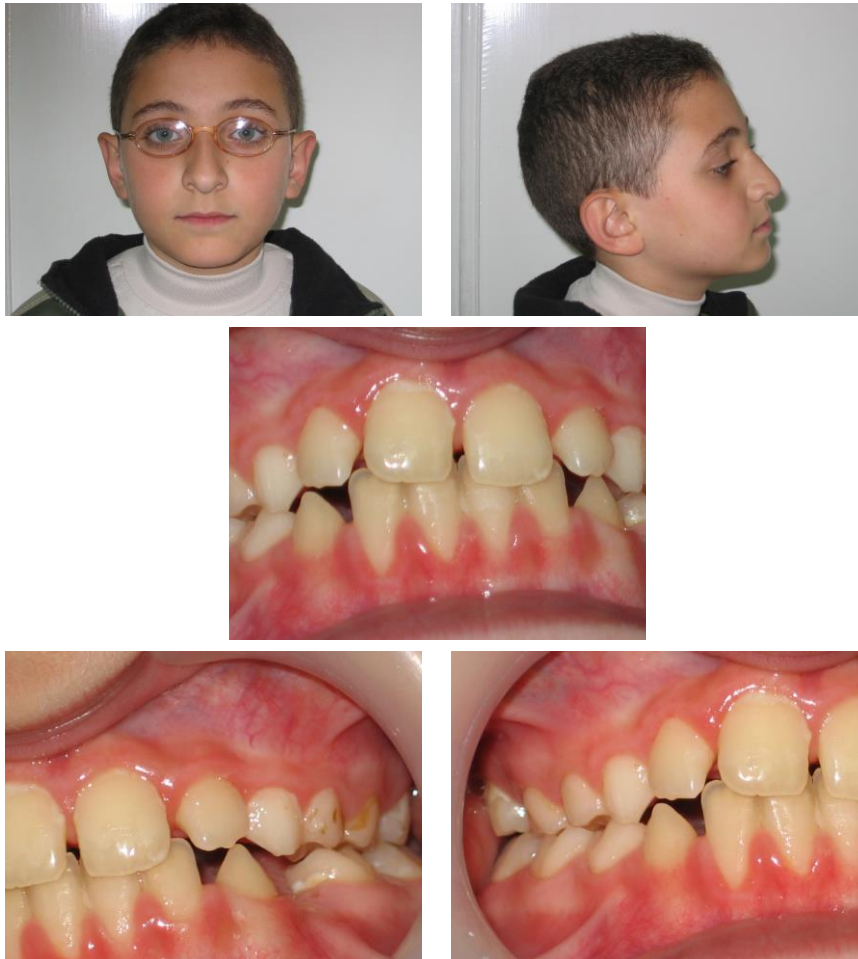	<b>Pre Mean ± SD</b>	<b>Post Mean ± SD</b>	<b>Paired t-test</b>	<b>P value</b>
<b>U lip thick.</b>	3.28 ± 0.91	3.89 ± 1.05	1.50	0.17 NS
<b>L lip thick.</b>	6.56 ± 1.24	4.17 ± 1.20	6.99	<0.0001*
<b>U lip length</b>	20.78 ± 2.86	20.89 ± 2.09	0.29	0.78 NS
<b>L lip length</b>	31.67 ± 2.60	34.11 ± 1.90	7.23	<0.0001*

\*: Statistically significant at  $P \leq 0.05$

NS: Not statistically significant



**Fig (3):** Pre treatment intraoral and extraoral photographs of patient 1



**Fig (4):** Post treatment intraoral and extraoral photographs of patient 1

## **DISCUSSION**

When a Class III child or adolescent presents for treatment no effort should be saved to utilize growth modification appliances in an attempt to improve the condition. For even if the results cannot be guaranteed it is worthwhile to normalize growth and improve the profile as much as possible.

The patients in this study were chosen in the age range of 8-10 years to ensure remaining growth potential. Some of the factors considered negative by some authors were not taken into consideration i.e. patients without functional shifts were included in the study; also patients with poor cooperation were motivated and included.

The appliance was worn for eight months to one year before the final treatment records were taken and without exception all the patient showed excellent clinical improvement and esthetic satisfaction.

The maxilla moved forward as evidenced by the significant increase in the SNA angle, this implies a skeletal effect of the appliance. This is in accordance with the results of Franchi and Baccetti<sup>(20)</sup> who showed a skeletal effect on the maxilla. While these results don't agree with the results of El Kenany and Ismail<sup>(21)</sup> who attributed the improvement only to dental changes.

The mandible was positioned more backward as evidenced by a decrease in the SNB angle, although that was probably because the mandible rotated backward and downward with an increase in mandibular steepness. This is similar to the observation of several authors regarding the action of the Frankel III appliance Ulgen and Firatli<sup>(18)</sup>, and Baik and coworkers<sup>(19)</sup> who concluded that FR-III treatment effects are mainly the result of backward and downward rotation of the mandible and linguoversion of the lower incisors.

The reversed overjet (anterior cross bite) with which all the cases started changed into a positive overjet ranging from one to three millimeters.

The upper incisor proclination increased significantly whereas the lower incisor inclination decreased illustrating the dental changes as was the case with the research of El Kenany and Ismail<sup>(21)</sup> and Franchi and Baccetti<sup>(20)</sup>

The soft tissue profile of Class III is so typical to the patients that it showed vast improvement with a significant decrease in lower lip thickness and an increase in its length, although the upper lips did not change significantly neither in thickness nor in length. Class III splint is considered quite a simple appliance for the treatment of Class III malocclusion with a mild to moderate maxillary deficiency as compared to the facemask.

## **CONCLUSIONS**

- 1- The Class III splint causes skeletal effects in the form of slight point A advancement and mandibular clockwise rotation.
- 2- Upper incisor proclination and lower incisor retroclination resulted from the appliance wear with resultant correction of the anterior cross bite. No significant change in the overbite was observed.
- 3- A decrease in the lower lip thickness and an increase in its length improved the typical Class III profile.

## **REFERENCES**

- 1- Ngan P: Biomechanics of maxillary expansion and protraction in Class III patients. *Am J Orthod Dentofacial Orthop.* 121:582-583, 2002.
- 2- Ngan P: Early Timely Treatment of Class III Malocclusion. *Semin Orthod.* 11:140–145, 2005.
- 3- Joondeph DR: Early orthodontic treatment. *Am J Orthod Dentofacial Orthop.* 104:199-200, 1993.
- 4- O'Brien K, Wright J, Conboy F, et al: Effectives of early orthodontic treatment with the twin-block appliance: multicenter, randomized, controlled trial. Part 2: Psychosocial effects. *Am J Orthod Dentofacial Orthop.* 124:4, 88-494, 2003.
- 5- Turpin DL: Early Class III treatment. Unpublished thesis presented at 81st session of the American Association of Orthodontists, San Francisco, 1981 Quoted Ngan P: Early Timely Treatment of Class III Malocclusion. *Semin Orthod.* 11:140–145, 2005.
- 6- Baik H S: Limitations in Orthopedic and Camouflage Treatment for Class III Malocclusion. *Seminars in Orthodontics*, Volume 13, Issue 3, September 2007, Pages 158-174.
- 7- Ellis E.E. and McNamara J.A., Components of adult Class III malocclusion, *J Oral Maxillofac Surg.* 42 (1984), pp. 295–305.
- 8- Baik H.S., Han H.K., Kim D.J. and Proffit W.R., Cephalometric characteristics of Korean Class III surgical patients and their

- relationship to plans for surgical treatment, *Int Adult Orthod Orthognath Surg.* 15 (2000)119-128.
- 9- Sakamoto T, Iwase I, Uka A, et al: A roentgenocephalometric study of skeletal changes during and after chin cup treatment. *Am J Orthod.* 85:341-350, 1984.
  - 10- Wendell PD, Nanda R, Sakamoto T, et al: The effects of chin cup therapy on the mandible: a longitudinal study. *Am J Orthod.* 87:265-274, 1985.
  - 11- Mitani H, Fukazawa H: Effects of chin cup force on the timing and amount of mandibular growth associated with anterior reverse occlusion (Class III malocclusion) during puberty. *Am J Orthod Dentofacial Orthop.* 9:454-463, 1986.
  - 12- Cameron C.G., Franchi L., Baccetti T. and McNamara J.A., Long term effects of rapid maxillary expansion: a posteroanterior cephalometric evaluation, *Am J Orthod Dentofacial Orthop.* 121 (2002), pp. 129–135.
  - 13- Braun S: Extraoral appliances: a twenty-first century update. *Am J Orthod Dentofacial Orthop.* 125:624-629, 2004.
  - 14- Hata S, Itoh T, Nakagawa M, et al: Biomechanical effects of maxillary protraction on the craniofacial complex. *Am J Orthod Dentofacial Orthop.* 91:305-311, 1987.
  - 15- Ngan P, Hagg U, Yiu C, et al: Treatment response and long-term dentofacial adaptations to maxillary expansion and protraction. *Semin Orthod.* 3:255-264, 1997.
  - 16- Kapust A, Sinclair P, Turley P: Cephalometric effects of facemask/expansion therapy in Class III children: a comparison of three age groups. *Am J Orthod.* 113:204-212, 1998 J.A.
  - 17- McNamara Jr and S.A. Hugg, Functional regulator (FR-3) of Frankel, *Am J Orthod.* 88 (1985), pp. 409–424.
  - 18- Ulgen M. and Firatli S., The effect of the Frankel's function regulator on the Class III malocclusion, *Am J Orthod Dentofacial Orthop.* 105 (1994), pp. 561–567.

- 19- Baik H.S, Jee S.H, Lee K.J. and. Oh T.K.: Treatment effects of Frankel functional regulator III in children with Class III malocclusion, *Am J Orthod Dentofacial Orthop.* 125 (2004), pp. 294–301.19.
- 20- Franchi L, Baccetti T: Splint therapy skeletal Class Iii Malocclusion in the primary dentition. *J Clin Pediat Dent.* 1998;22:93-98.
- 21- El Kenany W, Ismail H: .Early treatment of Class III malocclusion using intraoral splints or face mask. A comparative study. *Egypt Orthod J.* 2001;20:1-13.