

## COMPARATIVE STUDY BETWEEN BONE HEIGHT CHANGES AROUND IMPLANTS PLACED USING STEREOLITHOGRAPHIC VERSUS CONVENTIONAL SURGICAL GUIDES

Azza Farahat Metwally\* and Amal Ali Swelem\*

### ABSTRACT

**Background:** Accuracy of implant placement using computer designed surgical guides as compared to conventional laboratory-processed guides has been investigated by many researchers. However there are no published articles on the effect of placing dental implants using computer-designed guides on bone height changes around the implants as compared to those placed using conventional guides.

**Purpose:** The aim of this study was to compare between bone height changes around dental implants placed using stereolithographic surgical guides versus conventional guides in completely edentulous patients rehabilitated with 2-implant supported mandibular overdentures opposed by conventional maxillary complete dentures.

**Methods:** This parallel randomized controlled trial (RCT) included 14 participants (age ranging from 50-60) with a mean age of 56.7 years who were selected based on specific inclusion criteria. Conventional maxillary and mandibular complete dentures were constructed for all participants who were then randomly divided into two equal groups (7 participants in each). All participants received two implants, 3.5 mm in width and 10 mm in length, in the mandibular inter-foraminal areas (canine region). However implants in Group I (Control) were placed using a conventional surgical guide while implants in Group II (Experimental Group) were placed using a stereolithographic surgical guide. After implants' osseointegration, all participants received ball attachment- retained mandibular overdentures. Bone height changes around the installed implants were evaluated with the aid of cone beam computed tomography (CBCT) scans. Measurements were recorded three times at 0 months, 6 months and 12 months after overdenture insertion and the changes were calculated and statistically analysed. Statistical significance was set at 5 %.

**Results:** All participants attended all follow up visits with no drop outs. None of the implants was lost presenting a 100% survival rate for both groups. After 6 months post-insertion, the mean bone loss was 0.32mm and 0.31mm for groups I and II respectively. After 12 months post- insertion, mean bone loss reached 0.61mm and 0.49mm for groups I and II respectively. There were no statistically significant differences between the two groups at both (6 and 12 months) follow-up periods.

**Conclusion:** Bone height changes around implants placed with stereolithographic surgical guides versus conventional guides were statistically insignificant with no relevant superiority of one guide over the other. Both surgical guides provided clinically successful implant treatment with a 100% survival rate for both groups during the one-year follow-up period.

\* Associate Professor, Removable Prosthodontic Department, Faculty of Dentistry, Cairo University, Egypt.

## INTRODUCTION

Effective implant placement does not only necessitate the achievement of successful osseointegration of dental implants, but it should also account for anatomic limitations and the restorative goals and demands. This encouraged clinicians to seek precise planning and accurate “prosthodontically-driven” positioning of implants to be able to achieve aesthetic and functional implant-supported restorations.<sup>1,2</sup> The standard protocol for dental implant diagnosis and treatment planning combines a radiographic template with cone beam computed tomography (CBCT) as a non-invasive and precise surveying technique.<sup>3-5</sup> After accomplishing proper diagnosis and planning, the radiographic template is usually converted manually to a surgical template to be used for implant placement. Although this manual conversion of a radiographic template to a surgical one is considered reasonably effective, it still remains subjective, as the accuracy of the surgical template cannot be verified radiographically.<sup>2</sup>

There has been a paradigm shift in implant treatment since the development of computer-guided implant surgery, where visualization of CT scan images is achieved through computer software programs<sup>6</sup> that allow for 3-dimensional (3D) viewing and pre-surgical evaluation by the use of computer-aided design (CAD) technology.<sup>7</sup> These programs also allow the placement of virtual implants to further assist the clinician in predicting the size as well as the position of the implants before the surgery.<sup>8</sup> Despite that, transferring this sophisticated pre-operative planning precisely to the surgical field remains challenging. Several novel approaches have been developed to overcome this issue, including the use of computer-aided manufacturing (CAM) technology to fabricate anatomic models and osseous-supported surgical guides. Both, CT scan computer files and the clinician’s implant planning, are utilized by the computer software to design then fabricate surgical guides. Stereolithography (SLA) is one of the CAM technologies. It is a rapid prototyping polymerization process in which

three-dimensional acrylic resin models and surgical guides that can intimately fit the osseous surface are fabricated by using a computer-guided laser beam which polymerizes a photosensitive liquid acrylic through a series of layers. Spaces for stainless steel drill-guiding tubes are designed in the hardened acrylic surgical guides, into which the metal cylinders are forced. The surgical guides would then be ready for clinical use.<sup>9</sup>

Accuracy of implant placement using computer designed surgical guides as compared to conventional laboratory-processed guides has been investigated by many researchers.<sup>1,2,10-22</sup> Most of these studies revealed that more accurate surgical implant placement was achieved with the computer designed surgical guides and that this improvement was statistically significant. However to the best of the authors’ knowledge there are no published articles on the effect of placing dental implants using computer-designed guides on bone height changes around the implants as compared to those placed using conventional guides. Hence the aim of the study was to compare between bone height changes around dental implants placed using stereolithography surgical guides versus conventional guides. The null hypothesis was that there would be no significant difference between the two methods.

## MATERIALS AND METHODS

### Patient selection and Study design

This study was a controlled parallel randomized controlled trial (RCT) to rehabilitate completely edentulous patients with mandibular overdentures supported by two implants placed with surgical guides that were constructed by two different methods. The study protocol was reviewed and approved by staff members of the Prosthodontic Department and Ethics Committee in the Faculty of Oral and Dental Medicine, Cairo University. 14 patients (age ranging from 50-60) with a mean age of 56.7 years) were selected from the

out-patient clinic, Prosthodontic Department, Faculty of Oral and Dental Medicine based on the following inclusion criteria: Selected cases had completely edentulous maxillary and mandibular arches, Angle Class-I maxillo-mandibular relationship, sufficient bone quality and quantity, moderately developed residual ridge for implant placement that is covered by firm muco-periosteum. Edentulous condition of all patients fell within Class I and II cases based on the Prosthodontic Diagnostic Index (PDI) classification system for complete edentulism.<sup>23</sup> Exclusion criteria included patients with uncontrolled systemic diseases such as hypertension, diabetes, or immunodeficiency, systemic diseases that may affect bone metabolism such as osteoporosis, acute or active infection in the proposed implant areas, psychiatric or physical problems that could affect patient's recall, past or present radiotherapy in the head and neck region as well as patients who are heavy smokers (>10 cigarettes/day). Eligible patients were thoroughly informed about the nature of the research and those who were willing to commit to attend all follow up periods were allowed to participate after signing a written informed consent form.

Thorough medical and dental histories were taken for all selected participants. Radiographic, extra and intra oral clinical examination were carried out. Participants were instructed to undergo certain laboratory investigations including blood glucose level, complete blood picture and liver function tests to evaluate their current medical status.

Conventional maxillary and mandibular complete dentures were constructed for all participants following the standardized traditional protocol of the Department. They were then randomly divided into two equal groups (7 participants in each). Randomization was done by asking each participant to choose between two opaque envelopes, each representing one of two surgical guide types (conventional or stereolithographic). All participants received two implants (Legacy, Implant Direct LLC, Malibu Hills, CA 91301-

USA), 3.5 mm in width and 10 mm in length, in the mandibular inter-foraminal areas (canine region) following the flapless surgical protocol. However implants in Group I (Control) were placed using a conventional surgical guide while implants in Group II (Experimental Group) were placed using a stereolithographic surgical guide. After implants' osseointegration, all participants received ball attachment- retained mandibular overdentures.

### **Radiographic Template construction and Radiographic Examination**

The mandibular denture of all participants was duplicated into clear acrylic resin to construct a radiographic template. It was checked intra-orally for stability and fitness. Any pressure areas were relieved to allow for its complete seating. Cone beam computed tomography (CBCT) was then carried-out while the patient was wearing the radiographic template and biting on cotton rolls. The maxillary denture was utilized to stabilize the radiographic template.

### **Surgical guide construction**

**For Group (I)**, the radiographic templates were modified to be used as surgical guides. U-shaped notches were made in the surgical stent at the proposed implants sites.

**For Group (II)**, Virtual implant planning was carried out and a CAD/CAM surgical guide was constructed as follows: CBCT image was obtained in digital Imaging and Communications in Medicine (DICOM) format. CBCT-based virtual implant and surgical planning was made using the Blue Sky Plan software program (Blue Sky Plan version 2.19, Blue Sky Bio) CBCT images in (DICOM) format were fed to the software. The proposed implant sites were identified by the radiolucent channels, previously prepared in the radiographic templates, and then evaluated for sufficient bone height and sufficient buccolingual width. The implants were virtually placed in the mandibular canine areas bilaterally following the anatomic and prosthetic guidelines and

parallelism between them was evaluated. Whenever the implants' positions were accepted; the surgical guide with two channels was designed. Those two channels were considered to receive prefabricated metallic sleeves as a guide for implant installation. Three holes were made on the facial surface of the virtual surgical guide, one in the midline and two at the first molar regions bilaterally, to allow the insertion of fixation screws that served to stabilize the surgical guide during surgery (**Fig. 1**). The virtual implant plan was then saved as a ".STL" file and sent to the lab for fabrication and printing of the surgical guide using the stereolithographic (SLA) rapid prototyping machine (**Fig.2**).

Once hardened, the polymeric prototype contains holes for metallic sleeves or drill-guiding tubes. These sleeves precisely guide the osteotomy drills, precluding the need for the pilot drills. These sleeves with specific dimensions were fitted through and seated into position in the surgical guide. They are provided by the simple guide Dentis system (DENTIS Co., LTD6 Center point Dr. La Palma, CA 90623, USA) to fit all implant drills (as they all have the same common shank size till bone contact level).

### Surgical and Implant installation Procedures

#### *For Group (I):*

The conventional surgical guide was inserted into the patient's mouth, evaluated for stabilization and patient comfort. Bilateral field block local anesthesia (4% articaine) was applied; then the implant positions were marked through the surgical guide with the aid of an explorer. A tissue punch was utilized to remove the mucosa covering the residual ridge at the proposed implants' sites. The surgical guide was re-inserted into the patient's mouth, and then subsequent drilling was made under copious irrigation. Implants were installed in their corresponding beds; primary stability of implants and their parallelism were verified. Covering screws were then threaded into the implants.

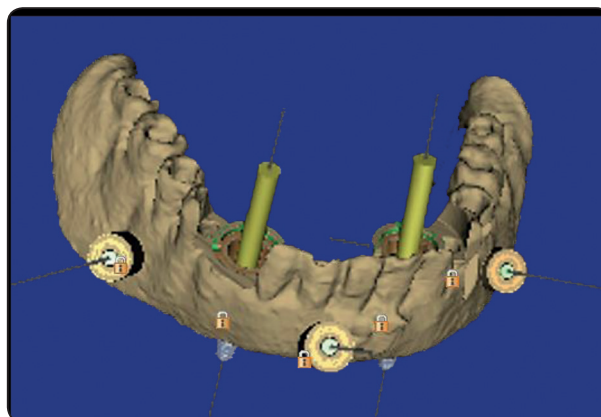


Fig. (1) The virtual surgical guide with channels for future implants and fixation screws

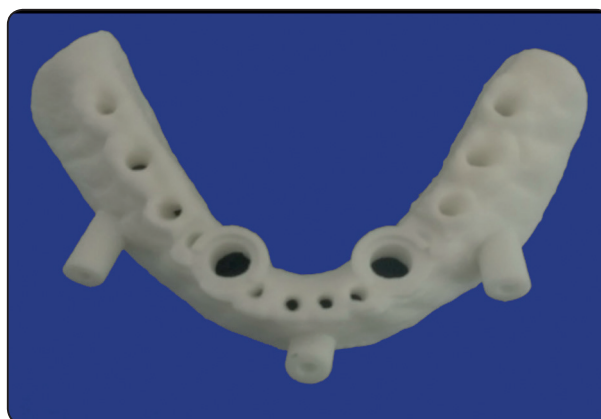


Fig. (2) The printed stereolithographic surgical guide

#### *For Group (II):*

The stereolithographic template was inserted in the patient's mouth. The maxillary complete denture was inserted and seated in place. The patient was then asked to bite on cotton rolls to stabilize the surgical guide. Under copious irrigation, an anchoring twist drill was used to drill into the bone through the holes that were prepared in the surgical guide for the fixation screws.

After anchoring the guide with all three fixation screws (**Fig. 3**), the patient was instructed to remove the maxillary denture. The surgical guide was then checked for adaptation and stability. Osteotomy was performed initially using four sequential drills of the simple guide from Dentis (DENTIS Co., LTD6



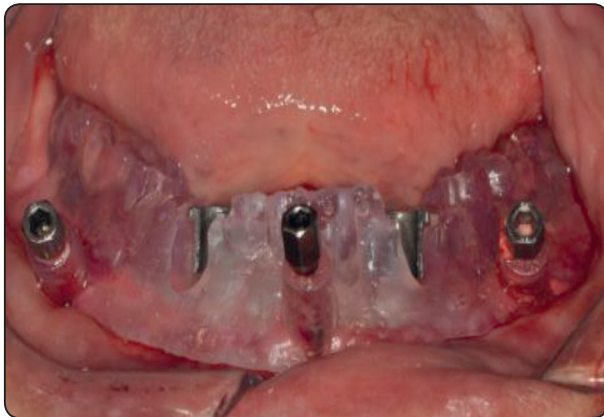

Fig. (3) The surgical guide after being stabilized by the fixation screws

Center point Dr. La Palma, CA 90623, USA). A cortical drill was utilized at first, then a drill of a 2.3 mm diameter and 8 mm length was used to drill the initial pathway in an up and down motion. Then a drill of 2.3 mm diameter and full length of the proposed implant was then used to continue drilling through the bone. Finally the final drill of the simple guide with 2.8 mm diameter and 10 mm length was used.

The fixation screws were un-tightened and the surgical guide was removed. The final drill from the Neobiotech surgical kit (Neobiotech Co. LTD, Seoul Korea) corresponding to the implant was used free hand to complete the shaping of the osteotomy site. Initially the implant was installed through the osteotomy manually then installation was continued using a ratchet until the top of the implant flushed with the bone surface. After complete installation, the covering screws were inserted and threaded onto the implants.

#### **Post- operative care and ball- attachment installation**

All participants were instructed not to wear their mandibular dentures for the next 48 hours and use antiseptic mouthwash (Antiseptol- El Nil) 2-3 times daily for three successive days. Cold soft diet was recommended. Antibiotic Augmentin (Augmentin

1g- Beecham MUP) 1gm was prescribed every 12 hours for the following five days. Brufen 600 mg (Ibuprofen, Knoll, Ludwigshafen, Germany) was prescribed as an analgesic and anti-inflammatory every 8 hours. Participants were instructed to recall the next day for check-up.

Three to four months later, participants were recalled to verify osseointegration. Once verified, participants were ready for second stage surgery. The surgical guide was used to locate the positions of the implants. Implants were exposed with a small crestal incision. A screw driver was used to unscrew the covering screws and Ball attachments (Ball abutment with collar height 1.6 mm, Zimmer dental, USA) were installed onto the implant fixtures (**Fig. 4**).

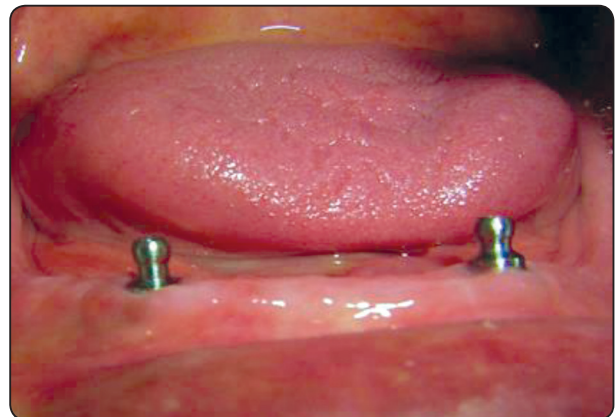


Fig. (4) The ball attachments screwed on to the corresponding implants.

After one week and after complete healing of the soft tissues around the implants, the metal housings of the attachments with their caps were placed over the attachment balls for the direct pick-up procedure. The fitting surface of the mandibular denture was sufficiently relieved to accommodate the attachment assembly. Two small holes were created in the lingual surface to allow for the escape of any excess resin. The relieved areas were filled with self-cure acrylic resin in the dough stage and the denture was re-inserted until complete and proper

seating was achieved. The patient was then guided to occlude into centric occlusion. After complete polymerization of the resin, the mandibular denture was removed (with the picked-up housings and caps). Any excess resin was removed, and the denture was adjusted to assure a comfortable and accurate fit. Dentures were then delivered to the participants who were instructed to follow strict oral and denture hygiene measures.

### Recall visits and Bone height measurements

For all participants, bone height changes around the installed implants were evaluated with the aid of CBCT scans. Mesial and distal crestal bone levels were calculated from the reconstructed corrected sagittal views by drawing a line parallel to the implant serrations extending from the crestal bone to the apical end of the implant. Each measurement was made three times then an average was calculated. Measurements were recorded at three occasions: at 0 months, 6 months and 12 months after overdenture insertion and the changes were calculated. During each recall visit, the oral and denture hygiene were assessed and re-emphasized upon to ensure the compliance of the participants to the hygiene instructions given.

### Statistical analysis

Data was statistically analyzed using SPSS software (SPSS 20.0; IBM Inc.) and presented as means and standard deviations. Data distribution

was tested for normality with the Kolmogorov-Smirnov test and found to be normally distributed. A paired t-test was conducted to detect any side (right and left) or site (mesial and distal) differences. No statistically significant differences were found between right and left implants and between the mesial and distal sides of each implant, so they were grouped for further analysis. A student t test was then performed to compare bone height changes between the two groups. Statistical significance was set at 5%.

### RESULTS

All participants attended all follow up visits with no drop outs. During the 12-months follow-up period, none of the implants was lost presenting a 100% survival rate for both groups. All participants maintained respectable oral and denture hygiene levels.

Mean bone height changes in both groups after 6 and 12 months follow-up are displayed in **Table 1**. After 6 months post-insertion, the mean bone height decreased in both groups by 0.32mm and 0.31mm for groups I and II respectively showing statistically insignificant differences between the two groups. At the end of the follow-up period (after 12 months post- insertion), mean bone height changes reached 0.61mm and 0.49mm for groups I and II respectively. Despite that the decrease in bone height was clearly greater in group I, yet this difference remained statistically insignificant.

Table (1) Mean bone height changes (in mm) in both groups after 6 and 12months follow-up

Follow-up period	Group I Conventional Guide	Group II Stereolithographic guide	P-value
	Mean ± SD	Mean ± SD	
0- 6 months	0.32 ± 0.14	0.31 ± 0.10	0.885
0-12 months	0.61 ± 0.17	0.49 ± 0.13	0.197

## DISCUSSION

The results of the current study accept the null hypotheses as there were no significant differences between bone height changes around implants placed using a computer guided stereolithographic surgical guide as compared with those placed using a conventional surgical guide.

It has been reported in the dental literature that bone loss around implants could be influenced by patient related factors such as age, gender, opposing occlusion, oral hygiene, medical conditions that compromise wound healing, smoking, arch in which the implants will be installed<sup>24-28</sup>, as well as, implant related factors such as implant design, implant size, location of implant placement and implant loading protocols.<sup>25,29,30</sup> Hence to ensure reliable and valid results, it was necessary to eliminate the influence of these variables on the study's outcome to assert as much as possible that the results obtained are solely and only due to the type of the surgical guide used. Therefore to eliminate the influence of implant related factors, the design, diameter, length and location of all implants were standardized in the current study, and the same traditional delayed loading protocol was followed in all cases. Due to the nature of the research however, it was not possible to conduct the comparison on the same patient, but the authors tried to control and restrict as much as possible the influence of patient-related factors on the results by following specific inclusion criteria. All participants were completely edentulous, they all wore complete dentures as the opposing occlusion, and all mandibular ridges lied within Class I and II categories based on the PDI index to ensure comparable bone quantity in all cases. All participants were relatively healthy and heavy smokers or those with uncontrolled systemic diseases or diseases that may affect bone metabolism were excluded. All implants were placed in the mandibular arch and in the intra-foraminal area (canine regions). All participants were of the same

age group however the convenient study sample included males and females as it was very difficult to standardize the gender of the participants with all other aforementioned inclusion criteria. This could be considered as a limitation of the current study.

Before discussing the results in detail it is worth mentioning that none of the implants were lost with a 100% survival rate indicating an equally comparable success rate for both groups in this aspect. Furthermore, the mean marginal bone loss recorded at the end of the one year follow-up for both groups did not exceed 0.7mm. This could be considered an exceptional outcome when compared to the "first-year 1.2 – 1.5mm" average bone loss that has been reported for successful standard implants.<sup>31,32</sup> Such finding could be attributed to several factors such as proper patient selection, compliance of the participants to the strict oral hygiene measures, as well as, restricting the opposing occlusion to complete dentures. Bone loss results in the current study do in fact coincide with those reported by **Ma and Payne**<sup>33</sup> who conducted a systematic review to critically evaluate the marginal bone loss in mandibular two-implant overdenture cases opposed by conventional complete maxillary dentures. They reported a first-year mean bone loss range of 0.2 to 0.7 mm for two stage loading protocols. As obvious from the results, mean bone loss values recorded in the current study lie within their reported range.

In-depth analysis of the results revealed that the mean bone loss was always greater in the conventional guide group when compared with the stereolithographic guide group with a one-year mean bone loss of 0.62 mm and 0.49 mm respectively. Direct comparison with other clinical studies was unfortunately not possible because as mentioned earlier, numerous studies compared between CAD/CAM surgical guides with conventional ones in terms of accuracy of implant placement,<sup>1,2,10-22</sup> however there are no published studies that compared between the two guide types in terms of

bone loss. Most of these studies reported that the CAD/CAM surgical guides were more accurate and improved implant placement significantly. In their study, **Sarment et al**<sup>1</sup> measured the angles formed between virtually planned implants and the actual implant osteotomies and found that the conventional guide resulted in an 8 degree deviation while the stereolithographic guide resulted in only 4.5 degree deviation. The average distance between the planned implant and the actual osteotomy was 1.5 mm 0.9 mm for the conventional and stereolithographic guides respectively at the implant head, and 2.1 mm and 1mm for the conventional and stereolithographic guides respectively at the apex. Similar findings were observed in an earlier study conducted by **Ersay et al**<sup>10</sup>, who reported an angular deviation of 4.9 degrees for stereolithographic surgical guides, and a mean linear deviation of 1.22 mm at the implant neck and 1.51 mm at the implant apex. They concluded that stereolithographic surgical guides are considerably reliable in implant placement. Taking into consideration that all other variables were standardized and controlled, such findings may imply that there could be a correlation between the accuracy of implant placement and bone height changes around implants. A suggested explanation to the findings of the current study could be that the stereolithographic surgical guides did indeed lead to more accurate implant placement which may have in turn helped in minimizing the non-axial forces falling on the implants and the prostheses. This consequently decreased the mechanical overload of the surrounding bone tissue hence resulting in less bone loss. However this still remains an assumption and such correlation has yet to be validated by scientific research.

It is only fair to say that despite that the mean bone loss was greater in the conventional guide group, yet the difference between the two surgical guides remained statistically insignificant. This statistically insignificant difference, in addition to the recorded mean bone loss values that lied

within the clinically acceptable range for both groups as mentioned earlier imply that, within this given one-year time frame, both conventional and stereolithographic surgical guides resulted in “clinically successful” implant treatment. Hence the superiority of computer-guided surgical guides over conventional ones cannot be proved to be clinically relevant when treating completely edentulous patients with two-implant supported mandibular overdentures opposed by conventional maxillary complete dentures. Such finding could be particularly favourable for such patients since it would certainly eliminate the additional costs of the CAD/CAM processing procedures. Somehow it could be considered favourable for some clinicians as well, because with no doubt such technology requires a skilfull clinician that does not only possess, but also be knowledgeable and experienced with these specialized computer software programs. That explains why some researchers recommend the use of computer guided surgical guides only for patients in whom simultaneous placement of multiple implants and complex restorations make additional planning and expenses necessary.<sup>1</sup>

Could the results have been statistically different in partially edentulous cases or completely edentulous cases where multiple implants are to be placed? This remains an un-answered question that could be a trigger for future research. Hence, future researches with a larger sample size, different prosthetic options and a more prolonged follow-up period are recommended for more definitive conclusions.

## CONCLUSION

Within the limitations of the current study and within the given one-year time frame and edentulous condition, it could be concluded that bone height changes around implants placed with stereolithographic surgical guides versus conventional guides were statistically insignificant



with no relevant superiority of one guide over the other. Both surgical guides provided clinically successful implant treatment with a 100% survival rate for both groups.

## REFERENCES

- Sarment DP, Sukovic P, Clinthorne N. Accuracy of implant placement with a stereolithographic surgical guide. *Int J Oral Maxillofac Implants*. 2003;18(4):571-7.
- Rungcharassaeng K, Caruso JM, Kan JY, Schutyser F, Boumans T. Accuracy of computer-guided surgery: A comparison of operator experience. *J Prosthet Dent*. 2015; 114(3):407-13.
- Todd AD, Gher ME, Quintero G, Richardson AC. Interpretation of linear and computed tomograms in the assessment of implant recipient sites. *J Periodontol* 1993; 64:1243-1249.
- Tepper G, Hofschneider UB, Gahleitner A, Ulm C. Computed tomographic diagnosis and localization of bone canals in the mandibular interforaminal region for prevention of bleeding complications during implant surgery. *Int J Oral Maxillofac Implants* 2001;16:68-72.
- Kourtis S, Skondra E, Roussou I, Skondras EV. Presurgical planning in implant restorations: correct interpretation of cone-beam computed tomography for improved imaging. *J Esthet Restor Dent* 2012;24:321-32.
- Cavalcanti MG, Yang J, Ruprecht A, Vannier MW. Validation of spiral computed tomography for dental implants. *Dentomaxillofac Radiol* 1998;27:329-333.
- Kraut RA. Utilization of 3D/Dental software for precise implant site selection: Clinical reports. *Implant Dent* 1992;1:134-139.
- Verstreken K, Van Cleynenbreugel J, Marchal G, Naert I, Suetens P, van Steenberghe D. Computer-assisted planning of oral implant surgery: A three-dimensional approach. *Int J Oral Maxillofac Implants* 1996;11:806-810
- Sarment DP, Misch CE. Scannographic templates for novel pre-implant planning methods. *Int Mag Oral Implantol* 2002;3:16-22.
- Ersoy AE, Turkyilmaz I, Ozan O, McGlumphy EA. Reliability of implant placement with stereolithographic surgical guides generated from computed tomography: clinical data from 94 implants. *J Periodontol*. 2008;79(8):1339-45.
- Ruppin J, Popovic A, Strauss M, Spintrup E, Steiner A, Stoll C. Evaluation of the accuracy of three different computer-aided surgery systems in dental implantology: optical tracking vs. stereolithographic splint systems. *Clin Oral Implants Res*. 2008;19(7):709-16.
- Park C, Raigrodski AJ, Rosen J, Spiekerman C, London RM. Accuracy of implant placement using precision surgical guides with varying occlusogingival heights: An in vitro study. *J Prosthet Dent* 2009;101:372-381.
- Valente F, Schirotti G, Sbrenna A. Accuracy of computer-aided oral implant surgery: a clinical and radiographic study. *Int J Oral Maxillofac Implants*. 2009;24(2):234-42.
- Ozan O, Turkyilmaz I, Ersoy AE, McGlumphy EA, Rosenstiel SF. Clinical accuracy of 3 different types of computed tomography-derived stereolithographic surgical guides in implant placement. *J Oral Maxillofac Surg*. 2009;67(2):394-401.
- Van Assche N, van Steenberghe D, Quirynen M, Jacobs R. Accuracy assessment of computer-assisted flapless implant placement in partial edentulism. *J Clin Periodontol* 2010;37:398-403
- Di Giacomo GA, da Silva JV, da Silva AM, Paschoal GH, Cury PR, Szarf G. Accuracy and complications of computer-designed selective laser sintering surgical guides for flapless dental implant placement and immediate definitive prosthesis installation. *J Periodontol*. 2012;83(4):410-9.
- D'haese J, Van De Velde T, Elaut L, De Bruyn H. A prospective study on the accuracy of mucosally supported stereolithographic surgical guides in fully edentulous maxillae. *Clin Implant Dent Relat Res*. 2012 Apr;14(2):293-303
- Giacomo GD, Silva J, Martines R, Ajzen S. Computer-designed selective laser sintering surgical guide and immediate loading dental implants with definitive prosthesis in edentulous patient: A preliminary method. *Eur J Dent*. 2014;8(1):100-6.
- Stübinger S, Buitrago-Tellez C, Cantelmi G. Deviations between placed and planned implant positions: an accuracy pilot study of skeletally supported stereolithographic surgical templates. *Clin Implant Dent Relat Res*. 2014;16(4):540-51.
- Noharet R, Pettersson A, Bourgeois D. Accuracy of implant placement in the posterior maxilla as related to 2 types of surgical guides: a pilot study in the human cadaver. *J Prosthet Dent*. 2014;112(3):526-32.

21. Geng W, Liu C, Su Y, Li J, Zhou Y. Accuracy of different types of computer-aided design/computer-aided manufacturing surgical guides for dental implant placement. *Int J Clin Exp Med*. 2015 15;8(6):8442-9.
22. Schnutenhaus S, Edelmann C, Rudolph H, Luthardt RG. Retrospective study to determine the accuracy of template-guided implant placement using a novel nonradiologic evaluation method. *Oral Surg Oral Med Oral Pathol Oral Radiol*. 2016;121(4):e72-9
23. McGarry TJ, Nimmo A, Skiba JF, Ahlstrom RH, Smith CR, Koumjian JH: Classification system for complete edentulism. *J Prosthodont* 1999; 8: 27- 39.
24. Manz MC. Factors associated with radiographic vertical bone loss around implants placed in a clinical study. *Ann Periodontol*. 2000 Dec;5(1):137-51.
25. Negri M, Galli C, Smerieri A, Macaluso GM, Manfredi E, Ghiacci G, Toffoli A, Bonanini M, Lumetti S. The effect of age, gender, and insertion site on marginal bone loss around endosseous implants: results from a 3-year trial with premium implant system. *Biomed Res Int*. 2014; 2014:1-7.
26. Veitz-Keenan A. Marginal bone loss and dental implant failure may be increased in smokers. *Evid Based Dent*. 2016 ;17(1):6-7.
27. Alfadda S. Current Evidence on Dental Implants Outcomes in Smokers and Non-Smokers: A Systematic Review and Meta-Analysis. *J Oral Implantol*. 2018 Jun 4. doi: 10.1563/aaaid-joi-D-17-00313. [Epub ahead of print]
28. Al Zahrani S, Al Mutairi AA. Stability and bone loss around submerged and non-submerged implants in diabetic and non-diabetic patients: a 7-year follow-up. *Braz Oral Res*. 2018; 10;32:e57.
29. Stein AE, McGlmpy EA, Johnston WM, Larsen PE. Effects of implant design and surface roughness on crestal bone and soft tissue levels in the esthetic zone. *Int J Oral Maxillofac Implants*. 2009;24:910–919.
30. Kim SY, Dodson TB, Do DT, Wadhwa G, Chuang SK5. Factors Associated With Crestal Bone Loss Following Dental Implant Placement in a Longitudinal Follow-up Study. *J Oral Implantol*. 2015;41(5):579-85.
31. Henry P., Bower R. and Woolridge J. Radiographic evaluation of marginal bone height around titanium implants. *J. Dent. Res*. 1988 ; 67: 629.
32. Albrektsson T, Isidor F. "Consensus report of session I," in *Proceedings of the 1st European Workshop on Periodontology*, N. P. Lang and T. Karring, Eds., pp. 365–369, Quintessence Publishing, London, UK, 1994.
33. Ma S, Payne AG. Marginal bone loss with mandibular two-implant overdentures using different loading protocols: A systematic literature review. *Int J Prosthodont* 2010; 23:117-26.