

EFFECT OF SOFT LINER FEMALE HOUSINGS RETAINING MANDIBULAR TWO IMPLANT-SUPPORTED OVERDENTURES ON HAND GRIP STRENGTH AND PATIENT SATISFACTION IN EGYPTIAN MALES

Elsayed A. Abdel-Khalek*

ABSTRACT

Introduction: Loss of natural teeth could make food consumption very difficult and leads to malnutrition that is associated with muscle wasting. It is well known that implant-supported mandibular overdentures increase the functional outcome, masticatory performance, nutritional status and patient's satisfaction compared with conventional complete dentures. The study aimed to evaluate the satisfaction and hand grip strength (HGS) for patients treated with two implant-supported mandibular overdentures retained by soft liner female housings with either bar or ball attachments and opposed by maxillary conventional dentures.

Materials and Methods: Twenty-one completely edentulous Egyptian males were selected with a mean age of 59.4 years and ranged between 53 and 67 years. Patients were allocated randomly into two groups: Group A (n=12) patients received Hader bar design connecting both implants in a straight line with soft liner female housing to retain the overdentures. Group B (n=9) patients received two ball patrices with soft liner female receptacles to retain the implant overdentures. Patient satisfaction was measured by using 100 mm VAS questionnaire and Hand grip strength (HGS) was recorded by using handheld JAMAR dynamometer. Patients were recalled for measurements at baseline with conventional dentures before implant placement (T0) and then 6 months (T6) and 12 months (T12) after overdenture insertion. All statistical tests were 2-tailed at the 5% level of significance.

Results: From the pairwise statistical analysis, it was noticed that significant satisfaction VAS values for bar group were higher in comparison to ball group in relation to retention and stability. Bar group revealed significantly higher HGS values from the baseline, while, Ball group exhibited no significant differences between times of observation.

Conclusion: Overdentures retained by soft liner around Hader bars splinting two implants may be beneficial for edentulous patients with impaired nutritional status manifested by weak hand grip.

* Lecturer of Removable Prosthodontics, Faculty of Dentistry, Mansoura University, Egypt.

INTRODUCTION

Edentulism can lead to a significant functional impairment, unfavorable aesthetic, and psychological changes in old patients.⁽¹⁻³⁾ Loss of natural teeth could make food consumption very difficult and leads to malnutrition that is associated with muscle wasting.⁽⁴⁻⁶⁾ Even with conventional denture treatment, complete denture wearers frequently consume soft mashed food rather than the intake of healthy, hard-to-chew foods that may lead to a decline in muscle strength of the body.⁽⁷⁻⁹⁾

It is well known that implant-supported mandibular overdentures increase the functional outcome, masticatory performance, nutritional status and patient's satisfaction compared with conventional complete dentures.^(4,7,10-12) The use of two interforaminal implants to stabilize dentures has been regarded as the gold standard of care for edentulous mandibles.⁽¹³⁾ Bar designs, telescopic crowns, Locators, balls, and magnets have been employed as attachment systems for implant overdentures and most of them consist of frictional contact between a matrix and a patrix.^(10,14,15)

Splinting effect and load sharing between the implants were the advantages of bar attachments.^(12,16) Lower incidence of prosthetic complications and higher retention were also reported when compared to stud-type attachments.⁽¹⁷⁻¹⁹⁾ On the other hand, the preferred use of solitary attachments is mainly due to the smaller space requirements, ease of cleaning, technical simplicity and cost effectiveness.^(15,20)

Despite the literature couldn't reveal significant difference between overdenture attachments, the decision for selecting bar or solitary attachments was based on the anatomical variations, the number of implants, and interimplant distance employed.^(14,16,18,20,21)

In this regard, wear and plastic deformation of the nylon inserts or clips was documented to be the most common complications associated

with overdenture attachments because of denture base rotations.^(10,14,15,21) Soft liner female housings with bar attachment had been reported with many advantages in clinical studies.^(16,22) Use of resilient liners to retain overdentures offered a unique space obturation around the bar, higher retentive force, cushion-effect against masticatory loads, and improved peri-implant tissue health.^(16,23,24)

Beside these merits, soft liner can solve many problems when the implant locations or angulations differ from the proposed treatment plan.^(20,25) Preservation of male parts from abrasion makes soft liner female receptacles a simpler, inexpensive method as an attachment for overdentures.^(14,15,26)

There are a limited number of studies, mostly in vitro, that have used the soft liner as a female housing with ball attachment system.^(25,26) However, the literature lacks clinical studies that compare between bars and ball patrices retaining overdentures by using soft liner housing.

Stabilizing the mandibular dentures by two dental implants could improve the mastication and offers a wide range of food choice to the patients, consequently, strengthen skeletal muscle of the body that reflected on the hand grip force.^(5,6)

Therefore, the present study aimed to evaluate the satisfaction and hand grip strength (HGS) for patients treated with two implant-supported mandibular overdentures retained by soft liner female housings with either bar or ball attachments and opposed by maxillary conventional dentures.

MATERIALS AND METHODS

Twenty-one completely edentulous Egyptian males were selected from Department of Removable Prosthodontics. Their mean age of 59.4 years and ranged between 53 and 67 years. The study protocol was discussed in detail with each patient, and then a signed consent was obtained. The study was approved by the local ethical committee.

Patients were evaluated and recruited for this study according to the inclusion criteria. Eligible patients were able to answer the questions and they had been willing to comply with implant procedures. The selected participants were required to have panoramic radiograph with at least 15 mm bone height in the anterior mandibular region. A sufficient bone width existed to accommodate two implants of minimum 4 mm diameter without grafting procedures. A minimum of approximately 15 mm of vertical space from the ridge crest to the occlusal plane was necessary (Class I restorative space according to Ahuja and Cagna.⁽²⁷⁾)

Patient were excluded when they had insufficient mandibular bone volume, psychologic problems with the acceptance of a removable denture, less than 1 year of total edentulism. Exclusion criteria also included presence of administrative, local or systemic conditions that would contraindicate the implant placement. Participants with bone metabolic diseases, neuromuscular disorders, blood disorders, radiotherapy to the head and neck region, and smoking habits were also excluded.

Complete denture treatment was fabricated according to a standard protocol that included preliminary impressions with irreversible hydrocolloid (*Cavex CA37, Holland*), zinc-oxide non-eugenol paste (*Cavex outline, Holland*) for final impressions and the artificial teeth were arranged in lingualized balanced occlusion. All dentures were processed by the same commercial laboratory using the same laboratory procedures, artificial teeth and denture base materials. Patients should wear their new well-fitted dentures for at least 2 months from insertion appointment. Baseline measurements (T0) were recorded at the appointment of implant surgery immediately before administering the local anesthesia .

Each patient was operated under local anesthesia and received two interforaminal mandibular tapered implants (*Biohorizon, USA*) according to two-stage surgical protocol.

An osseointegration period of 4 months was maintained with the conventional dentures in situ after relining with temporary resilient liner (*Acrostone soft, Egypt*) followed by occlusal adjustments. At the appointment of 2nd stage surgery, a tissue punch was used to expose the oseointegrated implants to connect the healing abutments for two weeks.

Patients were allocated randomly into two groups:

- Group A (n=12) patients received Hader bar design (*VSP-GS, Bredent, Germany*) connecting both implants in a straight line with soft liner female housing to retain the overdentures (Fig. 1).
- Group B (n=9) patients received two ball patrices (*Biohorizon, USA*) with soft liner female receptacles to retain the implant overdentures (Fig. 2).

All patients received mandibular implant-supported overdentures opposed to the existing maxillary conventional dentures. For bar group, a functional dual impression was recorded for each patient by using long pin transfer coping to relate the implants to the residual ridge and then a stone cast was poured. Burn-out plastic abutments were screwed into the implant analogues and connected by a segment of plastic Hader bar pattern. The plastic bar assembly was cast into Co-Cr using lost-wax technique. Converting the existing mandibular denture into implant overdenture was performed for ball group while new mandibular prostheses were constructed for bar group.

At the appointment of overdenture insertion, the healing abutments were removed and then ball or bar abutments of suitable gingival height were screwed and tightened to 25 Ncm with a torque controller. Suitable recesses were prepared in the fitting surface of the denture base ensuring no contact to the attachment patrices. The space under the bar attachment was blocked-out by soft utility wax. Overdentures were lined with autopolymerized

silicone soft liner (*Softliner, Promedica, Germany*) as a female housing over the patrices while the patient close in maximum intercuspal position. Patients were scheduled for postoperative care and occlusal adjustments, if necessary. The same investigator did all surgical and prosthetic procedures in this study.

Patient were recalled to measure their satisfaction and HGS with conventional dentures before implant placement (baseline, T0) and then 6 months (T1) and 12 months (T2) after overdenture insertion as follows:

(1) Patient's Satisfaction (VAS questionnaire)

Patient satisfaction with the overdenture was investigated through a questionnaire based on a visual analogue scale (VAS).^(2,12) Subjects were asked to answer the questionnaire frankly as a crossed mark on a 100 mm VAS scale. The levels of general satisfaction, as well as the stability, retention of their mandibular dentures, chewing comfort, ease of clean, speaking, esthetics and, function were recorded. The scale of each aspect was started from the right (0-mm), middle (50-mm), and to the left (100-mm) to score satisfaction ratings as 'not satisfied at all', satisfied, and 'completely satisfied', respectively. The sum of recorded data for each patient was calculated to give overall patient's satisfaction. The mean values and SD of patients' satisfaction in general and in specific aspects was calculated.

(2) Hand Grip strength measurement

Maximum HGS was measured with an adjustable handheld hydraulic dynamometer (*JAMAR dynamometer, Rolyan Ltd., UK*). Patients were seated comfortably on a chair without armrests (Fig. 3), the elbow flexed 90 degrees, with the forearm and wrist in neutral position. After adjusting the handle for hand size and demonstrating the technique, participants were asked to squeeze the appliance with their maximum efforts as hard as possible and maintain that for approximately 3 seconds.⁽²⁷⁾ The subject's dominant hand only was used for the measurement three times expressed as kilograms separated by at least one minute rest period. A stronger hand grip reflected an improvement in nutritional and metabolic state. The mean value of the three recordings was calculated and used for analysis.

Statistical tests

Data were entered and statistically analyzed using the Statistical Package for Social Sciences (SPSS) version 20. Quantitative data were described as mean and standard deviation after testing normality by Kolmogorov-Smirnov test. Student's t-test was used for comparison between study groups. A one-way repeated measured ANOVA test was used to compare parametric variable at different times of measurements with Post Hoc LSD test to detect changes within group comparison. All tests were 2-tailed at the 5% level of significance.

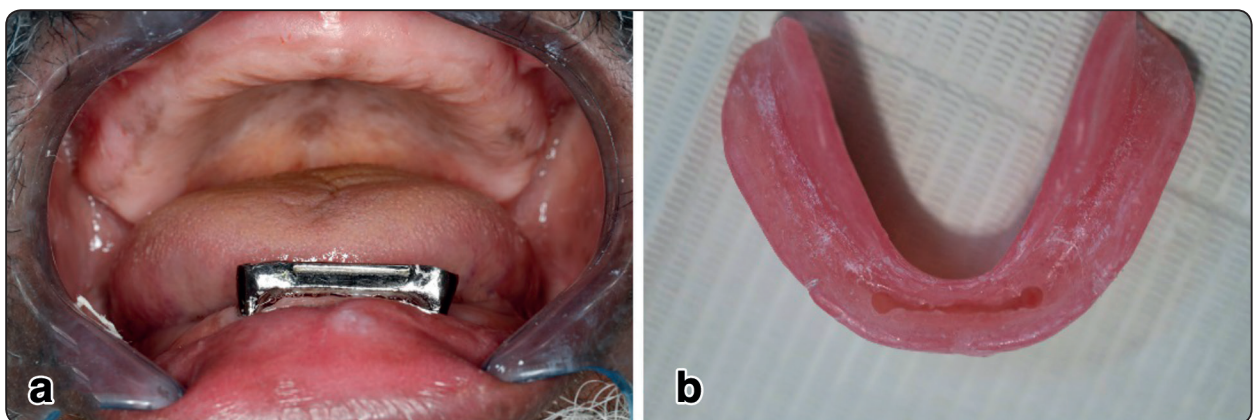


Fig. (1) Bar group involved; (a) straight Hader bar design (b) overdentures with soft liner female housing.

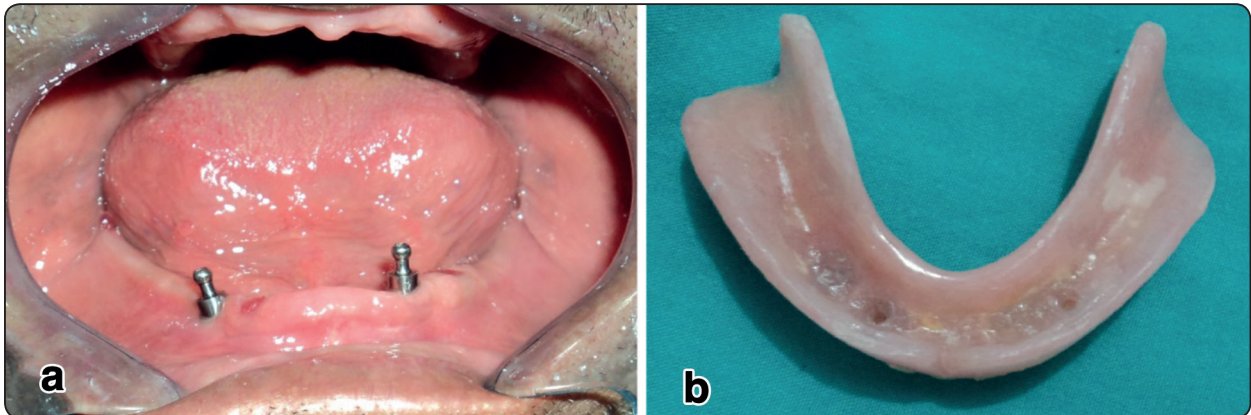


Fig. (2) Ball group involved; (a) two ball patrices (b) overdentures with soft liner receptacles.

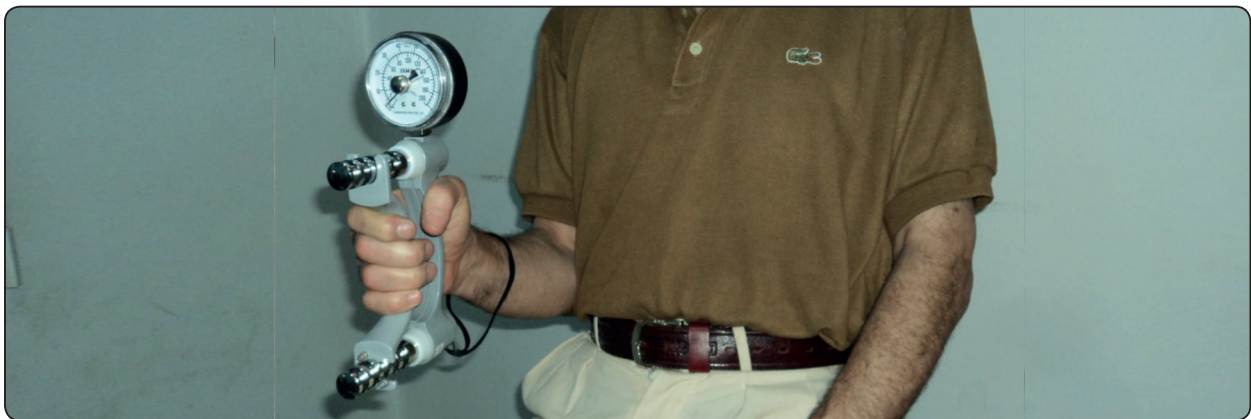

Fig. (3) Patient position for measuring hand grip strength by using JAMAR® dynamometer.

RESULTS

There was no patient dropped out from the study for any reason. All implants were 100% survived during the entire study period.

Table 1 summarized the mean values of the recorded VAS scores for both attachments retaining mandibular overdentures with soft liner female housings. The mean values were increased dramatically from the baseline (conventional dentures before implant placement). From the pairwise statistical analysis, it was noticed that significant satisfaction values for bar group were higher in comparison to ball group in relation to the VAS items of denture stability at T1 and denture retention at T2 after overdenture insertion.

Comparison between times of observations for overall satisfaction in both groups was shown by Table 2. The calculated overall satisfaction scores on the VAS questionnaire revealed a statistically significance difference between time points (T0, T1, T2) in each group. However, there were no significant differences between groups at each time point.

Table 3 compared the measured HGS for study participants. Bar group revealed significantly higher values from the baseline, while there was no significant differences between T1 and T2 after insertion of bar retained overdentures. Ball group exhibited no significant differences in the mean maximum value of HGS between times of observation.

TABLE (1) Satisfaction scores (100-mm VAS) for Bar group (n=12) and Ball group (n=9) at different time points.

VAS items	Bar Group			Ball Group		
	Baseline (T0) (X±SD)	6mo. (T1) (X±SD)	12mon. (T2) X±SD	Baseline (T0) (X±SD)	6mo. (T1) (X±SD)	12mon. (T2) (X±SD)
stability	40.75± 13.79	89.58± 2.84	92.17± 4.02	41.67± 13.74	83.22± 7.64	89.33± 4.63
retention	60.67± 9.63	93.08± 5.63	93.17± 4.06	51.33± 12.70	87.78± 5.84	86.56± 6.98
Chewing comfort	48.08± 4.90	88.83± 3.73	90.75± 3.81	56.56± 10.52	90.89± 3.75	91.11± 2.62
ease of clean	91.00± 4.39	89.17± 4.72	89.50± 4.85	91.78± 3.96	91.67± 3.93	91.89± 2.80
speaking	42.75± 7.829	76.75± 9.37	84.50± 6.00	42.89± 10.30	81.11± 7.04	83.44± 7.66
esthetics	86.58± 7.55	88.42± 5.71	89.92± 5.05	90.89± 5.01	90.44± 3.00	92.56± 5.50
function	36.92± 6.69	78.00± 6.15	84.33± 8.42	41.00± 8.515	82.56± 4.87	87.11± 5.73
general satisfaction	47.00± 7.31	88.83± 3.95	92.25± 3.13	48.78± 8.969	93.00± 4.387	95.44± 1.51

VAS: visual analogue scale

X: Mean

SD: standard deviation

TABLE (2) Comparison of calculated overall patient's satisfaction between groups and within subjects in each group.

	Time of observation			p-value
	T0 (X±SD)	T1 (X±SD)	T2 (X±SD)	
Bar	56.83± 2.44 ^a	86.58± 2.23 ^b	89.67± 1.72 ^c	.000*
Ball	58.33± 3.742 ^e	87.78± 3.03 ^h	89.89± 1.69 ^f	.000*
p-value	.314	.336	.771	

X: Mean

SD: standard deviation

*: statistically significant at probability of error ≤0.05

Similar superscripted letters in same row denote non-significant difference

TABLE (3) Comparison of recorded HGS between groups and within subjects in each group.

	Time of observation			p-value
	T0 (X±SD)	T1 (X±SD)	T2 (X±SD)	
Bar	30.42± 5.77 ^a	41.08± 5.28 ^b	41.33± 5.67 ^{b,c}	.001*
Ball	29.56± 3.67 ^{g,f}	32.78± 6.57 ^{g,h}	34.11± 6.37 ^{h,f}	.109
p-value	.682	.007*	.016*	

X: Mean

SD: standard deviation

*: statistically significant at probability of error ≤0.05

Similar superscripted letters in same row denote non-significant difference

DISCUSSION

Malnutrition is a well-recognized disease in the edentulous elderly because they consume more frequently softer and mashed food.⁽⁸⁾ The stabilization of mandibular complete dentures by means of osseointegrated implants could improve the masticatory efficiency, food choice, skeletal muscle forces, and subsequently the hand grip force.^(5,6)

Subjective and objective measures of outcome had been recognized as important fundamentals in prosthodontic treatment.⁽³⁾ VAS are commonly used to measure satisfaction with dentures, particularly with respect to comfort.^(2,12) This validated questionnaire has been found to be sensitive in the edentulous population.⁽¹²⁾

On the other hand, HGS was reported as a major parameter of physical performance and it has been repeatedly used to diagnose musculoskeletal function as a predictor of poor nutritional status.^(9,27,29) The present study was conducted on males taking into consideration substantial sex differences in HGS that was reported in the literature.⁽²⁹⁾ HGS was also significantly associated with age and dominant hand, however, all patients in this study fall in the same category of age and they were encouraged to only use their dominant hand (right or left) to avoid bias.

Because of its fast, easy application, and long-term viscoelastic properties; addition silicone soft liner was used in the present study keeping in mind to provide sufficient thickness of rigid denture base to resist fracture.^(24,27)

Initial measurements for baseline were recorded after 2-months from conventional denture insertion, to allow sufficient time for denture adaptation and post-insertion adjustments. This adaptation period has been considered as necessary to assess satisfactory use with the new dentures and to establish new memory patterns for the masticatory muscles, particularly for mandibular dentures.⁽³⁾ Accordingly, Mericske-Stern et al.⁽¹²⁾ stated that such post-insertion complications were often initially observed

after delivery of the dentures, and then they eventually disappeared over time.

Because of a lack in similar studies, bar group in this study could be compared to previous studies on soft liner housing. Elsyad et al.⁽¹⁶⁾ reported 100% survival rate without any implant failures even after 7 years of follow-up.

The results of the current study agreed with literature that implant-supported overdentures in both groups (ball or bar patrices) dramatically improved participants' overall satisfaction in comparison with the conventional dentures.^(2,17) These results concurred with Awad et al.⁽¹⁾ whose findings showed that the mandibular 2 implants ball-retained overdenture opposed by a maxillary conventional denture had significantly better oral function.

The study observed that satisfaction with denture stability was higher for bar group after 6 months that could be attributed to the vertical rigid walls that resist horizontal prosthesis movements under function. Moreover, soft liner housing provide a larger contact area to the bar with greater amount of adaptation and proper retention by friction.⁽¹⁹⁾ Also, an in vitro study reported that the key-hole cross section of Hader bar could allow deeper retentive undercuts compared to other bar cross sections.⁽²⁴⁾ The observed reduction in retention ratings for ball group after 12 months may result from plastic deformation of the soft liner receptacle in response to the denture rotation around the anteriorly placed implants as well as frequent removal and insertion of overdenture overtime.^(14,24)

The current study failed to identify differences in cleaning the patrices of both group when pairwise comparisons were performed. This finding confirmed that the resilient liners obturate the spaces within the denture, provide direct contact with the bar surface, continuously clean the bar and the abutments by frictional contact.^(22,23)

There were no significant differences among the overdenture groups in overall satisfaction at specific time of observation. These results may be attributed to the adaptability of patients to their chewing patterns with overdentures after a period of time.⁽¹²⁾ In this line, Stoumpis and Kohal⁽¹⁷⁾ reported that attachment mechanism did not have a notable effect on general patient satisfaction but it affected the aspect of prosthesis retention. However, the significant increase of overall satisfaction overtime confirmed the improved neuromuscular activity of the masticatory system, as the time extended, particularly after connecting the mandibular denture to the implants.^(3,30)

The initial measurements of HGS for men in the present study were within the acceptable range (27 kg) for a similar age-group estimated by Dodds et al.⁽²⁹⁾ Despite increasing the satisfaction by time for both group, the significant improvement in HGS from baseline was only observed for bar overdenture with no differences between 6 and 12 months of overdenture use.

The study revealed a significant increase in improvement of HGS with bar overdentures compared to ball overdentures. The significant increase for bar group could be explained by the ability to generate more chewing forces to consume harder food such as fruits and vegetables as a consequent to better overdenture stability provided by the bar framework.^(3,8,11) As the overdenture stability increases, the chewing ability and maximal biting force will increase and they stimulate salivary secretion from the parotid gland to facilitate the mastication.^(7,12)

The current study agrees with published studies that good retention may be the most important factor for the patient satisfaction.⁽¹²⁾ In the contrary, increasing the overdenture stability may significantly affect the food choice and nutrients intake that could be reflected on HGS.^(3,4,9,29)

The present study was limited by the following; Patient satisfaction with mandibular denture may be influenced by the stability of the maxillary complete denture. Variations in the retentive forces may be related to the dimensions and size of the ball attachment to enable the soft liner to engage deeper undercuts.⁽¹⁴⁾ The long-term effect of overdentures retained by ball patrices and soft liner receptacles on peri-implant tissues as well as on prosthetic events was highly recommended for further investigations.

CONCLUSION

Within this male limited study, it could be concluded that:

- Mandibular overdentures retained with two implants and soft liner housing could improve patients' satisfaction and hand grip strength compared to conventional complete dentures.
- Overdentures retained by soft liner around Hader bar splinting two implants may be beneficial for edentulous patients with impaired nutritional status manifested by weak hand grip.

REFERENCES

1. Awad MA, Lund JP, Dufrense E, et al. Comparing the efficacy of mandibular implant-retained overdentures and conventional dentures among middle-aged edentulous patients: satisfaction and functional assessment. *Int J Prosthodont.* 2003;16:117–22.
2. Sánchez-Siles M, Ballester-Ferrandis JF, Salazar-Sánchez N, et al. Long-term evaluation of quality of life and satisfaction between implant bar overdentures and conventional complete dentures: A 23 years retrospective study. *Clin Implant Dent Relat Res.* 2018;20:208–14.
3. Giannakopoulos NN, Corteville F, Kappel S, et al. Functional adaptation of the masticatory system to implant-supported mandibular overdentures. *Clin. Oral Impl. Res.* 2017;28:529-34.
4. Boven GC, Raghoobar GM, Vissink A, et al. Improving masticatory performance, bite force, nutritional state

- and patient's satisfaction with implant overdentures: a systematic review of the literature. *J Oral Rehabil.* 2015 42; 220-33
5. Laguna L, Sarkar A, Artigas G, et al. A quantitative assessment of the eating capability in the elderly individuals. *Physiol Behav.* 2015;147:274–81.
 6. Walls AWG, Steele JG, The relationship between oral health and nutrition in older people, *Mech. Ageing Dev.* 2004;125:853–7.
 7. Müller F, Duvernay E, Loup A, et al. Implant-supported Mandibular Overdentures in Very Old Adults: A Randomized Controlled Trial. *J Dent Res.* 2013; 92: 154S-60S.
 8. Moriya S, Notani K, Murata A, et al. Analysis of moment structures for assessing relationships among perceived chewing ability, dentition status, muscle strength, and balance in community-dwelling older adults. *Gerodontology* 2014; 31: 281–7.
 9. Lee S & Sabbah W. Association between number of teeth, use of dentures and musculoskeletal frailty among older adults. *Geriatr Gerontol Int.* 2018;18: 592–8.
 10. Naert I, Alsaadi G, van Steenberghe D, et al. A 10-year randomized clinical trial on the influence of splinted and unsplinted oral implants retaining mandibular overdentures: peri-implant outcome. *Int J Oral Maxillofac Implants* 2004; 19: 695–702.
 11. Emami E, Heydecke G, Rompre PH, et al. Impact of implant support for mandibular dentures on satisfaction, oral and general health-related quality of life: a meta-analysis of randomized-controlled trials. *Clin Oral Implants Res.* 2009;20:533–44.
 12. Mericske-Stern R, Probst D, Fahrlander F, et al. Within-Subject Comparison of Two Rigid Bar Designs Connecting Two Interforaminal Implants: Patients' Satisfaction and Prosthetic Results *Clin Implant Dent Relat Res.* 2009;11:228-37.
 13. Feine JS, Carlsson GE, Awad MA, et al. The McGill consensus statement on overdentures. Mandibular two-implant overdentures as first choice standard of care for edentulous patients. *Gerodontology* 2002; 19: 3–4.
 14. Alsabeeha NH, Payne AG, Swain MV. Attachment systems for mandibular two-implant overdentures: A review of in vitro investigations on retention and wear features. *Int J Prosthodont* 2009;22:429-40.
 15. Kobayashi M, Srinivasan M, Ammann P, et al: Effects of in vitro cyclic dislodging on retentive force and removal torque of three overdenture attachment systems. *Clin Oral Implants Res* 2014;25:426-34.
 16. ELSyad MA, Shaheen NH , Ashmawy TM. Long-term clinical and prosthetic outcomes of soft liner and clip attachments for bar/implant overdentures: a randomised controlled clinical trial. *J Oral Rehabil.* 2017 44; 472–80.
 17. Stoumpis C, Kohal RJ. To splint or not to splint oral implants in the implant-supported overdenture therapy? A systematic literature review. *J Oral Rehabil.* 2011;38:857-69.
 18. Lehmann KM, Kämmerer PW, Karbach J, et al Long-Term Effect of Overdenture Bar Design on Peri-implant Tissues. *Int J Oral Maxillofac Implants* 2013;28:1126–31.
 19. Saito M, Kanazawa M, Takahashi H, et al: Trend of change in retentive force for bar attachments with different materials. *J Prosthet Dent* 2014;112:1545-52.
 20. Sultana N, Bartlett DW, Suleiman M. Retention of implant-supported overdentures at different implant angulations: comparing locator and ball attachments. *Clin. Oral Impl. Res.* 2017;28:1406–10.
 21. Lachmann S, Kimmerle-Muller E, Gehring K, et al. A comparison of implant-supported, bar- or ball-retained mandibular overdentures: a retrospective clinical, microbiologic, and immunologic study of 10 edentulous patients attending a recall visit. *Int J Prosthodont.* 2007;20:37–42.
 22. Gibreel M, Fouad M, El-Waseef F, et al. Clips versus resilient liners used with bilateral posterior prefabricated bars for retaining four implant supported mandibular overdentures. *J Oral Implantol* 2017;43:273-81.
 23. Adrian ED, Krantz WA, Ivanhoe JR. The use of processed silicone to retain the implant-supported tissue-borne overdenture. *J Prosthet Dent* 1992; 67:219-22.
 24. Abdel-Khalek EA, Ibrahim AM. Effect of bar cross-section and female housing material on retention of mandibular implant bar overdentures: A comparative in vitro study. *J Indian Prosthodont Soc* 2017;17:340-7.
 25. Radi I & Elmahrouky N. Effect of two different soft liners and thicknesses mediating stress transfer for immediately loaded 2-implant supported mandibular overdentures: A finite element analysis study. *J Prosthet Dent* 2016; 116:356-61.

26. Koike T, Ueda T, Noda S, et al. Development of new attachment system with soft lining material for implant-retained complete denture. *Int J Prosthodont Restor Dent* 2013;3:21-4.
27. Ahuja S, Cagna DR. Classification and management of restorative space in edentulous implant overdenture patients. *J Prosthet Dent*. 2011; 105:332-7.
28. Trampisch U.S., Franke J., Jedamzik N, et al. Optimal JAMAR dynamometer handle position to assess maximal isometric hand grip strength in epidemiological studies, *J. Hand Surg.* 2012;37:2368–73.
29. Dodds RM, Syddall HE, Cooper R, et al. Global variation in grip strength: a systematic review and meta-analysis of normative data. *Age Ageing* 2016; 45: 209–16.
30. Geertman ME, Slagter AP, van't Hof MA, et al. Masticatory performance and chewing experience with implant-retained mandibular overdentures. *J Oral Rehabil.* 1999;26:7-13.