

## **NON-SURGICAL ERUPTION OF IMPACTED MAXILLARY CANINE: A RADIOLOGIC STUDY**

Mahasen Taha\*

### *ABSTRACT:*

*Spontaneous eruption of impacted maxillary canine after creation of a space in the arch, was studied on ten Saudian female patients.*

*The age range was 14 – 18 years. Panoramic X-rays were taken at the beginning of the treatment, then regularly every three months till the canine emerged into the oral cavity. The canine inclination angle (C I) and the overlap of the canine to the root of the upper lateral incisor were observed. There was a gradual straightening and eruption of the canine with significant decrease in the canine angle inclination from the first panoramic x-ray film to the last one. Also the overlap decreased from distal to the midline to no overlap in the last film.*

### **INTRODUCTION**

Impaction most commonly involves the lower third molar followed by the permanent upper canine<sup>(1)</sup>.

Approximately 1.5% to 2% of general population experiences impaction of the upper canine. Impactions are twice as common in females (1.17%) as in males (0.51%). Of all patients with maxillary canine impaction, it is estimated that 8 % have bilateral impactions<sup>(2-5)</sup>. The incidence of palatal impaction exceeds that of labial impaction by ratio of at least 2:1 or 3:1<sup>(6)</sup>.

The most common causes of canine impactions are the results of one or more factors. Long path of eruption, tooth size - arch length discrepancies, prolonged or early loss of the deciduous canine, abnormal position of the tooth bud, the presence of alveolar cleft, pathologic condition, ankylosis, and dilacerations of the root .

---

\*Lecturer of Orthodontics, Mansoura University, Egypt

More recently, the absence of the maxillary lateral incisor and variation in the timing of its root formation<sup>(7-9)</sup>. Also the impacted maxillary central incisor have been implicated as important etiologic factors<sup>(10)</sup>.

The early detection of eruptive disorder, as an anomalous inclination of the canine and / or overlapping of the canine and the root of the lateral incisor after the lateral incisor development is completed.

A number of authors favor preventive measures as selective extraction of the deciduous canines as early as 9 or 10 years of age in a Class I uncrowded cases<sup>(11,12,13)</sup>.

There are various treatment options available for the treatment of the patient with impacted canine . No treatment if the patient does not desire it. Removal of impacted canine and substitution by the first premolars in cases requiring extraction of dental units, when successful treatment would be doubtful<sup>(14)</sup>. Autotransplantation of the canine<sup>(15,16)</sup>, proesthetic replacement<sup>17</sup>, or surgical exposure and orthodontic treatment to bring it into the line of occlusion .

There are two methods for surgical exposing the impacted canine. Surgical exposure allowing natural eruption . Often, 6 months to 1 year may elapse before eruption, then apply orthodontic force to align it<sup>(18,19)</sup> . Surgical exposure with placement of an auxiliary attachment and orthodontic forces are applied to move the impacted tooth<sup>(20)</sup> .

The surgical exposure is complex and affects the periodontal health and alveolar bone support of the exposed canine<sup>(21,22)</sup> .

#### **The aim of the study:**

The aim of this study was to analyze the eruption of the impacted upper canine, after creation of space in the arch . In terms of :

- 1) Its inclination .
  - 2) Its relation to the lateral incisors root.
- On the basis of panoramic radiographic records.

#### **Material and Methods:**

The sample consisted of ten female patients with impacted upper canine. The age was ranged from 14 to 18 years. They were selected from Al Jazeera Dental Clinic, Riyadh, K.S.A. All patients had impacted upper canines with no sufficient space for the canine. Where, the first premolar was in contact with the lateral incisor, deciduous canine was retained or there was a moderate space distributed in the arch .

**Table I :** Showed the distribution of the patients :

| N  | Impaction   | class                                  | space   | Overlap of the canine to the lateral incisor |
|----|---|--|---|--|
| 10 | - 5 had palatal impaction<br>- 5 had buccal impaction | 4 class I<br>1 class II<br>5 class III | - 4 had no spaces.<br>- 3 had retained deciduous canine.<br>- 3 had moderate space distributed in the arch. | - 6 had overlap<br>- 4 had no overlap        |

**The following records were taken for each patient :**

- 1) Upper and lower orthodontic casts to make space analysis.
- 2) Panoramic radiographs.

They were taken for each patient before the treatment and later on, every three months till the canine had emerged into the oral cavity .

All radiographs were obtained by the same operator and apparatus (Rotograph plus). The radiographic measurements were performed by the same individual.

**The following variables were studied :**

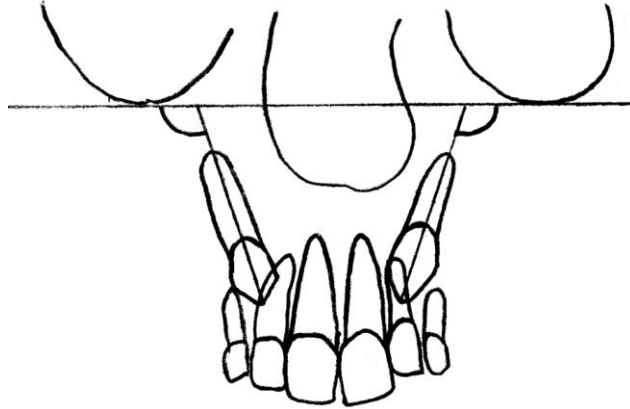
- 1) Canine inclination (CI):

Following the method described for the first maxillary molars<sup>(23)</sup> and eruption of the upper canine<sup>(11)</sup> . We measured the external angle formed by the major axis of the canine and the straight line through both suborbital points fig (1)

- 2) Relation of the canine to the lateral incisor. Two possibilities were considered according to whether the crown was distal or mesial to the distal border of the lateral incisor. When mesial, the two teeth were overlapping .

All the patients were treated orthodontically.

- 1) Creation of sufficient space in the arch for the impacted canine. This space was created by extraction of the first premolar, extraction of the retained deciduous canine or collecting the space in all arch in the canine region .
- 2) Maintenance of the space by either continuous tying of the teeth mesial and distal to the canine or placement of a closed – coil spring on the arch wire .



**Fig (1):** Canine inclination (Ci) is measured by the external angle formed by the major axis of the canine and a straight line through both suborbital points.

**Statistics:**

Mean and Standard Deviation (SD) of canine inclination angle were calculated for all patients every three months. Students t test was performed to detect any statistical significant changes during the period of treatment .

**RESULTS**

Table (II): Shows the changes in the canine inclination (CI) in the ten patients. It revealed gradual decrease in the canine inclination in all patients. In two patients the canine had erupted after 6 months. In one patient the canine erupted after 9 months. In five patients it erupted after 12 months. In one patient it erupted after 15 months. In one patient it erupted after 17 months.

Mean values, standard deviations of canine inclination and the results of t-test are presented in table (III). It showed a significant change in the mean values of canine inclination angle (CI) from the first panoramic – x ray film to the last film. In six patients who, had overlap of the canine to the root of the lateral incisor. There was a gradual uprighting of the canine and decrease in the overlap from up to the midline of the root of the lateral incisor till no overlap.

**Table (II) :** Shows the changes in the canine inclination (CI) in the ten patients .

| N  | At the beging of treatment | After 3 months | After 6 months | After 9 months | After 12 months | After 15 months | After 17 months |
|----|----------------------------|----------------|----------------|----------------|-----------------|-----------------|-----------------|
| 1  | 123                        | 117            | 108            | 106            |                 | 93              |                 |
| 2  | 114                        | 107            | 101            | 94             | 94              |                 |                 |
| 3  | 97                         | 94             | 91             |                |                 |                 |                 |
| 4  | 104                        | 97             | 93             |                |                 |                 |                 |
| 5  | 102                        | 97             | 94             | 91             |                 |                 |                 |
| 6  | 115                        | 107            | 102            | 97             | 94              |                 |                 |
| 7  | 120                        | 116            | 108            | 102            | 97              | 93              | 91              |
| 8  | 111                        | 106            | 101            | 97             | 92              |                 |                 |
| 9  | 110                        | 103            | 99             | 97             | 92              |                 |                 |
| 10 | 104                        | 100            | 96             | 93             | 91              |                 |                 |

**Table (III) :** Shows mean values of the canine inclination (CI) angle. From the first visit to emergence in oral cavity.

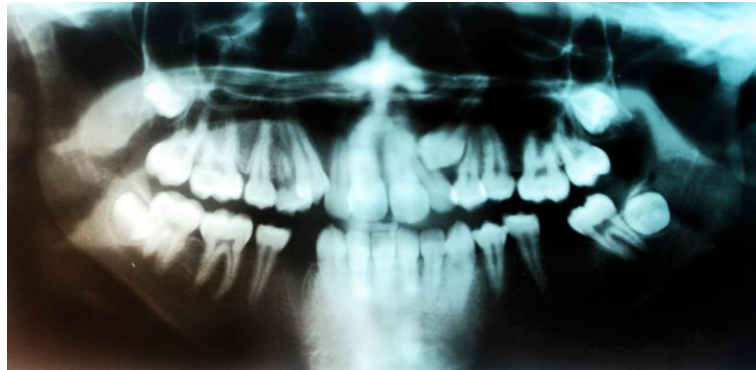
| Time         | Mean   | S.D    | T test  | P value  |
|--------------|--------|--------|---|--|
| Pretreatment | 110    | ± 8.27 | 10.755<br>7.965<br>6.110<br>4.926<br>2.033<br>2.572 | 0.000*<br>0.000*<br>0.000*<br>0.002*<br>0.036*<br>0.022* |
| 3 months     | 104.4  | ± 7.80 |   |  |
| 6 months     | 101.12 | ± 5.88 |   |  |
| 9 months     | 97.13  | ± 4.88 |   |  |
| 12 months    | 94.25  | ± 3.02 |   |  |
| 15 months    | 93     | —      |   |  |
| 17 months    | 91     | —      |   |  |

\*  $p \leq 0.05$  significant

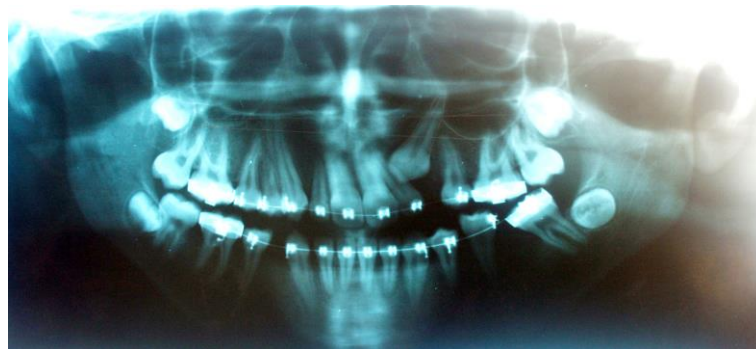Case presentation.

**Figures (2-3):** I illustrate the panoramic X-ray films of two Cases.

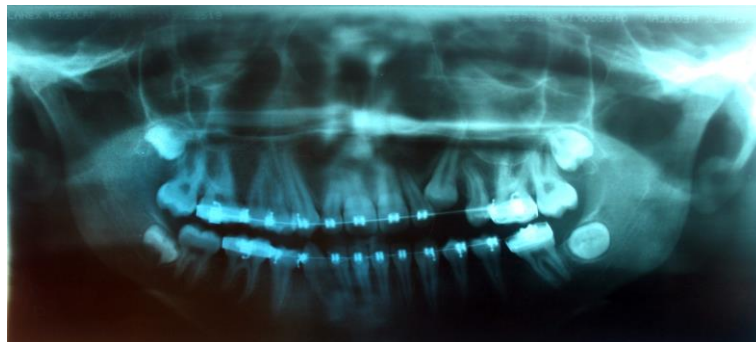
**Case (1)**



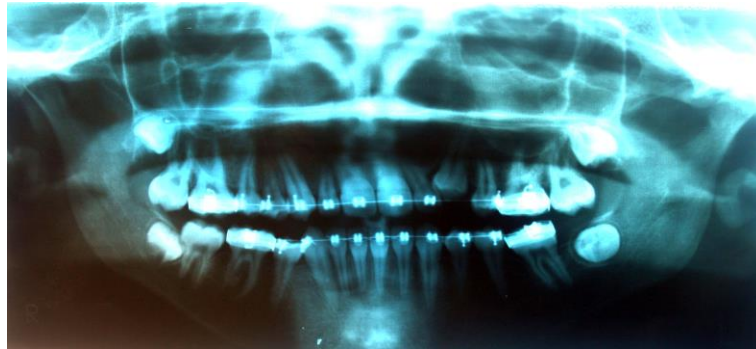
**Fig.: (2-a) :** Pre treatment Panoramic X - ray film



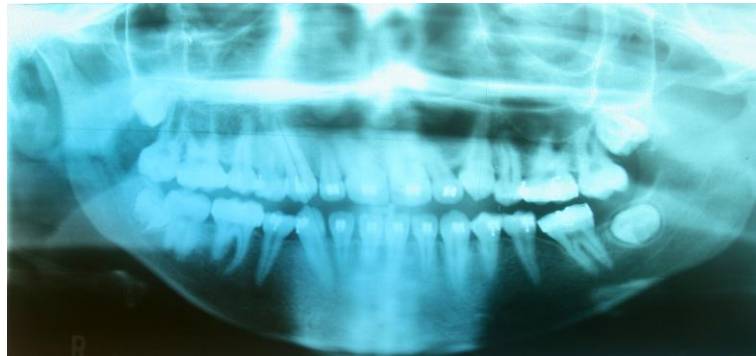**Fig.: (2-b):** After three months



**Fig.: (2-C):** After six months

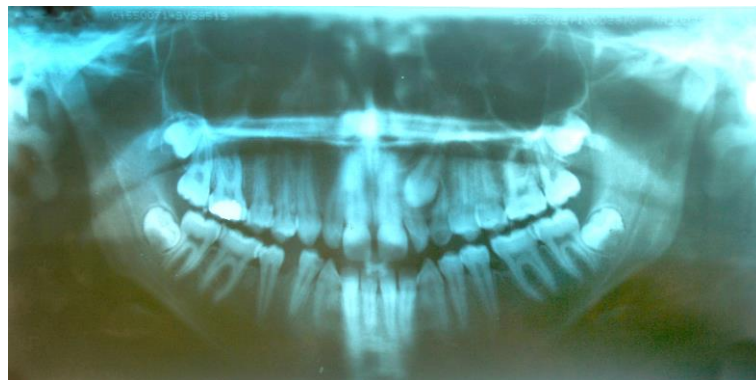

**Fig.: (2-D):** After nine months

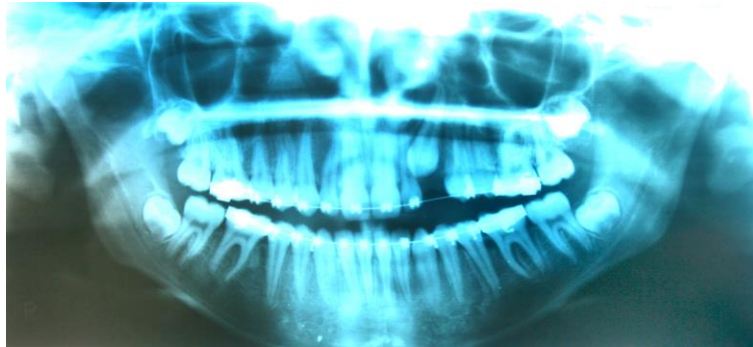

**Fig.: (2-E):** After fifteen months

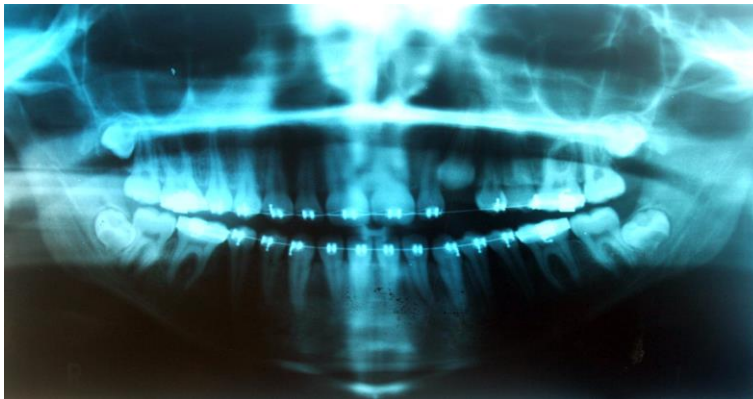
**Case (2)**



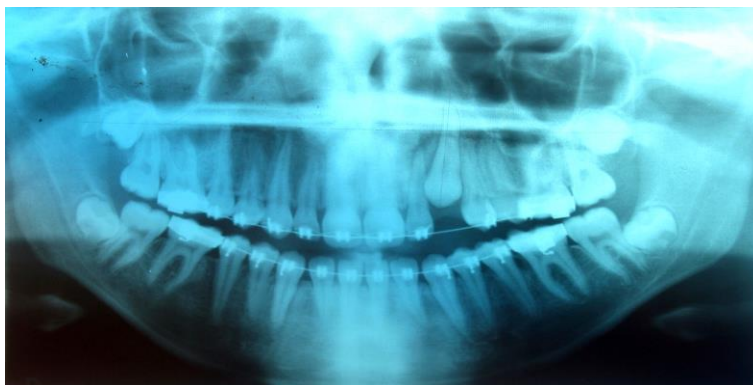
**Fig.: (3-A):** Pre treatment Panoramic X - ray film



**Fig.: (3-B):** After three months

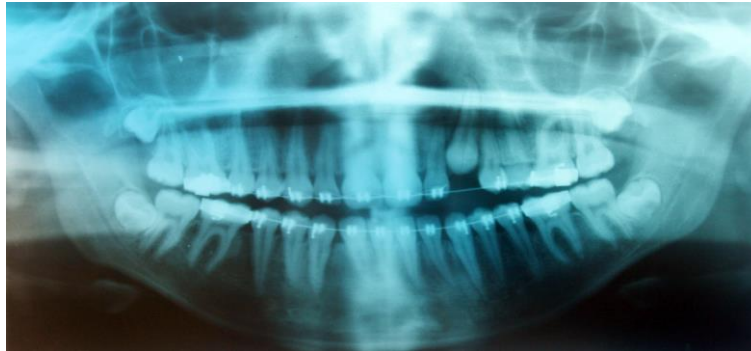


**Fig.: (3-C):** After six months



**Fig.: (3-D):** After nine months





**Fig.: (3-E):** After twelve months

## **DISCUSSION**

The results of this study showed that, the impacted upper canine spontaneously moved downward and distally away from the roots of the upper laterals . It gradually straightened itself and erupted vertically into the correct position in the created space in the arch . Where, there was a significant decrease in the mean angle of canine inclination .

These results, were not in agreement with other studies. The studies suggested removal of primary canine as a preventive measure to avoid impaction and allow spontaneous eruption of permanent canine . They recommended this approach only before age 11 years<sup>(11,12,13,24)</sup> . The studies treated the impacted canine by surgical exposure allowing natural eruption without the application of traction force . This approach is applied only if the impacted canine has a favorable vertical position and does not need to be uprighted. Also they recommended it in younger patients before root completion. Where as in older patients traction is almost always indicated<sup>(6)</sup>.

There was no difference in the timing of eruption between the patients of palatal impaction and the patients of buccal impaction. The average time of eruption was ranged from 6 to 17 months . In five patients presented palatal impaction with the presence of palatal bulge before the treatment. The canine gradually moved in the bone and corrected its position till erupted into the arch.

This finding was in contrast to other studies, which reported that, palatally impacted canines very rarely erupts spontaneously without surgical intervention.

This is due to the thickness of the palatal cortical bone, as well as the dense thick and resistant palatal mucosa<sup>(7)</sup>.

Two cases out of the ten patients showed faster eruption, where the canines erupted after 6 months. This might be due to the incomplete formation of the canine roots. Also two cases showed a slower eruption, where the canines erupted after 15 months in one patient, and after 17 months in the other patient. These two patients were having the most severe impaction in the all patients. One patient had palatal impaction and other one had buccal impaction. This finding was in agreement with other study which analyzed the factors affecting the non surgical eruption of palatally impacted canines. It found that, the severity of impaction was the most important factor affecting the duration of eruption<sup>(25)</sup>.

In the six patients presented with overlap of the upper canine to the root of the lateral incisors. The overlap gradually decreased from mesial to the midline of the lateral incisor to no overlap. This result was in contrary to the studies concerned to deciduous canine removal to allow eruption of the permanent canine. It will normalize the position of ectopically erupting permanent canines in 91% of the cases if the canine crown is distal to the midline of the lateral incisor. On the other hand the success rate is 64% if the canine crown is mesial to the midline of the lateral incisor<sup>(13)</sup>.

The main advantages of this method are, the natural eruption of the canine without surgical intervention, where most patients are afraid of surgery. There is no soft tissue recession or radicular bone loss. The main disadvantages are, the slow canine eruption, the increased treatment time, and the inability to influence the path of eruption.

## **CONCLUSIONS**

On the Basis of the result obtained from the present study, the following conclusion could be achieved.

- 1) This method of canine impaction management is successful before the age of 18 years.
- 2) The younger the patient, the faster the eruption of the canine.
- 3) The less severe the impaction, the faster the eruption.
- 4) The canine can erupt without surgical intervention after complete formation of the root.

## REFERENCES

1. **Moyers, R.E.:** Hand book of orthodontics, ed. 2, Chicago. Year book Medical publishers, Inc. 1963.
2. **Dachi, S.F., and Howell, F.V.:** A survey of 3.874 routine full mouth radiographs . Oral Surg Oral Med Oral path; 14: 1165-9, 1961.
3. **Thi Lander, B., and Myrberg, N.:** The prevalence of malocclusion in Swedish school children . Scand. J. Dent Res; 81: 12-20, 1973.
4. **Grover, P., and Loton, L.:** The incidence of unerupted permanent teeth and related clinical cases . Oral Surg oral Med Oral Path Oral Radiol Endod; 59 : 420 – 5, 1985 .
5. **Ericson, S., and Kurol, J.:** Radiographic assessment of maxillary canine eruption in children with clinical signs of eruption disturbances. Eur. J. Orthod; 8: 133 – 40, 1986.
6. **Fournier, A., Turcotte J., and Bernad, C.:** Orthodontic considerations in the treatment of maxillary impacted canines. Am. J. orthod., 81:236-9, 1982.
7. **Jacoby, H.:** The etiology of maxillary canine impaction Am. J. orthod., 84: 125-32, 1983 .
8. **Miller, B.H.:** Influence of congenitally missing teeth on the eruption of upper canine . Trans Br Soc Study Orthod., 50 : 17-24, 1963/64 .
9. **Beckel, A., Smith P., and Baher R.:** The incidence of anomalous lateral incisors in relation to palatally displaced cuspids . Angle Orthod ., 51 : 24 – 9, 1981 .
10. **Günduz, K., M., and Inal, S.:** Maxillary canine impactions related to impacted central incisors; Two case reports : J. Contemp. Dent. Pract., 8 (6): 72 - 82, 2007 .
11. **Fernandes, E., Bravo, L.A., and Canteras, M.:** Eruption of the permanent upper canine: A radiologic study . Am. J. Orthod. Dentofac. Orthop., 113: 414 – 20, 1998.
12. **Ericson, S., and Kurol, J. :** Incisor resorption caused by maxillary cuspids: a radiographic study . Angle Orthod., 57 : 332-46, 1987 .
13. **Ericson, S., and Kurol, J.:** Early treatment of palatally erupting maxillary canines by extraction of primary canines. Eur . J. Orthod., 10: 283 – 95, 1988.
14. **Altman, J.A., Arnold H., and Specter, P.:** Substituting maxillary first premolars for maxillary impacted canines in cases requiring the extraction of dental unites as part of orthodontic correction. Am. J. Orthod., 75 : 618. 1979 .

15. **Shaw, B., Schneider, S.S., and Zayer, J.:** Surgical management of ankylosed impacted maxillary canines . J. Am. Dent. Assoc., 102 : 497-500, 1981 .
16. **Sayne, S., Lennartsson B., and Thilander, B.:** Transalveolar transplantation of maxillary canines . Am. J. Orthod. Dentofac. Orthop., 90 : 149 – 57, 1986.
17. **Bishara, S.E.: Impacted Maxillary canine:** A review. Am. J. Orthod. Dentofac. Orthop., 101 : 159-71, 1992 .
18. **Clark, D.:** The management of impacted canines: Free physiologic eruption. J. Am Dent Assoc., 82 : 836-40, 1971 .
19. **Lewis, P.D.:** Preorthodontic surgery in the treatment of impacted canines. Am. J. Orthod., 60 : 383 – 97, 1971 .
20. **Mc Donald, F., and yap, W.L.:** The surgical exposure and application of direct traction of unerupted teeth . Am. J. Orthod., 89 : 331 – 40, 1982.
21. **Kohavi, D., Becker, A., and Zilberman, Y.:** Surgical exposure, orthodontic movement, and final tooth position as factors in periodontal breakdown of treated palatally impacted canines. Am. J. Orthod., 85: 72 – 7, 1984.
22. **Shapira, Y., and Kufinec, M.M.:** Treatment of impacted Cuspids the hazard lasso . Angle Orthod., 51 : 203 - 7, 1981 .
23. **Bjerklin, K., and Kurol, J.:** Ectopic eruption of the maxillary first permanent molar: Etiologic factors . Am . J. Orthod., 84: 147-55, 1983.
24. **Jacobs, S.G.:** The impacted maxillary canine. Further observations on aetiology, radiographic localization prevention / interception of impaction, and when to suspect impaction . Aust. Dent. J. 41 (5): 310 – 16, 1996.
25. **Richard, J., and Olive:** Factors influencing the non - surgical eruption of palatally impacted canines . Aust. Orthod. J., 21 : 95-101, 2005 .