

## Unusual Cause of Transient Unilateral Fixed Dilated Pupil in Infant with Bronchiolitis: A Case Report

Abdullah Al-Shamrani<sup>1</sup>, Reham M. Babiker<sup>2</sup>, Waleed A. Okash<sup>2</sup>, Naif I. Al-Oudah<sup>2</sup>, Rola A. Sleiman<sup>2</sup>

<sup>1</sup>Prince Sultan Medical Military City (PSMMC), <sup>2</sup> Dr. Sulaiman Al-Habib Medical City-Rayyan Hospital

Corresponding author: Abdullah Al-Shamrani, Email: [dr.alshamrani99@gmail.com](mailto:dr.alshamrani99@gmail.com),

Orcid.org/0000-0001-7157-1706, Mobile no.: 00966553367555

### ABSTRACT

**Background:** Unilateral anisocoria has a variety of causes, some of which could be life-threatening. Mydriasis can represent a serious neurological finding in intensive care units. Bronchiolitis is the most common cause of intensive care in the infancy period. Ipratropium bromide is anticholinergic and commonly used in the intensive care unit (ICU). Anisocoria is due to the overactivation of the sympathetic nervous system or hypoactivity of the parasympathetic nervous system.

**Objectives:** Assessment of cases of anisocoria in infants with bronchiolitis under ipratropium bromide therapy.

**Patient and methods:** A case report study of a 9-month-old infant with a fixed dilated pupil. He was admitted into the ICU and given ipratropium bromide.

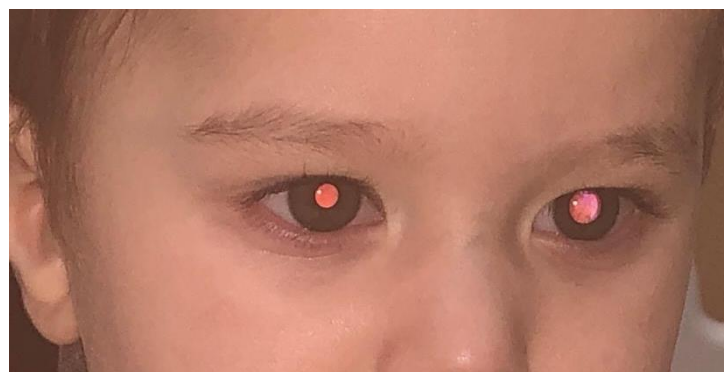**Results:** Ultimately, the patient's symptoms of pupillary dilation resolved over 24 hours with the discontinuation of ipratropium bromide, with a complete recovery. The case presented here is typical of anticholinergic side effects, and the evidence of this benefit is even more limited, which might lead to frustrating observations among patients and health care providers. **Conclusion:** Anisocoria is not an uncommon finding in patients receiving ipratropium bromide. Paediatricians should follow the Saudi Bronchiolitis Guideline recently published in 2018, in which no indication of ipratropium bromide in bronchiolitis was clearly stated.

**Keywords:** Anisocoria, pupil, bronchiolitis, ipratropium bromide, mydriasis.

### CASE REPORT

**Patient information:** A 9-month-old boy who presented to the Emergency Department with cough, fever and dyspnoea. He was admitted to the PICU for respiratory distress as a case of acute bronchiolitis. He was stabilized and then transferred to the paediatric ward on nebulized ipratropium bromide 0.5 ml delivered via a face mask every 4 hours.

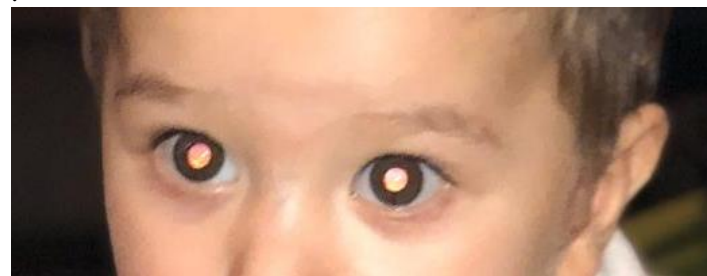
**Physical examination:** demonstrated that a child with minimal respiratory distress had vital signs on arrival to the General Paediatric Ward. The respiratory rate was 40/minute and the heart rate was 120/m with a saturation level of 94% in room air. He was afebrile with scattered wheezing in the chest. The rest of his general examination confirmed a fixed dilated left pupil that was nonreactive to light (Figure 1). The rest of the cranial nerves were normal, and the child was very alert with normal developmental milestones.



**Figure (1):** Fixed dilated left pupil and absence of light reflex induced by ipratropium bromide.

**Consent** was obtained from parents for the publication of the child's details and to publish figures 1 and 2 in this report.

**Diagnostic assessment:** An ophthalmologist consulted a fixed dilated pupil and confirmed that anisocoria faded slowly after nebulized ipratropium bromide was discontinued. Mydriasis completely resolved within 24 hours of its onset (Figure 2).



**Figure (2):** Recovery of mydriasis in the left pupil after 24 hours of stopping the nebulized ipratropium bromide.

### DISCUSSION

Bronchiolitis is very common and is the leading cause of hospital admission in the infancy period<sup>(1, 2)</sup>. Currently, there are no effective therapies for the management but only supportive. This condition represents an area of controversy despite the current Saudi National guidelines for its management<sup>(3)</sup>. A wide range of medications are commonly used in the management of acute bronchiolitis, but evidence of their effectiveness is limited. Among such medications is ipratropium bromide, which is often used as an adjuvant to bronchodilators to relieve bronchospasm and to minimize the associated nasal secretion<sup>(4)</sup>. Ipratropium bromide is an

anticholinergic agent (muscarinic antagonist) that is used as a bronchodilator due to its effect as a smooth muscle relaxant. Ipratropium bromide nebulizer is commonly used in intensive care with asthma exacerbation or bronchiolitis and is often a safe medication. The common side effects are dry mouth, tachycardia, altered taste and urinary retention, but it may cause unusual events, such as unilateral dilation of the pupil if the nebulizer mask is loose or broken, poorly fitting spacers, higher doses, or spillage of the medication direct into the eye, and leading to a dilated pupil (mydriasis) <sup>(5-10)</sup>.

A meticulous specialist observed the dilated pupil on the left side, as this is a very alarming sign for a patient who just arrived from intensive care, as it could be a sign of uncal herniation. A detailed neurological exam revealed that the alert child had a Glasgow Coma Scale score of 15 and no evidence of ptosis or facial weakness. Furthermore, all other cranial nerves were intact. The mydriasis was not related to any mass effect or uncal herniation. An ophthalmologist was consulted who confirmed ipsilateral anisocoria. Nebulized ipratropium bromide was discontinued, and the patient was kept under regular close observation. Within 12 hours, the patient showed marked improvement, and the condition resolved completely in 24 hours <sup>(5, 8)</sup>.

## CONCLUSION

Anisocoria is not an uncommon finding in patients receiving ipratropium bromide. It should be carefully monitored in patients receiving both inhaled and nebulized ipratropium bromide. Bronchiolitis is often overtreated and paediatricians should follow the Saudi bronchiolitis guideline recently published in 2018, in which no indication of ipratropium bromide in bronchiolitis was clearly stated.

**Financial disclosure:** The authors declared that this study did not receive any financial support.

**Conflict of interest:** No conflict of interests was declared by the authors.

**Acknowledgements:** We would like to thank American Journal Experts for editing the manuscript.

## Abbreviations:

- PICU: Paediatric intensive care unit
- PSMMMC: Prince Sultan Medical Military City.

## REFERENCES

1. **Bronchiolitis Guideline Team, Cincinnati Children's Hospital Medical Center (2005):** Evidence based clinical practice guideline for medical management of bronchiolitis in infants 1 year of age or less presenting with a first time episode. Available from: <http://www.cincinnatichildrens.org/svc/alpha/h/health-policy/ev-based/bronchiolitis.htm>.
2. **Nicolai A, Ferrara M, Schiavariello C, Gentile F, Grande ME, Alessandroni C et al. (2013):** Viral bronchiolitis in children: A common condition with few therapeutic options. *Early Hum Dev.*, 89 (3): S7-11
3. **Alharbi AS, Alqwaiee M, Al-Hindi MY et al. (2018):** Bronchiolitis in children, The Saudi initiative of bronchiolitis diagnosis, management and prevention (SIBRO), *Ann Thorac Med.*, 18 (13): 127-43.
4. **Karadag B, Ceran O, Guven G, Dursun E et al. (2008):** Efficacy of salbutamol and ipratropium bromide in the management of acute bronchiolitis--a clinical trial. *Respiration*, 76 (3): 283-7.
5. **Neslihan K, Seda C, GÖzde G et al. (2018):** Anisocoria in a patient with a cute bronchiolitis. *J Pediatr Inf .*, 12 (1): e 32-e34.
6. **Chaudhry P, Friedman DI, Yu W (2014):** Unilateral pupillary mydriasis from nebulized ipratropium bromide; a false sign of brain herniation in the intensive care unit. *Indian J Crit Care Med.*, 18: 176-7.
7. **Kedar S, Biousse V, Newman NJ (2017):** Approach to the patient with anisocoria *Up to date*. Available from: <https://www.uptodate.com/contents/approach-to-the-patient-with-anisocoria>.
8. **Brodie T, Adalat S (2006):** Unilateral fixed dilated pupil in a well-child. *Arch Dis Child.*, 91(12):961
9. **Ryan CA (2007):** Ipratropium bromide induced unilateral mydriasis. *Ir Med J.*, 90: 76
10. **Krovvidi, H P, Thillaivasan A (2008):** A benign cause for a unilateral dilated pupil in a critical care patient. *European Journal of Anaesthesiology*, 25(8): 692-693.