

## **MARGINAL BONE HEIGHT CHANGES AROUND MAXILLARY AND MANDIBULAR IMPLANTS SUPPORTING ALL ON FOUR FIXED DETACHABLE PROSTHESIS. ONE-YEAR PROSPECTIVE STUDY**

Ahmad Fathalla Shawky, \* Mohamad Hossam El- Din Helmy \*\*  
and Hebatalla Mahmoud El Afandy\*\*\*

### **ABSTRACT**

**Purpose of the study:** The aim of the present study was to investigate the marginal bone height changes around maxillary and mandibular implants supporting all on four fixed detachable prosthesis after one year follow up

**Materials and methods:** six completely edentulous patients (4 males and 2 females) received new conventional maxillary and mandibular dentures and were asked to wear them for 3 months to enhance adaptation. Four implants were inserted in the maxillary (between the nasal sinuses) and mandibular (between the mental foramina) arch of each patient according to the All On four protocol. Implants were immediately loaded with provisional dentures after connection of multiunit abutments, and after 3 months of osseointegration temporary dentures were replaced by fixed ceramo-metal prosthesis. Vertical marginal bone loss (VBL) was evaluated at the time of fixed hybrid prosthesis insertion, 6 and 12 months later using standardized peri-apical radiographs.

**Results:** Maxillary anterior implants recorded significant higher VBL ( $P \leq 0.005$ ) than mandibular implants after 6 months and 12 months of prosthesis insertion. Also, the maxillary anterior implants showed significant VBL ( $P \leq 0.005$ ) than the posterior implants. For the posterior implants, no significant difference in VBL was observed between the maxillary and mandibular implants. For the mandibular implants, no significant difference in VBL between the anterior and posterior implants was observed.

**Conclusion:** Within the limitation of this short-term study, taking the small patient cohort into account, it could be concluded that maxillary anterior implants supporting all on four fixed hybrid prosthesis are at increased risk for marginal bone loss compared to maxillary posterior implants or mandibular implants.

**KEY WORDS:** marginal bone, maxillary, mandibular, All on four

\* Associate Professor, Department of Removable Prosthodontics ,Faculty of Dentistry, Beni-suef University, Beni-suef, Egypt.

\*\* Lecturer, Department of Removable Prosthodontics, Faculty of Dentistry, Assiut University, Assiut, Egypt.

\*\*\* Lecturer at Prosthodontic Department Faculty of Dentistry , Future University

## INTRODUCTION

Implant supported prosthesis is considered a viable option for edentulous patients<sup>1</sup>. For those patients several types of implant supported prosthesis are available including; fixed prosthesis, implant overdentures, and hybrid fixed (detachable) cantilevered dentures<sup>2</sup>.

The “All on four” implant concept for rehabilitation of edentulous patient has gained popularity in the last decade<sup>3-5</sup>. The concept includes installing 2 implants in the canine or lateral incisor positions parallel to each other’s and vertically in the mandible or slightly inclined labially in the maxilla. The posterior implants are inclined distally to make an angle of 30-45° from the vertical planes. In the mandible, the posterior implants are placed just anterior to the mental foramen and in maxilla, the posterior implants are placed just anterior to the maxillary sinuses. The concept has several merits such as: 1) reduction of the necessity to used bone grafting augmentation or nerve repositioning in the mandible or use sinus lift procedure in the maxilla, thus it is suitable for medically compromised patients with reduced morbidity, 2) immediate loading of the implants, immediate restoration of mastication and esthetics by the provisional acrylic dentures, 3) cost effectiveness due to reduction of the number of used implants<sup>5, 6</sup>, 4) Placement of longer posterior implants due to tilting of the implants which increase surface area and bone to implant contact, 5) wide implant support which allow placement of short distal cantilevers, and 6) reduction of the duration of the treatment (time saving procedure)<sup>7, 8</sup>.

Maló et al<sup>6</sup> found a high cumulative implant and prostheses survival rates (96.7% and 98.2%) that can be compared to the conventional two-stage protocols<sup>9</sup> and conclude that the “All-on-Four” immediate-function concept is a viable concept.

Despite these several advantages, the concept has some drawbacks. The perfect parallelism and

the same vertical height of the implants are difficult to perform. Moreover, the total passive fit between the superstructure and the implants is difficult to be achieved which may cause harmful tensile, compressive, and bending forces that may result in increased marginal bone loss or even affection of osseointegration<sup>10-12</sup>. There is evidence from in vitro reports that there are stresses found around the tilted distal implants which depend on the angulation and that this may affect crestal bone remodeling<sup>13</sup>. However, in the majority of All-on-4 studies, peri-implant bone resorption is not sufficiently reported or not reported at all since these studies are concerned with evaluation of implant and/or prosthesis survival rate<sup>14</sup>.

Accordingly, the aim of the present study was to investigate marginal bone height changes around maxillary and mandibular implants supporting All on four fixed prosthesis after one year follow up. The null hypothesis was that there will be no significant difference in marginal bone loss between maxillary and mandibular implants.

## MATERIALS AND METHODS

### Patient cohort

Six patients (4 males and 2 females- average age of 58 year) with completely edentulous maxilla and mandible who suffered from insufficient retention and stability of their maxillary and mandibular conventional dentures and desire a fixed detachable prosthesis were selected from the outpatient clinic of the Prosthodontic Department. The inclusion criteria include: 1) Sufficient bone volume and quality in the interforaminal area of the mandible and between the maxillary sinuses to allow installation of 4 implants of at least 11 mm in length and 3.7mm in width, 2) last extraction performed at least one year ago, 3) normal maxillomandibular relationship (class I angle classification), and 4) adequate inter-ridge space to allow fabrication of maxillary and mandibular prosthesis. The participants who had

one of the following criteria were excluded: 1) systemic disease that preclude surgical procedure for implant placement as liver, heart and renal diseases, 2) chronic use of steroids, 3) metabolic bone diseases that affect osseointegration such as diabetes, osteoporosis and hyperparathyroidism and 4) radiation therapy to head and neck region. All patients signed approval consent to be included in the study with regular attendance of periodic recalls. The study was conducted according the guidelines of Helsinki Declaration for ethics in clinical trials and approved by the Faculty ethical Committee.

For all participants, new maxillary and mandibular conventional dentures were made and worn for 2 months to enhance muscle adaptation before implant insertion. The occlusal concept used in denture fabrication was bilateral balanced occlusion. After 2 months of adaptation, gutta percha markers were added to the polished surfaces of the dentures (at least 6 markers buccally and lingually/palatally). Each participant underwent a cone beam computerized tomography scan\* while the patient wearing the dentures with the radiopaque gutta percha markers. Another CBCT scan of the denture alone was made. The dual scan protocol was used. The data were overlapped using the accompanying software\*\* and the reformatted images were used to produce 3D image of each jaw and the images were stored on a compact disc. The implants were virtually placed according to the “All on four” implant protocol<sup>3,4</sup>. The anterior implants were placed in the canine/lateral incisor area of each jaw and posterior implants were distally tilted 30° from the vertical plane (anterior to the mental foramen in the mandible and anterior to maxillary sinuses in the maxilla) to emerge in the region of mesial cusp of the first molar artificial teeth. This arrangement allows shorten cantilever length,

and increases anteroposterior spread<sup>15</sup>. A mucosal supported stereolithographic surgical guide (fig1) was constructed using rapid prototyping technology\*\*\*.

The posterior 2 implants were installed firstly. Four implants\*\*\*\* were placed in the interforminal region of the mandible and between the maxillary sinuses using the flapless surgical technique. For accessibility, mandibular implants were inserted first, then maxillary implants. The stereolithographic template was fixed to the ridges using fixation pins. The drilling was made using the In2Guide surgical sleeves and drills (fig2).

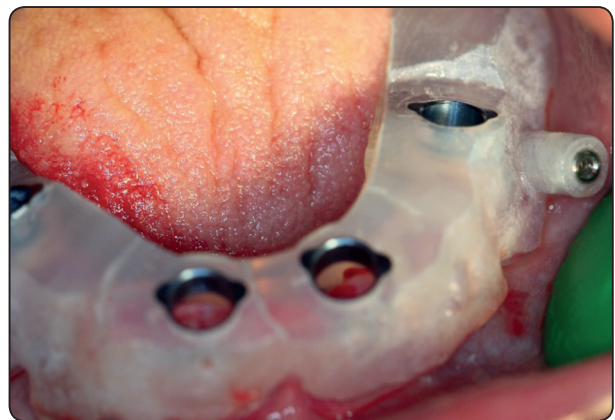


Fig (1) The stereolithographic template



Fig (2) The In2Guide universal surgical kit

\* (CBCT, i- CAT Vision®, Imaging Sciences International, Hatfield, PA, USA)

\*\* OnDemand V3

\*\*\* In2Guide universal surgical kit

\*\*\*\* TioLogic, Dentaurum, Germany

The implants were placed with at least 35 Ncm torque to allow immediate implant loading. Straight multiunit abutments were used for mandibular anterior implants, 17° multiunit abutments were used for anterior maxillary implants and 30° multiunit abutments were used for posterior maxillary and mandibular implants (fig 3).

Implants were immediately loaded by existing maxillary and mandibular dentures after hollowing the dentures opposite to the abutments. The flanges of the dentures, the palate of maxillary denture and second molar teeth were removed. Temporary titanium cylinders were attached to the multiunit abutments and picked up to the modified dentures using auto polymerized acrylic resin. The occlusal contact between the maxillary and mandibular first molar teeth were eliminated. Postoperative medications include antibiotics and anti-inflammatory medications were prescribed 5-10 days post surgically. Participants were informed to eat soft diet, instructed for oral hygiene procedures and informed to attend regular follow-up visits to perform denture adjustments.

Five months after integration period osseointegration, the abutment level open tray impression transfers were connected to the

abutments and open tray impression was completed using Light rubber base impression material\*. The analogues were screwed to the copings then the impression was poured. Plastic caps were screwed to the abutment analogues on the cast. Each patient received maxillary and mandibular screw-retained metal–ceramic fixed detachable prostheses (fig 4). The bridge was virtually planned using the accompanied software. The final prosthesis had 12 teeth. Patients were scheduled for follow-up every 3 months up to 1 year for necessary adjustments.

### Estimation of marginal bone level changes

The evaluation of changes in the marginal bone was made using a periapical radiograph taken regularly in the follow up visits at time of denture delivery, 6 months and 12 months after denture delivery. Radiographic evaluation was made using the digital imaging system\*\*. Rinn® XCP film holder\*\*\* was used for film fixation at a specific constant distance from the implant during the subsequent film exposures for standardization purposes. This was made to avoid the effect of changing the distance from the implant or the source of radiation on accuracy of image dimensions. The acquired images were stored on CD. The Digora software that was also supplied by the imaging

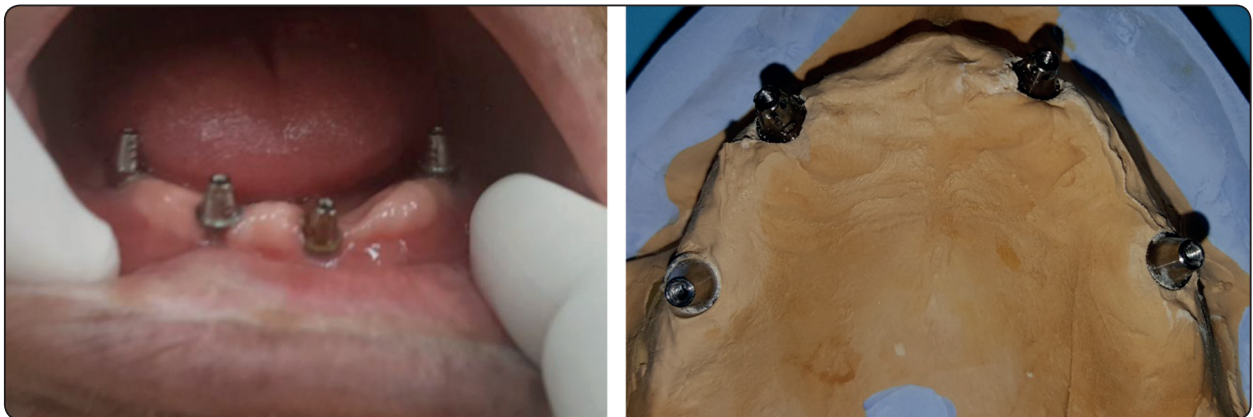


Fig. (3) Mandibular and maxillary multiunit abutments in place

\* Speedex, Colten/Whaledent Inc, Cuyahoga Falls, Ohio

\*\* Digora Optime, Orion Corp./Soredex

\*\*\* Dentsply, Elgin, IL, USA

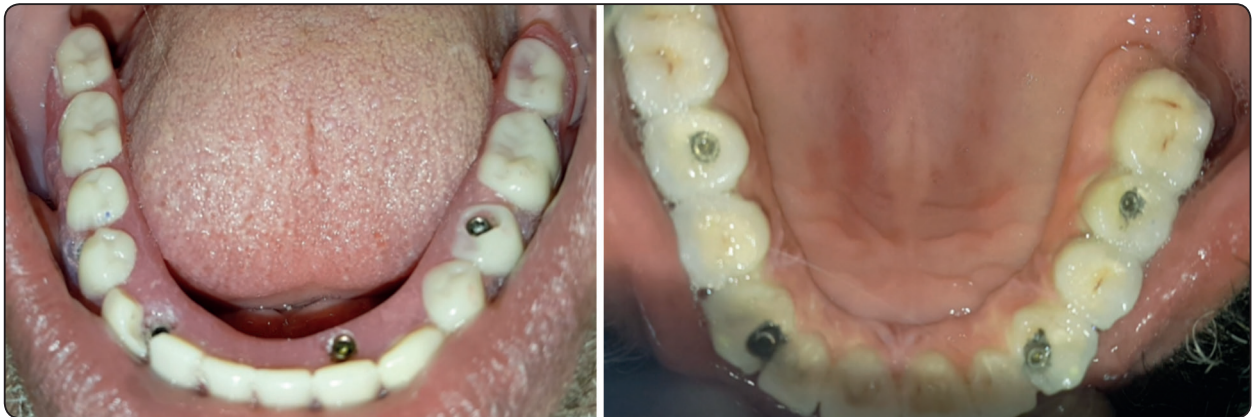

Fig. (4) Mandibular and maxillary fixed detachable prosthesis in place

system on the CD and was used to trace the digital images. Vertical bone height changes were measured as the distance between implant platform (IP) and first bone/implant contact (BI) (fig 3).

The Implant length and width was used to compensate for magnification or minification errors to obtain actual values of marginal bone height. Independent researcher performed all radiographic measurements after sufficient instructions and calibrations to reduce inter-examiner errors. Three readings were made by the same examiner on the same day for each image and the mean was subjected to statistical evaluation. The vertical distance IF-BI was evaluated 6 months and 12 months after insertion and the values were subtracted from the IF-BI at time of prosthesis insertion to obtain vertical bone loss at 6 and 12 months respectively<sup>16,17</sup>. Mesial and distal vertical bone loss were calculated. The difference between mesial and distal values were tested by Wilcoxon signed-rank test without significant difference obtained ( $p > .05$ ). Therefore, mesial and distal values were averaged and the mean was used to represent vertical bone loss for each implant. The measurement was done on patient level and not on implant level to avoid clustering effect.

#### Statistical analysis

SPSS software version 22 (SPSS Inc.) was used to analyze the data with the level of significance was

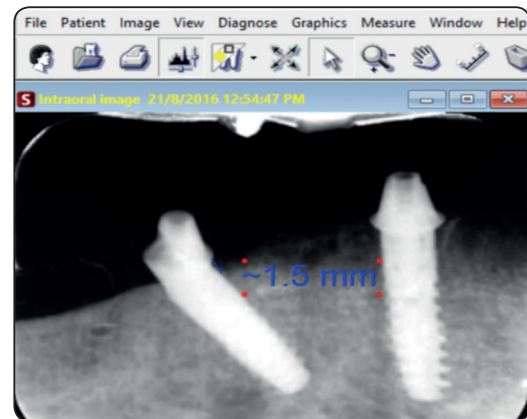


Fig. (5) Vertical bone height changes using the software

set at .05. The non-parametric tests were used for evaluation of the collected data since the data did not meet the normal distribution. Wilcoxon signed ranks test was used to detect significant difference in vertical bone loss between the two observation periods. Mann Whitney test was used to compare bone loss between maxillary and mandibular implants and between anterior and posterior implants.

#### RESULTS

The intention to treat principle was followed in this study. One patient could not complete the analysis and was excluded from the study due to failure of 2 maxillary anterior implants. The survival rate of mandibular implants was 100% and no implant failure occurred. The survival rate

of maxillary implants was 91.6%. The implant was consisted survived when it was still in place, meet success criteria suggested by Albrektsson et al<sup>18</sup> (no mobility, no signs of parathesia, regardless peri-implant bone loss). No significant difference in implant survival between groups was noted (Log rank test,  $P=.153$ ).

Comparison of VBL between 6 and 12 months with maxillary and mandibular jaw for anterior and posterior implants is presented in table 1 and 2. For anterior implants of maxillary and mandibular jaws, VBL after 12 months was significantly higher than VBL after 6 months ( $p<.003$ ). For posterior implants of maxillary and mandibular jaws, no significant difference in VBL between 6 and 12 months were observed.

Comparison of VBL between maxillary and mandibular implants after 6 and 12 months for anterior and posterior jaws is presented in table 1

and 2. For anterior implants, maxillary implants recorded significantly higher marginal bone loss than mandibular implants after 6 months ( $p<.001$ ) and 12 months ( $p=.005$ ) of prosthesis delivery. For posterior implants, no significant difference in marginal bone loss between maxillary and mandibular implants was observed after 6 months and 12 months of prosthesis delivery.

Comparison of VBL between anterior and posterior implants in both jaws after 6 and 12 months of prosthesis delivery are presented in fig 3 and 4 respectively. For mandibular implants, there was no statically significant difference in VBL between anterior and posterior implants after 6 months ( $p=.12$ ) and 12 months ( $p=.15$ ) of prosthesis insertion. For maxillary implants, anterior implants showed more significant VBL than posterior implants after 6 months ( $p<.001$ ) and 12 months ( $p<.001$ ) of prosthesis insertion.

TABLE (1) Vertical bone loss around anterior implants for maxillary and mandibular jaw after 6 months and 12 months of prosthesis insertion

	6 months			12 months			Wilcoxon signed ranks (p value)
	med	Min	max	med	Min	max	
<b>Mandibular jaw</b>	.10	.10	1.70	.20	.06	3.13	.001*
<b>Maxillary jaw</b>	1.28	.88	2.18	1.78	.78	2.28	.002*
<b>Mann-Whitney p value</b>	<.001*			.005*			

*Med=median, min=minimum, max=maximum*

TABLE (2) Vertical bone loss around posterior implants for maxillary and mandibular jaw after 6 months and 12 months of prosthesis insertion

	6 months			12 months			Wilcoxon signed ranks (p value)
	med	Min	max	med	Min	max	
<b>Mandibular jaw</b>	.25	.00	1.38	.17	.17	2.48	.91
<b>Maxillary jaw</b>	.33	.06	1.08	.48	.02	1.38	.55
<b>Mann-Whitney p value</b>	.71			.40			

*Med=median, min=minimum, max=maximum*

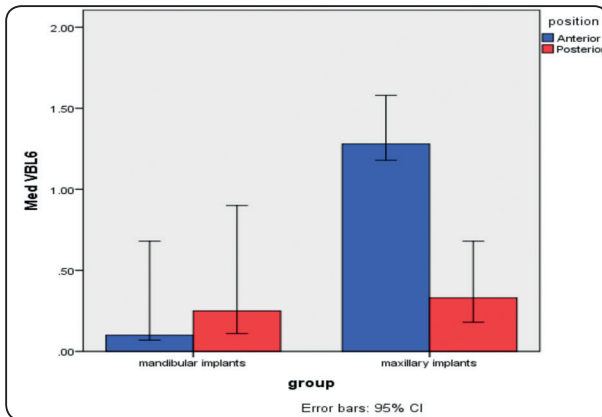


Fig. (6) Comparison of VBL between anterior and posterior implants in both jaws after 6 months of prosthesis delivery

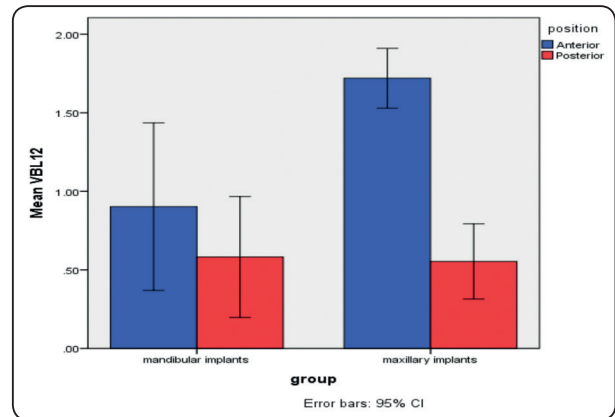


Fig. (7) Comparison of VBL between anterior and posterior implants in both jaws after 12 months of prosthesis delivery

## DISCUSSION

Studying of peri-implant marginal bone height changes was performed in the same patient. This allow standardization of all patient factors that may influence marginal bone loss such as gender, muscle activity, masticatory habits, bite forces and type of occlusal scheme. Moreover, a small sample size can be used with this within patient study compared to parallel group studies<sup>19</sup>. The flapless surgical approach was used in this study as it has several advantages including; minimal post-operative discomfort, reduced edema, and facilitate immediate prosthetic loading with provisional dentures (no sutures or open wound)<sup>20, 21</sup>. Moreover, the flapless approach reduced the peri-implant bone loss as reflection of the flap cause mucoperiosteal stripping that may induce bone loss around the implants<sup>22</sup>. Stereolithographic surgical stent together with CBCT was used for proper data transfer of the surgical field and for implant placement. This template allows accurate 3-dimensional placement of the implants in planned implant position. The conventional stent and the 2-dimensional panoramic radiographs are not capable for accurate visualization of bone and vital structure position in buccolingual dimension.<sup>23</sup>

No significant difference in implant survival between maxillary and mandibular implants was noted. Similarly, Malo and colleagues<sup>24</sup> found that the overall cumulative implant survival rate at 1 year was 97.2% and 100% in the maxilla and the mandible, respectively, without significant difference between maxillary and mandibular implants

The normal average of marginal bone loss values reported in the literature is less than 1mm in the first year and <0.2 mm annually thereafter<sup>18, 25-27</sup>. Except marginal bone loss of maxillary anterior implants (1.2-1.7mm), the marginal bone loss for both maxillary posterior implants and mandibular anterior and posterior implants observed after 6 and 12 months remains within the normal range. For anterior implants of maxillary and mandibular jaws, VBL after 12 months was significantly higher than VBL after 6 months. This was not surprising to find the VBL increased with time. This may be due to bone reorganization and maturation and healing combined with functional stresses<sup>18</sup>. However, the effect of time on VBL was evident for anterior implants only and not for posterior implants.

For anterior implants only, maxillary implants recorded significant higher marginal bone loss

than mandibular implants after 6 and 12 months of prosthesis delivery. The increased VBL around maxillary anterior implants compared to mandibular implants may be due to these implants are inclined palatally due to the shape of the palatine vault. The implant inclination was associated with greater strain and marginal bone loss than the vertical oriented ones<sup>28</sup>. Moreover, the reduced bone quality of maxilla contributes to more VBL than compact bone in the anterior mandible<sup>17, 29</sup>. Furthermore, the patients may develop the habit of habitual mandibular protrusion during wearing the provisional fixed acrylic prosthesis (as there is no contact with posterior teeth), thus transferring increased occlusal load on the anterior maxillary implants when final fixed prosthesis was delivered.

Also, maxillary anterior implants showed more significant VBL than posterior implants after 6 months and 12 months of prosthesis insertion. Similarly, Calandriello and Tomatis<sup>30</sup> found a lower bone loss values for tilted implants supporting fixed prosthesis, as compared with upright ones. Furthermore, Wismeijer et al.<sup>31</sup> reported that in cases with 4 interconnected straight implants, there was significantly more bone loss around the central 2 implants in comparison with the distal 2 implants. Earlier studies<sup>32, 33, 31</sup> reported a greater bone resorption around medially positioned implants in fixed retained prosthesis.

For posterior implants, no significant difference in marginal bone loss between maxillary and mandibular implants was observed after 6 months and 12 months of prosthesis delivery. In line with this observation, a relatively recent systematic review reported no difference between maxillary and mandibular implants supporting all on four prosthesis recorded after 1 year<sup>34</sup>.

For mandibular implants, there was no significant difference in VBL between anterior and posterior implants after 6 months and 12 months. Similar to this findings, a clinical study by Lopes et

al<sup>35</sup> found no significant difference in marginal bone loss between axially and distally tilted implants after 5-year evaluation period. Also Francetti et al.<sup>36</sup> assessed immediately loaded full-arch fixed bridges anchored to both tilted and axially placed implants (All-on-Four®) and compared the outcome of axial versus tilted implants, and found no significant difference in marginal bone loss between tilted and axial implants at 1-year evaluation.

## CONCLUSION

Within the limitation of this short-term study, taking the small patient cohort into account, it could be concluded that maxillary anterior implants supporting All on four hybrid prosthesis are at increased risk for marginal bone loss compared to maxillary posterior implants or mandibular implants. However, long term randomized controlled clinical studies are needed to accept or reject the findings of this study

## REFERENCES

1. Attard NJ, Zarb GA. Long-term treatment outcomes in edentulous patients with implant-fixed prostheses: the Toronto study. *Int J Prosthodont.* 2004;17:417-24.
2. Sadowsky SJ, Hansen PW. Evidence-based criteria for differential treatment planning of implant restorations for the mandibular edentulous patient. *J Prosthodont.* 2014;23:104-11.
3. Malo P, de Araujo Nobre M, Lopes A, Francischone C, Rigolizzo M. "All-on-4" immediate-function concept for completely edentulous maxillae: a clinical report on the medium (3 years) and long-term (5 years) outcomes. *Clin Implant Dent Relat Res.* 2012;14 Suppl 1:e139-50.
4. Malo P, Friberg B, Polizzi G, Gualini F, Vighagen T, Rangert B. Immediate and early function of Branemark System implants placed in the esthetic zone: a 1-year prospective clinical multicenter study. *Clin Implant Dent Relat Res.* 2003;5 Suppl 1:37-46.
5. Malo P, Rangert B, Nobre M. All-on-4 immediate-function concept with Branemark System implants for completely edentulous maxillae: a 1-year retrospective clinical study. *Clin Implant Dent Relat Res.* 2005;7 Suppl 1:S88-94.



6. Malo P, Rangert B, Nobre M. "All-on-Four" immediate-function concept with Branemark System implants for completely edentulous mandibles: a retrospective clinical study. *Clin Implant Dent Relat Res.* 2003;5 Suppl 1:2-9.
7. Pozzi A, Sannino G, Barlattani A. Minimally invasive treatment of the atrophic posterior maxilla: a proof-of-concept prospective study with a follow-up of between 36 and 54 months. *J Prosthet Dent.* 2012;108:286-97.
8. Francetti L, Agliardi E, Testori T, Romeo D, Taschieri S, Del Fabbro M. Immediate rehabilitation of the mandible with fixed full prosthesis supported by axial and tilted implants: interim results of a single cohort prospective study. *Clin Implant Dent Relat Res.* 2008;10:255-63.
9. Adell R, Eriksson B, Lekholm U, Branemark PI, Jemt T. Long-term follow-up study of osseointegrated implants in the treatment of totally edentulous jaws. *Int J Oral Maxillofac Implants.* 1990;5:347-59.
10. Gratton DG, Aquilino SA, Stanford CM. Micromotion and dynamic fatigue properties of the dental implant-abutment interface. *J Prosthet Dent.* 2001;85:47-52.
11. Kunavisarut C, Lang LA, Stoner BR, Felton DA. Finite element analysis on dental implant-supported prostheses without passive fit. *J Prosthodont.* 2002;11:30-40.
12. Spazzin AO, Dos Santos MB, Sobrinho LC, Consani RL, Mesquita MF. Effects of horizontal misfit and bar framework material on the stress distribution of an overdenture-retaining bar system: a 3D finite element analysis. *J Prosthodont.* 2011;20:517-22.
13. Begg T, Geerts GA, Gryzagoridis J. Stress patterns around distal angled implants in the all-on-four concept configuration. *Int J Oral Maxillofac Implants.* 2009;24:663-71.
14. Browaeys H, Dierens M, Ruyffelaert C, Matthijs C, De Bruyn H, Vandeweghe S. Ongoing Crestal Bone Loss around Implants Subjected to Computer-Guided Flapless Surgery and Immediate Loading Using the All-on-4(R) Concept. *Clin Implant Dent Relat Res.* 2015;17:831-43.
15. Krekmanov L, Kahn M, Rangert B, Lindstrom H. Tilting of posterior mandibular and maxillary implants for improved prosthesis support. *Int J Oral Maxillofac Implants.* 2000;15:405-14.
16. Elsyad MA, Elsaïh EA, Khairallah AS. Marginal bone resorption around immediate and delayed loaded implants supporting a locator-retained mandibular overdenture. A 1-year randomised controlled trial. *J Oral Rehabil.* 2014;41:608-18.
17. Elsyad MA, Ghoneem NE, El-Sharkawy H. Marginal bone loss around unsplinted mini-implants supporting maxillary overdentures: a preliminary comparative study between partial and full palatal coverage. *Quintessence Int.* 2013;44:45-52.
18. Albrektsson T, Zarb G, Worthington P, Eriksson AR. The long-term efficacy of currently used dental implants: a review and proposed criteria of success. *Int J Oral Maxillofac Implants.* 1986;1:11-25.
19. Elsyad MA, Khairallah AS. Chewing efficiency and maximum bite force with different attachment systems of implant overdentures: a crossover study. *Clin Oral Implants Res.* 2017;28:677-82.
20. Campelo LD, Camara JR. Flapless implant surgery: a 10-year clinical retrospective analysis. *Int J Oral Maxillofac Implants.* 2002;17:271-6.
21. Elsyad MA. A new surgical template with a handpiece positioner for use during flapless placement of four dental implants to retain a mandibular overdenture. *J Prosthodont.* 2012;21:573-7.
22. Caneva M, Botticelli D, Salata LA, Souza SL, Bressan E, Lang NP. Flap vs. "flapless" surgical approach at immediate implants: a histomorphometric study in dogs. *Clin Oral Implants Res.* 2010;21:1314-9.
23. Lal K, White GS, Morea DN, Wright RF. Use of stereolithographic templates for surgical and prosthodontic implant planning and placement. Part II. A clinical report. *J Prosthodont.* 2006;15:117-22.
24. Malo P, de Araujo Nobre M, Lopes A. The use of computer-guided flapless implant surgery and four implants placed in immediate function to support a fixed denture: preliminary results after a mean follow-up period of thirteen months. *J Prosthet Dent.* 2007;97:S26-34.
25. Roos J, Sennerby L, Lekholm U, Jemt T, Grondahl K, Albrektsson T. A qualitative and quantitative method for evaluating implant success: a 5-year retrospective analysis of the Branemark implant. *Int J Oral Maxillofac Implants.* 1997;12:504-14.
26. Albrektsson T, Zarb GA. Current interpretations of the osseointegrated response: clinical significance. *Int J Prosthodont.* 1993;6:95-105.
27. Zarb GA, Albrektsson T. Consensus report: towards optimized treatment outcomes for dental implants. *J Prosthet Dent.* 1998;80:641.

28. Elsyad MA, Abid KS, Elkhalek EA. Effect of Buccal Implant Inclination on Stresses Around Two-Implant-Retained Overdentures with Resilient Stud Attachments. *Int J Oral Maxillofac Implants*. 2017;32:e135-e42.
29. Rodriguez AM, Orenstein IH, Morris HF, Ochi S. Survival of various implant-supported prosthesis designs following 36 months of clinical function. *Annals of periodontology / the American Academy of Periodontology*. 2000;5:101-8.
30. Calandriello R, Tomatis M. Simplified treatment of the atrophic posterior maxilla via immediate/early function and tilted implants: A prospective 1-year clinical study. *Clin Implant Dent Relat Res*. 2005;7 Suppl 1:S1-12.
31. Wismeijer D, van Waas MA, Mulder J, Vermeeren JI, Kalk W. Clinical and radiological results of patients treated with three treatment modalities for overdentures on implants of the ITI Dental Implant System. A randomized controlled clinical trial. *Clin Oral Implants Res*. 1999;10:297-306.
32. Lindquist LW, Rockler B, Carlsson GE. Bone resorption around fixtures in edentulous patients treated with mandibular fixed tissue-integrated prostheses. *The Journal of prosthetic dentistry*, 1988;1988 .
33. Ahlqvist J, Borg K, Gunne J, Nilson H, Olsson M, Astrand P. Osseointegrated implants in edentulous jaws: a 2-year longitudinal study. *Int J Oral Maxillofac Implants*. 1990; 5:155-63.
34. Patzelt SB, Bahat O, Reynolds MA, Strub JR. The all-on-four treatment concept: a systematic review. *Clin Implant Dent Relat Res*. 2014;16:836-55.
35. Lopes A, Malo P, de Araujo Nobre M, Sanchez-Fernandez E, Gravito I. The NobelGuide(R) All-on-4(R) Treatment Concept for Rehabilitation of Edentulous Jaws: A Retrospective Report on the 7-Years Clinical and 5-Years Radiographic Outcomes. *Clin Implant Dent Relat Res*. 2017;19:233-44.
36. Francetti L, Agliardi E, Testori T, Romeo D, Taschieri S, Fabbro MD. Immediate rehabilitation of the mandible with fixed full prosthesis supported by axial and tilted implants: Interim results of a single cohort prospective study. *Clinical Implant Dentistry and Related Research*. 2008;10:255-63.