



RESEARCH ARTICLE

Stress Response in Both of Laparoscopic and Open Cholecystectomy in Dogs (An Experimental Study)

Shimaa A. Ezzeldein, Ahmed M. Abdelhady*, Ahmed E. Behery and AbdEl-Basit M. AbdEl-Aal
Surgery, Anesthesiology and Radiology Department, Faculty of Veterinary Medicine, Zagazig
University, 44511, Zagazig, Sharkia Government, Egypt.

Article History: Received: 03/09/2019 Received in revised form: 15/09/2019 Accepted: 17/09/2019

Abstract

This study was conducted to compare the serum level of Cortisol and Interleukin-6 (Stress Response) on eighteen clinically healthy mongrel male dogs of different ages (1-2 years old) with body weight ranged between 17-25 kg. Dogs were classified into two main groups open cholecystectomy and laparoscopic one. Anesthesia and postoperative management were identical in both groups. Serum level of cortisol was evaluated as a marker to assess surgical trauma and pain where it was measured before the operation (time 0) to obtain base line value and at 4 hours postoperatively. In addition, serum level of Interleukin-6 (IL-6) was evaluated also before the operation and at 4 and 24 hours after the surgery as a marker for the degree of systemic reaction to wide range of trauma. There was a significant ($P < 0.05$) lower concentration of serum cortisol in the laparoscopic group at four hours postoperatively than in the open surgery group. Serum levels of IL-6 during laparoscopic cholecystectomy were found to be significantly ($P < 0.05$) lower than that during open cholecystectomy at 4 and 24 hrs postoperatively. The current study concluded that the laparoscopic cholecystectomy with small skin incisions with the avoidance of open laparotomy and excessive manipulation of tissues can minimize surgical stress and provide more favorable postoperative conditions for dogs. This indicated that laparoscopic cholecystectomy is more recommendable than traditional open cholecystectomy.

Keywords: Stress response, Cortisol, Interleukin-6, Laparoscopy, Cholecystectomy.

Introduction

Laparoscopy is a minimally invasive surgical procedure with an endoscope inserted trans-abdominally to monitor organs within the abdominal and pelvic cavities. The surgeon can visually examine the viscera and peritoneal surfaces for evidence of disease during laparoscopy and perform surgical procedures [1, 2, 3].

Laparoscopic surgery has become popular in veterinary medicine providing a clear view of the abdominal organs with a direct image for surgeons. It is associated with faster return to function and reduction in both of surgical site infections and postoperative pain [4,5,6].

Laparoscopy can be used in diagnosis of internal diseases demanding direct visualization and histological examination. Diaphragm, peritoneum, liver, gallbladder,

spleen, omentum, intestine, kidneys, ovaries, pancreas and urinary bladder are obtainable structures. It gained place as a diagnostic and surgical tool in hepatic and biliary diseases. [7, 8].

Cholecystectomy is the most common procedure performed for the treatment of gallbladder diseases as biliary tract or gallbladder rupture, necrotizing cholecystitis gallbladder mucocele (GBM) and symptomatic gallstones [7,8]. Cholecystectomy can be performed either laparoscopically using a video camera without making the traditional incision or via an open surgical technique [9]. Surgical trauma caused by open cholecystectomy initiates a stress response which causes several bad biological effects on the operated dogs. In

contrast to open surgery, with minimal access to the abdominal cavity, laparoscopic surgical procedures are correlated with fewer postoperative complications [10, 11].

The stress response is the name given following injury or trauma to the hormonal and metabolic changes. This is part of the systemic injury reaction involving a wide range of endocrinological, immunological and haematological effects [12, 13].

The sympathetic nervous system (SNS) is activated in times of stress for the fight or flight response, causing a cascade of hormonal and physiological reactions. The amygdala is responsible for processing fear, arousal, and emotional stimuli to determine the appropriate response. If necessary, the amygdala sends a stress signal to the hypothalamus [14]. The hypothalamus activates the SNS, and the adrenal glands release a wave of catecholamines, like epinephrine; this causes tachycardia, hypertension, diaphoresis, increase in respiratory rate and an increase in blood glucose. The hypothalamus activates the hypothalamic-pituitary-adrenal (HPA) axis as the body continues to interpret the stimuli as a threat. The parasympathetic nervous system decreases the SNS reaction when the threat goes through [15]. The stress response to surgery is represented by enhanced secretion of pituitary hormones and sympathetic nervous system (SNS) activation. The changes in pituitary secretion have secondary influences on hormone secretion from target organs. As corticotrophin release from the pituitary stimulates cortisol secretion from the adrenal cortex. Cortisol secretion from the adrenal cortex increases quickly following the start of surgery. Its release is increased in response to stress and low blood-glucose concentration. It works to increase blood sugar through gluconeogenesis, suppress the immune system, and assist in fat, protein, and carbohydrate metabolism. Cortisol concentrations used for evaluation of surgical trauma and pain assessment [16, 17,18].

As an early stress response to tissue injury, cytokines are generated from activated

leukocytes, fibroblasts and endothelial cells and play a significant role in immunity and inflammation mediation. Interleukin-1 (IL-1), tumor necrosis factor- α (TNF- α) and Interleukin-6 (IL-6) are the primary cytokines produced. The original response is to release IL-1 and TNF- α into the damaged tissues from activated macrophages and monocytes. This encourages the production and release of extra cytokines, especially IL-6 [19, 20]. IL-6 is the primary cytokine responsible for causing systemic modifications known as the acute phase response that occurs after tissue injury. It plays a critical role in regulation of cellular processes like osteoclastogenesis, hematopoiesis and many aspects of immune regulation. Increased concentrations of IL-6 are frequently associated with homeostasis disorders, such as those associated with inflammation or trauma [21, 22]. The manufacturing of acute phase proteins in the liver is one of its characteristics. These proteins serve as inflammatory mediators, anti-proteinases and scavengers in the repair of tissues [23, 24].

This study aimed to compare the serum level of cortisol and IL-6 in dogs that underwent laparoscopic cholecystectomy to those who underwent open cholecystectomy.

Materials and Methods

This study was conducted on eighteen adult male mongrel experimental dogs (stray dogs) weighing 17-25 kg and aged from 1 to 2 years. Dogs were housed in isolated cages with water availability and dry food (MERA. The Pet food Family, Germany) in the Department of surgery, anesthesiology and radiology, Faculty of veterinary medicine, Zagazig university according to the basis of its committee of animal welfare and research ethics (ZU-IACUC/2/F/2/2019).

Dogs were classified into two main groups, open cholecystectomy (OC) and laparoscopic one (LC). Animals were premedicated with xylazine hydrochloride 2 % (Adwia pharmaceutical Co. 10th of Ramadan City, Egypt) at 1 mg/kg, body weight, IM. General anaesthesia was induced using intravenous

administration of Thiopental sodium 2.5% (SIGMATEC Pharmaceutical Industries. 6th October. Giza. Egypt) at 20 mg/kg, body weight.

Open Cholecystectomy (OC)

Under aseptic conditions, 8 cm laparotomy incision was done in the midline just behind the xiphoid cartilage up to the umbilicus. The wound was widened and gallbladder was visualized after grasping the pylorus and duodenum. The fundus of the gallbladder was caught by an Allis forceps and bluntly dissected from the hepatic fossa using a sterile piece of gauze [25].

The cystic duct was freed and 2 metallic clips were applied. The gallbladder was removed by cutting between the 2 clips using a blunt ended straight scissors. The resulting hemorrhage was controlled by tamponing. The abdominal wound was closed using Vicryl suture no. 2-0 (Hannover. D-28857. Syke. Germany) (Figure 1A).

Laparoscopic Cholecystectomy (LC)

Under aseptic conditions, dogs were positioned in dorsal recumbency (reverse trendelenburg). A three port technique was applied for performing laparoscopic cholecystectomy and arranged as following; portal no.1 was approximately 0.5 cm caudal to the umbilicus for exploration the abdomen and placed other two additional ports under direct visualization. Portal no.2 was placed on the left 3 to 5 cm cranial and 5 to 8 cm lateral to the umbilicus. Portal no.3 was placed on the midline 5 cm cranial to the umbilicus and each port represented by 1cm [26].

The gallbladder was retracted with a 5 mm laparoscopic babcock grasping forceps to elevate the gallbladder to a place where the cyst duct was visible. The gallbladder with cystic duct was dissected from its hepatic fossa with laparoscopic dissecting forceps. The cystic duct was supplemented with 3 medium/large hemostatic metallic clips using a reusable 10 mm laparoscopic clip applicator (Figure 1B).

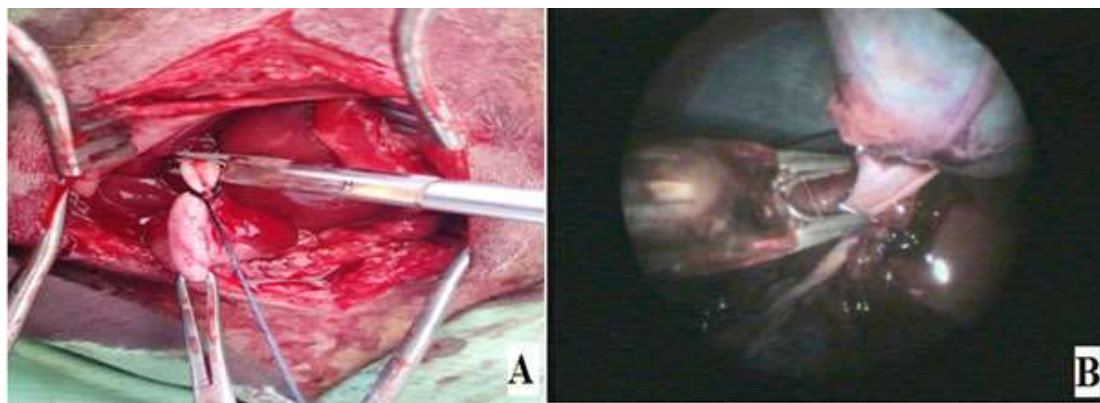


Figure (1): (A) Open Cholecystectomy technique; traction the gall bladder for visualization of the cystic duct with placement of surgical metallic clips using clip applicator prior to transection in dog aged two years old (B) Laparoscopic Cholecystectomy technique; the cystic duct is dissected and closed with medium/large hemostatic metallic clips using a reusable 10mm laparoscopic clip applicator prior to transection in two years age dog.

Cystic duct transection was performed with laparoscopic metzenbaum scissors leaving 2 clips in position around the cystic duct and 1 in position at the junction of the cystic duct with the gall bladder. The gallbladder was removed through the portal no.3. Portals were closed by single simple interrupted sutures using Vicryl no. 2-0.

Postoperative care

Daily dressing on the skin stitches was done with betadine antiseptic solution (10% The Nile Company for pharmaceuticals and chemical industries, Cairo. A.R.E.). Systemic dose of antibiotic (Amoxycillin sodium and Flucloxacillin sodium; (Flumox® 1gm) (EIPICO Company, Egypt) was injected

intramuscularly (22mg/kg) once daily for 5 days, anti-inflammatory (declophen®) (PHARCO Pharmaceutical Company, Egypt) 1 mg/kg I/M. The skin sutures were removed 10 days post operation.

Laboratory Examinations

Physical examination; attitude, gait, temperature, heart rate, respiratory rate and mucous membrane were evaluated for 5 days after surgery.

Blood samples for serum chemistry profile (cortisol and IL-6) were collected from cephalic vein (18 dogs). The first blood sample was drawn prior to surgical intervention to obtain baseline values. The other samples were obtained at 4 h post surgery for determination of cortisol value and at 4 h and 24 h for determination of IL-6 value utilizing quantitative sandwich enzyme-linked immunosorbent assay (ELISA). Invitrogen Kits (Cortisol Competitive ELISA Kit, Interleukin 6 (IL-6) ELISA Kit)

Statistical analysis

Statistical analysis was applied by SPSS (IBM SPSS Statistics for Windows) version 24. Parametric data were expressed as mean \pm SD and mixed model ANOVA was run to test differences between open and laparoscopy cholecystectomy techniques at different time points for cortisol and IL6. $P < 0.05$ was considered significant for all analyses. Duncan's multiple range test was used as post hock test [27].

Results

Experimental cholecystectomy in dogs was performed using two techniques (Open and Laparoscopic). The wounds in both groups were healed without any complications.

Physical examination of the operated animals in group of OC showed signs of discomfort, somewhat stiffness in gait and raised abdomen for the first three days post surgery. Animals in the group of LC showed less pain and normal attitude. The Visible Mucous membranes of dogs in the two groups appeared rosy red and moist. Temperature was ranging from (38.4°C-39.5°C) with an average (38.9°C) within normal limits except three cases in group of OC showed (40.2°C) on the 2nd day after surgery managed by anti-inflammatory (Declophen) 1 mg/kg I/M. Heart rate was ranged from (66 beat/min-125 beat/min) with an average (95.5beat/min) and respiratory rate was ranged from (15 breath/min-35breath/min) with an average (25 breath/min) within normal limits.

There was significant ($P < 0.05$) increase in cortisol value in OC group at 4 h post surgery in comparison to base line (0.48 ± 0.04 and 0.38 ± 0.03), respectively. In LC group, there was no significant ($P > 0.05$) difference in cortisol value at 4 h post-surgery (0.34 ± 0.18) in comparison to base line (0.34 ± 0.13). Cortisol value was significantly ($P < 0.05$) higher in OC group (0.48 ± 0.04) in comparison to LC group (0.34 ± 0.18) as revealed in Table (1) and Figure (2).

Table (1): Cortisol and IL6 values at base line and after open and laparoscopy surgery in dogs

	Base line	After 4hrs.	
Open	0.38 ± 0.03^b	0.48 ± 0.04^a	
Laparoscopy	0.34 ± 0.13^b	0.34 ± 0.18^b	
P-value		0.04*	
	Base line	After 4hrs.	After 24hrs.
Open	0.11 ± 0.01^e	0.36 ± 0.09^b	0.40 ± 0.07^a
Laparoscopy	0.11 ± 0.04^e	0.20 ± 0.14^{cd}	0.25 ± 0.2^c
P-value		0.02*	

Values are mean \pm SD. Means carrying different superscript were statistically different according to Duncan's multiple range test at $P < 0.05$.

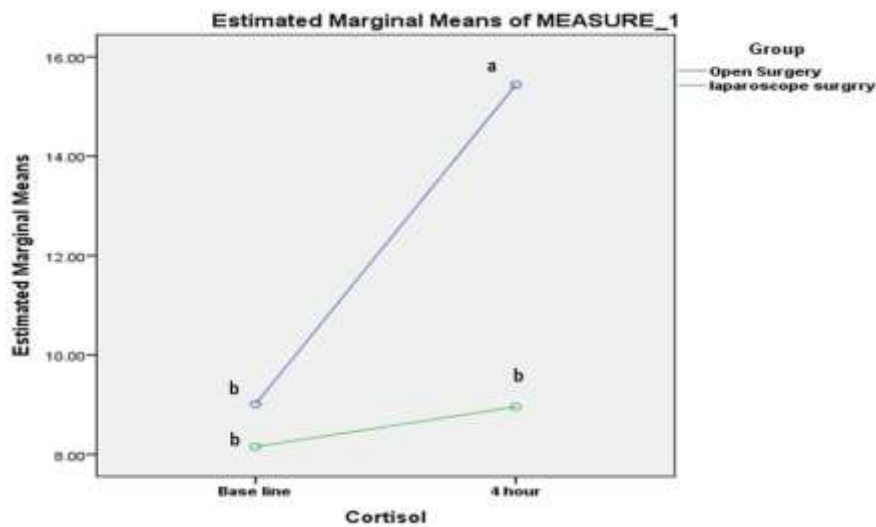


Figure (2): Interaction plot show the effect of interaction between type of surgery and time point at which reading of cortisol was recorded. At base line there was no significant difference in cortisol value between open and laparoscopy ($P > 0.05$), while at 4h cortisol value significantly higher in open surgery compared to laparoscopy surgery ($P < 0.05$) in dogs.

As presented in Table (1) and Figure (3), there was significant ($P < 0.05$) increase in IL-6 value in OC group at 4 h post surgery in comparison to base line (0.36 ± 0.09 and 0.11 ± 0.01), respectively and slightly significant ($P < 0.05$) increase was found at 24 h post surgery (0.40 ± 0.07) in comparison to 4 h values (0.36 ± 0.09).

Concerning with IL-6, there was significant ($P < 0.05$) increase in LC group

value at 4 h after surgery (0.20 ± 0.14) in comparison to base line (0.11 ± 0.04) and slight significant ($P < 0.05$) increase at 24 h post operation in comparison to 4 h values (0.25 ± 0.2 and 0.20 ± 0.14), respectively. Moreover, IL- 6 values were significantly higher ($P < 0.05$) at 4 h and 24 h post surgery in OC group (0.36 ± 0.09 and 0.20 ± 0.14) than its values in LC group (0.40 ± 0.07 and 0.25 ± 0.2) as depicted in Table (1) and Figure (3).

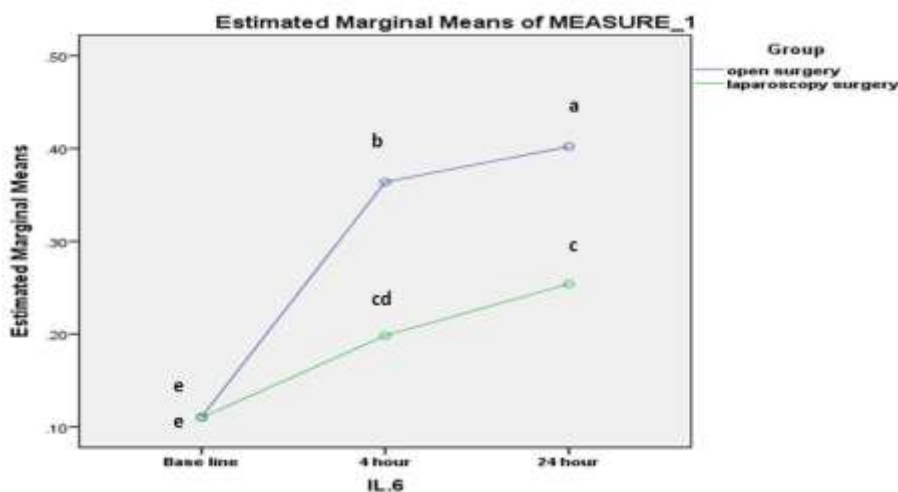


Figure (3): Interaction plot show the effect of interaction between type of surgery and time point at which reading of interleukin-6 was recorded. At base line there was no significant difference in IL6 value between open and laparoscopic surgery ($P > 0.05$), while at 4h IL6 value significantly higher in open surgery compared to laparoscopic surgery and also the value was significantly higher at 24 h in open surgery compared to laparoscopy ($P < 0.05$) in dogs.

Discussion

Both open and laparoscopic techniques of cholecystectomy were performed successfully in clinically healthy male dogs and the obtained results of the physical examinations were similar to that was reported by Scott [26].

Protocol of anesthesia of premedication of xylazine 2% followed by general anesthesia with thiopental sodium was applied providing optimal anaesthesia in dogs with minimal post operative side effects. This protocol in agreement with Ünsaldı [28] who was satisfied with the use of injectable thiopental induction without inhalation maintenance in colecystectomy in dogs as the used doses were sufficient for the time of the operations.

Regarding the open cholecystectomy technique applied in the present work in group I (open cholecystectomy group), a 8 cm ventral midline celiotomy in the epigastric region was sufficient for performing cholecystectomy successfully in dogs. These applications were in agreement with that was described by Martin [25]. On the other hand, Hotokezaka *et al.* [29] used the same technique with 20 cm long midline celiotomy and Mekawy [30] used the same technique with 10 -15 cm long midline celiotomy.

Concerning with group II (laparoscopic cholecystectomy group), laparoscopic cholecystectomy was successfully performed with securing of the cystic duct using 10 mm metallic hemostatic clips. The cystic duct was transected and gallbladder was removed without excess manipulation or trauma. Three port techniques were sufficient for providing proper visualization of the gallbladder and performing the cholecystostomy as previously performed in dogs [26].

For comparison between open and laparoscopic surgery in dogs, cortisol and IL 6 were measured as a markers for the pain and surgical stress in dogs.

Cortisol was evaluated at 4h post surgery as a serum marker for evaluation of surgical trauma and pain assessment and showed significant increase in (OC) group in

comparison to (LC) group. This was in agreement with Marcovich *et al.* [31] who stated that the cortisol concentrations increased to a maximum at 4 h post surgery and fell to baseline by 8 - 24 h.

Interleukin - 6 was evaluated at 4h hrs and 24 hrs after surgery as a serum marker for the degree of systemic reaction to wide range of trauma and showed significant increase in (OC) group in comparison to (LC) group. This was supported by the findings of Desborough [12] and Baigrie *et al.* [32] who stated that the concentration of IL-6 increased after the beginning of surgery within 30–60 min. The shift in concentration was significant after 2–4 h and concentrations were maximum at approximately 24 h and stayed high for 48 h postoperatively.

In agreement with Marcovich *et al.* [31], postoperative serum level of cortisol in dogs that underwent laparoscopic cholecystectomy was significantly lower than those in dogs of the open cholecystectomy group. They attributed the rapid decrease in serum cortisol after laparoscopic nephrectomy in dogs compared with open surgery to lesser degree or quicker surgical stress resolution. However, Hancock *et al.* [33] found that there were nosignificant differences in the concentrations of cortisol between the two groups of ovariohysterectomy with harmonic scalpel-assisted laparoscopy and traditional ovariohysterectomy in dogs and concentrations in both groups were considered normal at 6 h postoperatively.

Serum level of IL - 6 in dogs of LC group was found to be significantly lower than that of OC group. This finding was in consistent with Glaser *et al.* [34] and Silveira *et al.* [35] who stated that the minimally invasive surgical procedures lead to reduced operational wound size, less abdominal wall lesion, muscles and aponeurosis and therefore reduced tissue damage. The handling and traction of abdominal organs by retractors is lower in laparoscopic surgery. Tampons were not used on viscera or the abdominal wall was retracted. These factors may be associated with a

reduction in the magnitude and duration of cytokine serum concentrations after laparoscopic cholecystectomy. Other attributions were described by Hanly *et al.* [36] and Watson *et al.* [37] that the laparoscopic surgery required to inject gas into the abdominal cavity, producing pneumoperitoneum, the most commonly used gas being carbon dioxide (CO₂). The existence of CO₂ in the abdominal cavity appears to attenuate this acute inflammatory phase response, potentially triggering local cellular acidosis and blocking cytokine secretion, altering cytokine receptors in the liver and other tissues or acting in hepatocytes, altering the hepatic reaction to inflammatory stimuli.

Conclusion

Laparoscopic cholecystectomy with small skin incisions with the avoidance of open laparotomy and excessive manipulation of tissues can minimize surgical stress and provide more favorable postoperative conditions for dogs. From these points, laparoscopic cholecystectomy is more recommendable than traditional open cholecystectomy.

Conflict of interest

The authors have no conflict of interest to declare.

References

- [1] Bouré, L. (2005): General principles of laparoscopy. *Vet Clinic Food Anim*, 21: 227-249.
- [2] Milovancev, M. and Townsend, K. L. (2015): Current concepts in minimally invasive surgery of the abdomen. *Vet Clin North Am Small Anim Pract*, 45(3): 507-522.
- [3] Phipps, W. E.; Goodman, A. R. and Sullivan, M. (2016): Ovarian remnant removal using minimally invasive laparoscopic techniques in four dogs. *J Small Anim Pract*, 57(4): 214-216.
- [4] Ezzeldein, S.A. (2016): Laparoscopic Surgery for Ovariectomy in She donkeys (An Experimental Study), Ph.D. (Veterinary Surgery). Faculty of Veterinary Medicine. Zagazig University. Egypt.
- [5] Hancock, R. B.; Lanz, O. I.; Waldron, D. R.; Duncan, R. B.; Broadstone, R. V. and Hendrix, P. K. (2005): Comparison of the postoperative pain after ovariohysterectomy by harmonic scalpel-assisted laparoscopy compared with median celiotomy and ligation in dogs. *Vet Surg*, 34:273–282.
- [6] Sali, K. M. (2010): Determination of anatomical location to the parts of female genital system of Awassi ewes by using laparoscopy. *J.Vet.Anat*, 3(2): 47-54.
- [7] Kirpensteijn, J.; Fingland, R. B.; Ulrich, T.; Sikkema, D. A. and Allen, S. W. (1993): Cholelithiasis in dogs: 29 cases (1980-1990). *J Am Vet Med Assoc*, 202(7): 1137-1142.
- [8] Besso, J. G.; Wrigley, R. H.; Gliatto, J. M. and Webster, C. R. L. (2000): Ultrasonographic appearance and clinical findings in 14 dogs with gallbladder mucocele. *Vet Radiology and Ultrasound*, 41(3): 261-271.
- [9] Pike, F. S.; Berg, J.; King, N. W.; Penninck, D. G. and Webster, C. R. (2004): Gallbladder mucocele in dogs: 30 cases (2000–2002). *J Am Vet Med Assoc*, 224(10):1615-1622.
- [10] Zorron, R. and Carvalho, G. (2015): Laparoscopy and laparotomy. *Yamada's Textbook of Gastroenterology*, 2693-2702.
- [11] Aspinen, S.; Kinnunen, M.; Harju, J.; Juvonen, P.; Selander, T.; Holopainen, A.; and Eskelinen, M. (2016): Inflammatory response to the surgical trauma in patients with minilaparotomy cholecystectomy versus laparoscopic cholecystectomy: a randomised multicentre study. *Scand J Gastroenterol*, 51(6): 739-744.
- [12] Desborough, J. P. (2000): The stress response to trauma and surgery. *Br J Anaesth*, 85(1): 109-117.

- [13] Nicholson, G. and Hall, G. M. (2016): Stress Response During Surgery. In *Gastrointestinal and Colorectal Anesthesia*. CRC Press. pp.: 55-66.
- [14] Hakamata, Y.; Komi, S.; Moriguchi, Y.; Izawa, S.; Motomura, Y.; Sato, E. and Tagaya, H. (2017): Amygdala-centred functional connectivity affects daily cortisol concentrations: a putative link with anxiety. *Sci rep*, 7(1), 8313.
- [15] Thau, L. and Sharma, S. (2019). *Physiology, Cortisol*. In *StatPearls [Internet]*. StatPearls Publishing.
- [16] Desborough, J.P. and Hall, G.M. (1993): Endocrine response to surgery. In: Kaufman L. *Anaesthesia Review*. Vol. 10. Edinburgh: Churchill Livingstone: 131–48.
- [17] Nicholson, G.; Burrin, J. M. and Hall, G. M. (1998): Peri-operative steroid supplementation. *Anaesthesia*, 53(11): 1091-1104.
- [18] Taves, M. D.; Gomez-Sanchez, C. E. and Soma, K. K. (2011): Extra-adrenal glucocorticoids and mineralocorticoids: evidence for local synthesis, regulation, and function. *Am J Physiol Endocrinol Metab*, 301(1), E11-E24.
- [19] Trotta, P. P. (1991): Cytokines: an overview. *Am J Reprod Immunol*, 25(3): 137-141.
- [20] Sheeran, P. and Hall, G. M. (1997): Cytokines in anaesthesia. *Br J Anaesth*, 78(2): 201-219.
- [21] Daynes, R. A.; Araneo, B. A.; Ershler, W. B.; Maloney, C.; Li, G. Z. and Ryu, S. Y. (1993): Altered regulation of IL-6 production with normal aging. Possible linkage to the age-associated decline in dehydroepiandrosterone and its sulfated derivative. *J Immunol*, 150(12): 5219-5230.
- [22] Lutgendorf, S. K.; Garand, L.; Buckwalter, K. C.; Reimer, T. T.; Hong, S. Y. and Lubaroff, D. M. (1999): Life stress, mood disturbance, and elevated interleukin-6 in healthy older women. *J Gerontol A Biol Sci Med Sci*, 54(9), M434-M439.
- [23] Kushner, I. (1993): Regulation of the acute phase response by cytokines. *Perspect Biol Med*, 36(4): 611-622.
- [24] Kushner, I. and Rzewnicki, D. L. (1994): The acute phase response: general aspects. *Baillieres Clin Rheumatol.*, 8(3): 513-530.
- [25] Martin, R.A.; Lanz, O.I. and Tobias, K.M. (2003): Slatter, D. H. (3rd Ed.). *Textbook of small animal surgery* (Vol. 1). Elsevier health sciences. CHAPTER 44 , Liver and Biliary System :708-726 , surgery of the gallbladder and bile duct: 718-719.
- [26] Scott, J.; Singh, A.; Mayhew, P. D.; Brad Case, J.; Runge, J. J.; Gatineau, M. and Kilkenny, J. (2016): Perioperative complications and outcome of laparoscopic cholecystectomy in 20 dogs. *Veterinary surgery*, 45(S1): O49-O59.
- [27] Corp I.B.M. Released (2016): *IBM SPSS Statistics for Windows, Version 24.0*. Armonk, NY: IBM Corp.
- [28] Ünsaldı, S.; Kılıç, S.; Yılmaz, Ö. and İşler, C. T. (2009): Effect of xylazine-thiopental anesthesia on canine fatty acid profiles. *Yüzüncü yıl Üniversitesi Veteriner Fakültesi Dergisi*, 20(1): 49-51.
- [29] Hotokezaka, M.; Combs, M. J.; Mentis, E. P. and Schirmer, B. D. (1996): Recovery of fasted and fed gastrointestinal motility after open versus laparoscopic cholecystectomy in dogs. *Ann Surg*, 223(4): 413-419.
- [30] MekKawy N .H. M. (1978): Experimental studies on cholecystectomy in the dog. M.V.Sc. (Veterinary Surgery). Faculty of veterinary medicine, Zagazig University, Egypt: p 14 -16.
- [31] Marcovich, R.; Williams, A. L.; Seifman, B. D. and Wolf Jr, J. S. (2001): A canine model to assess the biochemical stress

- response to laparoscopic and open surgery. J Endourol, 15(10): 1005-1008.
- [32] Baigrie, R. J.; Lamont, P. M.; Kwiatkowski, D.; Dallman, M. J. and Morris, P. J. (1992): Systemic cytokine response after major surgery. Br J Surg, 79(8): 757-760.
- [33] Hancock, R. B.; Lanz, O. I.; Waldron, D. R.; Duncan, R. B.; Broadstone, R. V. and Hendrix, P. K. (2005): Comparison of postoperative pain after ovariohysterectomy by harmonic scalpel-assisted laparoscopy compared with median celiotomy and ligation in dogs. Vet Surg, 34(3): 273-282.
- [34] Glaser, F.; Sannwald, G. A.; Buhr, H. J.; Kuntz, C.; Mayer, H.; Klee, F. and Herfarth, C. (1995): General stress response to conventional and laparoscopic cholecystectomy. Ann. Surg, 221(4), 372.
- [35] Silveira, F. P.; Nicoluzzi, J. E.; Saucedo Júnior, N. S.; Silveira, F.; Nicollelli, G. M. and Maranhão, B. S. D. A. (2012): Evaluation of serum levels of interleukin-6 and interleukin-10 in patients undergoing laparoscopic versus conventional cholecystectomy. Rev Col Bras Cir, 39(1): 33-40.
- [36] Hanly, E. J.; Mendoza-Sagaon, M.; Murata, K.; Hardacre, J. M.; De Maio, A. and Talamini, M. A. (2003): CO₂ pneumoperitoneum modifies the inflammatory response to sepsis. Ann. Surg, 237(3), 343-350.
- [37] Watson, R. W. G.; Redmond, H. P.; McCarthy, J.; Burke, P. E. and Bouchier-Hayes, D. (1995): Exposure of the peritoneal cavity to air regulates early inflammatory responses to surgery in a murine model. Br J Surg, 82(8): 1060-1065.

الملخص العربي

الاستجابة للإجهاد الناتج من عمليات استئصال المرارة باستخدام منظار البطن وبالجراحة في الكلاب (دراسة تجريبية)

شيماء احمد عز الدين¹, احمد محمد عبدالهادي^{2*}, احمد السيد بحيري¹ وعبدالباسط محمد عبدالعال¹

قسم الجراحة والتخدير والاشعة - كلية الطب البيطري - جامعة الزقازيق - الزقازيق ٤٤٥١١ مصر

تهدف هذه الدراسة إلى إجراء مقارنة بين مستوى الكورتيزون والإنترليوكين-٦ (الاستجابة للإجهاد) حيث أجريت هذه الدراسة على ثمانية عشر من الكلاب الذكور السليمة ظاهرياً من مختلف الأعمار حيث تراوحت أعمارها بين عام إلى عامين وتراوحت أوزانها بين ١٧-٢٥ كجم. صنفت الحيوانات إلى مجموعتين رئيسيتين هما استئصال المرارة بالجراحة التقليدية والجراحة باستخدام المنظار الجراحي. كان التخدير والمتابعة بعد الجراحة متطابقة في كلتا المجموعتين. تم تقييم نسبة الكورتيزول كعلامة لتقييم الصدمة الجراحية والالام حيث تم قياسه قبل العملية الجراحية للحصول على القيمة الطبيعية لمستوى الكورتيزول في الدم وقياسه بعد ٤ ساعات من بداية العملية. أيضاً تم تقييم نسبة الإنترليوكين-٦ قبل العملية وقياسه بعد ٤ و ٢٤ ساعة بعد الجراحة كعلامة لتقييم رد الفعل النظامي للجسم لمجموعه من الصدمات. اثبتت النتائج ان تركيزات نسبة الكورتيزول في الدم أقل بكثير ($P < 0.05$) عند قياسها بعد ٤ ساعات بعد الجراحة في مجموعة المنظار الجراحي مما كانت عليه في مجموعة الجراحة التقليدية. وايضا اشارت النتائج ان نسبة الإنترليوكين-٦ في مجموعة المنظار الجراحي اقل بكثير ($P < 0.05$) من قيمها في مجموعة الجراحة التقليدية عند قياسها بعد ٤ و ٢٤ ساعة بعد العملية الجراحية. وخلصت الدراسة الحالية إلى أن استئصال المرارة بالمنظار الجراحي مع وجود شق صغير في الجلد و تجنب فتح البطن والتلاعب المفرط للأنسجة، يمكن أن تقلل من الإجهاد الجراحي وتوفر ظروف مواتية بعد الجراحة للكلاب. ومن هذا يمكن أن نستنتج ان استئصال المرارة بالمنظار الجراحي موصى به أكثر من استئصالها بالجراحة التقليدية.