

# Osteotomy Methods for Treatment of Blount's Disease

## A Systematic Review

Mohamed O. Hegazy<sup>a</sup>, Hani A. Bassiouni<sup>a</sup>, Adel S. El Hammady<sup>a</sup>, Mostafa M. El-Morsi<sup>b</sup>

<sup>a</sup> Department of Orthopedic surgery, Benha faculty of Medicine, Benha University, Egypt, <sup>b</sup> Department of Orthopedic surgery, El Matariya Hospital, Egypt.

**correspondence to:** Mostafa M. El-Morsi, Department of Orthopedic surgery, El Matariya Hospital Egypt

email:

freesprinter59@gmail.com

available online: 27 June 2020

### Abstract:

Blount disease is one of the pathological idiopathic causes of genu varum. Includes the infantile and late-onset (adolescent) types. Pathological changes are localized to the posteromedial part of the proximal tibia due to the increased stresses on this part. Treatment by osteotomy followed by gradual correction and external fixation is becoming more popular for precise correction and diminished morbidity. Prognosis depends on the patient's age and the severity of deformity at the time of intervention.

**Key words:** Blount disease, osteotomy, acute correction, gradual correction, Ilizarov and external fixators.

### Background

Blount disease is a developmental condition characterized by multiplanar deformities of the tibia with varus, procurvatum (apex anterior), and internal rotation [1]. The first detailed description was provided by Blount [2], and this was followed by another extensive study by Langenskiöld [3]. Blount disease can lead to a progressive deformity with gait deviations, limb-length discrepancy, and premature arthritis of the knee [4].

The epidemiology of Blount disease is not well documented. The estimated prevalence is less than 1% [5] in the United States. There is an increased incidence of disease in the overweight African American population [6]. The frequency is increased if other family members have been diagnosed as having the disease [7,8].

Predisposition for tibia vara has been attributed to race, genetics, age at walking, and obesity.

Blount disease most likely is caused by a combination of excessive compressive forces on the proximal medial metaphysis of the tibia and altered endochondral bone formation [9–11].

Two clinically distinct forms of Blount disease, early-onset, or infantile, and late-onset have been described, with the classifications based on whether the limb deformity develops before or after the age of 4 years [12]. Thompson and Carter [13] further classified the late-onset form into juvenile type (onset at the age of 4–10 years) and an adolescent type (onset after the age of 10 years) [14]. Bilateral involvement is common, particularly with an early-onset presentation [15]. Langenskiöld and Riska [16] described six radiographic stages of progressive changes at the proximal tibial epiphysis and metaphysis in children with the early-onset type. With advancing age and higher Langenskiöld stages (V and VI), irreversible physeal changes with permanent inhibition of the medial portion of the tibial growth plate can occur. Although the Langenskiöld classification is useful, there is substantial interobserver variability, especially with regard to the intermediate stages [9].

The physical manifestations of Blount disease include the internal tibial torsion, genu varum, limb-length disparity, gait changes, and ligamentous instability of the knee [13].

Definitive diagnosis of Blount disease is based on the progressive clinical bowing which occurs in the presence of characteristic radiographic changes about the proximal and

medial tibial physis, as initially described by Langenskiöld [14].

The principle of management in Blount disease is alteration of abnormal compressive forces so that the normal growth will resume and the genu varum will be corrected [17]. The treatment should begin in an early stage by restoring the anatomical axis of the knee until completing the merging of all growth cartilage while addressing the leg's length discrepancy [12].

Different methods have been reported for the treatment of Blount disease depending on factors such as the patient's age, the magnitude of deformity, severity of physeal and epiphyseal changes, and the presence or absence of secondary valgus deformity of the distal part of the femur [9].

The treatment is broadly the same whatever the cause and comprises either acute or gradual correction of the deformity. In the former, the tibia is osteotomized, the mechanical axis is corrected, and the osteotomy is stabilized in the corrected position [18]. Once the deformity has been corrected and stabilized, there is very little scope for further correction if the position is suboptimal without recourse to further surgery. There are also potential complications of nerve palsy, malalignment, loss of alignment, limb-length inequality, compartment syndrome, failure of fixation,

and recurrence of deformity [19,20]. The alternative technique of gradual deformity correction by distraction osteogenesis using an external fixator allows for accurate deformity correction and has the potential to allow fine tuning of the correction without any further surgical intervention to achieve an optimal reduction [21]. However, this technique requires a high degree of patient compliance and has the potential for different complications such as premature consolidation of the regenerate bone, which may also require further operations [22]. Other treatment options include bracing, which may be suitable in milder forms of infantile Blount's disease, and hemiepiphysiodesis, which may be suitable in adolescents with milder degrees of varus deformity and with open physes [23].

### **Aim of this study**

To conduct a systematic review and best evidence synthesis on different methods of osteotomy in the treatment of Blount disease (tibia vara). The primary outcome measure is accuracy of correction on radiographs; secondary outcome measures are reoperation for residual deformity and other complications.

---

### **Patients and methods**

A systematic review of the literature was conducted across the two major medical literature databases, MEDLINE and

EMBASE. A search of the Cochrane Library for relevant reviews or trials was also made. All forms of primary interventional study in any language that reported radiographic outcome measures after a single-level tibial osteotomy as a primary procedure for idiopathic tibia vara in children were considered. Those which also reported reoperation rates were used to extract the secondary outcome data. Articles were included that reported correction in multiple different bones as long as the data on tibial correction could be extracted separately. Similarly, articles that reported correction for different etiologies were included, as long as the data on Blount disease could be extracted separately. Exclusion criteria included case reports, studies that combined angular deformity correction with lengthening, studies that reported a change in angular deformity rather than absolute values for limb alignment, studies where correction was performed without a tibial osteotomy (e.g. distraction of a physis), and studies reporting on congenital deformities. The reference sections of the included studies were also searched to identify additional relevant studies.

---

### **Results**

The search of MEDLINE and EMBASE initially gave 99 possible articles. Of these, 18 were reviewed on the basis of the inclusion and exclusion criteria. One study compared

acute with gradual correction of tibia vara in Blount disease. The remaining 17 studies were retrospective case series and will be summarized thereafter.

Feldman *et al.* [17] reported a retrospective comparative study comparing the accuracy of acute with gradual correction of tibia vara deformity in children with Blount disease. The two groups were similar with regard to age, sex, and severity of deformity (Fig. 1), although they were not randomized or matched. No significant differences were found in preoperative deformity parameters between the groups. Both groups underwent the same osteotomy. The acute correction group (AC,  $n=14$  tibiae) was stabilized with a monolateral fixator, whereas the gradual correction group (GC,  $n=18$ ) was stabilized with a Taylor Spatial Frame (Fig. 2). All the patients in the AC group had prophylactic fasciotomies. All patients were followed up for 2 years after the operation. The preoperative, postoperative, and final follow-up deformities were assessed (Figs 3–5) using the system described by Paley and colleagues. Both groups spent a similar time in the frame. One patient in the AC group had a delayed union, and there were no cases of nonunion. The only other complications were two pin site infections in the AC group and three in the GC group; there were no re-operations, deep infections, neurovascular complications,

or cases of compartment syndrome in either group (Fig. 6).

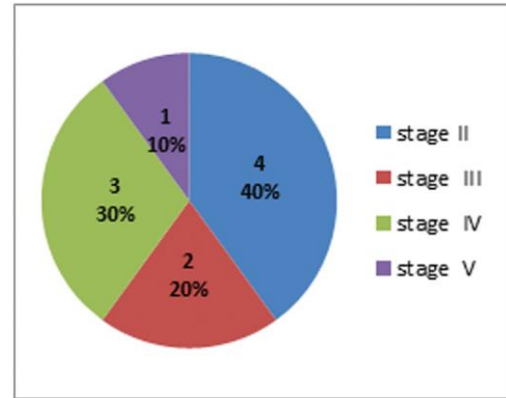


Fig. (1): Langenskiöld stage (infantile group).

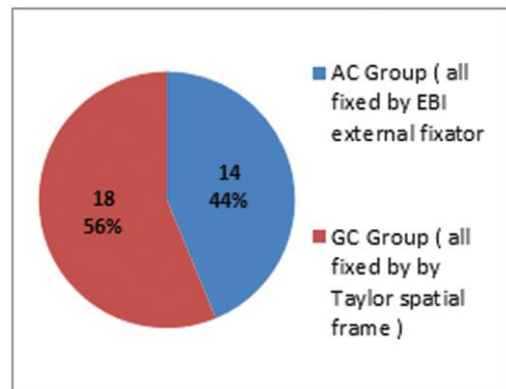


Fig.(2): Methods of correction and type of fixation.

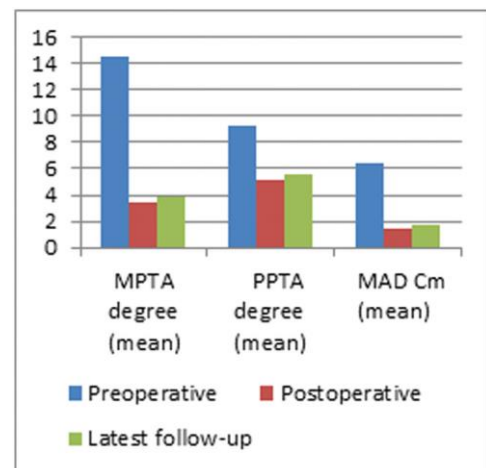


Fig. (3): Radiological outcome of the acute correction group.

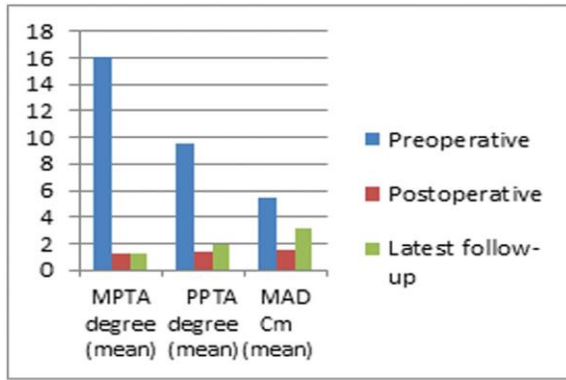


Fig.(4): Radiological outcome of the gradual correction group.

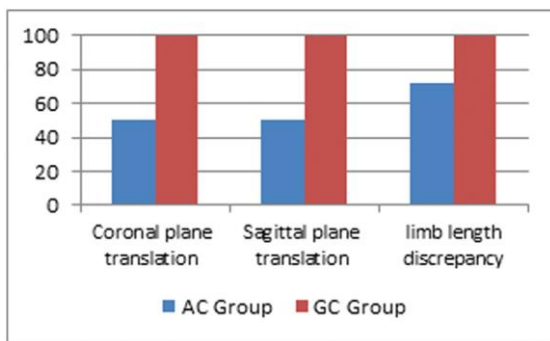


Fig. (5): Accuracy of coronal, sagittal plane translation, and limb-length discrepancy correction (percentage).

The mean medial proximal tibial angle for the GC group at the final follow-up was less than that for the AC group, but this was not statistically different (1.3 and 3.9°, respectively); however, the difference in mechanical axis deviation was significant, with the GC group doing better both postoperatively (13.9 mm for AC vs. 1.5 mm for GC) and at final follow-up (17.1 mm for the AC group vs. 3.1 mm for the GC group). In terms of accuracy of reduction, 94.4% of the GC group were accurate compared with 50% of the AC group at the final follow-up. This was significant. This was the only study

that attempted to compare the two methods of deformity correction. Theoretically, there is no reason why complete correction and maintenance thereof should not be achievable with a monolateral fixator if it is mounted exactly in the plane of the deformity.

Gradual correction using a Taylor Spatial Frame would seem to give a more accurate reduction after 2 years than acute correction and external fixation, but what is still not clear is whether the difference is principally due to the rate of correction or the type of fixator used.

The remaining studies consisted of retrospective case series describing one or other treatment type. For the most part, they are each unique in describing a particular combination of osteotomy (Fig. 7), fixation (Fig. 8), and rate of correction. There were 12 studies reporting on acute correction, comprising 182 tibiae in 144 children (Tables 1–3). A considerable variety of osteotomies are described, including oblique, double elevating, upright dome, inverted dome, serrated W/M, opening and closing wedge, and percutaneous transverse. This reflects the fact that in acute correction, very often, the configuration of the osteotomy is fundamental to stability or alignment, or both, and accuracy when performing the osteotomy is therefore often critical. The range of final mean mechanical axes achieved was from 10.6° valgus to 2° varus, with the majority

being within the range of 0 to 5° valgus (Fig. 9). Re-operations were required in 16 cases, most of which were major procedures for recurrent deformity or inadequate correction. Deep infections were seen in three patients who had been treated with external fixation (of 116) and none in the patients treated with internal fixation or cast immobilization (Fig. 10).

There were five studies reporting on gradual correction, comprising 146 tibiae in 98 patients (Table 3). The osteotomies, where reported, were all of the simple transverse type (Fig. 11). The range of final mean mechanical axes was from 1 to 7.5° of valgus, with the majority being within the 0 to 5° range (Fig. 12). Re-operations were required in 26 cases, of which, eight were major, for recurrence of deformity, inadequate correction, or premature consolidation of the regenerate. There were no cases of deep infection (Fig. 13).

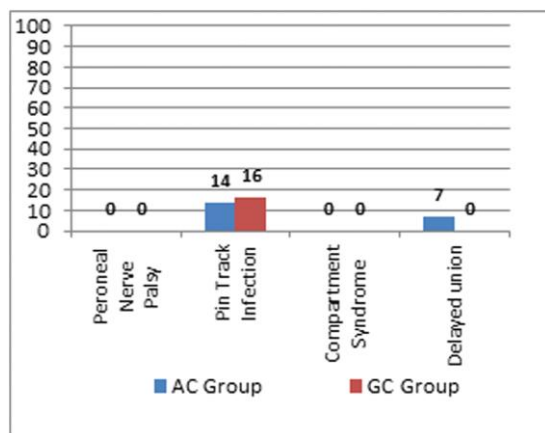


Fig. (6): Postoperative complications of acute correction versus gradual correction group

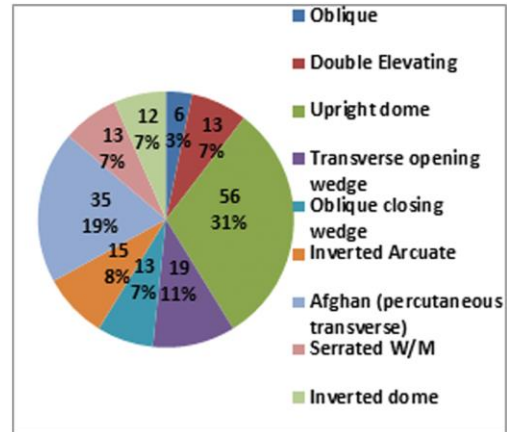


Fig. (7): Type of osteotomy in acute correction studies.

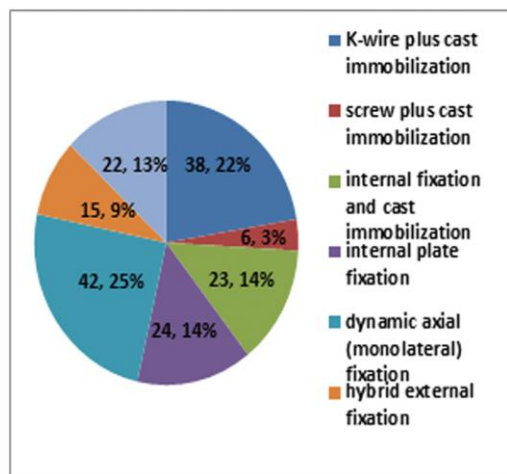


Fig. (8): Type of fixation in acute correction studies.

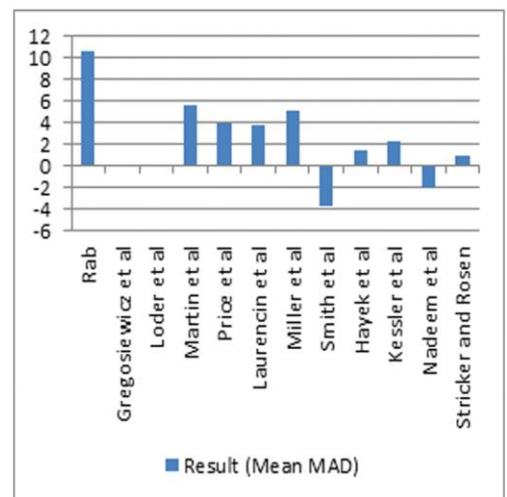


Fig. (9): Result (mean mechanical axis deviation) in acute correction studies; positive values represent valgus overcorrection while negative values represent residual varus deformity.

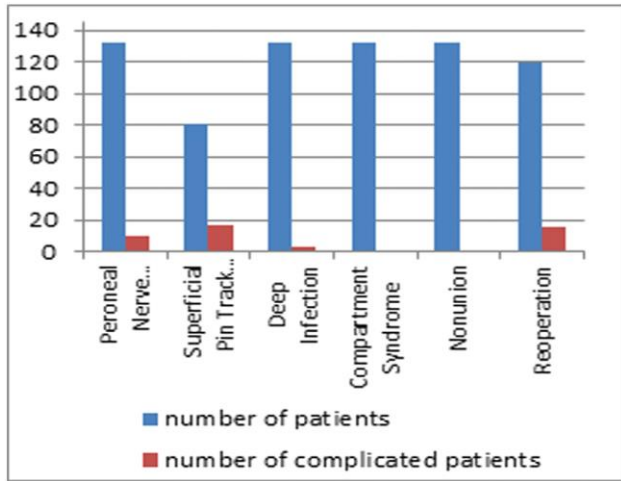


Fig. (10): Postoperative complications in acute correction studies.

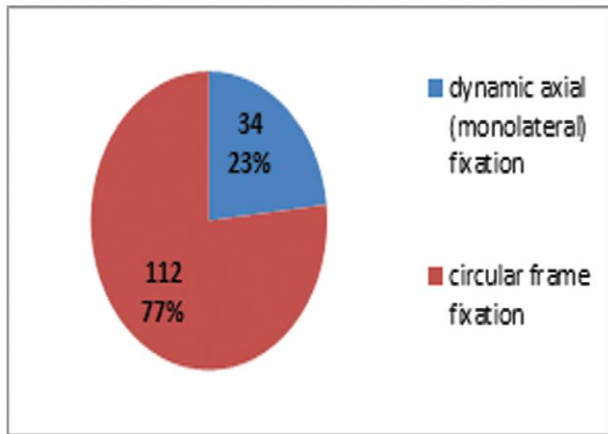


Fig. (11): Type of fixation in gradual correction studies.

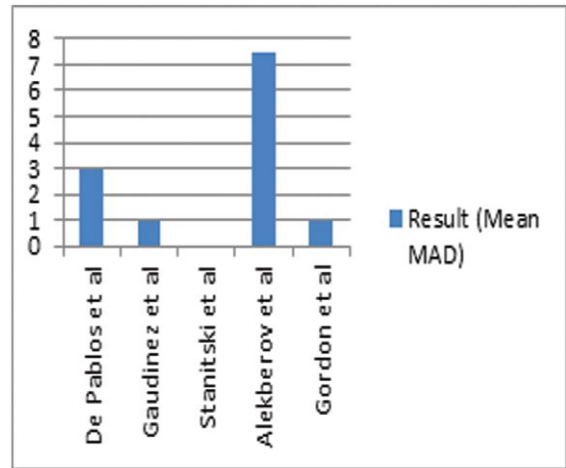


Fig. (12): Results (mean mechanical axis deviation) of the gradual correction group; positive values represent valgus overcorrection while negative values represent residual varus deformity.

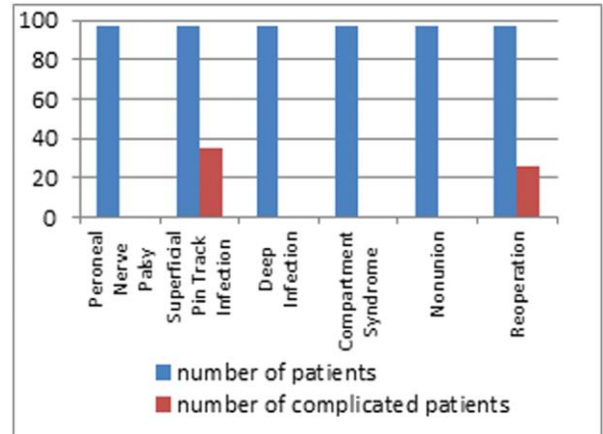


Fig. (13): Postoperative complications of the gradual correction group.

Table 1 Twelve case series of acute correction

Study	Miller <i>et al.</i> [24]	Smith <i>et al.</i> [25]	Hayek <i>et al.</i> [20]	Kessler <i>et al.</i> [26]	Dilawaiz Nadeem <i>et al.</i> [27]	Stricker and Rosen [28]
Sample size	15 tibiae and 12 limbs	23 tibiae in 19 patients	13 tibiae in 9 patients	12 tibiae in 12 patients	12 tibiae	22 tibiae in 17 patients
Type of correction and fixation	Acute correction and hybrid external fixation	Acute correction and monolateral external fixation	Acute correction and cast immobilization+K-wire	Acute correction and monolateral external fixation	Acute correction and K-wire and cast fixation	Acute correction and circular frame fixation
Type of osteotomy	Inverted arcuate	Afghan (percutaneous transverse)	Serrated W/M	Afghan (percutaneous transverse)	Inverted dome	Upright dome
Follow-up	2 years 6 months	2.7 years	2.8 years	NS	2 years	25 months
Result	Mean MA, 5.1-degree valgus	Mean MA, 3.8-degree varus	Mean MA, 1.4-degree valgus	Mean MA, 2.2-degree valgus	Mean MA, 2-degree varus	Mean MA, 1 degree
Reoperation	3 (major)	4 minor, plus serial debridements for infection	None	NS	Not certain	None
Peroneal nerve palsy	None	1 (transient)	None	NS	1 (transient)	None
Superficial pin track infection	None	2	NA	NS	None	5
Deep infection	2	1	None	NS	None	None
Compartment syndrome	None	None	None <sup>a</sup>	NS	None	None
Nonunion	None	None	None	NS	None	None



**Table 2:** Twelve case series of acute correction

Study	De Pablos <i>et al.</i> [29]	Gaudinez and Adar [30]	Stanitski <i>et al.</i> [22]	Alekberov <i>et al.</i> [31]	Gordon <i>et al.</i> [32]
Sample size	20 tibiae in 10 patients	14 tibiae in 11 patients	24 tibiae in 16 patients	69 tibiae in 45 patients	19 tibiae in 15 patients
Type of correction and fixation	Gradual correction with monolateral frame	Gradual correction with monolateral fixator	Gradual correction with circular frame	Gradual correction with circular frame	Gradual correction with circular frame
Type of osteotomy	Transverse	Transverse	NS	Transverse	Transverse
Follow-up	3 years 3 months	2 years	16 months to 61/2 years	6 years 8 months	5 years
Result	Mean MA, 3-degree valgus	Mean MA, 1-degree valgus	All were within 5 degrees of normal	Mean TFA, 7.5-degree valgus (SD, 5.4 degrees)	Mean MPTA, 88 degrees
Reoperation	None	1 (major)	1 (major)	6 (all major)	18 of 19 limbs (all minor)
Peroneal nerve palsy	None	1 (transient)	None	None	None
Superficial pin track infection	40%	2	8	6	15 patients
Deep infection	None	None	None	None	None
Compartment syndrome	None	None	None	None	None
Nonunion	None	None	None	None	None

**Table 3:** Five case series of gradual correction

Study	Rab [33]	Gregosiewicz <i>et al.</i> [34]	Loder <i>et al.</i> [35]	Martin <i>et al.</i> [36]	Price <i>et al.</i> [37]	Laurencin <i>et al.</i> [19]
Sample size	6 tibiae in 5 patients	13 tibiae in 10 patients	23 tibiae in 15 patients	11 tibiae in 7 patients	19 tibiae in 15 patients	13 tibiae in 11 patients
Type of correction and fixation	Acute correction and screw plus cast immobilization	Acute correction and K-wire plus cast immobilization	Acute correction; assortment of internal fixation and cast immobilization	Acute correction and internal plate fixation	Acute correction and dynamic axial (monolateral) fixation	Acute correction and internal plate fixation
Type of osteotomy	Oblique	Double elevating	Dome or valgus wedge	Crescentic (dome)	Transverse opening wedge	Oblique closing wedge
Follow-up	15 months	8 years	4 years 4 months	3 years	2 years 5 months	8 years 6 months
Result	Mean, 10.6-degree valgus (SD, 3.7 degrees)	Mean, 0 degree (SD, 4.1 degrees)	Mean TFA, 0 degree (SD, 6.1 degrees)	Mean MA, 5.6-degree valgus (SD, 1.1 degrees)	Mean MA, 4-degree valgus (SD, 4.1 degrees)	Mean MA, 3.8-degree valgus
Reoperation	1 (major)	2 (major)	2 (major)	2 (major)	None	1 (major)
Peroneal nerve palsy	1 (partial recovery)	1 (transient)	4 (all transient)	None	2 (transient)	None
Superficial pin track infection	NA	1	NA	NA	9	NA
Deep infection	None	None	None	None	None	None
Compartment syndrome	None <sup>a</sup>	None	1	None <sup>a</sup>	None <sup>a</sup>	None <sup>a</sup>
Nonunion	None	None	None	None	None	None

---

## Discussion

General criticisms of all the articles in this review are that they are retrospective, use small sample sizes, and often tend to report on quite different etiologies of tibia vara, which may respond differently to any one treatment. This is perhaps understandable, given that Blount disease is quite uncommon, and it takes most authors several years to gather enough data for a small series, even in specialized centers. They mostly have relatively short follow-up periods, considering these are surgical interventions in the long bones of children who are still growing. There is also some variability in the description of deformities. Particularly in the earlier articles, the authors would quote deformities in degrees of varus or valgus without defining how that measurement was derived. In later articles, greater standardization is seen, largely because of the work of Paley *et al.* [38] starting in the early 1990s. Positive points to take from the series generally is that whichever treatment modality was used, the general complication rate was extremely low. In particular, of all 328 high tibial osteotomies, there was only one documented case of compartment syndrome. Even excluding the 62 cases with prophylactic fasciotomy, there were 265 osteotomies without this complication. There were no cases of nonunion, three cases of deep infection, and 11 cases of peroneal nerve

palsy. Ten of these were in the AC group. All but one was transient, and none was permanently disabling. Superficial pin track infections in the external fixator cases were not common and resolved with oral antibiotics. Suggestions for future research would be to collect data prospectively, to use the same modality of stabilization, and to exclude patients needing more than one procedure on the same limb

---

## Conclusion:

There is weak (level III) evidence that gradual correction using a Taylor Spatial Frame provides a more accurate correction of the mechanical axis than acute correction with a monolateral frame. There is no evidence that either technique leads to a higher reoperation rate or a higher rate of compartment syndrome. There is evidence that acute correction is associated with a higher risk of peroneal nerve palsy, but most cases are transient.

---

## References:

1. Cosma D, Vasilescu DA, Vasilescu D. Comprehensive treatment of complex tibial deformities by single-cut corrective osteotomy. *J Pediatr Orthop* 2005; 8:42–47.
2. Blount WP. Tibia vara: osteochondrosis deformans tibiae. *J Bone Joint Surg Am* 1937; 19:1–29.
3. Langenskiöld A. Tibia vara (osteochondrosis deformans tibiae); a survey of 23 cases. *Acta Chir Scand* 1952; 103:1–22.

4. Zayer M. Osteoarthritis following Blount's disease. *Int Orthop* 1980; 4:63–66.
5. Smith CF. Tibia vara (Blount's disease). *J Bone Joint Surg Am* 1982; 64:630–632.
6. Bradway JK, Klassen RA, Peterson HA. Blount disease: a review of the English literature. *J Pediatr Orthop* 1987; 7:472–480.
7. Cook SD, Lavernia CJ, Burke SW, Skinner HB, Haddad RJ. A biomechanical analysis of the etiology of tibia vara. *J Pediatr Orthop* 1983; 3:449–454.
8. Sabharwal S, Zhao C, McClemens E. Correlation of body mass index and radiographic deformities in children with Blount disease. *J Bone Joint Surg Am* 2007; 89:1275–1283.
9. De Pablos J, Franzreb M. Treatment of adolescent tibia vara by asymmetrical physal distraction. *J Bone Joint Surg Br* 1993; 75:592–596.
10. Sabharwal S, Lee J, Zhao C. Multiplanar deformity analysis of untreated Blount disease. *J Pediatr Orthop* 2007; 27:260–265.
11. Sabharwal S. Blount disease. *J Bone Joint Surg Am* 2009; 91:1758–1776.
12. Stricker S, Edwards P, Tidwell M. Langenskiöld classification of tibia vara: an assessment of interobserver variability. *J Pediatr Orthop* 1994; 14:152–155.
13. Schroerlucke S, Bertrand S, Clapp J, Bundy J, Gregg F. Failure of orthofix eight-plate for the treatment of Tibia vara. *J Pediatr Orthop* 2009; 29:57–60.
14. Davids JR, Blackhurst DW, Allen BL. Radiographic evaluation of bowed legs in children. *J Pediatr Orthop* 2001; 21:257–263.
15. Greene WB. Infantile tibia vara. *J Bone Joint Surg Am* 1993; 75:130–143.
16. Langenskiöld A, Riska EB. Tibia vara (osteochondrosis deformans tibiae): a survey of seventy-one cases. *J Bone Joint Surg Am* 1964; 46:1405–1420.
17. Feldman DS, Madan SS, Ruchelsman DE, Sala DA, Lehman WB. Accuracy of correction of tibia vara: acute versus gradual correction. *J Pediatr Orthop* 2006; 26:794–798.
18. Kempf I, Grosse A, Abalo C. Locked intramedullary nailing. Its application to femoral and tibial axial, rotational, lengthening, and shortening osteotomies. *Clin Orthop* 1986; 212:165–173.
19. Laurencin CT, Ferriter PJ, Millis MB. Oblique proximal tibial osteotomy for the correction of tibia vara in the young. *Clin Orthop* 1996; 327:218–224.
20. Hayek S, Segev E, Ezra E, Lokiec F, Wientroub S. Serrated W/M osteotomy. Results using a new technique for the correction of infantile tibia vara. *J Bone Joint Surg Br* 2000; 82:1026–1029.
21. McCarthy JJ, Mark AK, Davidson RS. Treatment of angular deformities of the tibia in children: acute versus gradual correction. *J Surg Orthop Adv* 2007; 16:118–122.
22. Stanitski DF, Dahl M, Louie K, Grayhack J. Management of late-onset tibia vara in the obese patient by using circular external fixation. *J Pediatr Orthop* 1997; 17:691–694.
23. Henderson RC, Kemp GJ Jr, Greene WB. Adolescent tibia vara: alternatives for operative treatment. *J Bone Joint Surg Am* 1992; 74:342–350.
24. Miller S, Radomisli T, Ulin R. Inverted arcuate osteotomy and external fixation for adolescent tibia vara. *J Pediatr Orthop* 2000; 20:450–454.

25. Smith SL, Beckish ML, Winters SC, Pugh LI, Bray EW. Treatment of late-onset tibia vara using Afghan percutaneous osteotomy and Orthofix external fixation. *J Pediatr Orthop* 2000; 20:606–610.
26. Kessler AC, Pugh LI, Stasikelis PJ. Length changes in tibial osteotomy with angular correction. *J Pediatr Orthop B* 2005; 14:337–339.
27. Dilawaiz Nadeem R, Quick TJ, Eastwood DM. Focal dome osteotomy for the correction of tibial deformity in children. *J Pediatr Orthop B* 2005; 14:340–346.
28. Stricker SJ, Rosen E. Correction of adolescent tibia vara in severely obese children. *Int Pediatr* 2007; 22:17–22.
29. De Pablos J, Azcárate J, Barrios C. Progressive opening-wedge osteotomy for angular long-bone deformities in adolescents. *J Bone Joint Surg Br* 1995; 77:387–391.
30. Gaudinez R, Adar U. Use of orthofix T-Garcke fixator in late-onset tibia vara. *J Pediatr Orthop* 1996; 16:455–460.
31. Alekberov C, Shevtsov VI, Karatosun V, Günal I, Alici E. Treatment of tibia vara by the Ilizarov method. *Clin Orthop* 2003; 409:199–208.
32. Gordon JE, Heidenreich FP, Carpenter CJ, Kelly-Hahn J, Schoenecker PL. Comprehensive treatment of late-onset tibia vara. *J Bone Joint Surg Am* 2005; 87:1561–1570.
33. Rab GT. Oblique tibial osteotomy for Blount's disease (tibia vara). *J Pediatr Orthop* 1988; 8:715–720.
34. Gregosiewicz A, Wosko I, Kandzierski G, Drabik Z. Double-elevating osteotomy of tibiae in the treatment of severe cases of Blount's disease. *J Pediatr Orthop* 1989; 9:178–181.
35. Loder RT, Schaffer JT, Bardenstein MB. Late onset tibia vara. *J Pediatr Orthop* 1991; 11:162–167.
36. Martin SD, Moran MC, Martin TL, Burke SW. Proximal tibial osteotomy with compression plate fixation for tibia vara. *J Pediatr Orthop* 1994; 14:619–622.
37. Price CT, Scott DS, Greenberg DA. Dynamic axial external fixation in the surgical treatment of tibia vara. *J Pediatr Orthop* 1995; 15:236–243.
38. Paley D, Herzenberg JE, Tetsworth K, McKie J, Bhave A. Deformity planning for frontal and sagittal plane corrective osteotomies. *Orthop Clin North Am* 1994; 25:425–465.

**To cite this article:** Mohamed O. Hegazy , Hani A. Bassiouni , Adel S. El Hammady , Mostafa M. El-Morsi' Osteotomy Methods for Treatment of Blount's Disease : A Systematic Review. *BMFJ*, 2020; 37 (2): 449