

THE EFFECT OF SODIUM ALENDRONATE GEL ON OSSEOINTEGRATION OF SUBMERGED DENTAL IMPLANTS

Ahmed A. Hotieba¹*BDS, Ahmed A. Sharara²PHD, Saeeda M. Osman²PHD

ABSTRACT

INTRODUCTION: A plenty of materials have been used to increase the success rate, decrease time needed for osseointegration, stimulate bone formation around dental implants. Bisphosphonates increase bone mineral density by inhibiting osteoclast-mediated bone resorption. Alendronate sodium hydrate is a bisphosphonate that potently inhibits bone resorption and is used to treat osteoporosis. A 1% sodium alendronate gel is manufactured and tested in order to accelerate osseointegration around dental implants.

OBJECTIVES: This study aims to compare clinically and radiographically the osseointegration for 2 groups of submerged dental implants both in upper anterior and premolar region, first group with the use of local sodium alendronate gel prior to placement of dental implant and the second group without.

MATERIALS AND METHODS: A clinical trial on 24 implants divided into 2 groups indicated for dental implant placement in the upper anterior and premolar region selected from the outpatient clinic of the Oral and Maxillofacial department, Faculty of Dentistry, Alexandria University. For the test group 12 implants were placed with sodium alendronate gel just prior to implant placement. For control group 12 implants were placed without sodium alendronate gel.

RESULTS: On the 12 week the resonance frequency analysis (RFA) median records were (55.50, 54.0) and the Mean \pm SD (55.08 \pm 4.94, 54.67 \pm 5.69) for the control group and test group, respectively. The bisphosphonate-coated implants showed an increase in implant stability from 0 to 12 weeks more than the control's measures. On the 12 weeks, the mean peri-implant bone density value was 1417.92 \pm 310.54 for control group and 1550.25 \pm 286.15 for test group. These increases in the bone density were higher in test group than the control group.

CONCLUSIONS: Using sodium alendronate gel with delayed implant placement could enhance the osseointegration around dental implants.

KEYWORDS: Sodium Alendronate gel, osseointegration, cone beam CT, implants stability, bone density.

1. BDS,2011, Faculty of Dentistry, Alexandria University, Egypt.

2. Professor of Oral and Maxillofacial Surgery, Faculty of Dentistry, Alexandria University, Egypt.

*Corresponding author:

E-mail: hotieba@gmail.com

INTRODUCTION

Implant dentistry has been definitively established as a predictable treatment modality for replacing missing or non-restorable teeth which yields excellent clinical success rates (1).

In 1969, Brånemark, an orthopedic surgeon, used titanium to study blood flow in animal research projects. While conducting his research, he found again that the material became solidly embedded in bone, and he called this phenomenon "osseointegration." (2).

The desire to attain faster osseointegration is common for both health professionals and patients. This has motivated research into the development of materials and techniques to optimize the process of bone remodeling around dental implants (3).

During implant placement surgery, the primary stability of the implant in bone tissue is one of the aspects used to determine whether or not to apply an immediate load; In cases in which there is no primary stability during dental implant placement, it is recommended that the professional follows the protocol of two surgical stages, delaying functional loading for the period of osseointegration (3).

In this scenario it becomes important to accelerate the process of osseointegration, so that the delay between implant placement surgery and re-opening for the connection of the prosthetic abutment can be reduced. Interest in the use of bisphosphonates as bone

biomodulators in implant dentistry was aroused because of the known ability of these drugs to inhibit the activity of osteoclasts; this inhibition activity is why the drugs are used widely in the treatment of diseases characterized by excessive bone resorption, such as osteoporosis (4).

Studies have suggested that bisphosphonates may have a positive influence on bone formation and remodeling, and may consequently improve the fixation of titanium implants in humans (5, 6).

The intention is that the bisphosphonate will positively influence the remodeling of bone adjacent to the implant, without causing undesirable systemic side effects. The direct application of bisphosphonate to the osteotomy site immediately before implant insertion would appear to be a simple and more practical procedure (7-9).

Several formulations containing bisphosphonates have been applied to the management of osteoporosis. Alendronate sodium hydrate (alendronate) is a bisphosphonate that potently inhibits bone resorption and is used for the treatment of osteoporosis. Alendronate produces a sustained reduction in the levels of biochemical markers of bone remodeling, returning them to the premenopausal range (10, 11).

The aim of this study was to evaluate clinically and radiographically the osseointegration around submerged dental implants with and without the use of sodium alendronate gel.

MATERIALS AND METHODS

This study was a clinical trial on 24 patients divided into 2 groups: Group A: 12 patients indicated for dental implant placement in upper anterior and premolar region received submerged dental implants with application of 1% sodium alendronate gel. Group B: 12 patients indicated for dental implant placement in upper anterior and premolar region received submerged dental implants without 1% sodium alendronate gel. Patient selection was done from the outpatient clinic of the Oral and Maxillofacial Department, Faculty of Dentistry, Alexandria University. All procedures were done in accordance with Ethic research committee, Faculty of Dentistry, Alexandria University and in accordance with the 1964 Declaration of Helsinki. All patients were informed about the aim of the designed study and a written consent was obtained.

The inclusion criteria for patient selection were: missed anterior or premolar maxillary teeth, age ranging from 20-40 years, adequate bone quality and quantity, good oral hygiene, non-smokers, adequate zone of keratinized gingiva.

The exclusion criteria for patient selection were: presence of local infection, inadequate interocclusal space, bruxism or clenching, current chemotherapy or radiotherapy, alcohol or drug abuse, systemic diseases.

An informed consent was taken from all patients after explaining all the procedures to the patients including all the benefits and side effects in a simple and easy way, also the patients had the right for withdrawal at any time.

Materials:

Implants: Dentis system implants (Dentis s-clean tapered system, Woram-Dong, Dalseo-Gu, Daegu, Korea) with different diameters (3.4, 4.1 and 4.8 mm) and lengths (8, 10, 12 and 14 mm) were used in this study

Osstell ISQ “resonance frequency analyzer”: was used for measurement of implant stability. Osstell ISQ (Osstell AB, stampgatan, Goteborg, Sweden) consists of Osstell ISQ instrument, probe, charger, USB cable and test peg. The system includes the use of a SmartPeg™ attached to the dental implant by means of an integrated screw. The SmartPeg is excited by a magnetic pulse from the measurement probe on the handheld instrument. The resonance frequency, which is the measure of implant stability, is calculated from the response signal.

Results are displayed on the instrument as the implant Stability Quotient (ISQ), which is scaled from 1 to 100. The higher the value, the more stable the implant. SmartPeg Type 11 and type 22 were used.

Bisphosphonate “sodium alendronate” gel 1% (by volume)

1% Sodium alendronate gel “ALN Gel” was prepared as described by Reddy et al (12). Briefly, ALN obtained from FOSAMAX® (by Merck Sharp & Dohme Corp., a subsidiary of Merck & Co., Inc, USA) tablets was dissolved in a required amount of distilled water to achieve a concentration of 1% ALN. A weighed quantity of polyacrylic acid (PAA) (2% weight/weight) was added to the distilled water. The mixture was stirred gradually, and PAA was allowed to soak for 2 hours. One-percent triethanolamine was added to neutralize the PAA solution and to form the gel. The pH was adjusted to 6.8. Finally, the required amount of methyl paraben (0.1%) and propyl

paraben (0.05%) were dissolved in ethanol and added to the gel (12).

Methodology

I. Preoperative phase:

All patients went through preoperative phase including clinical examination of recipient site to ensure absence of infection or any signs of inflammation, radiographic examination of recipient site to be implanted by CBCT and primary impression and fabrication of study model and surgical stent (Figure 1).

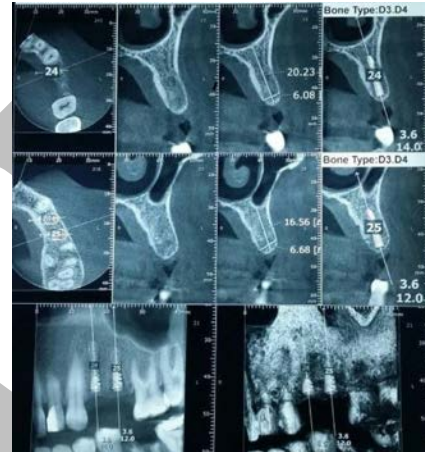


Figure (1): Preoperative CBCT with imaginary implant placement.

II. Operative phase:

Included using of chlorohexidine mouth wash (Hexitol Chlorhexidine HCl 1.25%, by adco company ltd, Alexandria, Egypt) for thirty seconds before operation. Nerve block and infiltration anesthesia using Mepeccaine hydrochloride 2% (Alexandria pharmaceutical company, Alexandria, Egypt). Surgical exposure of the maxillary crest by a trapezoidal flap was performed (Figure 2a). Drilling was made through the maxilla, the sequence of the drilling was carried out according to manufacturer’s instructions (Figure 2b). Implants were screwed directly into the osteotomy site, primarily the screwing was done mechanically by Fixture Mount Connection attached to the implant carrier (Figure 2c).

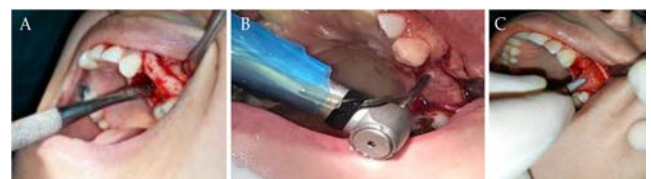

Figure 2: (A) Crestal incision with buccal reflection. (B) Drilling of the osteotomy site. (C) Placement of implant into osteotomy site.

In the test group patients 1% sodium alendronate gel was applied locally to the surface of the implant just before placement into osteotomy site.

Implant stability was measured using OsstellTM resonance frequency analyzer (RFA) using the SmartPeg (Figure 3). Suturing the wound using 3-0 black silk was then performed.

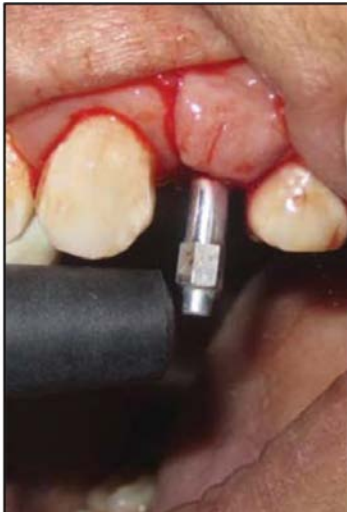

Figure 3: Measuring primary stability using Osstell™ resonance frequency analyzer (RFA).

III. Post-operative phase:

Postoperative instructions included: cold fomentation on the first day, warm saline mouth washes for the next seven days, oral hygiene instructions. Postoperative medication Antibiotic: Amoxicillin 875+clavulanic acid 125 was given 5 days 1 gram every 12 hours (Augmentin® 1 g Tablets by Galaxosmithkline co ltd, USA). Diclofenac potassium 50 mg was given every 8 hours for 5 days (Cataflam® tablets, by Novartis Pharmaceuticals Corporation). Chlorhexidine HCl 1.25% mouthwash was given twice daily for one week after the first day (Hexitol by adco company ltd, Alexandria, Egypt). Sutures were removed one week after surgery.

IV. Assessment phase:

- 1. Clinical Evaluation:** all Patients were evaluated clinically for pain and edema after the first week and for presence of infection every month for the following 3 months. Peri-implant probing depth was done after 3 months. Implant stability measured by Osstell™ immediately and after 3 months and the results were compared.

Pain was evaluated through “visual analogue scale” (13) as follows: 0 = no pain, 1 = mild pain: it is easily tolerated, 2 = moderate pain: it is causing discomfort but bearable, 3 = severe pain: it is causing discomfort, hardly tolerated and unbearable. Edema was evaluated by its ability to pit (14). The pitting is graded on a scale of +1 to +4 as follows: +1 (trace) slight indentation rapid return to normal, +2 (mild) the indentation returns to normal in few seconds, +3 (moderate) 6 mm indentation rebounds in 10-20 second, +4 (severe) 8 mm indentation rebounds after more than 30 second.

Periodontal follow up was designed to determine whether the soft tissue at teeth and implant region is normal or reflects any sign to inflammation (15,16).

Implant stability was measured immediately after placement and 3 months after surgery was assessed by Osstell™ resonance frequency analyzer (RFA) using the smart peg.

- 2. Radiographic evaluation:** was done using cone beam computed tomography (CBCT) software “On Demand 3D App” immediately and after 3 months of implant placement to evaluate bone density and osseointegration around the implant (Figure 4).

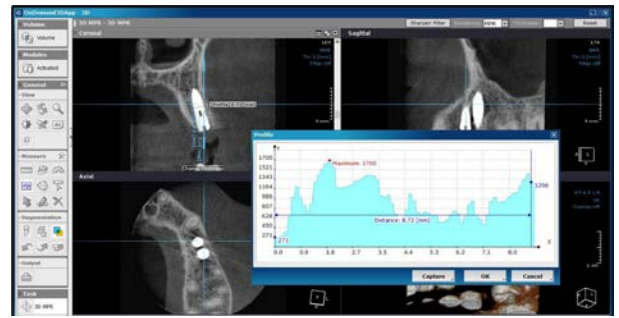


Figure 4: Measuring bone density “On Demand 3D Application”.

Finally, after 3 months, loading of abutment and final prosthesis was done using porcelain fused to metal crowns.

Statistical Analysis of the data

Data was fed to the computer and analyzed using International Business Machines Statistical Package for the Social Sciences (IBM SPSS) software package version 20.0. (Armonk, NY: IBM Corp) Qualitative data were described using number and percent. Quantitative data were described using range (minimum and maximum), mean, median and standard deviation.

The used tests were:

- 1-Mann Whitney test.
- 2-Student t-test.
- 3-Paired t-test.

RESULTS

Patients selected from the outpatient clinic of the Oral and Maxillofacial Surgery Department, Faculty of Dentistry, Alexandria University. Each had a missing maxillary anterior (14 cases) or premolar (10 cases) tooth that has been extracted for more than 6 months and indicated for implant placement. Their ages ranged between 20 and 40 years with mean age of 32.5 years, patients were selected free from systemic diseases because that may complicate the surgical procedure or the healing process of the implant procedure. All patients had undergone surgical procedures for delayed implant placement and loading. The Dentis system implants with different diameters (3.4, 4.1 and 4.8 mm) and lengths (8, 10, 12 and 14 mm) were used in this study.

All patients were followed up both clinically and radiographically for 3 months.

All patients have been operated under local anesthesia using surgical flap technique and implant placement, and no complications have been recorded during the operation. All patients have been examined periodically during the follow-up period up to 3 months. Healing was normal in all cases with no post-operative complications.

- 1. Clinical Evaluation:** parameters have been recorded such as: pain, edema, presence of infection, probing depth and implant stability.

- 1. Pain, edema and infection after surgery;** all patients experienced slight to mild pain at the surgical site which subsided by the 7th day post-operative. All patients experienced slight to mild edema on the 2nd post-operative day subsided by the 4th day post-operative. All patients continued the follow up period without any signs of infection, gingivitis, or peri-implantitis.
- 2. Peri implant probing depth;** on the third month, the mean probing depth for Control group was 2.10 ± 0.27 mm with a minimum recorded value of 1.75 mm and a maximum

recorded value of 2.50. On the third month, the mean probing depth for test group was 2.13 ± 0.29 mm with a minimum recorded value of 1.75 mm and a maximum recorded value of 2.50 mm.

3. Implant stability evaluation; the measurements revealed very good stability in all implants. At day 0 the range of the readings were between (48.0 – 63.0) and between (48.0 – 65.0) for the Control group and Test group, respectively. The median records were (55.50, 54.0) and the Mean \pm SD (55.08 ± 4.94 , 54.67 ± 5.69) for the control group and test group, respectively. (Table 1, Figure 5)

Table (1): Comparison between the two studied groups according to implant stability.

Implant stability	Control (n = 12)	Test (n = 12)	T	p
Immediately				
Min. – Max.	48.0 – 63.0	48.0 – 65.0		
Mean \pm SD.	55.08 ± 4.94	54.67 ± 5.69	0.191	0.850
Median	55.50	54.0		
After 3 months				
Min. – Max.	52.0 – 68.1	53.0 – 74.0		
Mean \pm SD.	60.17 ± 4.97	61.33 ± 6.21	0.508	0.617
Median	60.50	61.50		

t: Student t-test

p: p value for comparing between the two studied groups

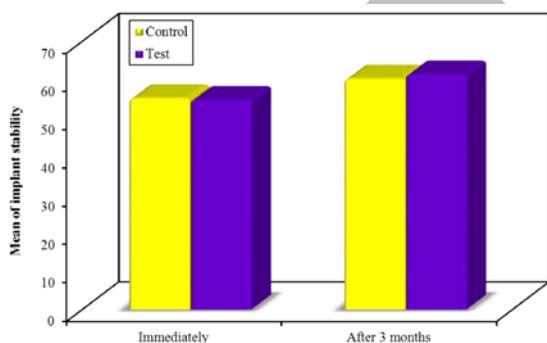


Figure 5: Comparison between the two studied groups according to implant stability

The bisphosphonate-coated implants showed an increase in resonance frequency analyzer RFA value from 0 to 12 weeks more than the control's measures (The difference in the median was about 1 unit. As the median for the RFA measures was (61.50) for the Bisphosphonate coated titanium implant and (60.50) for the control group.

After twelve weeks, the measurements were taken for all the implants in both groups again. All implants showed increase in RFA value ranging between (52.0 – 68.1) for the control group and between (53.0 – 74.0) for the test group.

As shown in (Table 1) all Bisphosphonate coated titanium implants showed a high stability revealed by higher increase in RFA value at all measurements time points than their paired controls. There was no statistical difference.

II. Radiographic evaluation was done immediately and after 3 months of implant placement to evaluate bone density. On the first week, the mean peri-implant bone density value was 1240.67 ± 341.20 HU for control group and 1256.17 ± 325.51 HU for test group. On 12 weeks, the mean peri-implant bone density value was 1417.92 ± 310.54 HU for control group and 1550.25 ± 286.15 HU for test group.

These increases in the bone density for the all implants were clear after 3 months also it was higher in bisphosphonate coated implants than the control group, and this is a very clear radiographic indicator for the response of the process of mineralization and remodeling of the maxillary bone to the Bisphosphonate. (Table 2, Figure 6)

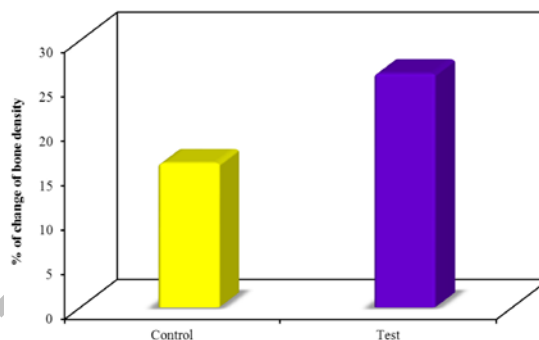


Figure 6 : Comparison between the two studied groups according to % change of bone density

Table (2): Comparison between the two studied groups according to bone density

Bone density	Control (n = 12)	Test (n = 12)	Test of sig.	p
Immediately				
Min. – Max.	714.0 – 1756.0	780.0 – 1740.0		
Mean \pm SD.	1240.67 ± 341.20	1256.17 ± 325.51	t= 0.114	0.910
Median	1215.0	1237.0		
After 3 months				
Min. – Max.	923.0 – 1920.0	1018.0 – 1992.0		
Mean \pm SD.	1417.92 ± 310.54	1550.25 ± 286.15	t= 1.086	0.289
Median	1358.0	1488.50		
% of change				
Min. – Max.	7.52 – 32.88	13.12 – 67.28		
Mean \pm SD.	16.20 ± 8.54	26.27 ± 15.97	U= 38.0	0.052
Median	12.53	21.10		

t: Student t-test

U: Mann Whitney test

p: p value for comparing between the two studied groups

DISCUSSION

Patients were selected from the outpatient clinic of the Oral and Maxillofacial Surgery Department, Faculty of Dentistry, Alexandria University. Each had a missing maxillary anterior or premolar tooth that has been extracted from more than 6 months and indicated for implant placement. Their ages ranged between 20 and 40 years with mean age of 32.5 years.

Regarding the mean peri-implant probing depth in the present study in both control and test group there wasn't any increase throughout the evaluation period, which indicates periodontally successful implants. That was in agreement with Pranskunas et al (17) in 2016, who concluded that the width of keratinized mucosa around dental implants was related with less mucosal inflammation, less plaque accumulation, increased stability of the peri-implant area, and prevention of mucosal recession.

In our study regarding implant primary stability, each implant was assessed by osstell device. The bisphosphonate-coated implants showed an increase in RFA value at 0 week and 12 weeks more than the control's measures (The difference in the median was about 1 unit). As the median for the RFA measures was (61.50) for the Bisphosphonate coated titanium implant and (60.50) for the control group.

As shown in all Bisphosphonate coated titanium implants showed a high stability revealed by higher increase in RFA value at all measurements time points than their paired controls. However, the increase was statistically insignificant ($p \geq 0.05$) this may be due to small sample size and short period of follow up.

Abtahi et al (5) in 2010, found similar results as they evaluated the clinical stability of bisphosphonate-coated dental implants. The level of the marginal bone around each implant was measured by intraoral periapical radiographs and implant stability was recorded using resonance frequency measurements. Resonance frequency values (RFA) were obtained pre-operatively before flap closure and after six months at abutment connection.

Furthermore, in agreement with our results Abtahi et al (6) in 2012, research showed that a drug released from the implant surface can improve parameters reflecting the quality or amount of this bone.

Kajiwara et al (18) in 2005, did several experimental studies with small laboratory animals investigating improvements in mechanical fixation of screw-shaped implants by coating the surface with bisphosphonates and their results are in line with our findings.

Regarding the bone density values immediately and after 3 months. The increase in peri-implant bone density starting from the first month to the end of the 3 months of the evaluation period indicates osseointegration of all implants. That was in agreement with Albrektsson et al. (19) in 1986 and Parithimarkalaignan and Padmanabhan (20) in 2013.

Hilding and Aspenberg (21) in 2006 outside the field of dentistry, found that bisphosphonate-coated screws for fixation of osteoporotic fractures, improved longevity of external fracture fixation, and better initial stability of joint replacements. It has been shown that bisphosphonate treatment can improve the early stability of total knee replacement in line with our results.

Meraw and Reev (22) and Meraw et al (23) in 1999, also in their research which was based on Qualitative analysis of peripheral peri-implant bone and influence of alendronate sodium on early bone regeneration found that; the local application of Bisphosphonate (alendronate) around dental implants in dog mandibles has shown increased bone density and bone formation and this was in agreement with our study. This method, however, does not directly immobilize the bisphosphonate onto the implants instead the implant is soaked in the solution.

These results are also supported by Stadelmann (24) in 2008, his study confirms that implants delivering bisphosphonate locally increase periprosthetic bone density in an osteoporotic sheep model.

A more recent study conducted by Kwak et al (25) in 2009, also supports our findings, they demonstrated that bisphosphonate incorporated on titanium implants increased bone density locally in the peri-implant region

with the effect of the antiresorptive drug limited to the vicinity of the implant.

On other hand, a study carried out by Denissen et al (26) in 2000, explored associating bisphosphonates with porous HA implants. The authors did not report any advantages or disadvantages associated with the locally delivered bisphosphonate.

Jakobsen et al (8) in 2009, also supports the results from this study. They found that the local Bisphosphonate (alendronate) treatment could increase the fixation of HA-coated implants inserted with bone compaction. They concluded, as initial implant stability is important for long-term implant survival, the combined effect of local bisphosphonate treatment and bone compaction might be beneficial for HA coated joint replacements.

Our results also are in line with those in a recent study by Toksvig-Larsen and Aspenberg (27) in 2013, as they compared bisphosphonate-coated pins with uncoated ones in the shaft, and with hydroxyapatite-coated pins in the metaphysis. In conclusion, the study suggests that bisphosphonate-coated external fixation pins can be used successfully in metaphyseal bone, where uncoated pins have a history of showing a very high rate of loosening.

Researchers have been striving to figure out the best way of administering bisphosphonate in particular focusing on systemic administration or local application of the bisphosphonate to implants.

Wermelin et al (28) in 2007, in their research which was conducted on rats found that, the Systemic administration is thought to be non-optimal, since bones are low-perfusion organs and drugs diluted in blood stream have low probabilities to reach the required locations with sufficient time or concentration to be effective. It is therefore suggested that to ensure the availability of bisphosphonate at the peri-implant area, where it is most needed, methods for local delivery maybe more beneficial

Mckenzie et al (29) in 2011 and Russell et al (30) in 2008 stated that locally released bisphosphonate from a coated implant will adhere to the nearest bone surface and stay there for a long time, with the bone surface acting as a store for repeated bisphosphonate release.

Therefore, it could be considered that the bisphosphonate coating lead to improvement of osseointegration and positive bone healing response around dental implant.

CONCLUSION

From the results of this study it was concluded that using sodium alendronate gel with delayed implant placement would enhance the osseointegration around dental implants.

CONFLICT OF INTEREST

The authors declare that they have no conflicts of interest.

REFERENCES

- 1-Ioannou AL, Kotsakis GA, McHale MG, Lareau DE, Hinrichs JE, Romanos GE. Soft tissue surgical procedures for optimizing anterior implant esthetics. *Int J Dent.* 2015;2015:1-9.
- 2-Brånemark P-I, Breine U, Adell R, Hansson B, Lindström J, Ohlsson Å. Intra-osseous anchorage of dental prostheses: I. Experimental studies. *Scand J Plast Reconstr Surg.* 1969;3:81-100.

- 3-Misch C, Wang H. Immediate occlusal loading for fixed prostheses in implant dentistry. *Dent Today*. 2003;22:50-6.
- 4-Mundy GR, Yoneda T. Bisphosphonates as anticancer drugs. *N Engl J Med*. 1998;339:398-400.
- 5-Abtahi J, Tengvall P, Aspenberg P. Bisphosphonate coating might improve fixation of dental implants in the maxilla: a pilot study. *Int J Oral Maxillofac Surg*. 2010;39:673-7.
- 6-Abtahi J, Tengvall P, Aspenberg P. A bisphosphonate-coating improves the fixation of metal implants in human bone. A randomized trial of dental implants. *Bone*. 2012;50:1148-51.
- 7-Cuairán C, Campbell PM, Kontogiorgos E, Taylor RW, Melo AC, Buschang PH. Local application of zoledronate enhances miniscrew implant stability in dogs. *Am J Orthod Dentofacial Orthop*. 2014;145:737-49.
- 8-Jakobsen T, Baas J, Kold S, Bechtold JE, Elmengaard B, Søballe K. Local bisphosphonate treatment increases fixation of hydroxyapatite-coated implants inserted with bone compaction. *J Orthop Res*. 2009;27:189-94.
- 9-Skoglund B, Holmertz J, Aspenberg P. Systemic and local ibandronate enhance screw fixation. *J Orthop Res*. 2004;22:1108-13.
- 10-Devogelaer J-P, Broll H, Correa-Rotter R, Cumming D, De Deuxchaisnes CN, Geusens P, et al. Oral alendronate induces progressive increases in bone mass of the spine, hip, and total body over 3 years in postmenopausal women with osteoporosis. *Bone*. 1996;18:141-50.
- 11-Tucci JR, Tonino RP, Emkey RD, Peverly CA, Kher U, Santora AC. Effect of three years of oral alendronate treatment in postmenopausal women with osteoporosis. *Am J Med*. 1996;101:488-501.
- 12-Reddy GT, Kumar TP, Veena K. Formulation and evaluation of alendronate sodium gel for the treatment of bone resorptive lesions in periodontitis. *Drug Deliv*. 2005;12:217-22.
- 13-McCormack HM, David JdL, Sheather S. Clinical applications of visual analogue scales: a critical review. *Psychol Med*. 1988;18:1007-19.
- 14-Kumar V, Abbas AK, Fausto N, Aster JC. Robbins and Cotran pathologic basis of disease, professional edition e-book. 9th ed. Elsevier Health Sciences; 2014.
- 15-Mombelli A, Lang NP. Clinical parameters for the evaluation of dental implants. *Periodontol* 2000. 1994;4:81-6.
- 16-Porter JA, von Fraunhofer JA. Success or failure of dental implants? A literature review with treatment considerations. *Gen Dent*. 2005;53:423-33.
- 17-Pranskunas M, Poskevicius L, Juodzbaly G, Kubilius R, Jimbo R. Influence of peri-implant soft tissue condition and plaque accumulation on peri-implantitis: a systematic review. *J Oral Maxillofac Res*. 2016;7:1-9.
- 18-Kajiwara H, Yamaza T, Yoshinari M, Goto T, Iyama S, Atsuta I, et al. The bisphosphonate pamidronate on the surface of titanium stimulates bone formation around tibial implants in rats. *Biomaterials*. 2005;26:581-7.
- 19-Albrektsson T, Jansson T, Lekholm U. Osseointegrated dental implants. *Dent Clin North Am*. 1986;30:151-74.
- 20-Parithimarkalaignan S, Padmanabhan TV. Osseointegration: An Update. *J Indian Prosthodont Soc*. 2013;13:2-6.
- 21-Hilding M, Aspenberg P. Postoperative clodronate decreases prosthetic migration: 4-year follow-up of a randomized radiostereometric study of 50 total knee patients. *Acta Orthop*. 2006;77:912-6.
- 22-Meraw SJ, Reeve CM. Qualitative analysis of peripheral peri-implant bone and influence of alendronate sodium on early bone regeneration. *J Periodontol*. 1999;70:1228-33.
- 23-Meraw SJ, Reeve CM, Wollan PC. Use of alendronate in peri-implant defect regeneration. *J Periodontol*. 1999;70:151-8.
- 24-Stadelmann VA, Terrier A, Gauthier O, Bouler J-M, Pioletti DP. Implants delivering bisphosphonate locally increase periprosthetic bone density in an osteoporotic sheep model. A pilot study. *Eur Cell Mater*. 2008;16:10-6.
- 25-Kwak HB, Kim JY, Kim KJ, Choi M-K, Kim J-J, Kim KM, et al. Risedronate directly inhibits osteoclast differentiation and inflammatory bone loss. *Biol Pharm Bull*. 2009;32:1193-8.
- 26-Denissen H, Montanari C, Martinetti R, van Lingen A, van den Hooff A. Alveolar bone response to submerged bisphosphonate-complexed hydroxyapatite implants. *J Periodontol*. 2000;71:279-86.
- 27-Toksvig-Larsen S, Aspenberg P. Bisphosphonate-coated external fixation pins appear similar to hydroxyapatite-coated pins in the tibial metaphysis and to uncoated pins in the shaft: a randomized trial. *Acta Orthop*. 2013;84:314-8.
- 28-Wermelin K, Tengvall P, Aspenberg P. Surface-bound bisphosphonates enhance screw fixation in rats—increasing effect up to 8 weeks after insertion. *Acta Orthop*. 2007;78:385-92.
- 29-McKenzie K, Bobyn JD, Roberts J, Karabasz D, Tanzer M. Bisphosphonate remains highly localized after elution from porous implants. *Clin Orthop Relat Res*. 2011;469:514-22.
- 30-Russell R, Watts N, Ebetino F, Rogers M. Mechanisms of action of bisphosphonates: similarities and differences and their potential influence on clinical efficacy. *Osteoporos Int*. 2008;19:733-59.