

EVALUATION OF BASAL DENTAL IMPLANTS IN EDENTULOUS POSTERIOR MAXILLARY REGION

Ayman E. Gaber^{1*} BDS, Riham M. Eldibany² PhD, Gaafar N. El-Halawani³ PhD

ABSTRACT

INTRODUCTION: Tooth replacement with dental implants has proven to be a reliable and effective means of restoring the dentition. The use of implant can conserve sound tooth by reducing the need to prepare adjacent teeth as abutment. Owing to mechanical and anatomic difficulties, implant treatment in the posterior maxilla represents a challenge due to several factors such as: type of bone, bone density and pneumatization of maxillary sinus.

OBJECTIVES: to evaluate the delayed placement of basal dental implants in the posterior maxillary region.

MATERIALS AND METHODS: The research conducted on 14 patients with missing maxillary posterior teeth. Panoramic x-ray together with Cone Beam Computed Tomography (CBCT) were done preoperatively before placement of the basal dental implants. Stability of the implants were measured by periostest immediately, 1 month postoperatively and 3 months postoperatively and CBCT were done immediately following implants insertion and after 3 months.

RESULTS: There was a statistically significant increase in the implant stability readings using periostest at one month and 3 months postoperatively and The mean bone density showed a statistically significant difference between immediate postoperative and at 3 month

CONCLUSIONS: The use of Basal dental implants in atrophic posterior maxilla provides clinicians with a more conservative option of the treatment and help to minimize treatment duration, cost and trauma.

KEYWORDS: Dental implants, stability, maxillary posterior region, basal implants.

1- B.D.S Faculty of Dentistry, Alexandria University

2- Professor of Oral and Maxillofacial Surgery, Faculty of Dentistry, Alexandria University

3- Lecturer of Oral and Maxillofacial Surgery, Faculty of Dentistry, Alexandria University

*Corresponding author:

E-mail: fefonow@gmail.com

INTRODUCTION

The posterior maxilla has been known as the most difficult and problematic intraoral area for implant dentistry, requiring a maximum of attention for the achievement of successful surgery. Dental implant placement in the missing maxillary posterior teeth region can present difficulties because of horizontal or vertical alveolar ridge deficiency, unfavorable bone quality, or increased pneumatization of the maxillary sinus (1).

Bone quality is defined by several micro-morphometric parameters and also by clinical assessment. Misch (2) proposed a classification based on the location, composition, and measurable density reading by Computed Tomography (CT). According to this classification, the posterior maxilla is composed of D3-D4 bone due to the porous thin layer of cortical bone and fine trabecular bone underneath the cortical bone.

To overcome problems associated with low bone density, several factors can produce adequate osseointegration; biomaterials for dental implants, surface composition and structure and implant design (3).

One of the key factors is the implant design, since it determines primary stability and stress distribution during osseointegration. The geometric features of an implant influences sufficient initial contact to facilitate primary stability of the implant. It also plays an important role in implant capacity to withstand forces during the process of Osseo integration. Therefore, the optimal implant design itself can improve the potential osseointegration process and the primary and secondary stability of the implant (3).

Implant design features such as macro- and micro-design may influence the overall implant success. Macro-

design includes the threads, body shape and thread design e.g., thread geometry, face angle, thread pitch, thread depth (height), thickness (width) or thread helix angle. These macroscopic geometric characteristics have helped to distribute applied forces along the implant-tissue interphases (4, 5).

On the other hand, Micro-design constitutes implant materials, surface morphology and surface coating. Surface treatment can be classified into mechanical, chemical, and physical methods. In dental implants, the surface treatments such as sand blasting, acid etching, plasma etching, plasma spray deposition, sputtering deposition and cathodic arc deposition, are used to modify the surface topography and surface energy, resulting in an improved wettability (6,7), increased cell proliferation and growth, and accelerated osseointegration process (8).

There is a new design for Basal Dental Implants, which consists of single-component implants used for multiple unit restorations. They can be placed in extraction sockets and also in healed bone. The structural characteristics allow placement in the bone that is deficient in height and width. They can be placed with flap or flapless technique. Most of these implants take support from the basal bone which is a lot more resistant to resorption. The long polished surface protects from accumulation of bacteria at the cervical part of the implant (9).

Although this new design of basal dental implants has been in the market for the last few years, yet no scientific researchers are available on their use. Therefore, this study was conducted to evaluate their placement in the posterior maxillary region.

MATERIALS AND METHODS

This was a prospective clinical trial. It was conducted on 7 patients with missing maxillary posterior teeth indicated for implant placement using 14 Basal Dental Implants.

Patients were selected from the Outpatient Clinic of the Oral and Maxillofacial Surgery Department, Faculty of Dentistry, Alexandria University. The appropriate ethical clearance was obtained from the ethics committee of the university and that an informed consent was signed by all participants.

Inclusion criteria

Patients of both genders, with age ranging between 20-55 years, patients with missing maxillary posterior teeth, good oral hygiene, adequate vertical dimension and vertical bone height between the crestal bone and the maxillary sinus floor > 8 mm.

Exclusion criteria

Medically compromised patients who are contraindicated to implant placement e.g., uncontrolled diabetes mellitus, current chemotherapy or radiotherapy, parafunctional habits (e.g.) bruxism, clenching, mouth breathing, heavy smokers and alcohol or drug abuse.

Materials

In this study, basal dental Implants (TRATE AG, Seestrasse 58 8806 Bäch, Switzerland) with different lengths (8, and 12), Implant Surgical Kit (ROOTT surgical Kit, Switzerland), Physiodespenser (Marathon Ki - 20 Implant Motor Set, Saeyang Microtech Co., Ltd), Expander Kit (Microdent expanders) and Periotest (Medizintechnik Gulden e. K. . . Eschenweg 3. 64397 Modautal/Germany) were used. Fig. (1, 2)

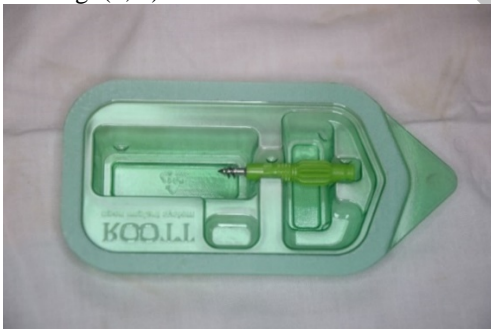

Figure (1): Basal dental implant.

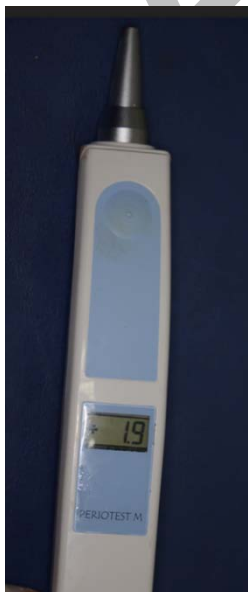

Figure (2): Periotest M

Methods

A- Pre-operative phase

All patients underwent pre-operative clinical examination: Patients' data were collected; name, gender and age, medical and dental histories were taken and the oral mucosa of the edentulous was examined for the color, texture, firmness and thickness.

Also all patients underwent preoperative panoramic radiographic examination to ensure that the selected site is free from any local pathological radiolucent or radiopaque shadow in the edentulous area and to evaluate the suitability of the patient regarding vertical bone height and pneumatization of the maxillary sinus. Also, Cone Beam computed Tomography (CBCT) x-rays were done to measure bone height and width, bone density and to determine the implant size. (Fig 3)

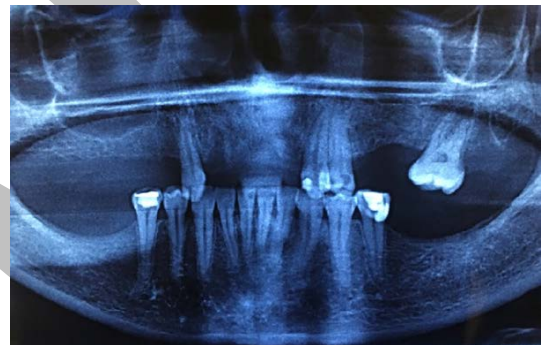


Figure (3): A photograph of a preoperative panoramic radiograph showing missing maxillary left second premolar and first molar teeth.

B- Operative phase

- All patients were operated under infiltration Local Anaesthesia (Mepecain-L, mepivacaine HCL 2% 1.8ml carpule with levonordefrin 1:20000) sub periosteal buccal and palatal infiltration at the site of operation and instructed to rinse their mouth using antiseptic mouth wash solution (Hexitol: Arabic Drug Company, Egypt) for 2 min.
- A full thickness pyramidal flap was performed using number 15 scalpel blade. (Fig 4)
- An osteotomy was done using the pilot drill for socket preparation then sequential drilling according to the manufacturer's instructions under copious irrigation.
- Expanders were used in some cases where the bone density is poor in order to achieve reasonable primary stability.
- Implants placement was done with hand pressure using the plastic cap and then using the ratchet wrench.
- Primary stability of the implant was tested using The Periotest and the readings were collected.
- The flap was repositioned and closed by interrupted suture using 3-0 silk sutures.

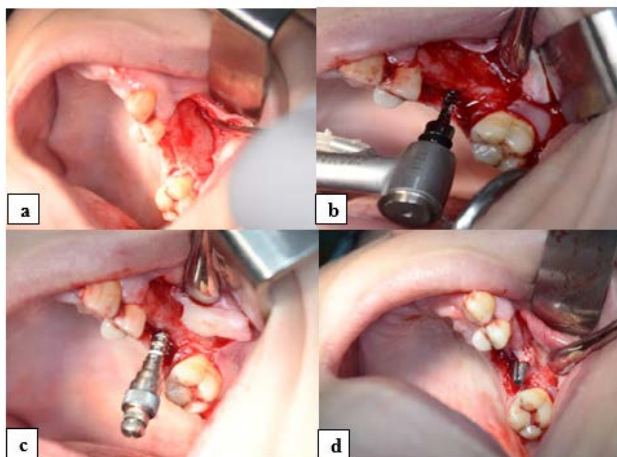


Figure (4): A photograph showing implant placement surgical procedures. (a) Mucoperiosteal flap reflection. (b) Osteotomy of the 1st molar site using the pilot drill. (c) Expanding the osteotomy site using expander n°3 PN-2938. (d) The implant after insertion.

C- Post-operative phase:

- The patients were instructed to apply cold fomentations intermittently and not to rinse or to drink hot drinks for 24 hours, start warm mouth wash the next day using antiseptic mouth wash, take postoperative oral antibiotics (Amoxicillin 875 mg + Clavulanic acid 125 mg 1 gm) every 12 hours for 5 days and non-steroidal anti-inflammatory analgesics (Diclofenac potassium 50 mg) every 8 hours for 5 days.
- Suture removal was done at 7-10 days postoperatively and the provisional acrylic restoration was delivered.

D- Follow-up phase

- All patients were evaluated for pain and Post-operative complications daily for the first week then weekly for the first month.
- All patients were evaluated immediately, 1 month postoperatively and 3 months later for implant stability using periotest.
- All patients were evaluated after 1 month and 3 months for probing depth and gingival index.
- Postoperative radiographic evaluation was done for Assessment of Bone density around implants immediately and after 3 months, using the grey scale of Galileos CBCT from each side of implant (mesial, distal, apical) the mean was calculated immediately postoperative as the base line and after 3 months, then converted to Hounsfield unit (HU). (Fig 5)
- Final prosthesis (porcelain fused to metal crowns) was delivered after 3 months. Fig (6)

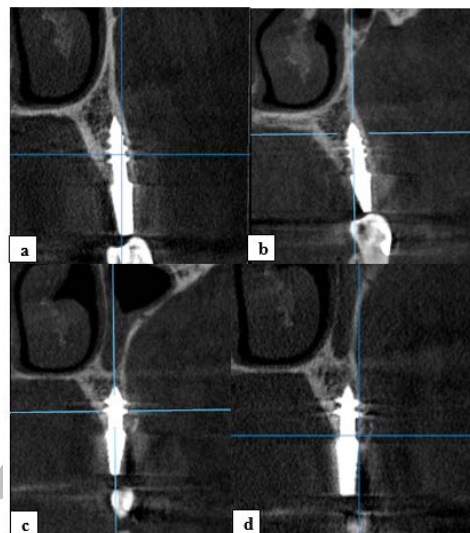

Figure (5): CBCT image of implant taken (a,b) photographs of postoperative CBCT showing implants in the first and second maxillary premolar sites immediately postoperative (c,d) photographs of postoperative CBCT showing implants in the first and second maxillary premolars sites after 3 months.

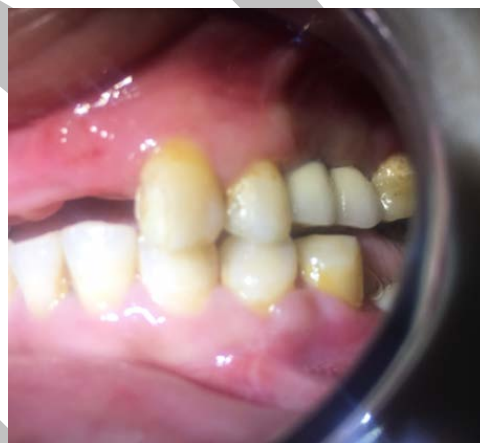

Figure (6): A photograph showing final restorations that were performed after 3 months.

Statistical Analysis

Statistical Package of Social Sciences (version 24.0; SPSS, Chicago, IL) was used to analyze the data. Descriptive statistics were done for quantitative data as minimum & maximum of the range as well as mean \pm SD (standard deviation) for quantitative parametric data.

The level of significance was taken at P value $<$ 0.05 is highly statistically significant, otherwise is non-significant. The p-value is a statistical measure for the probability that the results observed in a study could have occurred by chance.

RESULTS

The present study included seven patients of both sexes (5 females and 2 males). Their ages ranged between (20-55) years. They were selected from the Outpatient Clinic of the Oral and Maxillofacial Surgery Department, Faculty of Dentistry, Alexandria University.

All patients had missing maxillary posterior teeth with limited bone height below the maxillary sinus. Fourteen implants were placed and followed up both clinically and radiographically for 3 months.

In this study, from 14 implants placed in seven patients, three implants failed and this may be due to that there is no surface treatment for the implants, short and small diameter of the implants and the bad bone quality of the upper posterior region.

1)Pain, tenderness, infection or swelling

There was pain and tenderness on the first postsurgical days during the follow up period. According to Visual Analogue Scale (VAS), pain scores ranged between score 2 (which is mild annoying pain) occurred in 4 patients and score 4 (which is nagging, uncomfortable pain) occurred in 3 patients.

Healing was uneventful in all cases with very minimal and unobserved Post-operative edema and discomfort in 5 patients and moderate swelling and edema in 2 patients and healed spontaneously by prescribed postoperative medication and instructions.

2)Implant stability evaluation

The implant stability measurement was examined at the time of insertion, one month and 3 months postoperatively using Periotest M. (Table 1, Fig 7)

Table (1): Implant stability throughout the follow up period

	Immediate	After 1 st month	After 3 rd months
Range	4.5 to -1.3	2.4 to -2.0	3.2 to -2.6
Mean	0.97	-0.2	-0.83
S.D.	1.68	1.45	2.03
ANOVA	8.22		
p	0.0031*		
P1		0.002*	0.001*
P2			0.036*

P1 comparison between immediately and both after 1 and 3 months

P2 comparison between after 1 and 3 months.

* P is significant

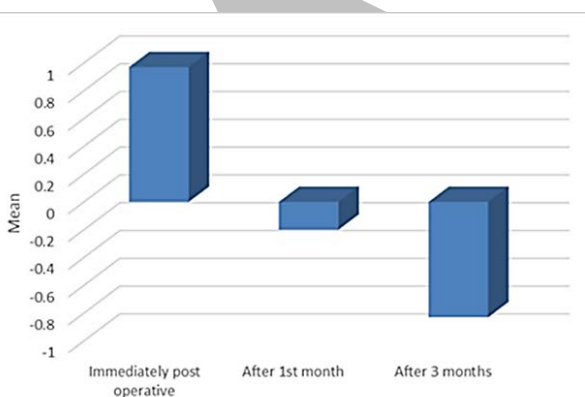


Figure (7): Implant stability throughout the follow up period.

Immediate postoperative: The mean implant stability was $+0.97 \pm 1.68$.

At 1 month: The mean implant stability was -0.2 ± 1.45 .

At 3 months: The mean implant stability was -0.83 ± 2.03 .

The implant stability showed a statistically significant difference at 1 and 3month postoperatively when compared with immediately measures.

3)Gingival index

There was no statistically significant difference between the 1st and 3rd months postoperatively regarding the mean gingival index (p 0.81).

4)Probing Depth

The probing depth showed no statistically significant difference between the 1st and 3rd months (p=0.154).

5)Radiographic evaluation

a) Changes in the marginal bone height: The bone level changes were measured by the software of the Galileos CBCT*. The mean of the bone height around the basal dental implants immediately post-operative increased from 7.3mm to 7.7mm after 3 months. The marginal bone height showed no statistically significant difference between the 1st and 3rd months (p=0.422).

b) Assessment of bone density: Bone density was measured using Galileos CBCT software immediate postoperatively and at 3 months. The bone density was measured at 6 points placed mesially, distally and apically to the implant and the mean was calculated.

The mean bone density was 367.35 ± 103.77 HU and 550.41 ± 104.23 HU at immediately postoperative and 3 months. The mean bone density showed a statistically significant difference between immediate postoperative and at 3month (p<0.0001). (Table 2, Fig 8)

Table (2): Bone density throughout the follow up period.

	Immediate	After 3 months
Range	231.65-540.33	395.02-693.54
Mean	367.35	550.41
S.D.	103.77	104.23
t-test	6.98	
p	0.0001**	

* P is significant.

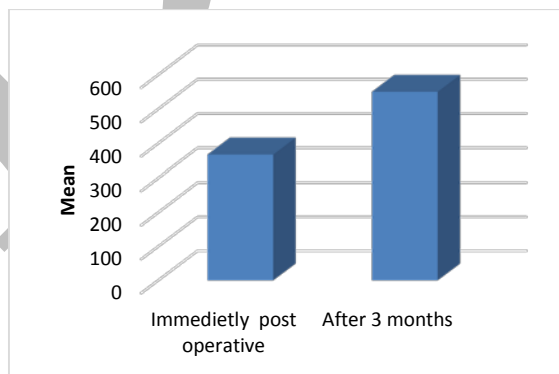


Figure (8): Bone density throughout the follow up period.

DISCUSSION

Bone resorption and pneumatization of the maxillary sinus, following tooth extraction, are common in the posterior maxilla. They may cause both a quantitative reduction and a qualitative deterioration of bone that leads to inadequate bone dimension for proper size/length implant placement. (10)

The present study was designed to evaluate clinically and radiographically the delayed placement of Basal Dental Implants in the posterior maxillary region.

In this study, from 14 implants placed in seven patients, three implants failed and this may be due to that there is no surface treatment for the implants, short and small diameter of the implants and the bad bone quality of the upper posterior region.

All the implants placed during the study had no surface treatment. The surface treatment of the implant placed in the

posterior maxilla had a role in the increase of the periosteal M value in the present study during the healing period. The surface treatment proved to increase the bone deposition around the dental implants (11, 12).

In 2007, Glauser et al (11) reported that implant design and surface treatment have a significant influence on soft bone.

Also, in 2010, Kim et al (12) mentioned that surface treatment may have significant effects on biological stability 3 weeks after implant placement.

By corroborating the aforementioned findings, in the year 2006, Misch (13) assured that the treated surfaces presented a large area in contact with bone. Consequently, they lead to less stress at bone/implant junction, displaying higher success rates.

In this study, the minimal residual bone height was 9 mm. In 2009, Rios et al. (14) reviewed the influence of the remaining alveolar bone upon implant survival and they concluded that a higher implant survival predictability as available residual bone increases.

Also, in 2012, Pommer et al (15) stated that the minimum requirements to allow implant placement are bone that is at least 10 mm in height and 3 mm to 4 mm in diameter.

In 2007, Barboza et al (16) assessed the clinical performance of short implants (220, 9.0 mm length; 128, 10 mm length; diameter of 3.5, 4.0, or 5.0 mm), during 6 years. It was installed 348 implants into 153 subjects. In 19 cases, early installation of implants was performed. All implants were prosthetically rehabilitated with single or multiple prosthesis. Success rate reached 96% (334 implants). Five losses occurred due to early spontaneous exposure; four due to peri-implantitis; three due to early load; and two due to lack of Osseo integration. The results obtained by the authors proved that short implants can be used, safely, for supporting prosthesis in the rehabilitation of lost teeth, displaying success and longevity rates similar to long implants.

In this study we used small diameter implants and accordingly in 2000, Winkler et al (17) mentioned that implants with wider diameter seemed to achieve better results than standard ones of corresponding lengths.

In several studies, there are significant findings of increased failure with smaller diameter implants either the comparison being between 3.3 versus 4.0 mm. (18)

In the present study, the implant stability was measured using the Periotest M. The Periotest device has the advantage of measuring the implant stability at any stages from implant placement to crown elaboration and even many years after the crown cementation. Most of the studies determined the reliability of Periotest on implant stability with measurements taken at the gingiva former stage only. (19)

In 2001, German and Lucas (20) conducted a study comparing the measurements of the Periotest at the 3 stages of the crown elaboration (gingiva former, abutment placement, crown cementation) using 2 different types of abutments. They found a main value increase of 3.5 between measurements taken at the gingiva former stage and at the final single crown cementation.

In this study, the mean implant stability immediately postoperative was (+0.97) that value indicates a high primary stability and the mean implant stability after 3

months was (-0.83) which indicate that a statistically significant more stability was gained.

The high primary stability is attributed to the surgical technique and implant taper. During the surgical preparation of the osteotomy site, a reduced osteotomy diameter was achieved to increased primary stability. Placing the implant into a smaller diameter osteotomy produce compressive forces along the implant/tissue interface, which enhance the implant stability (21).

Insertion of implant into a standard parallel-sided osteotomy increased the primary stability of the implant. The idea behind this approach is to induce controlled compressive forces in the cortical bone layer as the implant is inserted; these forces would increase the primary stability of the implant.

This agreed with O'Sullivan et al (21) in 2004, who analyzed the mechanical performance and the primary and secondary stability characteristics of endosseous titanium implants and concluded that the primary stability is affected by the surgical technique and implant taper.

In another study in 2011, Yoon et al (22) studied the influence of bone quality and surgical technique on the implant stability quotient (ISQ) value and they concluded that both the bone quality and surgical technique have influence on the implant primary stability, and resonance frequency has appositive relation with the density of implant fixture-surrounding bone.

In our study, we also used expanders in some cases to increase the primary stability. This coincides with Markovic et al (23), where they reported that the bone-condensing technique can be recommended as an alternate surgical approach for implant site preparation in reduced bone density to achieve greater implant stability in the posterior maxilla.

Interestingly, in 2006 Kong et al (24) considered 0.8 mm as the optimal thread pitch (pitch is the distance from the center of the thread to the center of the next thread, measured parallel to the axis of a screw) for achieving primary stability and optimum stress production on cylindrical implants with V-shape threads. They found that a shorter or a longer pitch had unfavorable stress generation. Furthermore, they also indicated that stresses are more sensitive to thread pitch in cancellous bone than in cortical bone. In conclusion, thread pitch plays a greater role in protecting dental implant under axial load than under off-axial (e.g., bucco-lingual) load.

Regarding the gingival index, the texture and color of the gingiva are important discriminators between Gingival Index scores. However, around implants, these features depend on the normal appearance of the recipient tissues before implantation and may be influenced by the properties of the implant surface. Difficulties in recording mucosal inflammation have been reported by Chaytor (25). Nonkeratinized peri-implant mucosa appeared redder than keratinized tissue. Therefore, the original Gingival Index cannot be used directly on implants, and measurements from teeth and implants should be handled separately. Regarding the probing depth, the results were insignificant in our study. Recent studies state that in contrast to natural teeth, for which average periodontal probing depth (PD) has been reported, the physiologic depth of the peri-implant sulcus of successfully Osseo integrated implants has been a matter of debate. Increasing periodontal PD and loss of clinical attachment are pathognomonic for periodontal

diseases. Pocket probing is therefore an important diagnostic process for the assessment of periodontal status and for the evaluation of periodontal therapy. The extent of probe penetration is influenced by factors such as probing force and angulation, probe tip diameter, roughness of the implant or root surface, inflammatory state of the periodontium, and firmness of the marginal tissues. Furthermore, it has to be realized that PD measurements may be affected by compromised access. Data demonstrate that the periodontal probe often fails to locate the histologic level of the connective tissue attachment around teeth. (26, 27)

Cone beam computed tomography was used during the preoperative and postoperative radiographic evaluation. Bornstein et al. (28) in 2014, reported that the indications for CBCT use in implant dentistry vary from preoperative analysis regarding specific anatomic considerations, site development using grafts and treatment planning to postoperative evaluation.

Moreover, in 2013 Cassette et al (29) reported that the lower radiation dose and reduced costs of CBCT make this a useful substitute for computerized tomography (CT), and unlike CT, the gray density values of the CBCT images are relative, which are based on densitometry variation of gray scale.

In this study, the mean bone height around the basal dental implants immediately post-operative increased from 7.3 mm to 7.7 mm after 3 months. This agrees with the study of Nedir et al (30) in 2006, who studied the long-term stability of the peri-implant bone formation following implant placement into resorbed maxilla.

In the subsequent follow up periods of this study the bone density around the implant increased and this was due to the compression of bone produced by implant placement technique. In addition, the bone density increase around the implant immediately postoperative and at 3 months postoperative was statistically significant. That was explained by the healing of the bone around implants and Osseo integration of dental implants.

These results were in agreement with the results of Yunus (31) in 2011. In his study, 30 patients were evaluated using CT to determine the changes of jaw bone density around the dental implant after placement. The study concluded that Bone density around dental implant increased after placement. He also stated that the increased rate of bone density could be determined by the quality of jaw bone before implant placement.

CONCLUSION

The use of Basal dental implants in atrophic posterior maxilla provides clinicians with a more conservative treatment option and helps to minimize treatment duration, cost and trauma.

CONFLICT OF INTEREST

The authors declare that they have no conflicts of interest.

REFERENCES

- 1-Caudry S, Landzberg M. Lateral window sinus elevation technique: Managing Chal-lenges and complications. *J Can Dent Assoc.* 2013; 79: 101–102.
- 2-Misch CE. Bone classification, training keys to implant success. *Dent Today.* 1989; 8:39–44.
- 3-Sennerby L, Meredith N. Implant stability measurements using resonance frequency analysis: biological and biomechanical aspects and clinical implications. *Periodontol* 2000. 2008; 47:51–66.
- 4-Lemons JE. Biomaterials, biomechanics, tissue healing, and immediate function dental implants. *J Oral Implantol.* 2004; 5:318-24.
- 5-Kopp CD. Overdentures and Osseo integration: Case studies and treatment planning. *Dent Clin North Am.* 1990; 34:729-39.
- 6-Rosales-Leal JI, Rodríguez-Valverde MA, Mazzaglia G. Effect of roughness, wettability and morphology of engineered titanium surfaces on osteoblast-like cell adhesion. *Colloids Surf A Physicochem Eng Asp.* 2010; 365:222–9.
- 7-Ponsonnet L, Reybier K, Jaffrezic N. Relationship between surface properties (roughness, wettability) of titanium and titanium alloys and cell behaviour. *Mater Sci Eng C* 2003; 23:551–60.
- 8-Sollazzo V, Pezzetti F, Scarano A. Zirconium oxide coating improves implant osseointegration in vivo. *Dental Mater.* 2008; 24:357–61.
- 9-Yadav R S, Sangur R, Mahajan T, Rajanikant A V, Singh N, Singh R. An Alternative to Conventional Dental Implants: Basal Implants. *Rama Univ J Dent Sci,* 2015; 2:22-28.
- 10-Soardi CM, Spinato S, Zaffe D, Wang HL. Atrophic maxillary floor augmentation by mineralized human bone allograft in sinuses of different size: a histologic and histomorphometric analysis. *Clin Oral Implants Res.* 2011; 22:560-6.
- 11-Glauser R, Zembic A, Ruhstaller P, Windisch S. Five-year results of implants with an oxidized surface placed predominately in soft quality bone and subjected to immediate occlusal loading. *J Prosthet Dent* 2007; 97: 59-68.
- 12-Kim SJ, Kim MR, Rim JS, Chung SM, Shin SW. Comparison of implant stability after different implant surface treatments in dog bone. *J Appl Oral Sci* 2010; 18:415-20
- 13-Misch CE, Steingga J, Barboza E, Misch-Dietsh F, Cianciola LJ, Kazor C. Short dental implants in posterior oartial edentulism A multicenter retrospective 6-year case series study. *J Periodntol* 2006; 77: 1340-7.
- 14-Rios HF, Avila G, Galindo P, Bratu E, Wang HL. The influence of remaining alveolar bone upon lateral window sinus augmentation implant survival. *Implant Dent* 2009; 18: 402-12.
- 15-Pommer B, Zechner W, Watzek G, Palmer G. To graft or not to graft? Evidence-based guide to decision making in oral bone graft surgery. In: Zorzi A, Batista de Miranda J, eds. *Bone Grafting.* Rijeka, Croatia: InTech; 2012:159-182.
- 16-Winkler S, Morris HF, Ochi S. Implant survival to 36 months as related to length and diameter. *Ann Periodontol.* 2000; 5:22-31.
- 17-Haas R, Mensdorff-Pouilly N, Mailath G, Watzek G. Success of 1,920 IMZ implants followed for up to 100 months. *IntJOralMaxillo facImplants.*1996; 11:581-88.

- 18-Bilhan H, Cilingir A, Bural C, Bilmenoglu C, Sakaro O, Geckilio. The evaluation of the reliability of periostest for implant stability measurements: an in vitro study. *J Oral Implantology*. 2014; 54: 232-8.
- 19-German Gomez-Roman, Dieter Lukas. Influence of the implant abutment on the periostest value: An in vivo study. *Quintessence int*. 2001; 32: 797-799.
- 20-O'Sullivan D, Sennerby L, Jagger D, Meredith N. A comparison of two methods of enhancing implant primary stability. *Clin Implant Dent Relat Res* 2004; 6: 48-57.
- 21-Yoon HG, Heo SJ, Koak JY, Kim SK, Lee SY. Effect of bone quality and implant surgical technique on implant stability quotient (ISQ) value. *J Adv Prosthodont* 2011; 3: 10-5.
- 22-Markovic A, Calasan D, Colic S, Stojcev-Stajcic L, Janjic B, Misic T. Implant stability in posterior maxilla: bone condensing versus bone-drilling: a clinical study. *Oral Surg Oral Med Oral Pathol Oral Radiol Endod*. 2011; 12: 557-63.
- 23-Kong, L., Liu, B.L., Hu, K.J., Li, D.H., Song, Y.L., Ma, P. & Yang, J. optimized thread pitch design and stress analysis of the cylinder screwed dental implant. 2006; 24: 509-15.
- 24-Chaytor DV, Zarb GA, Schmitt A, Lewis DW. The longitudinal effectiveness of osseointegrated dental implants. The Toronto study: bone level changes. *Int J Periodont Restorative Dent* 1991; 11: 113-125.
- 25-Armitage GC, Svanberg GK, Loe H. Microscopic evaluation of clinical measurements of connective tissue attachment levels. *J Clin Periodontol* 1977; 4:173-90.
- 26-Magnusson I, Listgarten MA. Histological evaluation of probing depth following periodontal treatment. *J Clin Periodontol* 1980; 7:26-31.
- 27-Bornstein MM, Scarfe WC, Vaughn VM, Jacobs R. Cone beam computed tomography in implant dentistry: a systematic review focusing on guidelines, indications, and radiation dose risks. *Int J Oral Maxillofac Implants* 2014; 29: 55-77.
- 28-Cassetta M, Sofan AA, Altieri F, Barbato E. Evaluation of alveolar cortical bone thickness and density for orthodontic mini-implant placement. *J Clin Exp Dent* 2013; 5: 245-52.
- 29-Nesir R, Bischof M, Vazquez L, Szmukler-Moncler S, Bernard JP. Osteotome sinus floor elevation without grafting material: A 1-year prospective pilot study with ITI implants. *Clin Oral Implants Res* 2006; 17: 679-86.
- 30-Yunus B. Assessment of the increased calcification of the jaw bone with CT-Scan after dental implant placement. *Imaging Sci Dent* 2011; 41: 59-62.