



Evaluation of Bio-Stimulatory Effect of Low Intensity Laser on Platelet Rich Fibrin System and Bone Graft in Treatment of Infra-Bony Defect

Soad O. Ebada^{1*}, Hamdy A. Nassar², Naglaa S. Elkilani³

Codex : 33/2004

azhardentj@azhar.edu.eg

http://adjg.journals.ekb.eg

DOI: 10.21608/adjg.2020.13013.1145

Oral Medicine & Surgical Sciences
(Oral Medicine, Oral & Maxillofacial
Surgery, Oral Pathology, Oral Biology)

ABSTRACT

Purpose: The current clinical study was done to examine clinical and biochemical changes of Vascular Endothelial Growth factor (VEGF) biomarker present in (GCF) in response to LLLT combined with Platelet Rich Fibrin (PRF) & bovine xenograft to treat infra-bony defects. **Material and methods:** The current study was conducted on twenty (20) sites from ten (10) patients. A split-mouth design used, sites were randomly selected from each patient, into two groups: laser group; ten (10) sites received PRF system without irradiation, and control group; ten (10) sites received PRF system and it will be irradiated with low level laser. Clinical parameters including probing pocket depth (PPD), clinical attachment level (CAL), Plaque index (PI), and gingival index (GI). ELISA quantification analysis of VEGF was done. **Results:** comparison between the groups at 6 months showed significant difference between both Probing depth and clinical attachment level, while Plaque index and Gingival index showed a significance difference starting from 2 weeks postoperatively. VEGF revealed no significant difference among groups. **Conclusion:** The using of low intensity laser with PRF system showed an improvement in the outcome of infra bony defects treatment.

KEYWORDS

Infra-bony defects,
LLLT, PRF, Xenograft, VEGF

INTRODUCTION

Periodontal disease is an inflammation of tooth-supporting tissue including cementum, periodontal fibers and alveolar bone leading

- A paper extracted from Master Thesis titled “Evaluation of Bio-stimulatory Effect of Low Intensity Laser on Platelet Rich Fibrin System and Bone Graft in Treatment of Infra-Bony Defect”
- 1. Demonstrator of Oral Medicine, Periodontology and Oral Diagnosis and Department, Faculty of Dental Medicine, Misr University for Science and Technology, Cairo, Egypt
- 2. Professor of Oral Medicine, Periodontology, Oral Diagnosis and Dental Radiology Department, Faculty of dental medicine for Girls, Al-Azhar University, Cairo, Egypt
- 3. Professor and the Head of Oral Medicine, Periodontology, Oral Diagnosis and Dental Radiology Department, Faculty of Dental Medicine for Girls, Al-Azhar University, Cairo, Egypt

* Corresponding author email: i_luv_egy@hotmail.com

to destruction of teeth supporting tissues then loss of teeth if not properly treated. The goal of periodontal treatment is the regeneration of lost periodontal tissues during the disease process. A diversity treatment approaches proposed to promote regeneration of periodontal tissues⁽¹⁾. Periodontal regeneration modalities used to progress the short-and long-term clinical results of periodontal affected teeth. Deep pockets allied with deep infra-bony defects are a clinical challenge⁽²⁾.

Bone grafts/bone substitutes are applied to allow alveolar bone and root cementum regeneration, and produce space needed for the process. They are classified according to its material characteristics as osteoneogenic grafts, osteoinductive, or osteoconductive. Besides, they are discriminated between autologous (collected from the same individual), allogenic (from other individuals of the same species), and xenografts (from different species)⁽³⁾.

Platelet-rich Blood Derivatives broadly used in different arenas of medicine and stem cell-based tissue engineering which usually stimulates cells by a solitary bioactive agent with significant regenerative functions⁽⁴⁾.

Numerous efforts made to advance new, easy-to-use platelet-derived product. This led to platelet-rich fibrin (PRF), as it is a single phase centrifuged product that does not require addition of several chemicals. Platelet Rich Fibrin release high amounts of multiple growth factors including TGF β -1, PDGF, and VEGF⁽⁵⁾.

Vascular Endothelial Growth Factor (VEGF) proteins are stored in large quantities in platelet α -granules and considered to be pro-angiogenic. Megakaryocytic secretes VEGF which can help in proliferation of vascular endothelial cells⁽⁶⁾. Regulation of VEGF expression within wound healing is significant since angiogenesis seems to be bothered in abnormally wounds healing⁽⁷⁾.

Studies have shown direct correlation of vascular endothelial growth factor values present in GCF and

the inflammatory state of the periodontal tissues⁽⁸⁾. One of them, studied the connection between VEGF expression and vascularization concerning the number and diameter of blood vessels and found that VEGF may be associated more to the healing phase of periodontal disease than to the destruction phase⁽⁹⁾.

These days, Lasers have a multiple application, from mechanical to life sciences. In the arena of Periodontology, Lasers are typically recognized for their claim in the elimination of tissues or hemostasis through their capability to improve the cellular processes through the functional energy in terms of space, time, and surface⁽¹⁰⁾.

Lasers and its usage in dentistry especially oral surgery are hastily improving⁽¹¹⁾. Benefits of LLLT in wound healing are multifold. LLLT causes bio modulation effects on different cell types, for instance keratinocytes, fibroblasts, osteoblasts, odontoblasts, cardiomyocytes, and endothelial cells. This, in turn, increases cell proliferation, matrix synthesis, increased granulation tissue, enhanced neovascularization, early epithelialization, anti-inflammatory, and antiedema effect. LLLT brings about a photo stimulatory effect in mitochondria processes of the cells which enhances growth factor release and ultimately hastens healing⁽¹²⁾.

The semiconductor diode lasers (Gallium arsenide (Ga As), gallium aluminum-arsenide (Ga Al As) are moveable compacted surgical units with effective and dependable benefits⁽¹³⁾. LLLT may induce bone formation within the bony defect more than PRF. However, combination of each LLLT and PRF as treatment way may induce bone formation within the bone defect over that of LLLT or PRF alone according to AHMED ABBASS in his experimental study on rats showed this combination may have synergic effect on bone healing⁽¹⁴⁾.

MATERIAL AND METHODS

Study design: Ten patients diagnosed as having periodontitis; stage III, grade (A) were selected from the outpatient clinic of Periodontology, Oral Medicine, Radiology & Diagnosis Department, Faculty of Dental Medicine for Girls, Al-Azhar University to be included in this study. All patients signed an informed consent. The inclusion criteria included patients who are free from systemic diseases with presence of at least seven natural teeth to provide reasonable number of teeth, matched periodontitis with a PD \geq 5 mm and attachment loss \geq 4 mm. The patients are non-smoker and non-pregnant (women cases) and they are not taking antibiotics or NSAID drugs within the last three months prior to treatment. Additionally, the selected sites should not have been treated surgically within the last year before the initiation of the study.

Sample Size: The sample size of 10 patients (10 sites in each group) was enough to detect the difference. All patients were divided randomly in two groups. (Lasered group): ten (10) sites side received PRF system and was irradiated with LLLT using 810 nm Diode laser. (Control group): ten (10) sites side received PRF system only without using of LLLT.

Study procedures: phase one therapy, supra & subgingival scaling, root planning also oral hygiene instructions were performed for each patient via manual and ultrasonic instrumentation. Approximately after the initial therapy by 4 weeks, the clinical parameters and plaque control were re-assessed. All the included patients had to have good oral hygiene prior to advancing to the surgical procedures. At the baseline and a week, 2 weeks, 3, 6 months, postoperatively the clinical examinations were done to assess the Pocket Probing Depth (PPD), Clinical Attachment Level (CAL), Gingival Index (GI) and Plaque Index (GI). In addition to ELISA quantification for VEGF.

Surgical procedures: All teeth, with pockets \geq five mm in the same quadrant as the teeth selected to the study, were surgically treated. In all locations, under local anesthesia, an intra-crevicular incision, full-thickness muco-periosteal flaps were reflected then followed by the elimination of G.T using manual instruments. Surface of roots were scaled and planed by curettes and flushed by a sterile saline solution. An interrupted suture of the flap and then covered with periodontal dressing to avoid any infection in all patients. Operations done on patients were almost identical. The teeth on the laser sets, were equal to control sets in numbers, and all procedures were accomplished in an hour. Post-operative instructions were as follows; Soft toothbrush to be used in 1st two weeks, and avoiding flossing, and chewing in the treated area for two weeks. Patients restarted full oral hygiene and function after then. Ibuprofen (200 mg) upon need was prescribed (The primary outcome of LLLT assisted-surgery was the lessening of a self-reported post-treatment ache which lead to stop using the analgesics), chlorhexidine (2 times/day) for six weeks, Augmentin (1g) tablets BID for five days to avoid possibility of contamination.

Laser protocol: Diode laser 810(\pm 20 nm ,one Watt power, contact - continuous mode) applied to the flap. A tip (400-mm-diameter) accustomed eliminating all viable epithelium inside the flap from F.G.M to the end of the flap. The tip was an initiated in type. Treatment was accomplished in parallel manner from the coronal to the apical aspect, and the beam of the laser was intermittent (thirty seconds) /ten seconds irradiation. The resulting char deposit was removed with wet cotton-gauze. Another application with the same WL of the laser used before but, a non-contact continuous mode at 0.1 Watt was used and by special bio-stimulation tip. All aspects of the flap, alveolar bone, and the graft material in addition to PRF membrane were irradiated, resulting in a complete dose of four J/cm² / surface. Protective eyewear was worn by all to prevent injury from laser wavelength exposure and to comply with safety standards.

Bio-chemical evaluation:

Collection of GCF samples and VEGF biochemical bone markers: At each three appointments (baseline, 1 week and 2 weeks), Collecting GCF samples from one pocket were done. Level of VEGF in GCF samples will be measured using means of Enzyme Linked Immune Sorbent Assay (ELISA).

Statistical analysis:

Values were presented as mean and standard deviation (SD) values. Data were explored for normality using Kolmogorov-Smirnov test of normality. For parametric data (Pocket depth and VEGF ELISA) independent t-test was used to compare both sets, while ANOVA-test (followed by Tukey's post-hoc test) was used to compare among different observations within the same group. For non-parametric data, Mann Whitney U-test was used to compare both sets, while Wicoxon-signed rank and Freidman tests were used for comparison between different observations within the same group. Significance level was set at ($p < 0.05$). The statistical analysis was performed with SPSS 18.0 for Windows.

RESULTS

All involved patients completed the study and were re-evaluated at follow up visits. Baseline values were not significant different among the test and control sets for all the assessed variables, suggesting that the initial defect characteristics did not affect the final differences between the treatment modalities, thus allowing post-treatment results to be compared.

With respect to the PD and CAL; A probing pocket depth showed significant decrease of 2.72mm in

laser group and 2.39mm for control group ($P < 0.05$), while comparison among groups there was no significant difference at 3 months ($P = 0.261$) but were significantly different at 6 months ($p = 0.035$). With respect to CAL, there was a significant gain in CAL of 2.61 mm for laser group and with 1.81 mm in control group by 3 months, to reach its maximum gain (almost no CAL) after Six months, without any significance between the groups. (Table 1).

Concerning plaque & gingival indices (PI & GI); There was significant decrease starting from 2 weeks, while the change among 2 weeks, 3 and six months was not significant in laser group, while, control group gradually decreased by time, to reach its lowest value after three months, then slightly increased at six months but with no significance between 3 and 6 months; PI (1.400 ± 0.163) at baseline for laser group, (1.800 ± 0.133) for control group, and (0.000 ± 0.000) for laser, (0.800 ± 0.200) for control group, postoperatively, GI score was (1.50 ± 0.17) at baseline in laser group, (1.60 ± 0.16) in control group, and (0.00 ± 0.00) in laser, (1.00 ± 0.00) in control group, , postoperatively. By comparing between groups there was a significant difference by time in favor to laser group. (Table 2)

The biochemical findings of VEGF revealed that there was statistically significant decrease in its level in GCF from baseline (163.37 ± 4.77) to 3 months (140.35 ± 3.37) to 6 months (130.39 ± 3.03) in laser group, while in control group the only significance was from baseline (158.58 ± 4.88) to 3 months (140.97 ± 2.33) with no significant difference by 6 months (134.21 ± 2.02) (Figure 1). By comparing between groups there was a non-significant difference in values. (Table 3)

Table (1) Descriptive statistics and comparison of pocket depth (mm) and CAL (mm) intra groups (T-test) and between groups (Mann-Whitney U test)

Variables	Groups	Baseline	3 months	6 months	P
PD (mm)	Laser	4.48 ^a ±0.26	2.28 ^b ±0.19	1.76 ^b ±0.12	0.00*
	Control	4.50 ^a ± 0.15	2.53 ^b ±0.10	2.11 ^b ± 0.10	0.00*
P (between groups)		0.953 ns	0.261 ns	0.035*	
CAL (mm)	Laser	2.74 ^a ± 0.34	0.13 ^b ±.05	0.00 ^b ±0.00	0.00*
	Control	2.04 ^a ± 0.34	0.23 ^b ±.007	0.00 ^b ± 0.00	0.00*
P (between groups)		0.159ns	0.306ns	1.000ns	

Significance level $P < 0.05$, ns=non-significant Wilcoxon signed Rank test: post hoc test means sharing the same superscript letter are not significantly different

Table (2) Descriptive statistics of PI and GI scores comparison intra-group (Friedman test) and in-between groups (Mann-Whitney U test)

Variables	Groups	Baseline	2 weeks	3months	6 months	P
PI(scores)	Laser	1.400 ^a ±.163	.000 ^b ±.000	000 ^b ±.000	000 ^b ±.000	0.00*
	Control	1.800 ^a ±.133	1.100 ^b ±.180	.600 ^c ±.163	.800 ^c ±0.20	0.00*
P (between groups)		.075ns	.000*	.004*	.002*	
GI(scores)	Laser	1.5000 ^a ±.16667	.0000 ^b ±.00000	.0000 ^b ±.000	.0000 ^b ±.000	0.00*
	Control	1.600 ^a ±.16330	.700 ^b ±.15275	.700 ^b ±.1527	1.000 ^b ±.00	0.00*
P (between groups)		.661ns	.001*	.001*	.000*	

Significance level $p < 0.05$, * significant Wilcoxon signed Rank test: means sharing the same superscript letter are not significantly different

Table (3) Descriptive statistics and comparison of VEGF in GCF (ELISA) within the same group (ANOVA test) and in between (independent T test)

Variables	Groups	Baseline	3 months	6 months	P
VEGF in GCF	Laser	163.37 ^a ±4.77	140.35 ^b ±3.37	130.39 ^c ±3.03	0.00*
	Control	158.58 ^a ±4.88	140.97 ^b ± 2.33	134.21 ^b ± 2.02	0.00*
P (between groups)		0.492ns	0.882ns	0.310ns	

Significance level $P < 0.05$, *significant. Tukey's post hoc test: means sharing the same superscript letter are not significantly different

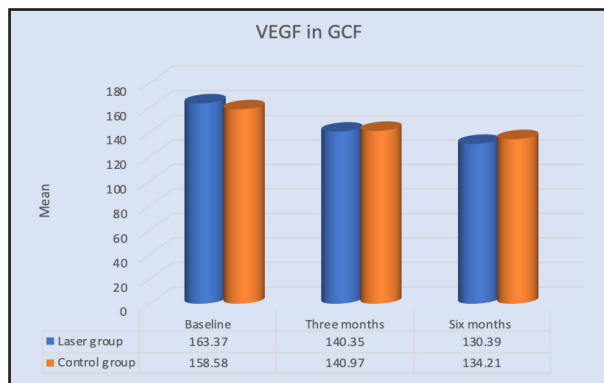


Figure (1) Bar chart showing mean VEGF in GCF in different observation times

DISCUSSION

Periodontitis is a chief community health problem owing to its huge incidence, and because it possibly will lead to loss of teeth and injury, damagingly affect mastication function and esthetics, and impair quality of life ⁽¹⁵⁾. Periodontitis is a chronic multifactorial inflammatory disease associated with dysbiotic plaque biofilms and considered a progressive destruction of the tooth-supporting apparatus. Its primary effect includes the loss of periodontal tissue support, revealed as clinical attachment loss (CAL) and radiographically assessed alveolar bone loss, presence of periodontal pocketing and gingival bleeding ⁽¹⁶⁾.

Regeneration of the lost periodontal structures is the purpose of the periodontal therapy to restore; health, function and esthetics of periodontium⁽¹⁷⁾. Several methods have been attempted for regeneration the lost tissues including OFP combined with grafts, guided tissue regeneration (GTR), several biological mediators such as GFs, application of extracellular matrix proteins & attachment factors, using of bone metabolism mediators, tissue engineering and recently the use of lasers considered a great of value ⁽¹⁸⁾.

Low level laser use for periodontal and oral purposes become the concern of various studies. Stimulation with LLL enhances the healing, such as acceleration of bony defects healing ⁽¹⁴⁾.

Selection the approach is usually depended on the infra-bony defect characteristics, as defect morphology, topography of root surface, and gingival phenotype, as it influence the regeneration potential. Consequently, most of intra-bony defects are frequently achieved using a mix of regenerative approaches ^(2,19).

In the current study, PRF system used in the current study is designed to be PRF membrane saddling the xenograft which was mixed with the PRF fluid to allow maximum biologic effect and also to investigate the PRF ability as a membrane to prevent the downward growth of junctional epithelium into the healing area, hence it can be used as a resorbable membrane for GTR ^(4,5), this in accordance to previous studies. Evaluated (PRF) effects on augmentation in animal model. PRF and bovine bone exhibited greater zone of bone deposition than the other groups at 3 months ⁽²⁰⁾.

There are studies in literature found the use of low level laser along the bone graft promoted a horizontal bone gain, which was significant compared to the control group used bone grafting only ⁽²¹⁾. Also several published experimental studies assessed the effects of either Laser or PRF in bone healing; however, in one of these experiments the combined effect of LLLT with PRF as a treatment modality in the bony surgical defects showed the greatest amount of bone formation with the best quality of the newly formed bone, Histological examination & statistical analysis confirmed superiority of combing bioactive surgical additive PRF and LLLT on bone repair ^(22,23). Therefore, the research question was the application of LLL does enhance the healing of infra-bony defects involvement.

During the surgical procedures in this study, infra-bony defect was irradiated using diode laser (810nm) in non-contact continuous wave mode (0.1 W) in an apicocoronally direction for 20-30 s ⁽²²⁾. This application protocol agrees with other studies, the same dose was used in our work, suggested that, the use of 1–5 J/cm² has helpful effects on the hard and soft tissues ^(23,24).

Analysis of gingival crevicular fluid (GCF) assessed periodontitis activity and clarified periodontal treatment outcome. GCF has been proven to be suitable for detection of biochemical markers that serves as indicator for periodontal disease activity⁽²⁵⁾.

Vascular Endothelial Growth Factor is the primary mediator in angiogenesis which are important characteristics of inflammation, wound healing, and bone remodeling. In periodontal compromised patients, the measurements of the entire quantity of VEGF from GCF in affected sites were more than from non-affected sites. VEGF stimulates collagen deposition, angiogenesis, and epithelization promoting wound healing^(8,9,26).

Low Level Laser Therapy using diode laser has a helpful effect in gingival healing, as it led to increase mRNA production of GFs. So, the best time to apply LLLT is at the stage of cell proliferation, when the secretion of VEGF, BFGF, HGF and SCF GFs is needed to promote the proliferation of fibroblasts and wound healing⁽²⁷⁾. So, the present study selected VEGF as a biochemical marker to detect the response of periodontitis to treatment with surgical regenerative procedure using PRF system and bone grafts only and assisted by low level laser Bio stimulation.

Results from present study proved that regeneration and pocket reduction surgical trials and adjunctive use of lasers revealed no clinical significance concerning PD reduction and CAL gain when compared to control group who received conventional approaches, although each group showed significantly difference from baseline to 6 months, this is in accordance to systemic review and meta-analysis to assess and compare studies concerning lasers as an adjunctive or monotherapy for surgical treatment⁽²⁸⁾.

However, within a short-term trial on chronic periodontitis patients with infra-bony defects getting treatment with GTR alone or in combination with

low-level laser (808 nm) therapy proved statistically better enhancements by means of PD reduction, CAL gain and lessen GR at six months⁽²⁹⁾.

Plaque index among the two groups showed significant difference indicated that laser groups showed better reduction in PI, indicating the bacterial reduction achieved using laser, as revealed by previous studies evaluated the effect of LLLT on plaque formation⁽³⁰⁾. Gingival index' results were significantly different between the groups in favor to laser groups, indicating its greater effect in reduction gingival inflammation. This is in accordance with few previous studies where diode laser was used adjunctive to non-surgical therapy in which no change observed among the groups in gingival index scores⁽³¹⁾. In literature, they have also demonstrated the presence of VEGF-A in the supernatant obtained from the culture of endothelial cells treated with LLLT⁽³²⁾.

Moreover, multiple authors compared GCF-VEGF concentrations in a study of PRF and xenograft at changed sampling times. VEGF concentrations in all group samples gained during the early post-operative period (1, 3, and 7 days) were significantly higher than those obtained further (14, 21, and 30 days) with ($P < 0.05$). No significance among the groups at all follow up periods. levels of VEGF lessened steadily in the samples gained on 14, 21, and 30 days in all groups with no significance ($P > 0.05$)⁽³³⁾.

In consistent to these studies, VEGF level in GCF tested in our study showed marked decrease from baseline time to 3 months and to 6 months with a significant difference between each observation times in laser group without any significance between the groups. These results are parallel to the findings of several authors, established changes (VEGF-A and TGF- β level) post irradiation of the laser (635 nm and 830 nm)⁽³⁴⁾. Another study used laser radiation 830 nm (3.75 mW/cm²) with energy density (2, 4, and 8 J/cm²), resulted in cell proliferation increase when compared to the

non-irradiated group but the results were not significant ($p>0.05$)⁽³⁵⁾.

In contrast to previous studies, an in-vitro study evaluated the low-power HeNe laser effect on endothelial cells concluded that LLLT increases VEGF during the early phases of inflammation as neovascularization is necessary for wound healing⁽³⁶⁾. Also, in contrast to our results, the level of VEGF was the lowest at energy of 8 J/cm² using (635 nm) at the same time, the significant proliferation level when compared to non lased groups⁽³⁷⁾. The differences contributed to low level laser application in present study.

It is important to note that, both treatment modalities used in this study showed improvements in the evaluated parameters. This may be attributed to the use of PRF system, but with more favorable results in the lased group which suggests the promising future therapeutic applications of LLLT for periodontal tissue regeneration.

CONCLUSION

Combination of low level laser in addition to PRF system as treatment modality may have a synergetic effect to encourage formation of bone in defects better than LLLT or PRF alone.

REFERENCES

1. Abramson J. The Cornell medical index as an epidemiological tool. *Am J Public health*. 1966; 56: 287-98
2. AlGhamdi A.S, Shibly O, Ciancio, S.G. Osseous grafting part II: Xenografts and alloplasts for periodontal regeneration—a literature reviews. *J Int Acad Periodontol* 2010;12: 39–44
3. Cortellini P, Tonetti MS. Clinical concepts for regenerative therapy in intrabony defects. *J Clin Periodontol* 2015; 68: 282–307
4. Ramaprabha G, Siji JT. Platelet rich fibrin-a boon for periodontal regeneration. *Indian J Multidisciplinary Dent*; 2014: 4:956-8
5. Masoudi E, Ribas J, Kaushik G, Leijten J, Khadem hosseini A. Platelet-Rich Blood Derivatives for Stem Cell-Based Tissue Engineering and Regeneration. *Curr Stem Cell Rep*. 2016; 2:33–42
6. Chesterman CN, Walker T, GregoB, Chamberlain K. Comparison of platelet derived growth factor prepared from release products of fresh platelets and from outdated platelet concentrates. *Biochem Biophys Res Comm*. 1983; 116: 809-16.
7. Banys-Paluchowski, M., Witzel, I., Riethdorf, S. The clinical relevance of serum vascular endothelial growth factor (VEGF) in correlation to circulating tumor cells. *Breast Cancer Res Treat* 2018; 1:172-93
8. Beral Afacan, Veli Ozgen ozturk, Cigdem Pasal, Emir Bozkurt, Timur Kose, Gulnur Emingil. Gingival crevicular fluid and salivary HIF-1 α , VEGF, and TNF- α levels in periodontal health and disease *J Periodontol*. 2018; 10:1–10
9. Padma R, Annaji Sreedhara, Indeevar P, Indranil, Sarkar, and Chetan S Kumar. Vascular Endothelial Growth Factor Levels in Gingival Crevicular Fluid Before and after Periodontal Therapy. *J Clin Diagn Res* 2014; 20:11-9
10. Aoki A, Ando Y, Watanabe H, Ishikawa I. In vitro studies on laser scaling of subgingival calculus with an erbium: YAG laser. *J Periodontol*. 1994; 65: 1097–106
11. Aoki A, Mizutani K, Schwarz F, Sculean A, Yukna RA, Takasaki AA, et al. Periodontal and peri-implant wound healing following laser therapy. *Periodontol* 2000. 2015; 68: 217–69
12. Evans G, Eke P, Wei L. Periodontitis among adults aged 30 years in United States in period between 2009-2010. *MMWR Surveill Summ* 2013; 62:129-35
13. Karoussis IK, Kyriakidou K, Psarros C, Koutsilieris M, Vrotsos JA. Effects and Action Mechanism of Low Level Laser Therapy (LLL) applications. *Periodontology* 2018; 8: 514
14. Khaled Atef El-Hayes, Ahmed Abbas Zaky, Zeinab Amin Ibrahim, Ghada Farouk Ahmed Allam, Mohamed Farouk Allam. Usage of Low Level Laser Bio stimulation and Platelet Rich Fibrin in Bone Healing: Experimental Study. *Dent. Med. Probl*. 2016; 53: 5
15. Tonetti MS, Greenwell H, Kornman KS. Staging and grading of periodontitis: framework and proposal of a new classification and case definition. *J Periodontol*. 2018;89:159–72.
16. Needleman I, Garcia R, Gkraniats N, et al. Mean annual attachment, bone level and tooth loss: a systematic review. *J Periodontol*. 2018;89: 120–39.

17. Christoph A. Ramseier¹, Giulio Rasperini, Salvatore Batia, and William V. Giannobile. Advanced regenerative technologies for periodontal tissue repair. *Periodontol* 2000. 2012; 59: 185–02
18. Laurell L, Gottlow J, Zybutz M, Persson R. Treatment of intrabony defects by different surgical procedures. A literature review. *J periodontol* 1998;69:303-13.
19. Mark A. Reynolds, Richard T. Kao, Salvador Nares, Paulo M. Camargo, Jack G. Caton, Donald S. Clem. Periodontal Regeneration of Intrabony Defects: Practical Applications From the AAP Regeneration Workshop 2017; 2.
20. Ozdemir H, Ezirganli S, Isa Kara M, Mihmanli A, Baris E. Effects of platelet rich fibrin alone used with rigid titanium barrier. *Arch Oral Biol*. 2013; 58:537–4
21. Adel S Alagl. A comparative study of low level laser in combination with bovine-derived xenograft for the treatment of the grade ii furcation involvements. *Al-Azhar Assiut medical journal* 2015; 4: 13-2
22. Weber JB, Pinherio AL, De Oliveira MG, Oliveira FA, Ramalho LM. Laser therapy improves healing of bone defects submitted to autologous bone graft. *Photomed Laser Surg* 2006 24:38–44.
23. Eliades A, Stavrianos C, Kokkas A, Kafas P, Nazarglou I. 808 nm diode laser in oral surgery: A case report of laser removal of fibroma. *Res J Med Sci*. 2010; 4:175–8
24. Weber JB, Pinherio AL, De Oliveira MG, Oliveira FA, Ramalho LM Laser therapy improves healing of bone defects submitted to autologous bone graft. *Photomed Laser Surg* 2006; 4:38–44.
25. Silvana P. Barros, Ray Williams, Steven Offenbacher, Thiago Morelli. Gingival crevicular fluid as a source of biomarkers for periodontitis. *Periodontology* 2000, 2016; 70: 53–64
26. Anca Virtej, Panagiota Papadakou, Hajime Sasaki, Athanasia Bletsas, Ellen Berggreen. VEGFR-2 reduces while combined VEGFR-2 and -3 signaling increases inflammation in apical periodontitis, *Journal of Oral Microbiology*, 2016; 8:1
27. Colaco AS. An update on the effect of low-level laser therapy on growth factors involved in oral healing. *J Dent Lasers* 2018; 12:46-9.
28. Bharathi Devi, Jonn Alagadda, Sruthima N. Gottumukkala, Dwarakanath, and Suneetha Koneru. Effect of Diode Laser-assisted Flap Surgery on Postoperative Healing and Clinical Parameters: A Randomized Controlled Clinical Trial *Contemp Clin Dent*. 2018; 9: 205-12.
29. Sanz-Moliner JD, Nart J, Cohen RE, Ciancio SG. The effect of an 810-nm diode laser on postoperative pain and tissue response after modified widman flap surgery: A pilot study in humans. *J Periodontol*. 2013; 84:152–8
30. Lobo TM, Pol DG. Evaluation of the use of a 940 nm diode laser as an adjunct in flap surgery for treatment of chronic periodontitis. *J Indian Soc Periodontol*. 2015; 5:19-43
31. Moritz A, Gutknecht N, Doertbudak O, Goharkhay K, Schoop U, Schauer P, et al. Bacterial reduction in periodontal pockets through irradiation with a diode laser: A pilot study. *J Clin Laser Med Surg*. 1997; 15:33–7.
32. Bao P, Kodra A, Tomic-Canic M, Golinko MS, Ehrlich HP, Brem H, et al. The role of vascular endothelial growth factor in wound healing. *J Surg Res* 2009;153:347-58.
33. Ahmed Y. Gamal, Khaled A. Abdel Ghaffar, and Osama A. Algezwy. Crevicular Fluid Growth Factors Release Profile Following the Use of Platelet-Rich Fibrin and Plasma Rich Growth Factors in Treating Periodontal Intrabony Defects: A Randomized Clinical Trial. *J Periodontol*, 2016; 9:36
34. Sayed IS, Saafan A, Abdel-Gawad FK, Harhash TA, Abdel-Rahman MA. Effect of low-level laser therapy on gene expression of vascular endothelial growth factor and interleukin-1 β in scalpel-induced and laser-induced oral wounds in rats. *J Dent Lasers* 2015; 9:23-30.
35. Kushibiki T, Hirasawa T, Okawa S, Ishihara M. Regulation of miRNA expression by low-level laser therapy (LLLT) and photodynamic therapy (PDT). *Int J Mol Sci* 2013;14:13542-58
36. Busnardo VL, Biondo-Simões ML. Effects of low-level helium-neon laser on induced wound healing in rats. *Rev Bras Fisioter* 2010;14:45-51
37. Krzysztof Goralczyk, Justyna Szymarska, Katarzyna Linkowska, Barbara Ruszkowska-Ciastek, Lukasz Gryko, et al. Effect of low level laser irradiation on VEGF gene expression in cultured endothelial cells. *Folia Medica Copernicana* 2014; 2:61–65