

## Assessment of Left Ventricular Asynchrony after Permanent Cardiac Pacing by Using Speckle Tracking Echocardiography

SALLY M. TEIMA, M.Sc.; ESSAM M.E. MAHFOUZ, M.D.; ABDUL RAZEK A. MAATY, M.D. and AHMED H. ELADAWY, M.D.

The Department of Cardiology, Faculty of Medicine, Mansoura University

### Abstract

**Background:** Echocardiography is important in assessing Left Ventricular (LV) Mechanical Dysynchrony (LVMD) and left ventricular function after permanent pacemaker. At present, Real-Time Three Dimensional Echocardiography (RT3DE) and tissue Doppler imaging (TDI) are the most sensitive and commonly used techniques for the quantification of LVMD. Global longitudinal strain (GLS) and LV dyssynchrony assessment enables us to detect early signs of LV dysfunction after cardiac pacing.

**Aim of Study:** To evaluate LV mechanical dyssynchrony and LV function in different pacing modes after permanent cardiac pacing by using TDI and speckle tracking echocardiography and to correlate these changes with other clinical, electrocardiographic and echocardiographic data.

**Patients and Methods:** Seventy patients were enrolled in this prospective cross sectional observational study, (mean age  $60.99 \pm 13.77$  years, 42 females), in Mansoura Specialized Medical Hospital over a period of 1 year from April 2018 to April 2019. All patients were assessed by thorough history taking, clinical examination, 12 lead surface ECG, echocardiography, 2D speckle tracking echocardiography STE to assess GLS and tissue Doppler imaging TDI.

**Results:** Regarding diastolic function by pulsed wave Doppler PWD: There was significant decrease in E/e' ratio ( $p < 0.001$  \*), significant increase in myocardial performance index Tei index ( $p < 0.001$  \*). Regarding internal dimensions and systolic function: There was significant increase in the following: Left Atrial Dimension (LAD) ( $p = 0.001$  \*), Left Ventricular End Systolic Dimension LVESD ( $p < 0.001$  \*) and Left Ventricular End Diastolic Dimension LVEDD ( $p < 0.001$  \*) while there was significant decrease in ejection fraction EF ( $p < 0.001$  \*) and fractional shortening FS ( $p < 0.001$  \*). Regarding parameters of LV dyssynchrony: There was significant increase in the following: Aortic preejection delay APED ( $p < 0.001$  \*), interventricular mechanical delay ( $p < 0.001$  \*) and septal posterior wall motion delay SPWMD by M mode ( $p < 0.001$  \*). Regarding parameters assessed by tissue synchronization imaging TSI: There was significant increase in the following: SD-Ts ( $p = 0.001$  \*) and all segments Max delay ( $p = 0.027$  \*).

Regarding parameters assessed by STE: There was significant decrease in global longitudinal strain GLS ( $p = 0.034$  \*) while there was significant increase in TP-SD by STE ( $p < 0.001$  \*).

Also, there was significant decrease in global longitudinal strain GLS ( $p < 0.001$  \*) and significant increase in TP-SD by STE ( $p = 0.001$  \*) in DDD group. While there was significant decrease in global longitudinal strain GLS ( $p < 0.001$  \*) and significant increase in TP-SD by STE ( $p < 0.001$  \*) in VVI group.

**Conclusion:** GLS and 2D STE can help in the detection of subclinical left ventricular dysfunction after permanent pacemaker implantation before appearance of symptoms. Also, cardiac pacing leads to LVMD whatever the pacing mode is which may needs later on upgrading to cardiac resynchronization therapy CRT.

**Key Words:** LVMD – GLS – Pacemaker – Speckle tracking echocardiography.

### Introduction

**THE** use of an optimal pacing mode for the treatment of bradycardia is important. In patients with Sick Sinus Syndrome (SSS), dual chamber pacing (DDD) and single chamber pacing (VVI) pacing modes may increase the risk of congestive heart failure, atrial fibrillation and thromboembolism [1]. The main mechanism behind this may be that the electrical dyssynchrony induced by the abnormal ventricular activation site and sequence in the DDD and VVI pacing modes leads to Left Ventricular Mechanical Dyssynchrony (LVMD) and Left Ventricular (LV) dysfunction [2]. The cardiac pacing at any point of the ventricle alters the natural heart activation and contraction pattern, as stimulus conduction velocity is slower across ventricular myocardium, when compared to that resulting from the specialized His-Purkinje system [3].

RV pacing creates abnormal contraction, reduced pump function, causes hypertrophy and

**Correspondence to:** Dr. Sally M. Teima, The Department of Cardiology, Faculty of Medicine, Mansoura University

ultrastructural abnormalities. Right ventricular apical pacing can induce both interventricular dyssynchrony [between the Right Ventricle (RV) and the Left Ventricle (LV)], as well as intraventricular dyssynchrony (within the LV) [4].

It has been demonstrated that the presence of ventricular dyssynchrony is associated with an increased risk of cardiac morbidity and mortality [5].

In addition, it has been suggested that the presence of mechanical dyssynchrony after long-term RV apical pacing is associated with reduced LV systolic function and deterioration in functional capacity [4].

Echocardiography is important in assessing LVMD and LV function. At present, Real-Time Three Dimensional Echocardiography (RT3DE) and Tissue Doppler Imaging (TDI) are the most sensitive and commonly used techniques for the quantification of LV mechanical dyssynchrony [6].

Speckle Tracking Echocardiography (STE) is a post-processing computer algorithm that uses the routine grayscale digital images. The utility of speckle tracking radial strain in quantifying dyssynchrony which is defined as the time difference in peak anteroseptum to posterior wall strain more than or equal to 130ms [7].

Global Longitudinal Strain (GLS) and LV dyssynchrony assessment enables us to detect early signs of LV dysfunction. Mechanisms of dyssynchrony development will be useful for pacemaker programming choices in order to prevent further dyssynchronisation [8].

The aim of this study was to evaluate LV mechanical dyssynchrony and LV function in different pacing modes after permanent cardiac pacing by using TDI and Speckle Tracking Echocardiography (STE) and to correlate these changes with other clinical, electrocardiographic and echocardiographic data.

## Patients and Methods

### Study population:

Seventy patients were enrolled in this prospective cross sectional observational study, (mean age  $60.99 \pm 13.77$  years, 42 females), in Mansoura Specialized Medical Hospital, over a period of 1 year from April 2018 to April 2019. Patients were enrolled into 2 groups, first group: 30 patients with implanted single chamber pacemaker (VVI), second

group: 40 patients with implanted dual chamber pacemaker (DDD).

### Ethics statement:

All procedures were performed as recommended by the guidelines as regard conventional and speckle tracking Echocardiography [17]. The study was explained to all patients and they gave oral informed consent. Besides, the study is approved by the Ethics Committee of the Faculty of Medicine, Mansoura University.

### Methodology:

All patients were assessed by thorough history taking including; age and gender, risk factors for coronary artery disease; hypertension, diabetes, dyslipidemia.

*Clinical examination included:* Blood pressure, pulse, general examination and local cardiac examination.

*Investigations included:* 12 lead surface Electrocardiography (ECG), Echocardiography, 2D speckle tracking echocardiography STE to assess GLS and Tissue Doppler Imaging (TDI).

### Echocardiography:

All patients have had an echocardiography using General Electric Vivid E9 XD clear Dimensions ultrasound system (GE Healthcare, USA) using the matrix M5Sc transducer. With more stress on the following pulsed wave Doppler PWD, TDI, septal posterior wall motion delay SPWMD by M mode, aortic pre-ejection delay, inter-ventricular mechanical delay, tissue synchronization imaging TSI (septal to lateral delay, septal to posterior delay and SD-Ts), 2D STE (TP-SD and global longitudinal strain). The left ventricular systolic function also was evaluated LVEF. The reference limits of all the echocardiographic parameters were defined according to the American Society of Echocardiography (ASE) Guidelines assessed in the PSLAX, PSSAX, apical 2 chambers and apical 4 chambers views.

### Exclusion criteria:

*Exclusion criteria include the following:* Patients with poor echo window, patients with symptoms of overt heart failure, previous cardiac surgery, dilated cardiomyopathy, prosthetic valves, patients with previous coronary artery disease detected by evidence of LV regional wall motion abnormalities at the echocardiogram or pathological Q waves in electrocardiogram, previous Percutaneous Coronary Intervention (PCI) or Coronary Artery Bypass

Grafting (CABG), previous implanted pacemaker or Implantable Cardioverter-Defibrillator (ICD), frequent PVCs in ECG and patients with terminal co-morbidities such as end stage malignancy, end stage renal or liver diseases.

#### Statistical analysis:

The clinical and laboratory data were recorded on an "investigation report form". These data were tabulated, coded then analyzed using the computer program SPSS (Statistical package for social science) version 20 to obtain:

#### Descriptive data:

Descriptive statistics were calculated for the anthropometric measurements and laboratory data in the form of:

- Mean  $\pm$  Standard Deviation (SD).
- Frequency (number-percent).

#### Analytical statistics:

- In the statistical comparison between the different groups, the significance of difference was tested using the following test.
- Student's *t*-test: Used to compare between mean of two groups of numerical (parametric) data.
- Inter-group comparison of categorical<sub>2</sub> data was performed by using chi square test ( $\chi^2$ -value).
- Paired *t*-test was used for comparison within groups.
- Wilcoxon signed ranks test (Z) was used for comparison within group.
- A *p*-value <0.05 was considered statistically significant and a *p*-value <0.0001 was considered highly significant (HS) in all analyses.

## Results

The study done on 70 patients (mean age  $60.99 \pm 13.77$  years) who were divided into two groups: The first group with pacing mode single chamber pacemaker VVI with mean age  $65.7 \pm 12.3$  years, and the second group with pacing mode dual chamber pacemaker DDD with mean age  $57.45 \pm 13.89$  years and each group was assessed at 1 month and after 3 months of permanent pacemaker implantation (Table 1).

Smokers were 15.7%, 65.7% were hypertensive patients, 12.9% were dyslipidemic and 15.7% were diabetic patients of the whole studied population (Table 1). While (Table 2) demonstrates baseline criteria among the two studied groups.

Table (1): Baseline characteristics of the studied patients.

	All patients (n=70)	
	No.	%
Age:		
<40y	6	8.6
40-60y	28	40
>60y	36	51.4
Mean $\pm$ SD	60.99 $\pm$ 13.77	
Sex:		
Male	28	40
Female	42	60
Hypertension	46	65.7
Diabetes	11	15.7
Smoking	11	15.7
Dyslipidemia	9	12.9
Beta blocker	10	14.3
ACEI	38	54.3
Diuretic	31	44.3
Aspirin	13	18.6
Warfarin	4	5.7
Congested neck veins	18	25.7
Edema LL	29	41.4
Dyspnea	18	25.7

ACEI : Angiotensin Converting Enzyme Inhibitor.  
LL : Lower Limb.

Table (2): Baseline characteristics among the two studied groups.

	DDD (n=40)		VVI (n=30)		$\chi^2$	<i>p</i>
	No.	%	No.	%		
Hypertension	27	67.5	19	63.3	0.132	0.716
Diabetes	8	20	3	10	1.294	0.255
Smoking	10	25	1	3.3	6.076	0.014*
Dyslipidemia	6	15	3	10	0.383	0.536
Betablocker	8	20	2	6.7	2.489	0.115
ACEI	24	60	14	46.7	1.228	0.268
Diuretic	17	42.5	14	46.7	0.121	0.728
Aspirin	10	25	3	10	2.551	0.110
Warfarin	0	0	4	13.3	5.657	0.017*
Congested neck veins	10	25	8	26.7	0.025	0.875
Edema LL	18	45	11	36.7	0.491	0.484
Dyspnea	12	30	6	20	0.897	0.343

LL : Lower Limb. *p* : Probability value.  $\chi^2$  : Chi square.  
N : Number. \* : Significant value >0.05. % : Percentage.

#### Comparative analysis of echocardiographic parameters after 1 and 3 months of PPM implantation among the whole cases (70 patients):

Regarding diastolic function by pulsed wave Doppler PWD: No significant change in E wave deceleration time ( $p=0.752$ ), while there was significant decrease in E/e' ratio ( $p<0.001$  \*).

Significant increase in myocardial performance index Tei index ( $p<0.001$  \*).

Regarding internal dimensions and systolic function: There was significant increase in the following: Left Atrial Dimension (LAD) ( $p=0.001$  \*), left ventricular end systolic dimension

LVESD ( $p < 0.001$  \*) and left ventricular end diastolic dimension LVEDD ( $p < 0.001$  \*) while there was significant decrease in ejection fraction EF ( $p < 0.001$  \*) and fractional shortening FS ( $p < 0.001$  \*).

*Regarding parameters of LV dyssynchrony:* There was significant increase in the following: Aortic pre-ejection delay APED ( $p < 0.001$  \*), interventricular mechanical delay ( $p < 0.001$  \*) and septal posterior wall motion delay SPWMD by M mode ( $p < 0.001$  \*).

*Regarding parameters assessed by tissue synchronization imaging TSI:* There was significant increase in the following: SD-Ts ( $p = 0.001$  \*) and

all segments Max delay ( $p = 0.027$  \*), while there was no significant change in the following: Septal posterior delay ( $p = 0.688$ ) and septal to lateral delay ( $p = 0.528$ ).

*Regarding parameters assessed by STE:* There was significant decrease in global longitudinal strain GLS ( $p = 0.034$  \*) while there was significant increase in TP-SD by STE ( $p < 0.001$  \*).

Also in the two studied groups VVI and DDD after 1 and 3 months of pacemaker implantation there is significant increase in most of LV dyssynchrony parameters and decrease in LV GLS by 2D STE.

Table (3): Comparative analysis of echocardiographic parameters after 1 and 3 months of PPM implantation among the whole studied population (70 patients).

	1 month (n=70)	3 month (n=70)	t	p
• E DT	230.41±79.65	228.31±84.53	0.317	0.752
• E/e' ratio	11.07±4.4	9.24±3.65	9.844	<0.001 *
• Tei index	0.69±0.2	0.78±0.22	5.113	<0.001 *
• LAD	3.97±0.57	4.03±0.56	3.308	0.001 *
• LVEDD	5.45±0.61	5.67±0.66	8.345	<0.001 *
• LVESD	3.75±0.59	3.95±0.66	7.415	<0.001 *
• EF	60.36±8.39	56.3±8.6	10.339	<0.001 *
• FS	32.53±5.74	29.63±5.74	8.887	<0.001 *
• APED	136.56±27.97	151.11±25.44	6.729	<0.001 *
• IVMD	30.04±21.78	36.61±21.58	4.416	<0.001 *
• SPWMD by M Mode	79.43±36.6	93.71±46.88	3.698	<0.001 *
• SD Ts by TSI	53.89±19.14	59.8±18.37	3.632	0.001 *
• Septal posterior delay by TSI	30.41±74.11	25.7±84.14	0.404	0.688
• All segments Max delay by TSI	164.13±54.2	174.99±50.83	2.262	0.027*
• Septal to lateral delay by TSI	23.63±77.53	15.59±88.07	0.634	0.528
• GLS by STE	-15.96±7.29	-14.25±3.4	2.160	0.034*
• TP SD by STE	35.04±20.47	47.94±23.92	5.522	<0.001 *

N : Number.  
 t : Student t-test.  
 p : Probability value.  
 \* : Significant value >0.05.  
 DT : Deceleration Time.  
 LAD : Left Atrial Dimension.  
 LVEDD : Left Ventricular End Diastolic Dimension.  
 LVESD : Left Ventricular End Systolic Dimension.  
 EF : Ejection Fraction.  
 FS : Fractional Shortening.  
 APED : Aortic Pre-Ejection Delay.  
 IVMD : Inter-Ventricular Mechanical Delay.  
 SPWMD : Septal Posterior Wall Motion Delay.  
 TSI : Tissue Synchronization Imaging.  
 SD-Ts : Standard Deviation of time to peak systolic velocity.  
 GLS : Global Longitudinal Strain.  
 STE : Speckle Tracking Echocardiography.  
 TP SD : Standard Deviation of time to peak strain.

Table (4): Comparative analysis of echocardiographic parameters after 1 and 3 months of PPM implantation in DDD group.

	1 month (n=40)	3 month (n=40)	t	p
• E DT	215.35±69.74	225.28±75.44	1.280	0.208
• E/e' ratio	10.23±3.85	8.58±2.99	6.570	<0.001 *
• Tei index	0.73±0.22	0.78±0.21	3.668	0.001 *
• LAD	3.85±0.52	3.92±0.56	2.421	0.020*
• LVEDD	5.47±0.62	5.72±0.66	6.520	<0.001 *
• LVESD	3.81±0.63	4.01±0.71	5.965	<0.001 *
• EF	58.93±8.61	54.75±8.84	7.318	<0.001 *
• FS	31.35±5.74	28.7±5.77	5.239	<0.001 *
• APED	133.63±28.71	148.25±27.01	5.689	<0.001 *
• IVMD	28.68±22.72	36.35±23.78	5.476	<0.001 *
• SPWMD by M Mode	73.75±31.78	89.5±44.43	3.348	0.002*
• SD Ts by TSI	53.9±19.16	59.4±18.45	2.460	0.018*
• Septal posterior delay by TSI	42.35±70.63	28.35±84.52	0.976	0.335
• All segments Max delay by TSI	163.5±53.47	172.1±47.04	1.279	0.208
• Septal to lateral delay by TSI	13.8±74.53	3.48±83.31	0.600	0.552
• GLS by STE	-15.41±3.88	-14.08±3.93	6.058	<0.001 *
• TP SD by STE	37.7±21.04	49.25±25.75	3.719	0.001 *

N : Number.  
 t : Student t-test.  
 p : Probability value.  
 \* : Significant value >0.05.  
 DT : Deceleration Time.  
 LAD : Left Atrial Dimension.  
 LVEDD : Left Ventricular End Diastolic Dimension.  
 LVESD : Left Ventricular End Systolic Dimension.  
 EF : Ejection Fraction.  
 FS : Fractional Shortening.  
 APED : Aortic Pre-Ejection Delay.  
 IVMD : Inter-Ventricular Mechanical Delay.  
 SPWMD : Septal Posterior Wall Motion Delay.  
 TSI : Tissue Synchronization Imaging.  
 SD-Ts : Standard Deviation of time to peak systolic velocity.  
 GLS : Global Longitudinal Strain.  
 STE : Speckle Tracking Echocardiography.  
 TP SD : Standard Deviation of time to peak strain.

Table (5): Comparative analysis of echocardiographic parameters after 1 and 3 months of PPM implantation in VVI group.

VVI	1 month (n=30)	3 month (n=30)	t	p
• E DT	250.5±88.45	232.37±96.54	1.656	0.108
• E e ratio	12.19±4.88	10.12±4.28	7.544	<0.001 *
• Tei index	0.65±0.17	0.78±0.24	3.830	0.001 *
• LAD	4.12±0.59	4.17±0.54	2.475	0.019*
• LVEDD	5.41±0.61	5.62±0.66	5.162	<0.001 *
• LVESD	3.67±0.54	3.87±0.6	4.434	<0.001 *
• EF	62.27±7.82	58.37±7.94	7.509	<0.001 *
• FS	34.1±5.42	30.87±5.56	9.119	<0.001 *
• APED	140.47±26.95	154.93±23.08	3.849	0.001 *
• IVMD	31.87±20.7	36.97±18.64	1.735	0.093
• SPWMD by M Mode	87±41.54	99.33±50.17	1.883	0.070
• SD Ts by TSI	53.88±19.44	60.33±18.56	2.701	0.011 *
• Septal posterior delay by TSI	14.5±76.81	22.17±84.93	0.394	0.697
• All segments Max delay by TSI	164.97±56.06	178.83±56.09	2.037	0.051
• Septal to lateral delay by TSI	36.73±80.76	31.73±92.99	0.263	0.794
• GLS by STE	-17.11±2.57	-14.15±2.42	16.118	<0.001 *
• TP SD by STE	31.51±19.47	46.18±21.53	4.109	<0.001 *

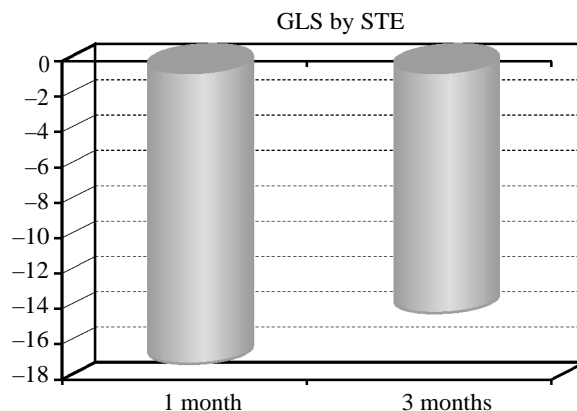


Fig. (3): Global longitudinal strain by speckle tracking imaging after 1 and 3 months of single chamber PPM implantation ( $p<0.001*$ ).

### Discussion

Cardiac pacing is the only effective treatment for symptomatic sinus node disease, and it can improve symptomatic chronotropic incompetence [9]. In addition, numerous studies have demonstrated symptomatic and functional improvement by cardiac pacing in patients with Atrioventricular (AV) block [10].

Sick sinus syndrome and Atrio-Ventricular (AV) conduction disorders still remain the most important indications for cardiac pacing [11].

Right Ventricular (RV) pacing or Left Bundle Branch Block (LBBB) results in a left ventricular (LV) contraction pattern that is dyssynchronous. As a result of the out-of-phase contraction and relaxation of the LV septal and lateral walls, there is a loss of stroke work to internal energy transfer from a contracting wall to the opposite wall that is in relaxation. An additional consequence of the dyssynchronous LV contraction pattern is that the LV lateral wall, which contracts last, is overstretched and performs a disproportionate fraction of the total stroke work [12].

The concept of 'pacing-induced' cardiomyopathy (CMP) has been applied to describe the condition characterized by LV dilatation and hypokinesia, often with symptoms of heart failure, associated with a high burden of RV pacing. However, pacing-induced CMP has not been specifically included in classification schemes of cardiomyopathies, nor has its definition been fully established [13].

Echocardiographic assessment of LV dyssynchrony has been extensively used because it is noninvasive, widely available, and has no known risk or side effect. Most of the assessment modalities used Tissue Doppler Imaging (TDI) [14,15].

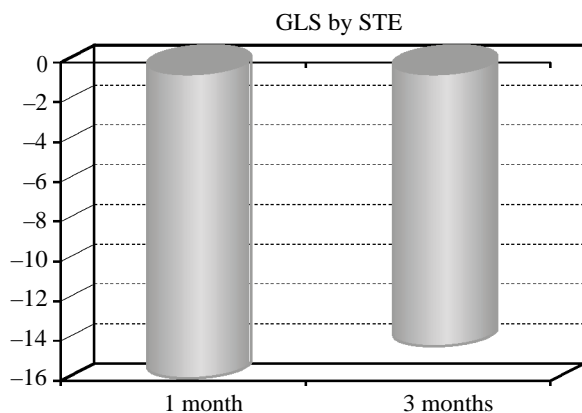


Fig. (1): Change in GLS by STE among all studied cases after 1 and 3 months of PPM implantation ( $p=0.034*$ ).

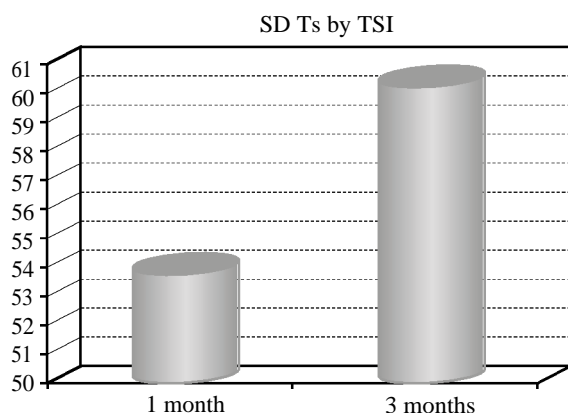


Fig. (2): Standard deviation of time to peak systolic velocity by tissue synchronizing imaging after 1 and 3 months of dual chamber PPM implantation ( $p=0.018*$ ).

However, more recent studies have employed the use of Speckle-Tracking Echocardiography (STE) and 3-Dimensional (3D) echocardiography [16].

The use of Two-Dimensional (2D) STE is an established approach to assess LV dyssynchrony. Two-Dimensional STE utilizes 2D gray scale images to identify discrete speckle patterns within myocardium, and then tracks the motion of these speckles from frame to frame to quantify myocardial deformation [7,17].

The assessment of LV dyssynchrony has gradually shifted towards a 3D approach, providing more comprehensive information about LV mechanics as a whole. Three-dimensional echocardiography with regional volumetric analysis is the initial 3D technique to assess LV dyssynchrony [18].

We therefore performed this study to evaluate LV mechanical dyssynchrony and LV function in different pacing modes after permanent cardiac pacing by using TDI and speckle tracking echocardiography.

We studied LV dyssynchrony and function by using the following parameters: PWD, TDI, SPWMD by M mode, aortic pre-ejection delay, interventricular mechanical delay, TSI (septal to lateral delay, septal to posterior delay and SD-Ts), 2D STE (TP-SD and global longitudinal strain).

The study findings showed that most of LV dyssynchrony parameters were affected (increased) after cardiac pacing whatever the pacing mode is; either single or dual chamber pacing. Also, LV function assessed by 2D STE was affected by cardiac pacing, GLS decreased after permanent pacemaker implantation after 1 and 3 months of implantation.

Algazzar et al., [19] found that mitral deceleration time showed a statistically significant difference between two modes of cardiac pacing (VVI and DDD) only at 6 months ( $p$ -value of 0.01). Doppler patterns of mitral inflow reflect the pressure gradient between the left atrium and LV; transmitral velocities are directly related to left atrial pressure (preload) and independently and inversely related to ventricular relaxation.

Our study revealed significant increase in myocardial performance index Tei index ( $p<0.001^*$ ). Agree with us, Algazzar et al., [19] who found increase in Myocardial Performance Index (MPI) in both groups (VVI & DDD) with statistically significant difference between both groups at 6 months ( $p$ -value of 0.03).

In our study there was significant increase in the following: Left Atrial Dimension (LAD) ( $p=0.001^*$ ), left ventricular end systolic dimension LVESD ( $p<0.001^*$ ) and left ventricular end diastolic dimension LVEDD ( $p<0.001^*$ ), while there was significant decrease in ejection fraction EF ( $p<0.001^*$ ) and fractional shortening FS ( $p<0.001^*$ ).

Lieberman et al., [20] studied a group of patients with preserved LV ejection fraction, RV apical pacing induced a moderate decrease in LV ejection fraction (from  $51 \pm 12\%$  to  $48 \pm 14\%$ ,  $p$ =non significant), whereas the LV dimensions remained unchanged.

In our study there was significant increase in the following: Aortic pre-ejection delay APED ( $p<0.001^*$ ), interventricular mechanical delay ( $p<0.001^*$ ) and septal posterior wall motion delay SPWMD by M mode ( $p<0.001^*$ ).

Tops et al., [4] studied 55 patients and found that after long-term RV pacing, mean SPWMD was  $121 \pm 64$ ms (range 11 to 240ms). In 27 patients (49%) a SPWMD  $\geq 130$ ms was present indicating LV dyssynchrony. Also, interventricular mechanical delay revealed a significant increase in the patients with LV dyssynchrony after long-term RV pacing ( $25 \pm 12$ ms vs.  $49 \pm 19$ ms,  $p<0.05$ ). In 19 patients (70%) with LV dyssynchrony, an interventricular delay  $\geq 40$ ms was present after long-term RV pacing, indicating the presence of interventricular dyssynchrony.

Also, Alhous et al., [21] stated that in a study done on 25 patients, three exhibited SPWMD  $\geq 130$ ms at baseline. With right ventricular apical pacing increased SPWMD and the number of patients with intra-ventricular dyssynchrony using this method increased to six. Also, right ventricular pacing resulted in an increased IVMD in comparison with baseline and in five patients IVMD was  $\geq 40$ ms.

In our study there was significant decrease in global longitudinal strain GLS ( $p=0.034^*$ ), while there was significant increase in TP-SD by STE ( $p<0.001^*$ ).

Ha et al., [22] stated that during the follow-up periods after permanent pacing, lower peak global systolic strain (GLS) of LV was the only independent predictor for LV dyssynchrony (OR 1.252, 95% Confidence Interval [CI] 1.059-1.481,  $p=0.009$ ) which leads to development of PICM. So patients with lower GLS value could be at risk of PICM and need more close monitoring of transthoracic echocardiography for developing PICM.

Our study revealed significant increase in the following: SD-Ts ( $p=0.001^*$ ) and all segments Max delay ( $p=0.027^*$ ).

Agree with our results Pastore et al., [23] who assessed LV dyssynchrony using tissue Doppler echocardiography at baseline and after at least 24h (mean  $1.7\pm 0.3$  days) of continuous RV apical pacing, a total of 101 patients (66%) exhibited significant LV dyssynchrony.

Also, agree with our study DAI et al., [6] whom said that in a study done on 20 patients, the descriptive analysis of TDI-derived LV dyssynchrony indices revealed Ts-SD in DDD and VVI modes was  $42.3\pm 9.7$  and  $46.1\pm 5.6$  msec respectively while the Ts-Dif in DDD and VVI modes was  $106\pm 23.6$  and  $112\pm 28.7$  msec respectively. So, significant increase in Ts-SD after pacemaker implantation whatever the pacing mode either VVI or DDD.

#### Study limitations:

Some limitations should be declared. The small sample size was an important shortcoming of the current study. It should be noted that a limited number of patients met the inclusion criteria and were enrolled into the study. This small sample size could reduce the statistical power of our analyses. Short term follow-up period.

Comparison of the different pacing modes only, not taking into consideration different pacing sites (RV apical pacing; RV septal pacing either low, mid or high; His bundle pacing). RT3DE and 3D STE needed for more evaluation. The need for correlation of study results regarding LV dyssynchrony with primary clinical end points as HF symptoms, the need for hospitalization and mortality.

#### Conclusion:

The new modalities in echocardiography as GLS and 2D STE can help in detection of subclinical left ventricular dysfunction after permanent pacemaker implantation before appearance of symptoms. Also, cardiac pacing leads to LVMD whatever the pacing mode is which may needs later on upgrading to cardiac resynchronization therapy CRT.

### References

- 1- SWEENEY M.O., HELLKAMP A.S., ELLENBOGEN K.A., GREENSPON A.J., FREEDMAN R.A., LEE K.L. and LAMAS G.A.: MOde Selection Trial (MOST) Investigators: Adverse effect of ventricular pacing on heart failure and atrial fibrillation among patients with normal baseline QRS duration in a clinical trial of pacemaker therapy for sinus node dysfunction. *Circulation*, 107: 2932-7, 2003.
- 2- TOPS L.F., SUFFOLETTO M.S., BLEEKER G.B., BORSMA E., VAN DER WALL E.E., GORCSAN J. III, SCHALIJ M.J. and BAX J.J.: Speckle-tracking radial strain reveals left ventricular dyssynchrony in patients with permanent right ventricular pacing. *J. Am. Coll. Cardiol.*, Vol. 50, No. 12, (September 2007), pp. 1180-8, 2007.
- 3- MANOLIS A.S.: The deleterious consequences of right ventricular apical pacing: Time to seek alternate site pacing. *Pacing. Clin. Electrophysiol.*, 29: 298-315, 2006.
- 4- TOPS L.F., SCHALIJ M.J., HOLMAN E.R., VAN ERVEN L., VAN DER WALL E.E. and BAX J.J.: Right ventricular pacing can induce ventricular dyssynchrony in patients with atrial fibrillation after atrioventricular node ablation. *J. Am. Coll. Cardiol.*, 48: 1642-8, 2006.
- 5- CHO G.Y., SONG J.K. and PARK W.J.: Mechanical dyssynchrony assessed by tissue Doppler imaging is a powerful predictor of mortality in congestive heart failure with normal QRS duration. *J. Am. Coll. Cardiol.*, 46: 2237-43, 2005.
- 6- DAI M., LU J., QIAN D., CAI J., LIU X., WU X., YANG Z., LI X. and WANG R.: Assessment of left ventricular dyssynchrony and cardiac function in patients with different pacing modes using real-time three-dimensional echocardiography: Comparison with tissue Doppler imaging. *Experimental and Therapeutic Medicine*, 6: 1213-9, 2013.
- 7- SUFFOLETTO M.S., DOHI K., CANNESON M., SABA S. and GORCSAN J. 3rd: Novel speckle-tracking radial strain from routine black-and-white echocardiographic images to quantify dyssynchrony and predict response to cardiac resynchronization therapy. *Circulation*, 113: 960-8, 2006.
- 8- BARONAITE-DŪDONIENE K., VASKELYTE J., PUODZIUKYNAS A, ZABIELA V, KAZAKEVICIUS T. and SAKALYTE G.: Evaluation of left ventricular longitudinal function and synchrony after dual chamber pacemaker implantation. *Medicina*, 50: 340-4, 2014.
- 9- EPSTEIN A.E., DiMARCO J.P., ELLENBOGEN K.A., et al.: ACC/AHA/HRS 2008 guidelines for device-based therapy of cardiac rhythm abnormalities: A report of the American College of Cardiology/American Heart Association Task Force on Practice Guidelines (Writing Committee to Revise the ACC/AHA/NASPE 2002 Guideline Update for Implantation of Cardiac Pacemakers and Antiarrhythmia Devices). *J. Am. Coll. Cardiol.*, 51: e1-62, 2008.
- 10- BAROLD S. S.: Indications for permanent cardiac pacing in first-degree AV block: Class I, II, or III? *Pacing Clin. Electrophysiol.*, 19: 747-51, 1996.
- 11- MOND H.G., IRWIN M., MORILLO C. and ECTOR H.: The world survey of cardiac pacing and cardioverter defibrillators: Calendar year 2001. *Pacing. Clin. Electrophysiol.*, 27: 955-64, 2004.
- 12- KIEHL E.L., MAKKI T., KUMAR R., et al.: Incidence and predictors of right ventricular pacing-induced cardiomyopathy in patients with complete atrioventricular block and preserved left ventricular systolic function. *Heart Rhythm.*, 13: 2272-8, 2016.

- 13- McKENNA W.J., MARON B.J. and THIENE G.: Classification, epidemiology, and global burden of cardiomyopathies. *Circ. Res.*, 121: 722-30, 2017.
- 14- CHO G.Y., KIM H.K., KIM Y.J., et al.: Electrical and mechanical dyssynchrony for prediction of cardiac events in patients with systolic heart failure. *Heart*, 96: 1029-32, 2010.
- 15- WO H.T., CHANG P.C., CHEN T.H., et al.: Cardiac resynchronization therapy in patients with and without atrial fibrillation. *Acta Cardiol. Sin.*, 27: 46-51, 2011.
- 16- TANAKA H., NESSER H.J., BUCK T., et al.: Dyssynchrony by speckle-tracking echocardiography and response to cardiac resynchronization therapy: Results of the speckle tracking and resynchronization (STAR) study. *Eur. Heart J.*, 31: 1690-700, 2010.
- 17- DELGADO V., YPENBURG C., VAN BOMMEL R.J., et al.: Assessment of left ventricular dyssynchrony by speckle tracking strain imaging comparison between longitudinal, circumferential, and radial strain in cardiac resynchronization therapy. *J. Am. Coll. Cardiol.*, 51: 1944-52, 2008.
- 18- KAPETANAKIS S., KEARNEY M.T., SIVA A., et al.: Real-time three-dimensional echocardiography: A novel technique to quantify global left ventricular mechanical dyssynchrony. *Circulation*, 112: 992-1000, 2005.
- 19- ALGAZZAR A.S., MOHARRAM M.A., KATTA A.A., SOLTAN G.M. and ABD ELAZIZ W.F.: Comparison of early effects of right ventricular apical pacing on left ventricular functions in single and dual chamber pacemakers. *The Egyptian Heart Journal*, 67: 129-35, 2015.
- 20- LIEBERMAN R., PADELETTI L., SCHREUDER J., JACKSON K., MICHELUCCI A., COLELLA A., EASTMAN W., VALSECCHI S. and HETRICK D.A.: Ventricular pacing lead location alters systemic hemodynamics and left ventricular function in patients with and without reduced ejection fraction. *J. Am. Coll. Cardiol.*, 48: 1634-41, 2006.
- 21- ALHOUS M.H., SMALL G.R., HANNAH A., HILLIS G.S. and BROADHURST P.: Impact of temporary right ventricular pacing from different sites on echocardiographic indices of cardiac function. *Europace*, 13: 1738-46, 2011.
- 22- HA S.J., SONG Y.J., LEE W.K., BANG W.D., YOO S.Y. and CHEONG S.S.: Global longitudinal strain improves prediction of right ventricular pacing induced left ventricular dyssynchrony in patients with permanent pacemaker. *European Heart Journal*, (38): 1; P1676, 2017.
- 23- PASTORE G., NOVENTA F., PIOVESANA P., et al.: Left ventricular dyssynchrony resulting from right ventricular apical pacing: Relevance of baseline assessment. *Pacing. Clin. Electrophysiol.*, 31: 1456-62, 2008.

## تقييم عدم تزامن البطين الأيسر بعد منظم القلب الإصطناعي الدائم باستخدام التتبع الرقطي لصدى القلب

إختيار النوع الأفضل في المنظمات الإصطناعية لعلاج مرضى إنقطاع التوصيل الكهربائي يعتبر أمر هام على الرغم من أن تركيب المنظمات الإصطناعية الأحادي والثنائي الحجرات بالقلب يزيد من إحتماليه حدوث هبوط في وظائف القلب. ويعتبر استخدام التتبع الرقطي لصدى القلب لقياس الإجهاد الطولى لعضلة القلب من الطرق الدقيقة في قياس الإختلال التزامنى للبطين الأيسر. لذا فإن تقييم الإختلال التزامنى ووظيفة البطين الأيسر في مرضى المنظمات الإصطناعية يساعد في كيفية إختيار نوع المنظم الإصطناعي المستخدم وكذلك في التنبؤ بإحتمالية حدوث تدهور في وظائف القلب ويساعد أيضاً في محاولة التغيير في برمجة المنظم لتقليل الإختلال التزامنى للبطين الأيسر. تهدف الدراسة إلى تقييم إختلال تزامن ووظيفة البطين الأيسر في مرضى نوى المنظمات الإصطناعية الدائمة باستخدام التتبع الرقطي لصدى القلب.

تم إجراء هذه الدراسة بقسم القلب والأوعية الدموية، مستشفى الباطنة التخصصي، جامعة المنصورة. تم إجراء هذه الدراسة في الفترة من أبريل ٢٠١٨ حتى أبريل ٢٠١٩.

شملت هذه الدراسة سبعون مريض نوى منظمات القلب الإصطناعية الدائمة. وتم إستبعاد المرضى الذين يعانون من فشل في وظائف القلب. المرضى الذين سبق لهم تركيب دعامات بالقلب. المرضى نوى الصمامات الإصطناعية بالقلب. المرضى نوى جراحة القلب المفتوح سابقاً.

وتم تقييم المرضى الذين شملتهم الدراسة عن طريق: التاريخ المرضي، الفحص الإكلينيكي الكامل، تقييم الإختلال التزامنى للبطين الأيسر باستخدام تخطيط دوبلر الأنسجة والتتبع الرقطي لصدى القلب.

وقد أثبتت هذه الدراسة حدوث إختلال في وظيفة البطين الأيسر مع عدم تزامن بين البطين الأيمن والأيسر وذلك بعد تركيب المنظم الصناعي الدائم أياً كان نوعه مما إستلزم في بعض الحالات تركيب المنظم الثلاثي للتغلب على مشكلة عدم التزامن.