

Study of the Protective Effect of Nigella Sativa Oil on Tartrazine-Induced Hematological Disorders in Rats

RAMEZ A. BARHOMA, M.D.*; AMIRA M. ELSHAMY, M.D.** and ALAA I. AMER, M.D.***

The Departments of Physiology, Biochemistry** and Pathology***, Faculty of Medicine, Tanta University, Egypt*

Abstract

Background: Tartrazine is a food colorant used in most food products that consumed almost every day. In view of the adverse effects of its excessive ingestion, it is essential to investigate new and safe protection. Nigella sativa oil, by its beneficial medicinal effects may offer a good protective therapy in this issue.

Aim of Study: In this study the possible protective effect of Nigella Sativa Oil (NSO) on hematological disorders induced by tartrazine was investigated.

Material and Methods: Thirty male Wistar rats were included in this study and divided into three groups: Control group (treated by distilled water), tartrazine treated group (20mg/kg/day), Nigella sativa+ tartrazine treated group (10ml NSO/kg/day + tartrazine treatment). Hematological state was evaluated by measuring total Red Blood Cells (RBCs) count, Packed Cell Volume (PCV), Hemoglobin (Hb) concentration, Mean Cell Volume (MCV), Mean Corpuscular Hemoglobin (MCH), Mean Corpuscular Hemoglobin Concentration (MCHC), Total White Blood cells (WBCs) count and total platelets count. Moreover, oxidative markers; Malondialdehyde (MDA) and reduced glutathione (GSH), were measured in kidney, spleen, Bone Marrow (BM) and RBCs. In addition, bone marrow was examined for histopathological changes.

Results: Tartrazine significantly decreased RBCs count, Hb content, PCV, total WBCs count, lymphocytic, monocytic and granulocytic counts, and significantly increased the MCV, MCH and the platelet count, it also significantly decreased GSH, and increased MDA levels in RBCs, kidney, spleen and BM tissues. Histopathological examination provoked increased number of megakaryocytes and occurrence of myelofibrosis in BM of tartrazine group. Treatment with Nigella sativa oil significantly improved all the tartrazine-induced disturbances.

Conclusion: The findings of the current study revealed that Nigella sativa oil improved the tartrazine-induced hematological disorders, most probably through its antioxidant properties.

Key Words: *Nigella sativa oil – Tartrazine – Hematological disorders – Antioxidant properties.*

Introduction

IN the last several years, great attention has been paid to assessing the toxic effects of food additives and colorants. Food colorant is any dye that shows its color when added to the food or non-food items such as drugs and pharmaceuticals [1,2]. Among the food colorants, tartrazine is considered to be very toxic to humans when consumed in excess amount [3-6].

Tartrazine (also known as FD &C Yellow 5 and/or E102) is a water soluble synthetic lemon-yellow dye, commonly used as a food colorant [7-9]. It is used in food products that consumed almost every day such as soft drinks, flavored chips, cereals, cake mixes, pastries, custard powder, jelly, sauces, powdered drink mixes, ice cream, candy, chewing gum, yogurt, noodles, potato chips, biscuits [10], and other non-food products like soaps, cosmetics, shampoos and some medications [11].

However, long-term or excessive ingestion of tartrazine has been reported to induce several side effects [11-16], such as allergic reactions, renal and hepatic impairment [10]. Also, it has been reported that tartrazine induce chromosomal aberration, carcinogenic and mutagenic effects in mammalian cells, as well as learning and memory loss and behavioral changes in animals [8,11,17,18]. These adverse effects vary depending on the route of administration and the administered dose [8]. Tartrazine toxicity may results directly or indirectly from its metabolic products [19], as some metabolites of tartrazine can generate reactive oxygen species, producing oxidative stress, that affect hepatic and renal architectures and biochemical profiles [20].

Correspondence to: Dr. Ramez A. Barhoma,
[E-Mail: ramez.barhoma@gmail.com](mailto:ramez.barhoma@gmail.com)

Nigella sativa (also known as black cumin), is an annual plant belongs to the botanical family of Ranunculaceae [21]. It commonly grows in Europe, Middle East and Western Asia but commonly used in the Middle East, North Africa and India as a traditional medicine for a wide range of diseases including headache, bronchial asthma, gastrointestinal problems, dysentery, infections, back pain and hypertension [22,23].

The *Nigella sativa* oil has many beneficial medicinal effects, such as acting as an antioxidant, carminative, anti-tumor, diuretic, anti-hyperlipidemic and anti-inflammatory agent [24-26].

The pharmacological investigations of the effect of *Nigella sativa* oil on hematological factors are few; nevertheless, the effect of *Nigella sativa* oil on tartrazine induced hemato-immunological alterations in rats had not been studied yet. So, the present study aimed to investigate the effect of *Nigella sativa* oil on some hematological parameters in presence of tartrazine.

Material and Methods

Chemicals:

Tartrazine was purchased from Sigma-Aldrich Co. (St. Louis, MO, USA), whereas *Nigella sativa* oil was purchased from Al-Nasr Press for Natural Oils, (Giza, Egypt). All the used kits were obtained from Bio-Diagnostic Co. (Giza, Egypt).

Animals and study design:

This work was carried out at Tanta Faculty of Medicine, from Mars 2019 to June 2019, according to guidelines of the Ethical Committee of Medical Research, Faculty of Medicine, Tanta University, Egypt.

30 male Wistar rats, weighing 200-220g., were purchased from the Experimental Animal House, Faculty of Science, Tanta University. The rats were kept in clean cages (5 rats per cage) under controlled environmental conditions, 12/12h. light/dark cycle, at room temperature ($23 \pm 2^\circ\text{C}$), with free access to water and food.

Rats were divided randomly into 3 groups, 10 rats per each group.

- *Group 1:* Control group, rats were gavaged with 1 ml distilled water, daily as a vehicle.
- *Group 2:* Tartrazine treated group, rats received a daily dose of tartrazine (20mg/kg body weight), dissolved in 1ml distilled water, by oral gavage [27]. This dose was considered to be effective, as

it exceeds the acceptable daily intake [28], and not lethal because, it still far from the lethal dose [29].

- *Group 3:* *Nigella sativa* + tartrazine treated group, received the same dose of tartrazine, as in group 2, beside a daily dose of 10ml/kg body weight *Nigella sativa* oil [30].

All medications were given daily for 60 days, and in order to optimize doses; animals were fasted for 1 hour prior to doses administration.

Blood and tissue collection:

At the end of the experiment, and after 24 hours from the last medication, rats in all groups were anaesthetized with 60mg/kg ketamine with 6mg/kg xylazine injected intraperitoneally [31], midline laparotomy was performed and blood samples were collected, from each rat, immediately from the heart through cardiac puncture.

Each blood sample was divided into two parts. The first was placed in EDTA tubes for hematological evaluations, and the second was placed in citrated tubes and prepared for determination of oxidative markers in erythrocyte.

Also, parts from kidneys and spleens were immediately dissected out and prepared for determination of oxidative markers in their tissues. Then femurs were excised for determination of oxidative markers and histopathology examination of bone marrow, and finally the animals were sacrificed by cervical dislocation.

Hematological evaluations:

Blood samples in EDTA containing test tubes was used to measure total Red Blood Cells (RBCs) count, Packed Cell Volume (PCV), Hemoglobin (Hb) concentration, Mean Cell Volume (MCV), Mean Corpuscular Hemoglobin (MCH), Mean Corpuscular Hemoglobin Concentration (MCHC), total White Blood Cells (WBCs) count, lymphocytic, monocytic, and granulocytic counts and total platelets count using an automatic hematological assay analyzer (BC-2800 VET mindray auto hematology analyzer).

Determination of oxidative markers in erythrocytes:

Citrated blood samples were centrifuged, and the packed red blood cells were washed twice with isotonic saline to remove the buffy coat. Then, the packed cells were subjected to hemolysis according to the method of Dodge et al., [32] then centrifuged at 12000rpm, for 40-45min, at 4°C . The supernatant was used for the measurement of reduced Glutathione (GSH) and Malondialdehyde (MDA) using

GSH and MDA assay kits, based on the spectrophotometric methods as described by Akerboom and Sies [33], and Janero [34], respectively.

Determination of oxidative markers in kidney and spleen:

Weighted pieces from kidneys and spleens were homogenized in sodium phosphate buffer (pH 7.4) to measure reduced Glutathione (GSH), and Malondialdehyde (MDA), using GSH and MDA assay kits, according to the previous methods [33,34].

Determination of oxidative markers in bone marrow:

Bone marrow cells were obtained from the excised femurs by flushing technique [35], then they were centrifuged at 2500rpm for 7 minutes and the supernatant was collected for measurement of GSH and MDA, using GSH and MDA assay kits, according to the previous methods [33,34].

Histopathological examination of bone marrow:

Excised femurs were fixed in 10% buffered formalin, then, decalcified in 5% EDTA for 10 days, and finally, specimens were embedded in paraffin, followed by sectioning into slices 8 micrometers thickness. Tissue sections were stained with hematoxylin and eosin and evaluated by light microscopy at X40 magnifications [36].

Statistical calculations:

Collected data were statistically analyzed by one-way ANOVA, followed by Tukey test, to determine statistical significance between different groups using Statistical Package for Social Sciences (SPSS) software, version 23.0 (SPSS Inc., Chicago, IL, USA). Data was presented as mean \pm SD, and $p < 0.05$ was considered statistically significant.

Results

Effect of tartrazine and Nigella sativa oil on hematological parameters:

Administration of tartrazine significantly decreased the RBCs count, Hb content, PCV, total WBCs count, lymphocytic, monocytic and granulocytic counts while, it significantly increased the MCV, MCH and the platelet count, when compared with those of control group. Treatment with Nigella sativa oil improved all these parameters as it significantly increased the RBCs count, Hb content, PCV, total WBCs count, lymphocytic, monocytic and granulocytic counts. Also, it significantly decreased the MCV, MCH and the platelet count, when compared with those of tartrazine group (Table 1).

Effect of tartrazine and Nigella sativa oil on oxidative stress markers: The GSH levels in RBCs, kidney, spleen and bone marrow were significantly reduced, while their MDA levels were significant elevated, following tartrazine administration, when compared to those of control group. However, treatment of rats with Nigella sativa oil together with tartrazine, significantly elevated GSH levels, and, significantly reduced MDA levels in erythrocytes, kidney, spleen and bone marrow when compared to those of tartrazine group (Table 2).

Bone marrow histopathological observations:

Bone marrow from control rats showed normal cell morphology Fig. (1A). While, those from tartrazine treated rats showed abnormalities in the form of increased numbers of Megakaryocytes (MKs) and appearance of myelofibrosis Fig. (1B,C). These abnormalities were completely improved and cell morphology returns to normal after treatment with Nigella sativa oil Fig. (1D).

Table (1): Hematological parameters for all groups.

Parameters	Control	Tartrazine	Tartrazine + NSO
RBCs ($X 10^6/mm^3$)	6.38 \pm 0.26	5.20 \pm 0.22 ^a	6.14 \pm 0.17
Hb (g/dL)	14.13 \pm 0.53	11.83 \pm 1.02 ^a	13.64 \pm 0.71 ^b
PCV (%)	42.28 \pm 1.84	36.94 \pm 1.35 ^a	40.69 \pm 1.30 ^b
MCV (fl)	65.29 \pm 0.32	73.09 \pm 0.32 ^a	65.31 \pm 0.32 ^b
MCH (Pg)	21.70 \pm 0.31	24.30 \pm 0.32 ^a	21.90 \pm 0.32 ^b
MCHC (g/dL)	32.83 \pm 0.71	33.25 \pm 1.01	32.93 \pm 0.52
Platelet ($X 10^3/mm^3$)	536.30 \pm 6.63	568.50 \pm 8.68 ^a	539.10 \pm 6.64 ^b
WBCs ($X 10^3/mm^3$)	7.96 \pm 0.19	6.50 \pm 0.23 ^a	7.30 \pm 0.23 ^a ^b
Lymphocytes ($X 10^3/mm^3$)	6.65 \pm 0.16	5.41 \pm 0.19 ^a	6.10 \pm 0.19 ^a ^b
Monocytes ($X 10^3/mm^3$)	0.51 \pm 0.03	0.42 \pm 0.03 ^a	0.47 \pm 0.04 ^b
Granulocytes ($X 10^3/mm^3$)	0.82 \pm 0.02	0.67 \pm 0.02 ^a	0.75 \pm 0.02 ^a ^b

Values are presented as the mean \pm SD (n=10).

^a : $p < 0.05$ vs. control group.

^b : $p < 0.05$ vs. tartrazine group.

RBCs : Total Red Blood Cells count.

PCV : Packed Cell Volume.

Hb : Hemoglobin concentration.

MCV : Mean Cell Volume.

MCH : Mean Corpuscular Hemoglobin.

MCHC : Mean Corpuscular Hemoglobin Concentration.

WBCs : Total White Blood Cell count.

Table (2): Levels of MDA and GSH in RBCs, kidney, spleen and bone marrow tissues for all groups.

Parameters	Control	Tartrazine	Tartrazine + NSO
RBCs GSH ($\mu\text{mol/g Hb}$)	9.79 \pm 0.36	4.22 \pm 0.39	9.43 \pm 0.62 ^b
RBCs MDA (nmol /g Hb)	6.19 \pm 0.09	10.35 \pm 0.65 ^a	7.36 \pm 0.23 ^a ^b
Renal GSH ($\mu\text{mol/g protein}$)	13.44 \pm 0.84	8.81 \pm 0.94 ^a	12.58 \pm 0.90 ^b
Renal MDA ($\mu\text{mol/g protein}$)	1.54 \pm 0.23	2.24 \pm 0.15 ^a	1.59 \pm 0.11 ^b
Spleen GSH ($\mu\text{mol/g protein}$)	7.19 \pm 0.16	4.93 \pm 0.55 ^a	7.08 \pm 0.26 ^b
Spleen MDA ($\mu\text{mol/g protein}$)	0.12 \pm 0.06	0.21 \pm 0.01 ^a	0.13 \pm 0.01 ^b
BM GSH ($\mu\text{mol/g protein}$)	23.29 \pm 2.03	12.51 \pm 1.22 ^a	18.22 \pm 2.60 ^a ^b
BM MDA ($\mu\text{mol/g protein}$)	3.22 \pm 0.33	5.85 \pm 0.53 ^a	3.63 \pm 0.35 ^b

Values are presented as the mean \pm SD (n=10).

^a : $p < 0.05$ vs. control group.

^b : $p < 0.05$ vs. tartrazine group.

GSH : Reduced Glutathione.

MDA : Malondialdehyde.

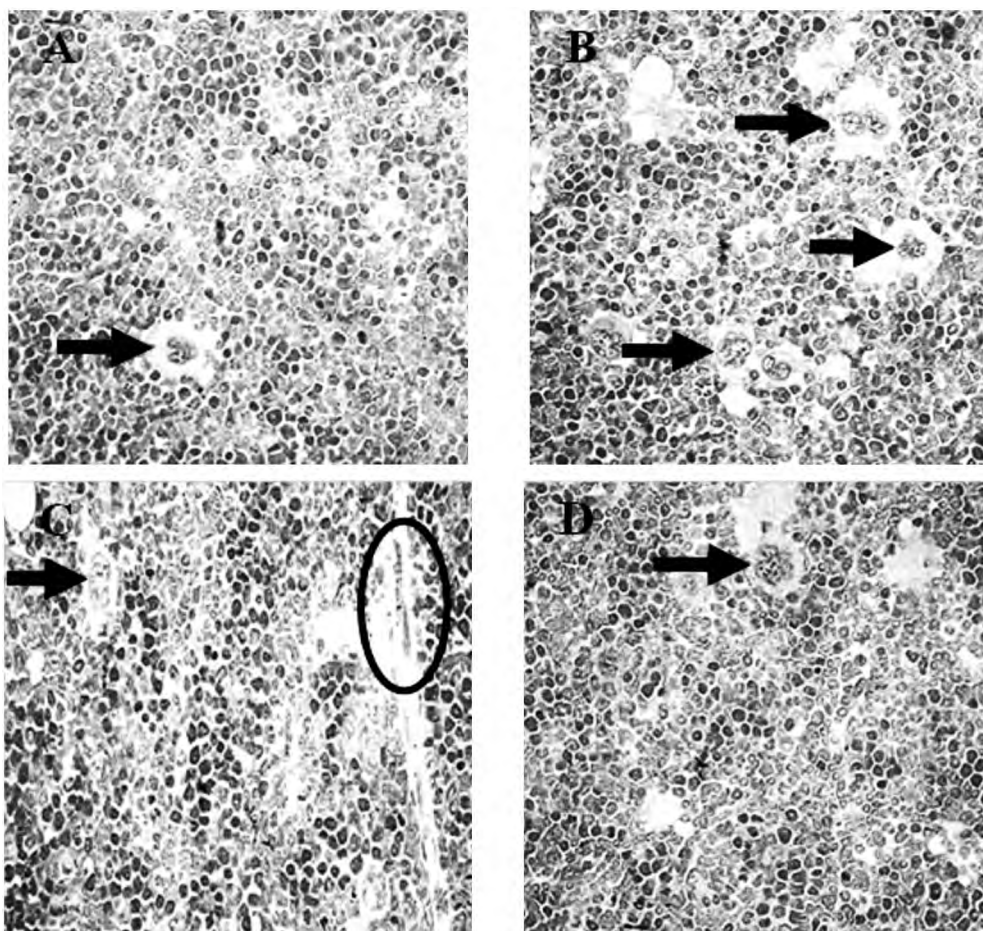


Fig. (1): Bone marrow histopathology (X40). (A) Control group: Normal cell morphology. (B,C) Tartrazine group: Increased number of Megakaryocytes (MKs) indicated by arrows and myelofibrosis indicated by a circle. (D) Nigella sativa treated tartrazine group: Normal cell morphology.

Discussion

The main finding of this study, is that treatment with nigella sativa oil resulted in correction of tetrazine induced hematological alterations and exhibited a notable immune stimulatory effects, as dissected in this current study.

As regarding the hematological parameters, results obtained from the present work revealed a significant alteration in the blood picture indicated by decreased RBCs count, PCV and Hb content upon tartrazine treatment. Moreover, the decreased RBCs count was associated with increased MCV and MCH, with no alteration in the MCHC, refer-

ring to the occurrence of normochromic macrocytic anemia. Similar findings were recorded by previous studies [9,37-40].

These alterations appeared to be mediated through provocation of oxidative stress response as indicated herein by increased MDA and decreased GSH levels in RBCs which could reduce their life span due to oxidation of their membrane phospholipids [41], and in BM which, together with myelofibrosis, may affect the function of hemopoietic stem cells of BM; most probably mediated via different signaling pathways that affect their hemopoietic function as recorded previously [42-44].

In accordance, Battisti et al., [45] and Zhou et al., [46] recorded that oxidative stress could be involved in the pathophysiology of some hematopoietic diseases. Also, oxidative damage has been suggested to be associated with inadequate erythropoietin production [47], which was considered to be the main mechanism of anemia due to impaired erythropoiesis [48].

It has been reported that oxidative stress-related anemia could be mediated via oxidation of erythrocyte membrane phospholipids with subsequent shortening of erythrocyte life span; increased production of liver hepcidin with blocking of intestinal iron absorption and mobilization; reduction in transferrin levels with diminished iron availability and resistance to erythropoietin actions [41].

In addition, tartrazine can inhibit iron absorption by developing RBCs [9], induce conformational alterations and great damage in the helicity of Hb by direct binding with its central cavity [49,50] and interfere with absorption of vitamins and minerals essential for erythropoiesis [51] through producing atrophy of the gastric glands and ulceration of its mucosal lining [30,52].

The renal oxidative stress noted in tartrazine treated rats in the present study came in agreement with, and confirmed by Himri et al., [20] and Mehedi et al., [18] who reported altered renal histological structure in experimental animals treated with tartrazine. Moreover, Amin et al., [10] reported a tartrazine induced significant elevation in renal function tests, and, Rus et al., [53] found that tartrazine causes congestion and edema in the kidney associated with atrophy of renal structures.

Interestingly, co-administration of tartrazine and *Nigella sativa* oil in the present study significantly increasing the RBCs count, PCV and Hb content when compared to tartrazine treated rats,

these findings came in agreement with previous studies [21,54,55].

These findings could be mediated, partially in part, through mitigating redox state, as it significantly decreased MDA and increased GSH levels in RBCs; this attenuation of oxidative stress was shown to decrease susceptibility of RBCs to hemolysis with subsequent increase in their life span [56]. Moreover, antioxidants can improve BM hemopoietic stem cell survival and affect the potency and differentiation of these cells [57,58]. Consistently, *Nigella sativa* significantly increased the bone marrow cellularity [59]. In addition, administration of *nigella sativa* oil to tartrazine treated rats caused regeneration of gastric glands [30,60], possibly via prostaglandin mediated effect or through its antioxidant activity [61]. It also attenuated the renal oxidative stress [26,62], and significantly improved renal functions [63,64].

Regarding WBCs count, our investigations recorded a significant decrease in total WBCs, monocytic, granulocytic and lymphocytic counts of tartrazine treated rats. This could be explained also by the injurious effect of tartrazine on the hemopoietic stem cells of the bone marrow beside the oxidative stress that occurs in the BM and spleen, which are the main sites for their synthesis [65-68], as indicated herein by increased MDA and decreased GSH in BM and splenic tissues of tartrazine treated group compared to control one.

These results came in accordance with those reported by Sharma et al., [9] who revealed a decrease in total leucocytic count after tartrazine treatment which could be due to direct tartrazine toxicity on WBCs. Oxidative stress in spleen of tartrazine-exposed rats was recorded to be accompanied by concomitant diminution of peripheral lymphocytes with decreased proportion of CD8+ T lymphocytes in the spleen which was supposed to be mediated by the deleterious effects of tartrazine on lymphocyte proliferation and induction of cell death [28,38,40].

Notably, treatment with *nigella sativa* oil exhibited a significant increase in total WBCs, monocytic, granulocytic and lymphocytic counts, together with correction of bone marrow picture when compared to tartrazine treated rats, which could be mediated through attenuating tartrazine induced oxidative stress parameters in splenic and BM tissues.

In line with our findings, treatment with *nigella sativa* was shown to enhance the total WBCs count, significantly increase the weight of the spleen and

the bone marrow cellularity, indicating its immunostimulatory activity [59]. In addition, Nigella sativa extract was reported to increase in the phagocytic activity through its role in stimulating the immune cells and increase the activity of immune potential [69], antioxidant and anti-inflammatory activity which may protect the phagocytic cell [23,70] or by the effect of Nigella sativa on the DNA synthesis during cell proliferation and the ability of scavenging the super oxide radicals [71].

On the other hand, regarding platelet count, our investigations recorded a significant increase in the platelet count of tartrazine treated rats which was in accordance with the study of Golli et al., [28] who suggested that the rise in platelet counts may be reactive or secondary to a pathological condition such as infection, inflammation, iron deficiency or stress [72]. This increase in platelet counts may be attributed to the potentially deleterious effect of this dye, and could lead to a risk of thrombosis and cardiovascular disease [28].

This increased platelet count could be explained by the increased number of megakaryocytes detected in the bone marrow histopathology. It is well established that megakaryocytes give rise to the circulating platelets and there is a relationship between the number of megakaryocytes in the bone marrow and the number of platelets in the circulation [73,74]. However, abnormal proliferation of megakaryocytes can cause malignant diseases like megakaryocytic leukemia, which characterized by proliferation of abnormal megakaryocytes and myelofibrosis [75].

Meanwhile, normalization of platelet count was noted upon nigella sativa treatment and may be a result of normalization of bone marrow megakaryocytes. It was in agreement with the study of George and Kumaran, [21] who reported that nigella sativa oil produced a significant decrease in the platelet count, preventing the monosodium glutamate induced thrombocytosis.

The recorded hematological alteration in this current study (decreased RBCs, WBCs and lymphocytes with increased platelets count), are consistent with the blood picture findings of some hematopoietic diseases like aplastic anemia, myelofibrosis and megakaryocytic leukemia [76-78]. Moreover, high Reactive Oxygen Species (ROS) production can inhibit self-renewal and induce senescence of hematopoietic stem cells, resulting in their rapid exhaustion and hematopoietic dysfunction [79]. And, one of the clinical consequences of hematopoietic stem cells damage is alternation

in the circulating RBCs, WBCs and platelet counts [80]. Therefore, changes in the numbers of circulating blood cells in several relations may reflect toxicity to hematopoietic stem cells [81]. Accordingly, from both blood picture and histopathological findings, we could suggest possible tartrazine induced toxicity to hematopoietic stem cells, and an emerging role of antioxidants, like Nigella sativa oil, in treating tartrazine associated hematological disorders.

Conclusion:

The present study suggests that adverse effects of tartrazine on hematological parameters are most probably due to oxidative stress-induced bone marrow toxicity, and treatment with Nigella sativa oil prevents the altered hematological parameters by its antioxidant effects.

Acknowledgment:

The authors would like to acknowledge the technicians in Biochemistry and Pathology Departments and in the Central Laboratory, Faculty of Medicine, Tanta University, Egypt for their technical assistance.

References

- 1- De BOER L.: Biotechnological production of colorants. *Adv. Biochem. Eng. Biotechnol.*, 143: 51-89, 2014.
- 2- NEWSOME A.G., CULVER C.A. and VAN BREEMEN R.B.: Nature's palette: The search for natural blue colorants. *J. Agric. Food Chem.*, 62: 6498-511, 2014.
- 3- AL-DEGS YS: Determination of three dyes in commercial soft drinks using HPLC/MS and liquid chromatography. *Food Chem.*, 117: 485-90, 2009.
- 4- AXON A., MAY F.E., GAUGHAN L.E., WILLIAMS F.M., BLAIN P.G. and WRIGHT M.C.: Tartrazine and sunset yellow are xenoestrogens in a new screening assay to identify modulators of human oestrogen receptor transcriptional activity. *Toxicology*, 298: 40-51, 2012.
- 5- MPOUNTOUKAS P., PANTAZAKI A., KOSTARELI E., CHRISTODOULOU P., KARELI D., POLILIOU S., MOURELATOS C., LAMBROPOULOU V. and LIALIARIS T.: Cytogenetic evaluation and DNA interaction studies of the food colorants amaranth, erythrosine and tartrazine. *Food Chem. Toxicol.*, 48: 2934-44, 2010.
- 6- NGAH W.S., ARIFF N.F. and HANAFIAH M.A.: Preparation, characterization, and environmental application of crosslinked chitosan-coated bentonite for tartrazine adsorption from aqueous solutions. *Water Air. Soil Pollut.*, 206: 225-36, 2010.
- 7- MITTAL A., KURUP L. and MITTAL J.: Freundlich and langmuir adsorption isotherms and kinetics for the removal of tartrazine from aqueous solutions using hen feathers. *J. Hazard Mater.*, 146 (1-2): 243-8, 2007.
- 8- SASAKI Y.F., KAWAGUCHI S., KAMAYA A., OHSHIMA M., KABASAWA K., IWAMA K., TANIGUCHI K. and TSUDA S.: The comet assay with 8 mouse organs:

- Results with 39 currently used food additives. *Mutat. Res.*, 519: 103-19, 2002.
- 9- SHARMA G., GAUTAM D. and GOYAL R.P.: Tartrazine induced haematological and serological changes in female Swiss albino mice, *mus musculus*. *Pharmacology online*, 3: 774-88, 2009.
 - 10- AMIN K.A. and AL-SHEHRI F.S.: Toxicological and safety assessment of tartrazine as a synthetic food additive on health biomarkers: A review. *Afr. J. Biotechnol.*, 17 (6): 139-49, 2018.
 - 11- AMIN K.A., ABDEL HAMEID H. and ABD ELSTTAR A.H.: Effect of food azo dyes tartrazine and carmoisine on biochemical parameters related to renal, hepatic function and oxidative stress biomarkers in young male rats. *Food. Chem. Toxicol.*, 48 (10): 2994-9, 2010.
 - 12- BASU A. and KUMAR G.S.: Studies on the interaction of the food colorant tartrazine with double stranded deoxyribonucleic acid. *J. Biomol. Struct. Dyn.*, 34 (5): 935-42, 2016b.
 - 13- DEMIRKOL O., ZHANG X. and ERCAL N.: Oxidative effects of Tartrazine (CAS No 1934-21-0) and New Coccin. CAS No. 2611-82-7) azo dyes on CHO cells. *J. Verbr. Lebensm.*, 7: 229-36, 2012.
 - 14- KASHANIAN S. and ZEIDALI S.H.: DNA binding studies of tartrazine food additive. *DNA Cell Biol.*, 30: 499-505, 2011.
 - 15- TANAKA T.: Reproductive and neurobehavioral toxicity study of Tartrazine administered to mice in the diet. *Food Chem. Toxicol.*, 44: 179-87, 2006.
 - 16- TANAKA T., TAKAHASHI O., OISHI S. and OGATA A.: Effects of tartrazine on exploratory behavior in a three-generation toxicity study in mice. *Reprod. Toxicol.*, 26: 156-63, 2008.
 - 17- GAO Y., LI C., SHEN J., YIN H., AN X. and JIN H.: Effect of food azo dye tartrazine on learning and memory functions in mice and rats, and the possible mechanisms involved. *J. Food Sci.*, 76: T125-129, 2011.
 - 18- MEHEDI N., MOKRANE N., ALAMI O., AINAD-TABET S., ZAOUI C., KHEROUA O. and SAIDI D.: A thirteen week ad libitum administration toxicity study of tartrazine in Swiss mice. *Afr. J. Biotechnol.*, 12 (28): 4519-29, 2013.
 - 19- KHAYYAT L., ESSAWY A., SOROUR J. and SOFFAR A.: Tartrazine induces structural and functional aberrations and genotoxic effects in vivo. *Peer J.* 5, e3041, 2017.
 - 20- HIMRI I., BELLAHCEN S., SOUNA F., BELMAKKI F., AZIZ M., BNOUHAM M., ZOHEIR J., BERKIA Z., AZIZ M. and SAALAOUI E.: A 90-day oral toxicity study of tartrazine, a synthetic food dye, in wistar rats. *Int. J. Pharm. Pharm. Sci.*, 31 (3): 159-69, 2011.
 - 21- GEORGE B. and KUMARAN B.: Effect of Nigella Sativa oil against Monosodium Glutamate-Induced Toxicity on Hematological Parameters In Rats. *Int. J. Recent. Sci. Res.*, 7 (6): 11592-6, 2016.
 - 22- CHEIKH-ROUHOUS S., BESBES S., HENTATI B., BLECKER C., DEROANNE C. and ATTIA H.: Nigella sativa L. Chemical composition and physiochemical characteristics of lipid fraction. *Food Chem.*, 101: 673-81, 2007.
 - 23- SALEM M.L.: Immunomodulatory and therapeutic properties of the Nigella sativa L. seed. *Int. Immunopharmacol.*, 5: 1749-70, 2005.
 - 24- ALI B.H. and BLUNDEN G.: Pharmacological and toxicological properties of Nigella sativa. *Phytother. Res.*, 17: 299-305, 2003.
 - 25- BADARY O.A., TAHA R.A., GAMAL EL-DIN A.M. and ABDEL-WAHAB M.H.: Thymoquinone is a potent superoxide anion scavenger. *Drug Chem. Toxicol.*, 26: 87-98, 2003.
 - 26- YAMAN I. and BALIKCI E.: Protective effects of Nigella sativa against gentamicin-induced nephrotoxicity in rats. *Exp. Toxicol. Pathol.*, 62: 183-90, 2010.
 - 27- TAWFEK N. S., AMIN H.M., ABDALLA A.A. and FARGALI S.H.M.: Adverse Effects of some food additives in adult male albino rats. *Curr. Sci. Int.*, 4 (4): 525-37, 2015.
 - 28- GOLLI N.E., BINI-DHOUB I., JRAD A., BOUDALI I., NASRI B., BELHADJHMIDA N. and EL FAZAA S.: Toxicity Induced after Subchronic Administration of the Synthetic Food Dye Tartrazine in Adult Rats, Role of Oxidative Stress. *Recent Adv. Biol. Med.*, 2: 20-8, 2016.
 - 29- AI-MASHHEDY L.A.M. and FIJER A.N.: Acute Toxicity of Food additives Tartrazine and carmoisine on white male Mice. *Int. J. Pharm. Tech. Res.*, 9 (4): 364-7, 2016.
 - 30- AL-SEENI M.N., EL RABEYHA, AL-HAMED A.M. and ZAMAZAMI M.A.: Nigella sativa oil protects against tartrazine toxicity in male rats *Toxicology Reports*, 5: 146-55, 2018.
 - 31- ORDODI V.L., MIC F.A., MIC A.A., TANASIE G., IONAC M., SANDESC D. and PAUNESCU V.: Bone marrow aspiration from rats: A minimally invasive procedure. *Lab. Animal.*, 35 (5): 41-4, 2006.
 - 32- DODGE J.T., MITCHELL G. and HANAHAN D.J.: The preparation and chemical characteristics of hemoglobin-free ghosts of human erythrocytes. *Arch. Biochem. Biophys.*, 100: 119-30, 1963.
 - 33- AKERBOOM T.P. and SIES H.: Assay of glutathione, glutathione disulfide, and glutathione mixed disulfides in biological samples. *Methods Enzymol.*, 77: 373-82, 1981.
 - 34- JANERO D.R.: Malondialdehyde and thiobarbituric acid-reactivity as diagnostic indices of lipid peroxidation and peroxidative tissue injury. *Free Rad. Biol. Med.*, 9: 515-40, 1990.
 - 35- YAHYA N.J., ABD HAMID Z., ABU HANIPAH E.N., AJIK E.M., YUSOFF N.A. and TAIB I.S.: Oxidative stress and morphological assessment of bone marrow in monosodium glutamate-treated rat. *Jurnal Teknologi (Sciences & Engineering)*, 80: 105-11, 2018.
 - 36- APGAR J.M., JUARRANZ A., ESPADA J., VILLANUEVA A., CANETE M. and STOCKERT J.C.: Fluorescence microscopy of rat embryo sections stained with haematoxylin-eosin and Masson's trichrome method. *J. Microsc.*, 191: 20-7, 1998.
 - 37- CHAKRAVARTY G., GOYAL R.P., SHARMA S. and SHARMA A.: Hematological changes induced by a common non-permitted food colour, malachite green (MG) in Swiss albino mice. *Ind. J. Env. Sci.*, 9: 113-7, 2005.

- 38- SHARMA A., GOYAL R.P., CHAKRAVARTY G. and SHARMA S.: Hematotoxic effect of chocolate Brown, a commonly used blend of permitted food colour on Swiss albino mice. *Asian. J. Exp. Sci.*, 19 (2): 93-103, 2005a.
- 39- SHARMA A., GOYAL R.P., CHAKRAVARTY G. and SHARMA S.: Toxicological studies on effect of apple green-A permitted food colour on Swiss albino mice. *Ind. J. Env. Sci.*, 10 (1): 21-4, 2006.
- 40- SHARMA S., GOYAL R.P., CHAKRAVARTY G. and SHARMA A.: Orange red a permitted food colours induced haematological changes in Swiss albino mice, *mus musculus*. *Bull. Pure App. Sci.*, 24A (2): 99-103, 2005b.
- 41- VAZIRI N.D. and ZHOU X.J.: Potential mechanisms of adverse outcomes in trials of anemia correction with erythropoietin in chronic kidney disease. *Nephrol. Dial. Transplant.*, 24: 1082-8, 2009.
- 42- AL-SHINNAWY M.S. and ELKATTAN N.A.: Assessment of the changes in some diagnostic parameters in male albino rats fed on an Azo Dye. *Int. J. Enviro. Sci. Eng.*, 4: 85-92, 2013.
- 43- DENU R.A. and HEMATTI P.: Effects of Oxidative Stress on Mesenchymal Stem Cell Biology. *Oxidative Medicine and Cellular Longevity*, 2989076, 2016.
- 44- LU W.Y. and ZHAO M.F.: Effect of oxidative stress on bone marrow mesenchymal stem cells. *Zhongguo yi xue ke xue Yuan xue Bao*, 34 (1): 90-4, 2012.
- 45- BATTISTI V., MADERS L.D., BAGATINI M.D., SANTOS K.F., SPANEVELLO R.M., MALDONADO P.A., BRULÉ A.O., ARAÚJO M.C., SCHETINGER M.R.C. and MORSCH V.M.: Measurement of oxidative stress and antioxidant status in acute lymphoblastic leukemia patients. *Clin. Biochem.*, 41: 511-8, 2008.
- 46- ZHOU F.L., ZHANG W.G., WEI Y.C., MENG S., BAI G.G., WANG B.Y., YANG H.Y., TIAN W., MENG X., ZHANG H. and CHEN S.P.: Involvement of oxidative stress in the relapse of acute myeloid leukemia. *J. Biol. Chem.*, 285: 15010-5, 2010.
- 47- LANKHORST C.E. and WISH J.B.: Anemia in renal disease: Diagnosis and management, *Blood Rev.*, 24 (1): 39-47, 2010.
- 48- DAENEN K., ANDRIES A., MEKAHLI D., VAN SCHEP-DAEL A., JOURET F. and BAMMENS B.: Oxidative stress in chronic kidney disease. *Pediatr. Nephrol.*, 34 (6): 975-91, 2019.
- 49- BASU A. and KUMAR G.S.: Multispectroscopic and calorimetric studies on the binding of the food colorant tartrazine with human hemoglobin. *J. Hazard Mater.*, 318: 468-76, 2016a.
- 50- LI Y., WEI H. and LIU R.A.: Probe to study the toxic interaction of tartrazine with bovine hemoglobin at the molecular level. *Luminescence*, 29 (2): 195-200, 2014.
- 51- KOURY M.J. and PONKA P.: New insights into erythropoiesis: The roles of folate, vitamin B 12, and iron. *Annu. Rev. Nutr.*, 24 (1): 105-31, 2004.
- 52- SARKAR R. and GHOSH A.A.: Metanil yellow-an azo dye Induced histopathological and ultrastructural changes in albino rat (*Rattus norvegicus*). *Int. Q. J. Life Sci.*, 7 (1): 427-32, 2012.
- 53- RUS V., GHERMAN C., MICLAUS V., MIHALCA A. and NADAS G.: Comparative toxicity of food dyes on liver and kidney in guinea pigs: A histopathological study. *Annals of RSCB*, 15 (1): 161-5, 2010.
- 54- MOHAMED M.A. and AWAD S.M.: Effect of *Nigella Sativa* oil on some hematological values in aluminum-treated rats. *Aust. J. Basic & Appl. Sci.*, 2 (4): 1157-64, 2008.
- 55- YUSUKSAWAD M. and CHAIYABUTR N.: Restoration of renal hemodynamics and functions during black cumin (*Nigella sativa*) administration in streptozotocin-induced diabetic rats. *Journal of Experimental Pharmacology*, 4: 1-7, 2012.
- 56- MERAL I., YENER Z., KAHRAMAN T. and MERT N.: Effect of *Nigella sativa* on glucose concentration, lipid peroxidation, antioxidant defense system and liver damage in experimentally-induced diabetic rabbits. *J. Vet. Med. A Physiol. Pathol. Clin. Med.*, 48: 593-9, 2001.
- 57- SHABAN S., EL-HUSSENY M.W.A., ABUSHOUK A.I., SALEM A.M.A., MAMDOUH M. and ABDEL-DAIM M.M.: Effects of antioxidant supplements on the survival and differentiation of stem cells. *Oxid. Med. Cell Longev.*, 5032102, 2017.
- 58- WAMBI C., SANZARI J., WAN X.S. NUTH M., DAVIS J., KO Y.H., SAYERS C.M., BARAN M., WARE J.H. and KENNEDY A.R.: Dietary antioxidants protect hematopoietic cells and improve animal survival after total-body irradiation. *Radiat. Res.*, 169 (4): 384-96, 2008.
- 59- GHONIME M., ELDOMANY R., ABDELAZIZ A. and SOLIMAN H.: Evaluation of immunomodulatory effect of three herbal plants growing in Egypt. *Immunopharmacol Immunotoxicol.*, 33 (1): 141-5, 2011.
- 60- EL-DAKHAKHNY M., BARAKAT M., ABD EL-HALIM M. and ALY S.M.: Effects of *Nigella sativa* oil on gastric secretion and ethanol induced ulcer in rats, *J. Ethnopharmacol.*, 72: 299-304, 2000.
- 61- AL MOFLEH I.A., ALHAIDER A.A., MOSSA J.S., ALSOHAIBANI M.O., AL-YAHYA M.A., RAFATULLAH S. and SHAIK S.A.: Gastroprotective effect of an aqueous suspension of black cumin *Nigella sativa* on necrotizing agents-induced gastric injury in experimental animals. *Saudi J. Gastroenterol.*, 14 (3): 128-34, 2008.
- 62- UZ E., BAYRAK O., UZ E., KAYA A., BAYRAK R., UZ B., TURGUT F.H., BAVBEK N., KANBAY M. and AK-CAY A.: *Nigella sativa* oil for prevention of chronic cyclosporine nephrotoxicity: An experimental model. *Am. J. Nephrol.*, 28 (3): 517-22, 2008.
- 63- ELKHATEEB A., EL KHISHIN I., MEGAHED O. and MAZEN F.: Effect of *Nigella sativa* Linn oil on tramadol-induced hepato-and nephrotoxicity in adult male albino rats, *Toxicolo. Rep.*, 2: 512-9, 2015.
- 64- MAJEED N. and TAHIR M.: Effect of *Nigella sativa* extract on renal functions in amphotericin induced nephrotoxicity in mice. *Biomedic.*, 30 (1): 1-4, 2014.
- 65- BALOGH P., HORVATH G. and SZAKAL A.K.: Immunohistochemistry of distinct reticular fibroblastic domains in the white pulp of mouse spleen. *J. Histochem. Cytochem.*, 52 (10): 1287-98, 2004.
- 66- CESTA M.F.: Normal Structure, Function, and Histology of the Spleen; *Toxicologic Pathology*, 34: 455-65, 2006.

- 67- NOLTE M.A., HAMANN A., KRAAL G. and MEBIUS R.E.: The strict regulation of lymphocyte migration to splenic white pulp does not involve common homing receptors *Immunology*, 106: 299-307, 2002.
- 68- RIEGER M.A. and SCHROEDER T.: Hematopoiesis. *Cold. Spring Harb. Perspect. Biol.*, 4: a008250, 2012.
- 69- BUNYAMIN S., CELIK I. and TULUCE Y.: The effect of diet supplemented with the black cumin (*Nigella sativa* L.) upon immune potential and antioxidant marker enzymes and lipid peroxidation in broiler chicks. *J. Animal and Veterinary advances*, 7 (10): 1190-9, 2008.
- 70- ABDULELAH H. and ZAINAL-ABIDIN B.: In vivo anti-malarial tests of *Nigella sativa* (Black seed) different extracts. *Am. J. Pharmacol. and Toxicol.*, 2 (2): 46-50, 2007.
- 71- MUSA D., DUISIZ N., GUMUSHAN H., ULAKOGLU G. and MUHARREM B.: Antitumor activity of an ethanol extract of *Nigella Sativa* seeds. *Biologia Bratislava*, 59: 635-70, 2004.
- 72- SULAI N.H. and TEFFERI A.: Why does my patient have thrombocytosis? *Hematol. Oncol. Clin. North Am.*, 26 (2): 285-301, 2012.
- 73- DEUTSCH V.R. and TOMER A.: Megakaryocyte development and platelet production. *Br. J. Haematol.*, 134: 453-66, 2006.
- 74- LONG M.W.: Megakaryocyte differentiation events. *Semin. Hematol.*, 35: 192-9, 1998.
- 75- OKI Y., KANTARJIAN H.M., ZHOU X., CORTES J., FADERL S., VERSTOVSEK S., O'BRIEN S., KOLLER C., BERAN M., BEKELE B.N., PIERCE S., THOMAS D., RAVANDI F., WIERDA W.G., GILES F., FERRAJOLI A., JABBOUR E., KEATING M.J., BUESO-RAMOS C.E., ESTEY E. and GARCIA-MANERO G.: Adult acute megakaryocytic leukemia: An analysis of 37 patients treated at M.D. Anderson Cancer Center Blood, 107: 880-4, 2006.
- 76- CASCIO M.J. and DELOUGHERY T.G.: Anemia: Evaluation and Diagnostic Tests. *Med. Clin. North Am.*, 101 (2): 263-84, 2017.
- 77- GREEN R. and DWYRE D.M.: Evaluation of Macrocytic Anemias. *Semin. Hematol.*, 52 (4): 279-86, 2015.
- 78- ISHII K. and YOUNG N.S.: Anemia of central origin. *Semin Hematol.*, 52 (4): 321-38, 2015.
- 79- SHAO L. LI H., PAZHANISAMY S.K., MENG A., WANG Y. and ZHOU D.: Reactive oxygen species and hematopoietic stem cell senescence. *Int. J. Hematol.*, 94 (1): 24-32, 2011.
- 80- ZHANG L., TANG X., ROTHMAN N., VERMEULEN R., JI Z., SHEN M., QIU C., GUO W., LIU S., REISS B., FREEMAN L.B., GE Y., HUBBARD A.E., HUA M., BLAIR A., GALVAN N., RUAN X., ALTER B.P., XIN K.X., LI S., MOORE L.E., KIM S., XIE Y., HAYES R.B., AZUMA M., HAUPTMANN M., XIONG J., STEWART P., LI L., RAPPAPORT S.M., HUANG H. FRAUMENI, J.F., SMITH M.T. and LAN Q.: Occupational exposure to formaldehyde, hematotoxicity, and leukemia-specific chromosome changes in cultured myeloid progenitor cells. *Cancer Epidemiol. Biomarkers. Prev.*, 19: 80-8, 2010.
- 81- YU G.Y., SONG X.F., LIU Y. and SUN Z.W.: Inhaled Formaldehyde Induces Bone Marrow Toxicity via Oxidative Stress in Exposed Mice *Asian Pac. J. Cancer Prev.*, 15 (13): 5253-7, 2014.

دراسة التأثير الوقائي لزيت حبة البركة على اضطرابات الدم التي يسببها الترتازين في الفئران

الهدف: تهدف هذه الدراسة إلى تقييم التأثير الوقائي المحتمل لزيت حبة البركة على الاضطرابات الدموية الناجمة عن الترتازين.

طرق البحث: تم إجراء البحث على 30 من الجرذان البيضاء الذكور مقسمة إلى 3 مجموعات (10 جرذان في كل مجموعة):

- مجموعة 1: مجموعة ضابطة، معالجة بالماء المقطر.
- مجموعة 2: مجموعة معالجة بالتارتازين (20 ملجم/كجم/يوم).
- مجموعة 3: مجموعة معالجة بزيت حبة البركة (10 ملجم/كجم/يوم) + التارتازين.

وفي نهاية التجارب تم ذبح الجرذان وتجميع عينات الدم لتقييم حالة الدم عن طريق قياس إجمالي عدد خلايا الدم الحمراء (RBCs) وحجم الخلايا المكسدة (PCV) وتركيز الهيموجلوبين (Hb) ومقدار حجم الخلية (MCV) ومتوسط الهيموجلوبين بالخلية (MCH)، متوسط تركيز الهيموجلوبين بالخلية (MCHC) وإجمالي عدد خلايا الدم البيضاء (WBCs) وإجمالي عدد الصفائح الدموية. علاوة على ذلك، تم تقييم حالة الأكسدة، عن طريق قياس المالوندايالدهيد (MDA) والجلوتاثيون المختزل (GSH)، في الكلى والطحال ونخاع العظام وكريات الدم الحمراء. بالإضافة إلى ذلك، تم فحص نخاع العظم لمعرفة التغيرات المرضية.

النتائج: أدت المعالجة بالتارتازين إلى انخفاض كبير في عدد كرات الدم الحمراء، وتركيز الهيموجلوبين، حجم الخلايا المكسدة، إجمالي عدد كرات الدم البيضاء، وتعداد الخلايا اللمفاوية وأحادية الخلية والمحببة، بينما زاد بشكل كبير مقدار حجم الخلية (MCV) ومتوسط الهيموجلوبين بالخلية (MCH) وعدد الصفائح الدموية، كما قل بشكل ملحوظ مستوى الجلوتاثيون المختزل، بينما زاد مستوى المالوندايالدهيد في كرات الدم الحمراء وأنسجة الكلى والطحال ونخاع العظم.

أثارت الدراسة الميكروسكوبية لنخاع العظم زيادة عدد الخلايا المصنعة للصفائح الدموية وظهور تليفات في المجموعة المعالجة بالتارتازين. وقد أدى العلاج بزيت حبة البركة إلى تحسين الاضطرابات الناجمة عن التارتازين.

الخلاصة: كشفت نتائج الدراسة الحالية أن زيت حبة البركة قد حسن الاضطرابات الدموية التي يسببها الترتازين، على الأرجح من خلال خصائصه المضادة للأكسدة.