

Ameliorating effects of some trematode antigens on arthritis induced in Wistar rats

Mohamed L. Salem^{1,2,*}, Ahlam S. Aboshafey³, Lamia I. Bakr³ and Shima M. Abduljalil³

¹Immunology and Biotechnology Division, Zoology Department, Faculty of Science, Tanta University, Egypt

²Center of Excellence in Cancer Research, Teaching Hospital, Tanta University, Egypt

³Zoology Department, Faculty of science, Tanta University, Egypt

ABSTRACT

Background: Rheumatoid Arthritis (RA) is an autoimmune disease mediated by T helper 1 type (Th1) immune cells. It has been established that parasitic antigens are capable of polarizing the immune response towards T helper 2 (Th2) immune cells. **Aim:** To assert the potential effect of *Schistosoma mansoni* soluble egg antigen (Sm) and *Fasciola hepatica* adult worm antigen (Fh), which are known to induce Th2 type response. **Methods:** RA was induced in female Wistar rats by intradermal injection (i.d) of 0.1 mL complete Freund's adjuvant (CFA). After 12 days of CFA injection, rats were treated with i.d injection of 0.1 mL saline, 0.2 mg/1mL methotrexate (MXT) via intra-peritoneal (i.p) injection once a week four 3 weeks as a reference drug, 100 µg Sm (i.p or i.d), 100 µg Fh (i.p or i.d). Rats were treated with antigens daily for two weeks. **Results:** Compared to control RA rats, treatment with Sm and Fh antigens resulted in significant amelioration in the clinical symptoms of the disease, including paw thickness and deformity measured by X-ray. These effects were further confirmed by significant amelioration in the histopathological changes in the hind paw. Analysis of Th1 and Th2 cytokines revealed higher and lower serum levels of the Th1 (IL-6 and TNF-α) and Th2 (IL-4 and IL-10), respectively, as compared to untreated RA rats. Analysis of the liver function showed that treatment of RA rats with Sm or Fh antigens associated with significant amelioration in hepatic enzymes, including ALT, AST and ALP, coinciding with significant amelioration in the increased number of white blood cells and absolute number of neutrophils. **Conclusion:** Our data indicate that Sm possesses higher anti-arthritic effect than Fh, where the i.d route is more effective than the i.p. one. These results open new avenue for the use of trematode antigens as a potential therapeutic approach to ameliorate arthritis.

ARTICLE INFO



Dr. M. L. Salem, PhD

Article history:

Received: April 9, 2019

Revised: July 25, 19

Accepted: November 30, 2019

Correspondence to:

Dr. Mohamed L. Salem, PhD
Prof. of Immunology, Immunology and Biotechnology Division, Zoology Department, Faculty of Science Tanta University, Egypt
Tel: +2 01274272624
Mohamed.labib@science.tanta.edu.eg
mohamedlabibsaleem@yahoo.com

Keywords: Cytokines, *Fasciola hepatica*, Methotrexate, Rheumatoid arthritis; *Schistosoma mansoni*, Th cells

INTRODUCTION

Rheumatoid Arthritis (RA) is defined as a systemic autoimmune disease which is characterized by pain and swelling of joints due to chronic synovial inflammation, progressive bone and cartilage damage which finally leads to joint destruction (Heinmann et al., 2018).

The peri-articular bone erosions are the most characteristic symptoms of the disease which lead to deformation, laxity, and loss of function (Ali et al., 2015).

Several autoimmune diseases including RA are mediated by imbalance of Th1 and Th2 subsets. Th1 subset produces pro-

inflammatory cytokines including TNF- α and IFN- α whereas the Th2 subset suppresses Th1 immune response by deriving the anti-inflammatory cytokines including IL-4 and IL-10 (Calabresi et al., 2018). Such a mutual antagonistic effect of Th1 and Th2 responses could be used as a therapeutic target in RA. Therefore, modulating Th1 type of RA can significantly alter the disease course. Th1 cells play an important role in the initiation of RA through activation of synovial fibroblasts, macrophages and other cell populations which are the main producers of the pro-inflammatory cytokines TNF- α and IL-6 (Chen et al., 2018). It has been established that during helminth infection or immunization that Th2 responses are predominant and are combined with the production of IL-4, IL-5, IL-10 and IL-13 (Lang and Schick 2017) followed by the induction of regulatory networks that induces tolerance to control immune mediated pathology this could explain which treatment of RA with helminthes manifest a decrease in Th1 cytokines and accordingly decrease symptoms were reduced or relieved completely (Heylen et al., 2014). *Fasciola hepatica* infection polarizes a potent Th2 response and reduces the experimental autoimmune encephalomyelitis via suppression of Th1 and Th17 (Vukman et al., 2013). Similarly, eggs glycoprotein of *Schistosoma mansoni* has also been reported to induce Th1 immune response via releasing of IL-4 and IL-13 from basophils thus it can prevent the onset of autoimmune disease diabetes mellitus type 1 (Schramm et al., 2003; Araújo et al., 2004).

The present study was undertaken to investigate the therapeutic effect of *S. mansoni* (Sm) and *F. hepatica* (Fh) antigens to modulate the inflammatory symptoms in arthritis induced in Wistar rats as a novel potential therapy biological therapy for arthritis.

MATERIALS AND METHODS

Materials: All the other chemicals were of the highest analytical grade; complete Freund's adjuvant (CFA) was purchased from Sigma-Aldrich (St Louis,MO, USA), methotrexate

(MXT) was obtained from Mylan SAS [USA], liver enzymes were obtained from Spin react Company [Spain]. Soluble egg from *Schistosoma mansoni* (Sm) and somatic antigens from whole worm *Fasciola hepatica* (Fh) were purchased from Theodor Bilharz research Institute Hospital is a tertiary hospital in Waraq El-Hadar, Giza, Egypt.

Animals: Seventy adult female Wister rats, weighing 180–200 g, were obtained from VACSERA for Biological Products and Vaccine (Cairo, Egypt). Animals were housed in suitable cages with free access to commercial diet and tap water and acclimatized to laboratory conditions for a period of 1 week before the commencement of the experiments. All animals were humanely treated in accordance with WHO guidelines for animal care and the study design was approved by Tanta University Research Ethics Committee. Once arthritis developed, food was served on the bottom of the cages as severely arthritic rats have difficulty in feeding from the cage top.

Induction of arthritis by adjuvant: For induction of RA, Wistar female rats were injected i.d at the tail base with a single dose of 0.1 ml of CFA under ether anesthesia, as previously described (Zhao et al, 2013), Control animals were those injected i.d with a single dose of 0.1 ml of saline into the dorsal root of the tail at day 0.

Experimental setup: After one week of acclimatization, RA was induced in rats as above and then treated on day 13 with the following; 0.2 mg/1ml methotrexate (MXT) intra-peritoneal injection (i.p) once a week for 3 weeks of as a reference drug, 100 μ g Sm (i.p) or (i.d), 100 μ g Fh (i.p) and (i.d). Rats were treated with antigens daily for two weeks. After 28th day, the animals were sacrificed for histopathological, biochemical and cytokines analysis (Fig. 1),

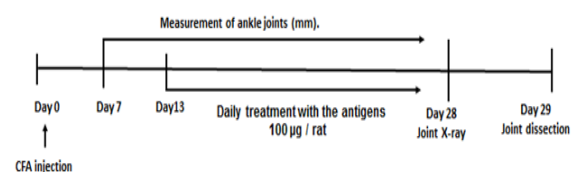


Figure 1: Diagram for treatment schedule. It shows timing of induction and treatment of arthritis.

Measurement of paw thickness: The anterior-posterior diameter of the inflamed hind paw was measured using a digital Vernier caliper until the pain was elicited as indicated by leg withdrawal (Ramprasath et al., 2006). Measurements were done on 7th, 14th, 21st and 28th day after the induction of RA .

Radiological imaging and scoring: At the end of the experiment, i.e. on the 29th day, the rats were anesthetized and placed in the anterior-posterior position on a radiographic box at a distance of 90cm from the X-ray source.

Radiographic analysis of arthritic hind paws was performed by using digital X-ray machine (Agfa – CR-30), with a 48 kVp exposure for 0.5 mAs for confirmation and evaluation of the severity of deformities in joints, bones and soft tissues of hind paws in CFA-induced rats. Radiographs were carefully examined for bone erosion, tissue swelling and osteophyte formation (Cuzzocrea et al., 2001).

Blood and Tissue Sampling: The feed was withdrawn 12 hours before the blood collection and animals were subjected to light diethyl ether anesthesia before killing on day 29. After treatment was completed, blood samples were collected from orbital venous plexus under light anesthesia. Each sample was divided into two portions; the first was collected in clean dry Eppendorf tubes containing EDTA as anticoagulant to be used for hemogram studies (Parasuraman et al., 2010).

The second part was collected into non heparinized tubes which were centrifuged at 3000 rpm for 10 minutes for separation of serum. The collected sera were stored at -20oC for biochemical estimation.

Histopathological Processing and Analysis: Arthritic paws were collected on day 29 after the induction of arthritis and fixed in 10% buffered formalin. The fragments were then treated with a 10% acidic nitric solution for decalcification, dehydrated, cleared and embedded in paraffin. Serial sagittal sections of the whole paw were cut (3–4 Am thick), stained with hematoxylin (Shealy et al., 2002) and eosin and examined for the degree of synovitis and bone destruction. This will be

based on the three main features of chronic arthritis (Chillingworth and Donaldson 2003). These are enlargement of epidermal lining, cellular density of synovial stroma and leukocyte infiltration. Each will be assigned a score of 0-3, with 0 being no change and 3 the high grade synovitis. The joints of at least three animals were observed in each experimental group.

Liver enzymes: Aspartate amino transaminase (AST) and Alanine transaminase (ALT) activities in serums were measured according to (Schumann et al., 2011).

Counting of peripheral blood cells: Rats were bled from the retro-orbital plexus, and blood samples were then processed to assess the total count of peripheral blood leukocytes (PBL). The total number of leucocytes in peripheral blood was enumerated using an automated instrument for CBC (VetScan HM2™ Hematology System, Abaxis®, and Union City, CA)

Measurement of cytokines: Levels of serum pro-inflammatory and anti-inflammatory cytokines were determined by in vitro Enzyme Linked Immunosorbent Assay [ELISA] kit, using colorimetric reaction method as instructed in the kit manual for TNF- α , IL-4, IL-6, and IL-10 according to the manufacturer's recommendations.

IL-4 was determined according to (Cook et al., 2012), IL-10 was determined according to (Weiss et al., 2004), Interleukin-6 (IL-6) was determined according to Muñoz et al. (2003), TNF- α was determined according to Taylor (2001).

Statistical Analysis

Statistical analysis was carried out using Graph Pad Prism 5 [Graph Pad Software, San Diego, CA, USA]. Groups of data were compared with an analysis of variance [one-way ANOVA] followed by Tukey's multiple comparison test. The paw thickness was plotted on Microsoft excel (Window 7.0) and Mean \pm SEM was calculated. P-values of < 0.05, < 0.01 and < 0.001 were considered statistically significant, highly significant and very highly significant,

respectively. Results are expressed as Mean \pm SEM.

RESULTS

Treatment with Sm and Fh antigens induced ameliorating effect on arthritic rats.

The main clinical symptoms of CFA-induced RA included erythema of one or more ankle joints followed by metatarsal joints, first appeared in the hind paws between 8 and 9 days after injecting with CFA, with a 100% incidence by day 13 \pm 1. Pronounced inflammation characterized by swelling, redness and restriction in movement was also observed in CFA rats as compared to the controls.

Paw volume (cu.cm) in all treated groups was significantly increased as compared to arthritic group at the respective time intervals on 7th, 14th, 21st and 28th day after the induction of RA (Fig. 2A). The macroscopical appearance of the paw of arthritic control group showed severe edema and erythema. Mild to moderate inflammation and reduced swelling was noticed in MXT group, while moderate inflammation was noticed in groups treated with Fh antigen. Groups treated with Sm showed reduced inflammation and very mild swelling. Paw of normal control group was devoid of any inflammation (Fig. 2B)

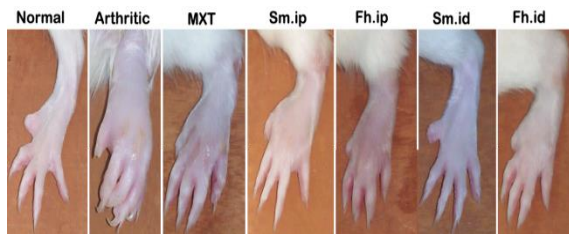


Figure 2: Effects of the treatment with helminthes antigens on edema in hind paw of adjuvant-induced arthritis in Wistar rats.

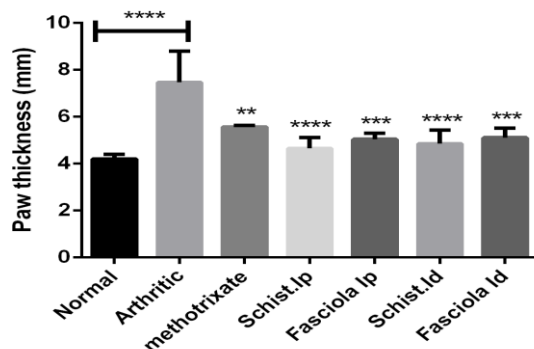


Figure 2: Effects of the treatment with helminthes antigens on hind paw edema in adjuvant-induced arthritis in rats. The graph is showing the change in paw thickness of CFA-induced arthritic rats. The results showing disease severity in terms of hind paw thickness the plot (A) of the normal control (vehicle / Saline), CFA-induced arthritis (Arthritic) and after treatment with Methotrexate (metho) 0.2 mg/1mL i.p. injection and treatment with some trematode antigens 100 μ g of Sm either i.d. or i.p. injection, and 100 μ g of Fh either i.d. or i.p. injection. The values are represented as Mean \pm SEM. The p value < 0.05 was considered as significant, where *** < 0.001, ** < 0.01, * < 0.05. The data of all the antigens treated groups is compared with the arthritic group.

Radiographic analysis of arthritic hind paws was performed by using digital X-ray machine. All illustrated X-ray images showed the change in bones and joint of hind limbs of all groups. Arthritic group showed severe soft tissue swelling, bone erosion and narrowed joint space. MXT group revealed moderate tissue swelling, moderate bone erosion and moderate osteophyte formation. The radiographs of Fh treated groups showed mild tissue swelling and no osteophyte formation, but no bone erosion. The radiographs of Sm treated groups showed no tissue swelling and no osteophyte formation, and no bone erosion, the normal control group revealed no pathological lesions in the radiograph (Fig. 3).

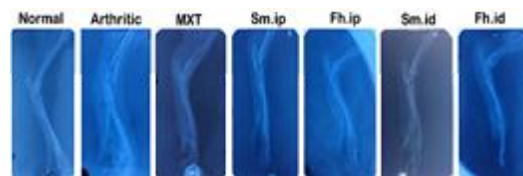


Figure 3: Effects of the treatment with helminthes antigens on the radiological imaging of the hind paws of CFA-induced arthritic rats.

Treatment with Sm and Fh antigens induced amelioration in the histopathological changes of arthritic rats

Histopathology of the joint tissue of the RA group severe infiltration of inflammatory cells, thickened epidermal, marked swelling of the synovial tissue, severe connective tissue proliferation and destruction in muscle layer, MXT group shows moderate infiltration of inflammatory cells, thickened epidermal and moderate connective tissue proliferation, Sm i.p. group shows reducing in infiltration of inflammatory cells, normal epidermal and

minimal connective tissue proliferation, Sm i.d. group, mononuclear cell infiltration was not pronounced, normal epidermal and connective tissue proliferation reduced markedly. Fh i.p. group shows mild infiltration of inflammatory cells, mild thickened epidermal and mild connective tissue proliferation. Fh i.d. group shows reducing in infiltration ration of inflammatory cells, minimal epidermal thickness and mild connective tissue proliferation (Fig. 4).

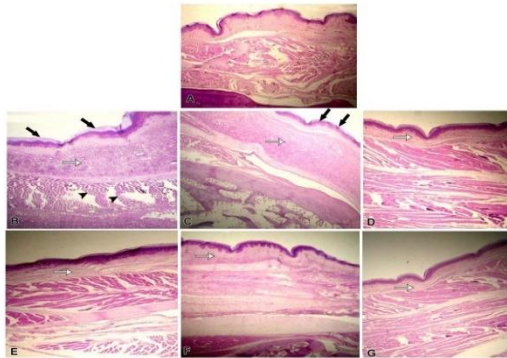


Figure 4: Histological changes in the left hind paws. RA was induced in Wistar rats and then animals were treated with saline, methotrexate or trematode antigens as described in the legend of Figure 1. (A) Normal control (vehicle/Saline). (B) CFA-induced arthritis (Arthritic) which show severe infiltration of inflammatory cells, thickened epidermis and severe connective tissue proliferation. (C) MXT 0.2 mg/1ml i.p injection shows moderate infiltration of inflammatory cells, thickened epidermis and moderate connective tissue proliferation. (D) 100 µg of Sm i.p, shows infiltration of inflammatory cells reduced markedly, normal epidermis and minimal connective tissue proliferation. (E) 100 µg of Sm i.d, shows reducing in infiltration of inflammatory cells, normal epidermis and minimal connective tissue proliferation. (F) 100 µg of Fh i.p, shows mild infiltration of inflammatory cells, mild thickened epidermis and mild connective tissue proliferation. (G) 100 µg of Fh i.d, shows reducing in infiltration of inflammatory cells, minimal epidermis thickness and mild connective tissue proliferation. Arrows show thickened epidermis, Stars show connective tissue of dermis, White arrows show muscular tissue destruction in arthritic group. Magnification; 10x in all micrographs.

Treatment with Sm and Fh antigens increased Th2 type cytokines

The disequilibrium in inflammatory cytokines has a central role in the perpetuation of chronic inflammation and tissue damage during progression of RA. The level of pro-inflammatory cytokines, TNF- α and IL-6 and anti-inflammatory cytokines, IL-4 and IL-10

served as the marker for Th2 and Th1 environment in rat's serum. The concentration of pro-inflammatory cytokines TNF- α (pg/mg) and IL-6 (pg/mg) in the serum revealed a significant effect in all treated groups while in MXT treated group was significant compared with the Arthritic group (Fig.5A&B).The concentration of anti-inflammatory cytokines of IL-4 (pg/mg) and of IL-10 (pg/mg) in the serum exert a significant effect in all treated antigens groups and it was more significant only in Sm intradermal injected group while no significant change was recorded at MXT compared with the arthritic group. (Fig. 6A&B).

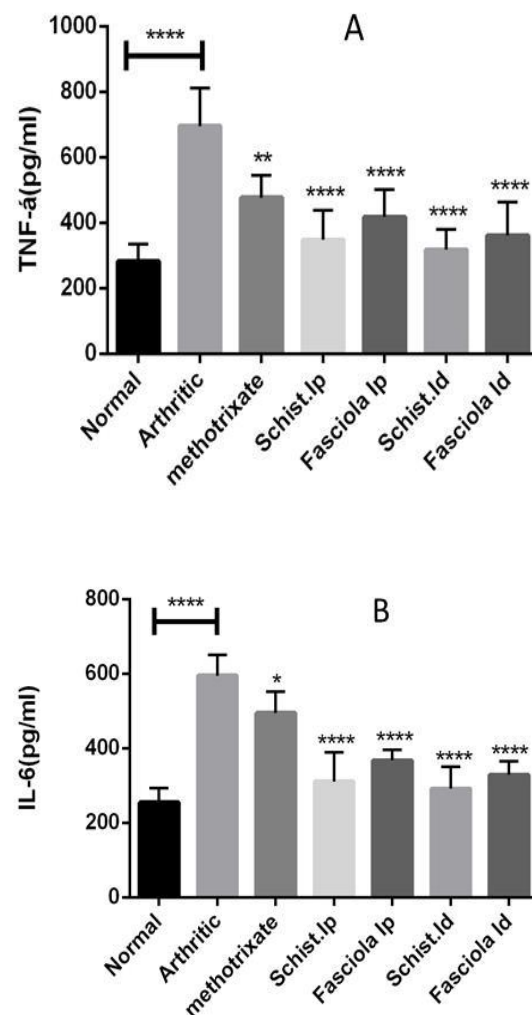


Figure 5: Effects of the treatment with helminthes antigens on the levels of Th1 type cytokines in CFA-induced arthritic rats. RA was induced in Wistar rats and then animals were treated with saline, methotrexate or trematode antigens as described in the legend of Figure 1. The results show the level of TNF- α (A) and IL-6 (B) measured in control rats and treated groups. The therapeutic significance level of different treated rats in comparison to arthritic rats. The data of all the treated

groups is compared with the Arthritic group. The values are represented as Mean \pm SEM. The p value < 0.05 was considered as significant, where *** < 0.001 , ** < 0.01 , * < 0.05 .

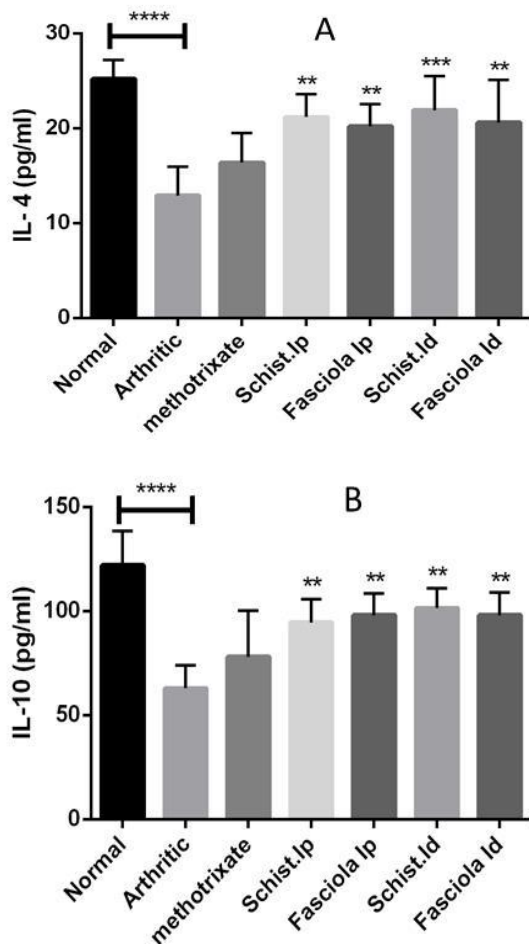


Figure 6: Effects of the treatment with helminthes antigens on the levels of Th2 type cytokines in CFA-induced arthritic rats. RA was induced in Wistar rats and then animals were treated with saline, methotrexate or trematode antigens as described in the legend of Figure 1. The results show the level of IL-10 (A) and IL-4 (B) measured in control rats and treated groups. The therapeutic significance level of different treated rats in comparison to arthritic rats. The data of all the treated groups is compared with the Arthritic group. The values are represented as Mean \pm SEM. The p value < 0.05 was considered as significant, where *** < 0.001 , ** < 0.01 , * < 0.05 .

The blood leukocyte count was significantly increased in the arthritic group compared with the normal group with concomitant increases in neutrophils count. In methotrexate group, significant decrease of total leucocytes, accompanied by neutrophilia, compared with arthritic groups. All antigens treated groups exert significant decreasing in total leukocyte

count but there was no significant influence in neutrophil count. (Fig. 7 A & B).

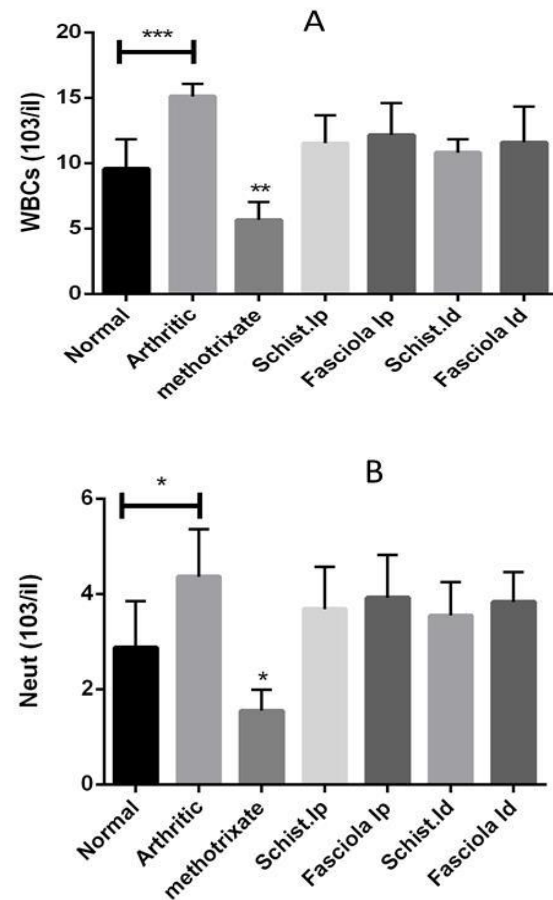


Figure 7: Effects of the treatment with helminthes antigens on the white blood cells and neutrophil counts in CFA-induced arthritic rats. RA was induced in Wistar rats and then animals were treated with saline, methotrexate or trematode antigens as described in the legend of Figure 1. The results show the number of WBC (A) and neutrophil (B) measured in control rats, CFA rats and experimental rats. The data of all the treated groups is compared with the normal group. The values are represented as Mean \pm SEM. The p value < 0.05 was considered as significant, where *** < 0.001 , ** < 0.01 , * < 0.05 .

The activity of alanine transaminase (ALT; IU/L) and of Aspartate aminotransferase (AST; IU/L) in serum revealed a significant rise in normal group as compared to arthritic group. The treatment groups only Sm antigens treated groups were significant compared to arthritic group (Fig. 8A & B). The activity of alkaline phosphatase (ALP; IU/L) in serum in normal group was significantly lower than all the other groups. There was significant rise in of Sm

antigens treated rats as compared to arthritic group. (Fig. 8C)

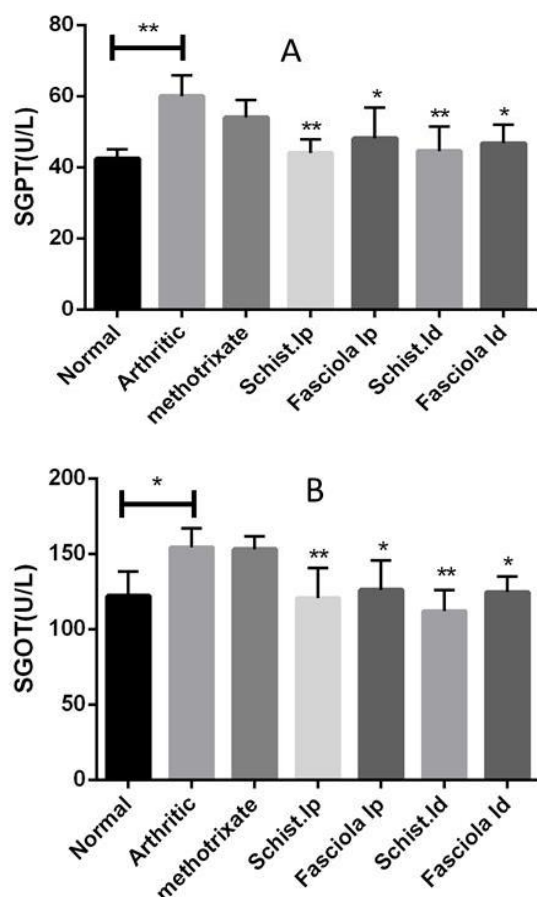


Figure 8: Effects of the treatment with helminthes antigens on the liver enzymes in CFA-induced arthritic rats. RA was induced in Wistar rats and then animals were treated with saline, methotrexate or trematode antigens as described in the legend of Figure 1. Results show the effect of antigens and methotrexate on serum ALT and AST in normal, CFA-induced arthritis with or without treatments modalities. The data of all the treated groups is compared with the normal group. The values are represented as Mean \pm SEM. The p value < 0.05 was considered as significant, where *** < 0.001, ** < 0.01, * < 0.05.

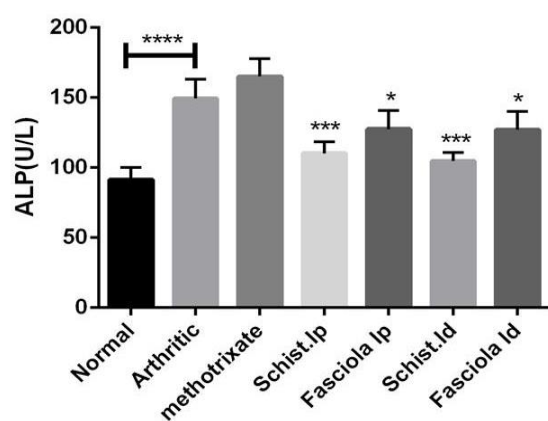


Fig. 8(C). Effects of the treatment with helminthes antigens on the liver enzymes in CFA-induced arthritic rats.

DISCUSSION

Rheumatoid Arthritis (RA) is an autoimmune disease mediated by T helper 1 immune cells (Th1). Methotrexate remains the primary treatment and the only hope for the cure of rheumatoid arthritis. However, it has been reported that the use of methotrexate is accompanied in most cases with toxicity and severe gastrointestinal, hematologic, pulmonary and hepatic complications (Omoigui *et al.*, 2014). Therefore, there is an urgent need for anti-rheumatoid drugs that are less harmful to the patient, and also more effective for use in rheumatoid arthritis treatment. Since parasitic helminthes antigens have been recognized as having the potential to ameliorate different types of autoimmune disorders via potentiating the Th2 immune response, the present study has suggested investigating the anti-rheumatoid effect of different antigens as purified soluble antigens from *Schistosoma mansoni* egg (Sm) and *Fasciola hepatica* whole worm (Fh) using different routes against RA experimentally induced in female rats.

Several studies revealed that parasitic helminthes antigens can ameliorate different types of autoimmune disorders, helminthic products have demonstrated potential for the treatment of multiple sclerosis, with a skewing in cytokine responses towards a Th2 immune response (Jorge 2014, Tanasescu and Constantinescu 2015). As examples for nematodes, intestinal pathology could be suppressed in a mouse model of colitis; by using excretory- secretory (ES) from the hookworm, *Ancylostoma caninum*. This was due to a potent Th2 immune response and the induction of activated macrophages to the site of ES injection (Sotillo *et al.*, 2017). Also, excretory-secretory (ES)-62 isolated from *Acanthocheilonema viteae* has been shown to attenuate the initiation of collagen induced inflammatory arthritis and also dampen the progression and severity of the disease (Al-Riyami *et al.* 2013). Regarding trematodes, the tropical liver fluke; *Fasciola gigantica* and

amphistome parasite; *Gigantocotyle explanatum* ameliorate the experimentally induced arthritic symptoms by strong polarization of the immune response towards the Th2 type (Khan et al., 2015). Coinciding, occurrence of the inflammatory disorders is associated with the absence of suitable priming of the immune system by parasitic helminths during the childhood (Sewell et al., 2002).

During our study, we tested two kinds of variables for treatment; the source of antigen to understand if this is a general phenomenon or specific for a certain parasite antigen and the route of injection to choose the best type for impacting the overall anti-arthritic effect. The literature is flush with examples of how different sources of antigens with different types used as potent immunomodulatory approach therapy.

The treatment of arthritic rats with Sm and Fh in comparison to MXT resulted in significant remission of the disease as shown by clinical symptoms (swelling, redness and restriction in movement), paw thickness, depletion in serum TNF- α and IL-6, increased serum IL-4 and IL-10 levels, decline in leukocyte influx and amelioration of liver enzymes and joint pathology.

The analysis of serum cytokines showed that the treatment with (Fh) and (Sm) also elicited potent Th2 type of immune response in Wistar rats as reflected by high levels of serum IL-4 and IL-10 and low level of TNF- α and IL-6 in CFA rats after treatment with antigens. IL-10 inhibits the paw swelling, pannus formation and cartilage degradation by suppressing pro-inflammatory cytokines in CIA rats (Khalifeh et al., 2010), this could explain the anti-arthritic effect of the antigens.

Paw volume and thickness were significantly ameliorated in antigens groups and more effective than MXT group in comparison with control group, which may be due to greater inhibition of joint inflammation by reducing soft tissue swelling, erythema and ankylosis of the joints. The extensive paw oedema in the arthritic rats was confirmed in histology and radiography that showed soft tissue swelling around ankle joints. This might be due to

mononuclear cell infiltration and proliferation of fibroblasts in the inflamed tissues. There is also an increase in the volume of intracellular fluid leading to oedema (Paleolog, 2009) which, along with other inflammatory vasodilators such as histamine and bradykinin contributes to erythema and increased blood flow in areas of acute inflammation (Branco et al., 2018). The macroscopical, radiographical and histological examination of joint tissues revealed that both antigens treated groups have markedly improved the histo-architecture of joints as compared to arthritis control group and more effective than MXT group.

Despite of insignificant variation in IL-4, IL-10, TNF- α and IL-6 level between Sm and Fh treated rats, the Sm was found to be more effective than the Fh which could possibly be due to the interspecific molecular differences that remain a subject for further discoveries and intradermal injection was found to be more effective than intra peritoneal injection in all antigens treated groups, and it may be due to the uptake of antigen by Langerhans cells in skin tissue and induction of the maturation and migration into the nearest lymph node. There, dendritic cells present antigens to T cells. Accordingly, induction of potent immunity, in contrast i.p induction of antigens doesn't induce such kind of events. The maximum disease suppression occurred at Sm intradermal injection treatment. From the very beginning the treated rats (except MXT) consistently showed low to moderate symptoms (redness, swelling and restriction in movement) as compared to the CFA rate. The therapeutic significance level of different antigen treated rats in comparison to CFA rats was as follows: MXT i.p. ($p < 0.05$), Fh i.p. ($p < 0.01$), Fh i.d. ($p < 0.01$), Sm i.d. ($p < 0.001$), Sm i.p. ($p < 0.001$) and the order of disease remission was: Sm i.d. > Sm i.p. > Fh i.d. > Fh i.p.

The hematological results showed that induction of rheumatoid arthritis caused a significant leukocytosis accompanied with neutrophilia due to stimulation of the immune response to help the body to fight infection by producing antibodies that circulate widely in the blood stream, recognizing the foreign

particles and triggering inflammation (Anderson et al., 2012). Treatment with methotrexate leads to leucopenia accompanied with neutrophilia (Omoigui et al., 2014).

Our study has shown that an immunological adjuvant induced to rats, changes hepatic biochemistry. Both antigen treated groups reduce this toxicity. Estimation of the levels of AST, ALT and ALP provides an accurate and simple tool for measuring the anti-arthritis activity of the target drug (Srivastava et al., 2012; Kumar et al., 2016). The activities of aminotransferases and ALP were significantly raised in arthritic rats, since these are good indices of liver and kidney impairment and are considered as important features of adjuvant arthritis (Mbiantcha et al., 2017). Serum AST and ALT has been reported to play a vital role in the production of active chemical mediators in inflammatory process (Glenn et al., 1965). In addition, positive correlation between the disease activity in RA and the elevated activity of alkaline phosphatase in serum (Li et al., 2018). Increase in the liver and bone fraction or both them, resulting in increased levels of serum ALP in adjuvant rats. This in turn involves a localized bone loss in the form of bone erosion and peri articular osteopenia, as the enzyme is released into circulation during bone formation (Rehman and Lane 2001; Kaithwas and Majumdar, 2010).

It has been reported that an increase of the baseline serum ALP level in RA, although of internal mechanism still uncertain (Aida, 1993). Currently, monitoring of serum samples from patients with RA suggested that ALP activity was found at a high prevalence of about 30 % (Aida, 1992). Similarly, adjuvant-treated rat showed critically higher serum biochemistry markers (AST, ALT and ALP) than normal rats (Hung et al., 2006). It may be expected that *Fasciola hepatica* somatic proteins may participate in liver cell damaging, and contribute to cell death and liver pathogenesis in the course of fasciolosis (Wesotowska et al., 2012)

Conclusion

From the current study, we can conclude that prophylactic therapy of some trematodes antigens ameliorates the experimentally induced arthritic clinical symptoms by potent polarization of the immune response towards the Th2 type. Helminth therapy showed a powerful anti-rheumatoid effect against Freund's Complete Adjuvant induced rheumatoid arthritis in experimental rats comparable to that exerted by DMARDs such as MXT. Sm therapy was even more effective with less adverse effects than the somatic antigen of Fh for further clinical trial.

REFERENCES

- Aida S (1992). Relation between alkaline phosphatase isoenzymes and disease activity in rheumatoid arthritis. *Acta Med Biol* 40(3): 79-83.
- Aida S (1993). Alkaline phosphatase isoenzyme activities in rheumatoid arthritis: hepatobiliary enzyme dissociation and relation to disease activity. *Ann Rheum Dis*, 52(7):511-516.
- Ali EA, Barakat BM and Hassan R (2015). Antioxidant and angiostatic effect of *Spirulina Platensis* suspension in complete Freund's adjuvant-induced arthritis in rats. *PLoS One* 10(4):e0121523.
- Al-Riyami L, Pineda MA, Rzepecka J, Huggan JK, Khalaf AI, Suckling CJ, Scott FJ, Rodgers DT, Harnett MM and Harnett W (2013) Designing anti-inflammatory drugs from parasitic worms: a synthetic small molecule analogue of the *Acanthocheilonema viteae* product ES-62 prevents development of collagen-induced arthritis. *J Med Chem.*,56 (24):9982–10002.
- Anderson J, Caplan L, Yazdany J, Robbins ML, Neogi T, Michaud K, Saag KG, O'dell JR and Kazi S (2012). Rheumatoid arthritis disease activity measures: American College of Rheumatology recommendations for use in clinical practice. *Arthritis Care Res (Hoboken)*, 64(5): 640-647.
- Araújo MI, Hoppe BS, Medeiros Jr M and Carvalho EM (2004). *Schistosoma mansoni* infection modulates the immune response against allergic and auto-immune

- diseases. Mem Inst Oswaldo Cruz, 99 (5 Suppl 1): 27-32.
- Branco AC, Yoshikawa FS, Pietrobon AJ and Sato MN (2018) Role of histamine in modulating the immune response and inflammation. Mediators Inflamm., 2018: 9524075.
- Calabresi E, Petrelli F, Bonifacio A, Puxeddu I and Alunno A (2018). One year in review 2018: pathogenesis of rheumatoid arthritis. Clin Exp Rheumatol, 36(2):175-184.
- Chen YL, Lin JZ, Mo YQ, Liang JJ, Li QH, Zhou CJ, Wei XN, Ma JD, Yang ZH and Zheng DH (2018). Joint damage is amplified in rheumatoid arthritis patients with positive thyroid autoantibodies. PeerJ 6:e4216.
- Chillingworth NL and Donaldson LF (2003) Characterisation of a Freund's complete adjuvant-induced model of chronic arthritis in mice. J Neurosci Methods, 128 (1-2):45-52.
- Cook PC, Jones LH, Jenkins SJ, Wynn TA, Allen J E and MacDonald AS (2012) Alternatively activated dendritic cells regulate CD4+ T-cell polarization in vitro and in vivo. Proc Natl Acad Sci USA. 109 (25): 9977-9982.
- Cuzzocrea S, Mazzon E, Dugo L, Serraino I, Britti D, Maio MD and Caputi AP (2001) Absence of endogenous interleukin-10 enhances the evolution of murine type II Collagen-Induced Arthritis. Eur Cytokine Netw, 12 (4), 568-580
- Glenn EM, Gray J and Kooyers W (1965). Chemical changes in adjuvant-induced polyarthritis of rats. Am J Vet Res. 26(114): 1195-1203.
- Heinimann K, von Kempis J, Sauter R, Schiff M, Sokka-Isler T, Schulze-Koops H and Müller R (2018). Long-Term Increase of Radiographic Damage and Disability in Patients with RA in Relation to Disease Duration in the Era of Biologics. Results from the SCQM Cohort. J Clin Med 7(3):57
- Heylen M, Ruysers NE, Gielis EM, Vanhomwegen E, Pelckmans PA, Moreels TG, De Man JG and De Winter BY (2014) Of worms, mice and man: an overview of experimental and clinical helminth-based therapy for inflammatory bowel disease. Pharmacol Ther, 143(2):153-167.
- Hung DY, Siebert GA, Chang P, Whitehouse MW, Fletcher L, Crawford DH and Roberts MS (2006). Hepatic pharmacokinetics of propranolol in rats with adjuvant-induced systemic inflammation. Am J Physiol Gastrointest Liver Physiol, 290(2): G343-G351.
- Jorge C (2014) Helminth/Parasite Treatment of Multiple Sclerosis. Curr Treat Options Neurol, 16 (6), 296
- Kaithwas G and Majumdar DK (2010). Therapeutic effect of *Linum usitatissimum* (flaxseed/linseed) fixed oil on acute and chronic arthritic models in albino rats. Inflammopharmacology 18,127-136.
- Khalifeh M, Al-Rukibat R, Hananeh W, Boumezrag A and Okour O (2010). Investigation of the role of tumour necrosis factor- α , interleukin-1 β , interleukin-10, nitric oxide and rheumatoid factor-immunoglobulin M in a rat model of arthritis. Lab Anim 44(2): 143-149.
- Khan YA, Umar S and Abidi SM (2015). Somatic antigens of tropical liver flukes ameliorate collagen-induced arthritis in wistar rats. PloS one 10(5): e0126429.
- Kumar V, Bhatt P C, Rahman M, Patel DK, Sethi N, Kumar A, Sachan NK, Kaithwas G, Alabbasi FA, Anwar F and Verma A (2016). *Melastomama labathricum* Linn attenuates complete freund's adjuvant-induced chronic inflammation in Wistar rats via inflammation response. BMC Complement. Altern. Med. 16:510.
- Lang R and Schick J (2017) Review: Impact of Helminth Infection on Antimycobacterial Immunity: A Focus on the Macrophage. Front. Immunol. 8:1864.
- Li Y, Kakkar R and Wang J (2018) In vivo and in vitro approach to anti-arthritic and anti-inflammatory effect of crocetin by alteration of nuclear factor-E2-related factor 2/hem oxygenase (HO)-1 and NF- κ B expression. Front Pharmacol.; 9: 1341
- Mbiantcha M, Almas J, Shabana SU, Nida D and Aisha F (2017) Anti-arthritic property of crude extracts of *Piptadeniastrum africanum* (Mimosaceae) in complete Freund's adjuvant-induced arthritis in rats. BMC Complement Altern Med.; 17: 111.

- Muñoz S, Hernández-Pando R, Abraham SN and Enciso JA (2003) Mast cell activation by *Mycobacterium tuberculosis*: Mediator release and role of CD48. *J Immunol*, 170 (11) 5590-5596
- Omoigui S, Fadare A and Ogbechie C (2014). Relief and resolution of fibromyalgia symptoms with low dose methotrexate—the origin of pain is inflammation and the inflammatory response. *Rheumatology (Sunnyvale)* 4(129):2161-1149.
- Paleolog EM (2009) The Vasculature in Rheumatoid Arthritis: Cause or Consequence? *Int J Exp Pathol*, 90 (3), 249-61
- Parasuraman S, Raveendran R and Kesavan (2010). Blood sample collection in small laboratory animals. *J Pharmacol Pharmacother*, 1 (2): 87-93.
- Ramprasath VR, Shanthi P and Sachdanandam P (2006). Therapeutic effects of *Semecarpus anacardium* Linn. nut milk extract on the changes associated with collagen and glycosaminoglycan metabolism in adjuvant arthritic Wistar rats. *Chem Biol Interact*, 162 (1): 43-52.
- Rehman Q and Lane NE (2001). Bone loss: Therapeutic approaches for preventing bone loss in inflammatory arthritis. *Arthritis Res*, 3(4): 221-227.
- Schramm G, Falcone FH, Gronow A, Haisch K, Mamat U, Doenhoff MJ, Oliveira G, Galle J, Dahinden CA and Haas H (2003). Molecular characterization of an interleukin-4-inducing factor from *Schistosoma mansoni* eggs. *J Biol Chem*, 278(20):18384-18392
- Schumann G, Klauke R, Canalias F, Bossert-Reuther S, Franck PF, Gella FJ, Jørgensen PJ, Kang D, Lessingerb JM, Panteghini M and Ceriotti F. (2011) IFCC primary reference procedures for the measurement of catalytic activity concentrations of enzymes at 37 °C. Part 9: Reference procedure for the measurement of catalytic concentration of alkaline phosphatase. *Clin Chem Lab Med*. 49 (9):1439-1446.
- Sewell DL, Reinke EK, Hogan LH, Sandor M and Fabry Z (2002). Immunoregulation of CNS autoimmunity by helminth and mycobacterial infections. *Immunol Lett*, 82(1-2): 101-110.
- Shealy DJ Wooley PH, Emmell E, Volk, A, Rosenberg A, Treacy G and Song XY (2002). Anti-TNF-alpha antibody allows healing of joint damage in polyarthritic transgenic mice. *Arthritis Res.*, 4(5): R7.
- Sotillo J, Ferreira I, Potriquet J, Laha T, Navarro S, Loukas A, Mulvenna J (2017) Changes in protein expression after treatment with *Ancylostoma caninum* excretory/secretory products in a mouse model of colitis. *Sci Rep.*; 7: 41883
- Srivastava S, Singh P, Jha K K, Mishra G, Srivastava S, Khosa R L. (2012) Evaluation of anti-arthritic potential of the methanolic extract of the aerial parts of *Costus speciosus*. *J Ayurveda Integr Med.*, 3(4): 204–208.
- Tanasescu R, Constantinescu CS (2015): Helminth Therapy for MS. *Curr Top Behav Neurosci* ,26:195-220.
- Taylor PC (2001) Anti-TNF therapy for rheumatoid arthritis and other inflammatory diseases. *Mol Biotechnol*, 19 (2), 153-168
- Vukman KV, Adams PN, Metz M, Maurer M and O'Neill SM (2013) *Fasciola hepatica* tegumental coat impairs mast cells' ability to drive Th1 immune responses. *J Immunol*, 190(6):2873-2879.
- Weiss E, Mamelak, A. J., La Morgia, S., Wang, B., Feliciani, C., Tulli, A. and Sauder, D. N. (2004) The role of interleukin 10 in the pathogenesis and potential treatment of skin diseases. *J Am Acad Dermatol*, 50 (5): 657-675
- Wesołowska A, Gajewska A, Smaga-Kozłowska K, Kotomski G and Wędrychowicz H (2012). Effect of *Fasciola hepatica* proteins on the functioning of rat hepatocytes. *Parasitol Res*, 110 (1):395-402.
- Zhao J, Zha Q, Jiang M, Cao H, Lu A. (2013) Expert consensus on the treatment of rheumatoid arthritis with Chinese patent medicines. *J Altern Complement Med*.19 (2):111-118.