

Original Article

Melatonin Effect on Short Implant Supporting Kennedy Class I Removable Partial Denture in Atrophied Posterior Mandibular Alveolar Ridge

Doaa A Rostom¹, Mohamed Farouk Abdulla¹

¹Prosthodontics Department, Faculty Of Dentistry, Cairo University

Received: 22-8-2019

Accepted: 21-2-2020

email: doaa.heshmat@dentistry.cu.edu.eg

Abstract:

Background: The lack of posterior abutments is the major problem in Kennedy class I removable prosthesis because of lack of partial denture retention and stability. Short implants can be used in case of alveolar bone heights less than 10mm, the focused question is In partially edentulous patients presenting severe resorption of the posterior region of the jaws, can topical application of melatonin improve short implant success rate? **Methodology:** Eight partially edentulous patients with mandibular posterior bilaterally free end saddle (Kennedy class I) were recruited to participate in this study, The study was a split-mouth study. Each patient served as his own control (served into 2 groups), the study side (topical application of melatonin in the molar area implant side), and the control side (no melatonin in the other implant side of the same patients at the molar area). Direct digital periapical sensors were used for assessing bone volumetric changes (bone height and bone density), this record were done 3 months, 6 months and 1 year from the baseline. **Result:** result revealed that there was insignificant difference between Group I & II regarding bone density & height in all follow up periods as (P-value > 0.05) **Conclusion:** According this clinical study, Melatonin effect on increasing bone implant contact and bone density and bone height is unclear. further clinical study on human is necessary to know the effect of melatonin on the bone volumetric changes

Keywords: Melatonin, Removable denture, Short implant

Introduction:

The lack of posterior abutments is the major problem in Kennedy class I removable prosthesis, consequently there is lack of partial denture retention and stability and there is a tendency of the removable prosthesis to rotate during function, which is

also due to the different degree of compressibility nature of supporting structures, which is viscoelastic behavior of the mucosa and periodontal ligament of the natural tooth (Grasso 1991). All of these complications lead to patient discomfort and dissatisfaction (Freitas et al ,2012)

The use of mandibular free-end RPD with posterior implant as abutments is considered as an alternative treatment for the partially edentulous cases (Sato et al. 2013). Many authors reported that the use of dental implant reduce prosthesis movement and keeps the removable denture more stable.

The presence of a last distal implant with resilient attachment converts Kennedy class I or II to a Kennedy class III RPD and maintains posterior bone. (Wismeijer and tawse, 2013)

On the other hand, after a long period of time after tooth extraction, residual bone resorption occurs as disuse atrophy, the deficient bone height makes regular sized implant placement difficult. If bone height is less than 10 mm, implant supported prostheses are considered at a higher risk of failure. (Chiapasco et al, 2004)

Invasive surgical techniques can be used to solve the problem of deficient residual alveolar ridge height, such as vertical bone augmentation or inferior nerve lateralization, in order to allow placement of longer implants. These techniques are associated with postsurgical complications, expensive sensitive technique, and require long periods of rehabilitation time (Fontana et al, 2008)

Short implants have been introduced several years ago, many literature citations proved that it could provide a successful restoration, it can be used in case of alveolar bone heights less than 10mm. According to some authors a short implant is an implant with a length of 7 mm to 10mm. Using short implants is a non aggressive technique, cheap and simple instead of the invasive surgical techniques. (Felice, Cannizzaro, Barausse, Pistilli, & Esposito, 2014)

Numerous studies have stated that short implants had higher failure rates than long implants because of the small surface area and others focused on the long term success rate of short implants (Kotsovilis et al. 2009). Recently many biomimetic agents have been introduced to induce bone formation to increase bone density and bone-implant contact which could improve osseointegration and may increase rate of

implant success and durability of the implants.

Furthermore studies documented that Melatonin was an efficient biomimetic agent (Rostom, et al. 2016). Melatonin hormone functions act as an antioxidant and an anti-inflammatory agent. It reduce the process of bone resorption through reducing the osteoclast, also It can synthesis type I collagen fibers, antioxidant scavenging and detoxifying free radicals (Gomez et al. 2010 and El-Daym et al, 2014)

Thus, the aim of this study was to answer the focused question "In partially edentulous patients presenting severe resorption of the posterior region of the jaws, can topical application of melatonin improve short implant success rate?"

Methodology

According to sample size calculation with Fisher Exact test (the normal distribution of these parameters), eight partially edentulous patients, mandibular posterior bilaterally free end saddle (Kennedy class I) were recruited from the outpatient clinic of the department of Prosthodontics, Faculty of Oral and Dental Medicine, Cairo University, to participate in this study. The patient's age were 45 to 65 year old

Patients were selected according to the following inclusion criteria. The inclusion criteria were, medically free patient from any systemic diseases that might affect bone quality, sufficient posterior inter arch space, good posterior alveolar ridge bone quality, posterior bone height less than 10 mm, normal maxilla mandibular relationship (Class I Angle classification), absence of para functions and absence of TMJ pathosis.

Cone beam CTs were taken to measure the amount of bone to receive 2 submerged short implants¹, one implant at each side of the lower arch of 3.7mm diameter and 7mm length. Mouth preparation and metallic

¹ Dentuim dental implant

removable partial denture was construction, surgical template was prefabricated for inserting the implants. The study was a split-mouth study. Each patient served as his own control (served into 2 groups), the study side (topical application of melatonin in the molar area implant side), and the control side (no melatonin in the other implant side of the same patients at the molar area).

The standard implant placement protocol as recommended by the manufacturer was followed. After finishing implant drilling, short implant 7mm length was installed in the implant bed in one side, before placement of the short implant in the other side, Melatonin 2 3 mg was mixed with one drop of saline and injected in the osteotomy and then the implant was directly inserted into the prepared site without touching any surface. The implant is threaded until it's flushed with the bone, the tightening torque was 25 Ncm then the flap was sutured

After 3 months second stage surgery was done, the metal caps inserted over the ball attachment, auto-polymerized acrylic resin used for metal cap pick up, a rubber dam placed around the ball attachment for block out, and the patient was asked to occlude in centric relation .fig(1)

After complete polymerization of the acrylic resin, the denture was removed and examined. The occlusion was checked.

Direct digital periapical sensors were used for assessing bone volumetric changes (bone height and bone density), this record were done 3 months, 6 months and 1 year from the baseline (fig2)

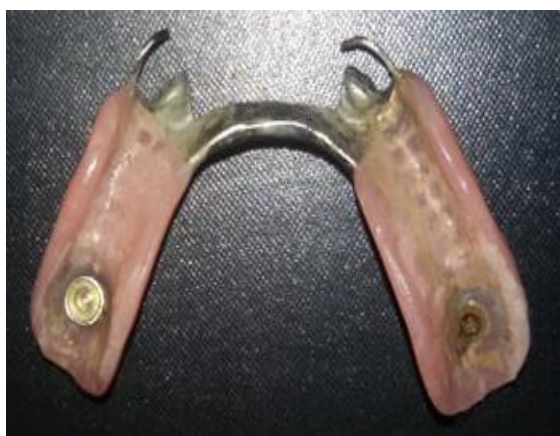

Fig (1) metal housing in the fitting surface of the partial denture



Fig (2) bone volumetric change assessment

Bone density was measured, where three lines were drawn parallel to the mesial and distal implant surfaces. The first line extended from the first thread of the implant to the implant apex passing parallel to the implant flutes and perpendicular to the implant apex. The second line was one millimeter apart, equal, and parallel to the first line. The same procedure was repeated for the third line. Bone density along each of the three lines was recorded, and then the mean value of the three readings was calculated for each surface. The mean values of the mesial and distal bone density. Bone height was measured from the crest of the ridge till the implant apex.

Every patient have its film holder and acrylic bite stent for periapical radiograph standardization. Statistical measurements were taken for bone density & bone height of both groups, mean and standard deviation were calculated. ANOVA was performed to compare between different follow up periods in each group regarding density & height

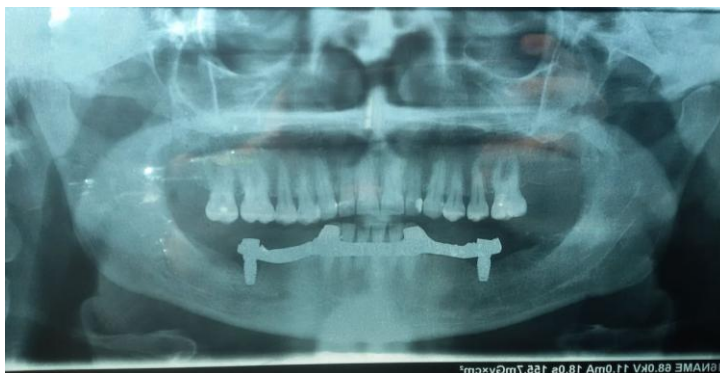

Fig (3) panoramic view to short implants with the metallic partial denture

Result:

Independent t-test was performed to compare between both groups, Group I (No melatonin) and Group II (melatonin group). One way analysis of variance (ANOVA) was performed followed by tukey's post Hok test for multiple comparisons to compare between different follow up periods in each group which revealed significant difference in bone density & bone height.

Measurements were taken for bone density & bone height of both groups, mean and standard deviation were calculated for further statistical study. For more accurate significance, mean change percentage was calculated for both groups for each follow up interval regarding density & height using the following equation:

$$\left[\frac{\text{[Bone density or height (after - Before)]}}{\text{Before}} \right] \times 100$$

In bone density, the measurements were (124 ± 30), (160 ± 45) for group I (NO melatonin group) & II (melatonin group) respectively. After 1 month follow up, there was an increase in bone density with percentage of change (4 ± 1.5) & (5.6 ± 2.1) for group I & II respectively. After three months follow up, there was a more increase in bone density calculated from the one month by (5.4 ± 2.1), (3.5 ± 1.9) for group I & II respectively. After 6 months there was further increase in density by (3.6 ± 0.8), (4.1 ± 0.9) for group I & II respectively. Finally, after 12 months there was a decrease in bone density by (-44.8 ± 5.6), (-39.5 ± 4.9) for group I & II respectively as presented in table (1) figure (1).

In Bone height. The measurements were (7 ± 1.1), (7 ± 0.9) for group I & II respectively.

After 3 months follow up, there was a decrease in bone height with percentage of change (-2.8 ± 1.1) & (-4.14 ± 1.7) for group I & II respectively. After six months follow up, there was a more decrease in bone height calculated from the three months by (-2.9 ± 1.1), (-1.9 ± 0.9) for group I & II respectively. Finally, after 12 months there was also a decrease in bone height by (-6.06 ± 1.2), (-6.6 ± 1.8) for group I & II respectively as presented in table (1) figure (4).

One way analysis of variance (ANOVA) was performed to compare between different follow up periods in each group regarding density & height that revealed significant difference ($P < 0.05$) regarding Group I & II density while revealed insignificant difference ($P > 0.05$) in group I & II height, ANOVA test was followed by tukey's post Hok test for multiple comparisons which revealed significant difference ($P < 0.05$) in means with different superscript letters while revealed in significant difference ($P > 0.05$) in means with the same superscript letters as presented in table (1).

After mean change percentage calculation, Independent t-test was performed to calculate and significance between both groups which concluded that there was insignificant difference between Group I & II regarding bone density & height in all follow up periods as ($P\text{-value} > 0.05$) as listed in table (2) and showed in figure (5).

Table (1): Bone density & height of group I & II

	Follow up	Group I (No Melatonin)	Group II (Melatonin)	P value
		M ± SD	M ± SD	
Bone Density	At baseline	124 a ± 30	160 a ± 45	0.089
	After 1 month	129 a ± 39	169 a ± 45	0.164
	After 3 months	136 a ± 33	175 a ± 46	0.068
	After 6 months	141 a ± 37.8	182 a ± 49.6	0.085
	After 12 months	86 b ± 21	110 b ± 28	0.078
	P value	0.015*	0.019*	
Bone Height	At baseline	7.00 a ± 1.11	7.00 a ± 0.99	0.991
	After 3 months	6.89 a ± 1.06	6.71 a ± 0.91	0.718
	After 6 months	6.61 a ± 0.88	6.58 a ± 0.83	0.806
	After 12 months	6.25 a ± 0.98	6.17 a ± 0.85	0.817
	P value	0.3	0.21	

M; Mean, SD; Standard deviation

*Significant difference

Table (2): Mean change percentage for both groups for each interval:

	Group I (No Melatonin)	Group II (Melatonin)	P-value	
	M % ± SD	M % ± SD		
Bone density	0-1 month	4.03 a ± 1.5	5.6 a ± 2.1	0.146
	1-3 months	5.4 a ± 2.1	3.5 a ± 1.9	0.078
	3-6 months	3.6 a ± 0.8	4.1 a ± 0.9	0.259
	6-12 months	-44.8 b ± 5.6	-39.5 b ± 4.9	0.066
	0-12 months	-27.7 b ± 6.5	-21.4 b ± 6.3	0.069
	P-value	0.000*	0.000*	
Bone height	0-3 months	-2.85 a ± 1.1	-4.14 a ± 1.7	0.082
	3-6 months	-2.94 a ± 1.1	-1.92 a ± 0.91	0.062
	6-12 months	-6.06 b ± 1.2	-6.61 a ± 1.8	0.491
	0-12 months	-11.42 c ± 2.6	-12.85 b ± 2.9	0.318
	P value	0.000*	0.000*	

M; Mean, SD; Standard deviation, P: *insignificant difference**significant difference

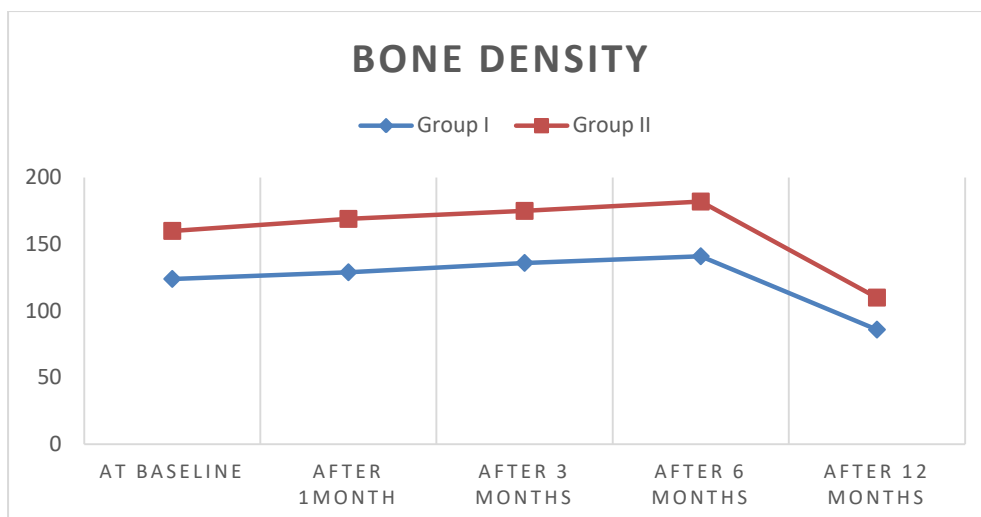


Fig (4): Bone density of group I & II.

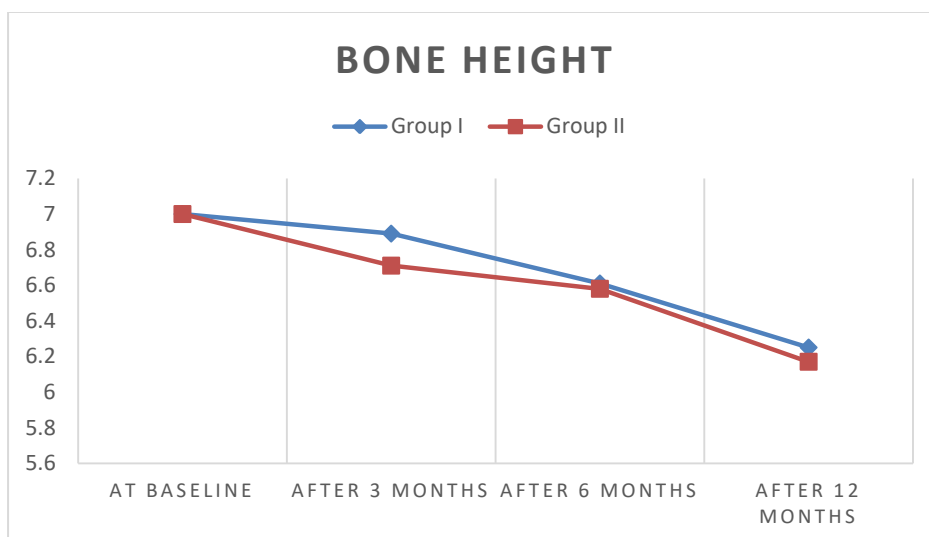


Fig (5): Bone height of group I&II

Discussion

Regarding short implant success rate, Kotsovilis et al. (2009) found no statistical difference between short (≤ 8 or < 10 mm) and conventional (≥ 10 mm) implants, but they did not perform a meta-regression analysis per implant length. Romeo et al. (2010) also found a similar survival rate for short and standard implants. Systematic review 2011 concluded that placing short implant in the mandible is more successful than placing it in the maxilla ((Tuppurainen et al., 2011)

Bone quality, a traumatic surgical protocols and occlusal overload play a major role in short-implant prognosis than prosthetic features, therefore all bruxier patient or with para-fauncions are excluded from the study (Paquette, Brodala, & Williams, 2006).

In the resorbed regions restored with short implant supporting single crown are subjected to occlusal overload because the clinical crown height may be greater than the implant length. This poor C/I ratio will lead to excessive occlusal loading and with a nonaxial loading creating bending moment which may lead to technical and biological complications (Monje et al., 2014), in our clinical study,

resilient ball attachment was used as reduce the occlusal loading of force over the implant plus it provide good and stable retention capacity , then it solve the kennedy class I problem and improve patient satisfaction (Zhang et al. 2008)

According to a systemic review in 2012 ,it was reported that association of dental implant with removable partial denture have stress braking action ,distribute the load between the abutment and dental implant thus reduce the forces over the implant especially the short implant thus improves the prosthetic biomechanics(De Freitas et al ,2012). Keltjens et al. 1993 showed that implant retaining removable partial denture improves biting force and patient comfort

The deficient residual alveolar ridge mainly associated with poor bone quality which may affect short implant survival rate. Melatonin was used in this study because according to many articles, it was found that melatonin acts on osteoclasts, reducing the formation of free radicals, also it has antioxidant activities, through detoxifying the free radicals produced during osteoclastogenesis. This improve may improve bone implant contact (Reiter et al. 2015 , Gomez, et al .2015)

Some normal life style action like smoking, alcohol consumption and high-fat diet generate free radical, Free radicals are also increasingly generated with age and are produced due to oxidative stress which can lead to excessive bone resorption, Maria et al, 2014 said that Melatonin's is a direct free-radical scavenger and as an indirect antioxidant which melatonin increased bone density and bone implant contact

The purpose of this study was to increase the bone density around the short implant to increase its survival rate especially in the posterior region where the occlusal loads are very high, in the study the bone density and bone height mean value in the side of the melatonin application is higher than the other side with no melatonin, this could be due to the fact that melatonin have biomemetic agent (Rostom, et al. 2016)

Scientific literatures proved that during the first month after implantation, bone density show marked reduction for almost all the cases, this related to the remodeling process of the alveolar bone that is initiated by the insertion of the implant and the activation of the osteoclasts. After six month the bone remodeling changes become stable ,that's why in our study we measure bone density one month postoperative ,considered as one of our exploratory data (Hasan et al., 2014)

The study result proved that after 1 month follow up, there was an increase in bone density with percentage of change (5.6 ± 2.1) for melatonin group and after three and 6 months there was further increase in density by (4.1 ± 0.9) for melatonin group, The increase in the bone density could be owing to the action of melatonin application and to the effects of melatonin on bone formation. Tao Sun et al , 2019 reported in histological analytical study that melatonin build new bone around the implants after 12 weeks from implantation day , which result in increase in the bone area ratio and bone to implant contact

The result showed that there is no significant difference regarding bone density and height for both group this may be as result of the small sample size. Many authors reported increase of the bone implant contact at melatonin area and they said that this is due to increased new cortical bone width and length during the early stages within 15 and 30 days by the melatonin action, which also promoted early cell differentiation (Calvo-Guirado et al.2009)

Many articles offered new evidence that melatonin stimulates proliferation and type I collagen melatonin increases the peri-implant osteogenesis in synthesis in human bone cells in vitro, other articles studies revealed that melatonin enhance healing around the implants ,but unfortunately all these studies were histological animal study.

As shown from the study, the patient was satisfied with their short implant for both groups, they reported an improvement in their chewing ability, better partial denture retention , less cost and little post-operative

discomfort ,2013 Sporniak-Tutak concluded in a systematic review that the use of short implants associated with improvement in clinical outcomes , decreased the risk of complications , patient discomfort. And high success rate of short implants which can be good alternative to the conventional implant

References

Calvo-Guirado JI, GÓmez-Moreno G, Maté-Sánchez Je, López-Març L, Delgado-Ruiz R, Romanos Ge. (2015)New Bone Formation In Bone Defects Aft Er Melatonin And Porcine BoneGraft S: Experimental Study In Rabbits. *Clin Oral Implants Res*;26:399-406.

Carvalho W, Casado Pl, Caúla Al, Barboza Ep. (2004)Implants For Single First Molar Replacement: Important Treatment Concerns. *Implant Dent*; 13: 328-335 [Pmid: 15591994]

Chiapasco M, Romeo E, Casentini P, Rimondini L.(2004) Alveolar Distraction Osteogenesis Vs. Vertical Guided Bone Regeneration For The Correction Of Vertically Deficient Edentulous Ridges: A 1-3-Year Prospective Study On Humans. *Clin Oral Implants Res*;15:82–95.

De Freitas, R. F. C. P., De Carvalho Dias, K., Da Fonte Porto Carreiro, A., Barbosa, G. A. S., & Ferreira, M. Â. F. (2012). Mandibular Implant-Supported Removable Partial Denture With Distal Extension: A Systematic Review. *Journal Of Oral Rehabilitation*, 39(10), 791–798. Doi:10.1111/J.1365-2842.2012.02326.X

Esposito M., Grusovin M.G., Rees J., Karasoulos D., Felice P., Alissa R., Worthington H.V. & Coulthard P. (2010) Interventions For Replacing Missing Teeth: Augmentation Procedures Of The Maxillary Sinus. *The Cochrane Database Of Systematic Reviews* 17, Cd008397

Felice, P., Cannizzaro, G., Barausse, C., Pistilli, R., & Esposito, M. (2014). Short Implants Versus Longer Implants In Vertically Augmented Posterior Mandibles: A Randomised Controlled Trial With 5-Year

Conclusion:

According this clinical study, Melatonin effect on increasing bone implant contact and bone density and bone height is unclear. Throughout the one year of function the short implant survived with no failure, but further clinical study on human is necessary to know the effect of melatonin on the bone volumetric changes.

After Loading Follow-Up. *European Journal Of Oral Implantology*, 7(4), 359–69. Retrieved From [Http://www.Ncbi.Nlm.Nih.Gov/Pubmed/25422824](http://www.ncbi.nlm.nih.gov/pubmed/25422824).

Fontana F, Santoro F, Maiorana C, Iezzi G, Piattelli A, Simion M(2008). Clinical And Histologic Evaluation Of Allogenic Bone Matrix Versus Autogenous Bone Chips Associated With Titanium-Reinforced E-Ptfe Membrane For Vertical Ridge Augmentation: A Prospective Pilot Study. *Int J Oral Maxillofac Implants*;23:1003–1012.

Grasso Je, Miller El. 3rd Ed. Mosby: St. Louis; (1991). *Removable Partial Prosthodontics*; Pp. 205–8.

Greenstein G, Tarnow D. (2006)The Mental Foramen And Nerve: Clinical And Anatomical Factors Related To Dental Implant Placement: A Literature Review. *J Periodontol*; 77: 1933-1943 Implants. *Journal Of Periodontology* 80, 1700– 1718.

Hasan, I., Dominiak, M., Blaszczyzyn, A., Bourauel, C., Gedrange, T., &Heinemann, F. (2014). Radiographic evaluation of bone density around immediately loaded implants. *Annals of Anatomy*, 2–7.

Jivraj S, Chee W. (2006)Treatment Planning Of Implants In Posterior Quadrants. *Br Dent J*; 201: 13-23 [Pmid: 16829878]

Keltjens Hm, Kayser Af, Hertel R, Battistuzzi Pg. (1993)Distal Extension Removable Partial Dentures Supported By Implants And

- Residual Teeth: Considerations And Case Reports. *Int J Oral Maxillofac Implants*;8:208–213.
- Kotsovilis, S., Fourmousis, I., Karoussis, I. K. & Bamia, C. (2009) A Systematic Review And Meta-Analysis On The Effect Of Implant Length On The Survival Of Rough-Surface Dental
- Sun, T., Li, J., Xing, H. L., Tao, Z. S., & Yang, M. (2019). Melatonin improves the osseointegration of hydroxyapatite-coated titanium implants in senile female rats. *Zeitschrift Fur Gerontologie Und Geriatrie*
- Maria S, Witt-Enderby Pa. (2014) Melatonin Effects On Bone: Potential Use For The Prevention And Treatment For Osteopenia, Osteoporosis, And Periodontal Disease And For Use In Bonegrafting Procedures. *J Pineal Res*;56(2):115-25.
- Massey Nd, Galil Ka, Wilson Td. (2013) Determining Position Of The Inferior Alveolar Nerve Via Anatomical Dissection And Micro-Computed Tomography In Preparation For Dental Implants. *J Can Dent Assoc*; 79: D39 [Pmid: 23920072]
- Monje, A., Suarez, F., Galindo-Moreno, P., García-Nogales, A., Fu, J. H., & Wang, H. L. (2014). A Systematic Review On Marginal Bone Loss Around Short Dental Implants (<10 Mm) For Implant-Supported Fixed Prostheses. *Clinical Oral Implants Research*, 25(10), 1119–1124. Doi:10.1111/Clr.12236.
- Moreno G, Aguilar-Salvatierra A, Boquete-Castro A, Guardia J, Piattelli A, Perrotti V, Et Al. Outcomes Of Topical Applications Of Melatonin In Implant Dentistry A Systematic Review. *Implant Dent* 2015;24:25-30.
- Paquette, D. W., Brodala, N., & Williams, R. C. (2006). Risk Factors For Endosseous Dental Implant Failure. *Dental Clinics Of North America*, 50(3), 361–374.
- Reiter Rj, Rosales-Corral Sa, Liu Xy, Acuna-Castroviejo D, Escames G, Tan Dx. (2015) Melatonin In The Oral Cavity: Physiological And Pathological Implications. *J Periodontal Res*;50:9-17.
- Rostom, D. A. A. H., Ela, A. A., & Abdalla, M. F. (2016). Effect Of Melatonin On Osseointegration Of Immediate Loading Implant Supported Mandibular Over Denture: Randomized Clinical Trail. *International Dental & Medical Journal Of Advanced Research - Volume 2015, 2(1), 1–5. Doi:10.15713/Ins.Idmjar.55.*
- Sato M, Suzuki Y, Kurihara D, Shimpo H, Ohkubo C. (2013) Effect Of Implant Support On Mandibular Distal Extension Removable Partial Dentures: Relationship Between Denture Supporting Area And Stress Distribution. *J Prosthodont Res*;57:109-112
- Sporniak-Tutak, K. (2013). Short Dental Implants In Reduced Alveolar Bone Height: A Review Of The Literature. *Medical Science Monitor*, 19, 1037–1042.
- Sporniak-Tutak, K. (2013). Short Dental Implants In Reduced Alveolar Bone Height: A Review Of The Literature. *Medical Science Monitor*, 19, 1037–1042. Doi:10.12659/Msm.889665.
- Tuppurainen, K., Pukkila, L., Tuomisto, A., Kuivila, R., Sirniö, P. H., Karttunen, T. J., & Mäkinen, M. (2011). Colorectal Serrated Adenocarcinoma To Cite This Version : R Fo Pe Er Re Vi.
- Vazquez L, Nizam Al Din Y, Christoph Belser U, Combescure C, Bernard Jp. (2011) Reliability Of The Vertical Magnification Factor On Panoramic Radiographs: Clinical Implications For Posterior Mandibular Implants. *Clin Oral Implants Res*; 22: 1420-1425 [Pmid: 21435009 Doi: 10.1111/J.1600-0501.2010.02131.X
- Wismeijer D, Tawse-Smith A, Payne Ag. Multicentre Prospective (2013) Evaluation Of Implant-Assisted Mandibular Bilateral Distal Extension Removable Partial Dentures: Patient Satisfaction. *Clin Oral Implants Res*;24:20-7
- Zhang, R.G., Hannak, W.B., Roggensack, M. & Freesmeyer, W.B. (2008) Retentive Characteristics Of Ankylos Syncone Conical Crown System Over Long-Term Use In Vitro. *European Journal Of Prosthodontics And Restorative Dentistry* 16:61–66.