

**Technical Report**

# Pre-Extractive Inter-Radicular Implant Bed Preparation versus Conventional Post-Extractive Inter-Radicular Implant Bed Preparation in Mandibular Molars: A Randomized Clinical Trial

Mohamed Abdel Wahid Elshoaby\*<sup>1</sup>

<sup>1</sup> Implantology Department, Faculty of Dentistry, Cairo University, Egypt.

email: mohamedalshoabi89@gmail.com

Received: 30-12-2019

Accepted: 11-2-2020

## Abstract

**Aim:** to assess the implant stability and amount of crestal bone loss in immediate implant placement in mandibular molars by using pre-extractive inter-radicular implant bed preparation versus conventional post-extractive inter-radicular implant bed preparation. **Subjects and Methods:** Twenty patients (5 males, 15 females), suffering from badly decayed vital or non-vital posterior mandibular molar teeth were selected and randomly divided into 2 groups, 10 per group; the first group received Pre-extractive interradicular implant bed preparation while the second group received Conventional post-extractive interradicular implant bed preparation. **Results:** immediate Implant stability results that assessed using Osstell device measuring ISQ values between groups were ( $58 \pm 0.81$  ISQ units) for the test group and ( $54.6 \pm 1.07$  ISQ units) for the control group at immediate implant placement which represent significant differences ( $p < 0.001$ ). marginal bone loss results of mesial and distal bones between one-year and six-months' post-operative implant placement were ( $0.21 \pm 0.09$  mm) in the test group and ( $0.37 \pm 0.17$  mm) in the control group and marginal bone loss results of buccal and lingual bones between same periods were ( $0.21 \pm 0.04$  mm) in the test group and ( $0.42 \pm 0.21$  mm) of the control groups with significant differences of ( $p = 0.022^*$ ) in mesial and distal bone loss and ( $p = 0.006^*$ ) in buccal and lingual bone loss between groups. **Conclusion:** Implants that placed by pre-extractive inter-radicular implant bed preparation had a high primary stability and a less marginal bone loss in both bucco-lingual and mesio-distal dimensions from six-months to one-year than that placed by post-extractive inter-radicular implant bed preparation.

**Keywords:** Immediate implant placement, dental implant, mandibular molar, implant stability, crestal bone loss.

## 1) Introduction

The anatomy of the posterior mandible, including the variability in the position of the inferior alveolar canal and the submandibular

fossa, may pose a high risk for inferior alveolar nerve injury and lingual plate perforation when attempting to achieve primary implant stability using native bone apical to the extraction socket.<sup>3</sup>

In molar extraction sockets, achieving initial implant stability may be challenging as a result of the width of the alveolar socket, poor bone quality and anatomical limitations beyond the apices of molar roots such as the inferior alveolar nerve. Therefore, in most cases the implant must be placed within the molar extraction socket itself.<sup>4</sup>

The protocol of immediate implant placement offers several advantages including a reduction in the number of the surgical procedures, preservation of esthetics, bone height and width, improved quality of life and increased patient comfort and satisfaction.<sup>6</sup>

Placing implants in an ideal position without compromising their primary stability represents a critical issue. The initial osteotomy must be directed into the medial portion of the alveolus while engaging the interradicular septum of the extraction socket. The drill may continuously slip, leading to inaccurate site preparation, and consequently to a deficient implant insertion. The implant is often placed directly into the extraction socket of the tooth to replace.<sup>10</sup>

## 2) Patients And Methods

Twenty patients (5 males, 15 females), suffering from badly decayed vital or non-vital posterior mandibular molar teeth, were selected from the outpatient clinic of Oral and Maxillofacial Surgery Department, Faculty of Dentistry, Cairo University to be included in this study. The present study was approved by the ethics committee at the Faculty of Dentistry, Cairo University. Each patient considered for the present study received only one implant. The selected patients were informed of the nature of the research. A written informed consent for surgical procedures and the use of clinical and radiographical data were obtained from each patient.

The patients were randomly divided using the sequentially numbered sealed

envelope. Random numbers were used to divide patients into two groups according to the drilling protocol used in implant placement. The test group received implant placed by pre-extractive inter-radicular implant bed preparation while control group received implant placed by conventional post-extractive inter-radicular implant bed preparation. All surgeries were performed by the same surgeon.

The inclusion criteria of this study was: (1) minimum alveolar bucco-lingual dimension of 6mm, (2) minimum septa coronal portions of 2.5 mm and minimum apical portions of 3.5 mm, (3) minimum distance from height of inter-radicular furcation of mandibular molars to the mandibular canal should be 10 mm, (4) minimum distance between roots apices and superior border of inferior alveolar nerve is 5mm, (5) peri-apical pathosis smaller than 2mm and (6) minimum thickness of buccal cortical plate of bone is 1mm with intact buccal and lingual plate of bone.

The exclusion criteria of this study was: (1) patients with systemic condition of high risk of bleeding (INR >3-3.5, platelet count <50,000/mm<sup>3</sup>) that affect normal healing, (2) patient under intravenous bisphosphonate treatment, (3) smoker patients, (4) periapical infections related to the tooth to be extracted causing radiolucency larger than 3mm.

Post-operative assessments were done as following: 1) *Clinical assessment*: Patients were called for follow-up 1-week post-operative and weekly for the first month, then monthly for six months, and were assessed for healing and implant threads exposures. 2) *Osstell assessment for implant stability*: The immediate and six-months' post-operative implant stability readings were assessed using Osstell device. A smart peg tool was tightened over each implant and Osstell tip was put at five surfaces of the implant which were occlusal, buccal, lingual, mesial and distal to get the average number of those readings.

*3) Radiographic assessment of crestal bone loss:* The immediate, six-months' post-operative and one-year post-operative CBCTs were assessed using Romexis Planmeca dicom viewer software. Standardization was done by the following steps: On 3D orthogonal plan, the long axis of the software was put on the long axis of the implant and perpendicular on buccolingual and mesiodistal axis. A standardized thickness and gap interval of 0.4 mm for all explorer views of all implants was set. A tangential line on the base of the implant and other lines on the highest point buccal, lingual, mesial and distal were put and the distance between them were measured. A three readings for a three cuts were measured which were the middle cut of the implant, cut before and cut after for taking the average of those three cuts and this were done for each side of buccal, lingual, mesial and distal.

### **3 ) Surgical And Prosthetic Procedures**

Pre-operative antibiotics were administered orally 1 hour before procedure. All procedures were performed under local anesthesia using Articaine 4% 1:100 000 epinephrine. Sectioning of the unrestorable mandibular molars was performed using fissure bur size 3 for atraumatic extraction under copious amounts of irrigation (figure 1).

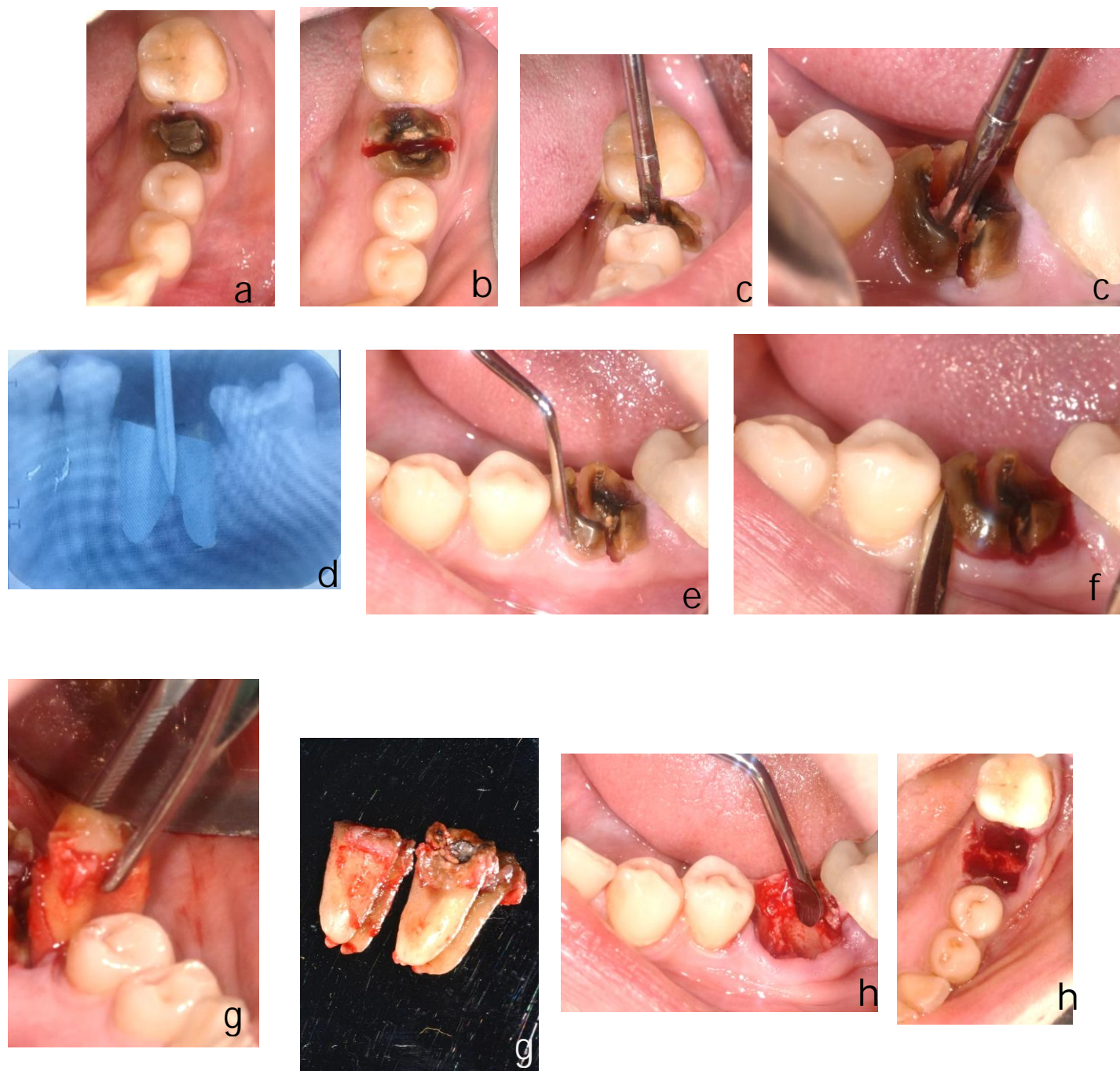
In the test group, Pre-extractive inter-radicular implant bed preparation was done after root separation in the regular sequence of drilling starting with point dill till the final drill before roots extraction and implant placement (figure 1). While in the control group, Post-extractive inter-radicular implant bed preparation was done after roots extraction in the regular sequence of drilling starting with point dill till the final drill and then implant placement (figure 4).

For all cases, a Periotope was used to cut the periodontal ligament attachments after tooth sectioning for atraumatic extraction (figures 1,4). Then the roots were luxated with

straight elevator (figures 1,4). Finally, remaining roots extraction using extraction forceps with extreme care to preserve integrity of buccal and lingual plates of bone (figures 1,4). For all cases, a proper debridement of extraction sockets using bone curette was done (figures 1,4). Implants were installed in the interseptal bone with 1mm apical to the buccal plate of bone (figures 2, 4).

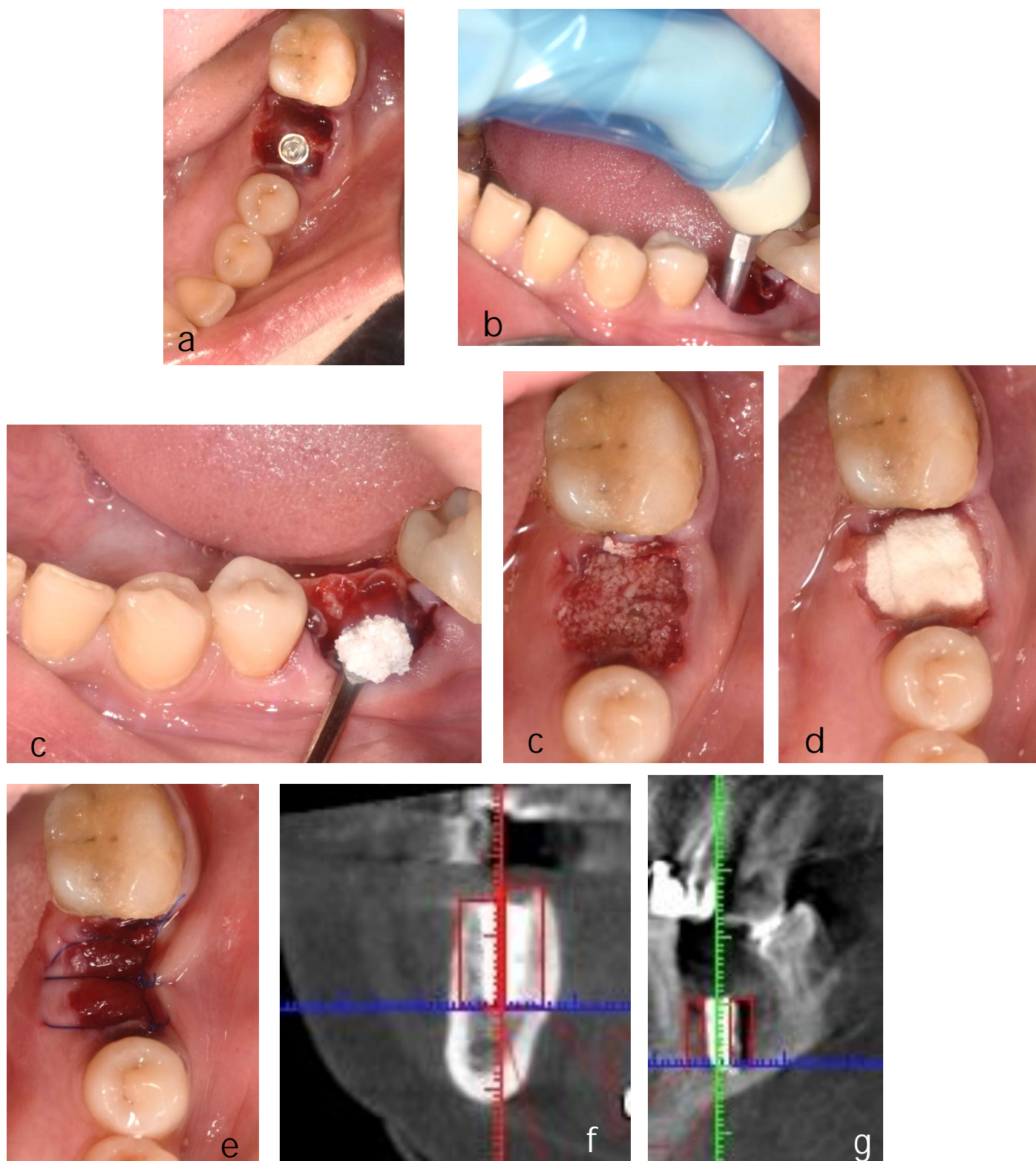
After implant placement, a smart peg tool was tightened over each implant and Implant Stability Quotient (ISQ) were measured using Osstell device (figures 2,4). The gap around the implant in the extraction socket was completely packed using xenograft bone particles (figure 2,4). After bone graft application, the extraction socket was covered using resorbable collagen membrane (gel foam) (figure 2,4). The collagen membrane was stabilized and the extraction socket was covered using horizontal mattress suture by 4-0 prolene suture material (figures 2,5). Immediately Postoperative CBCT after implant placement were done for radiographic assessment of crestal bone level of buccolingual and mesiodistal views of the two groups (figures 2,5)

After six-months of implant placement, a second stage surgery was performed making the incision slightly lingual to have more keratinized tissues on the buccal side. Gingival former was tightened above dental implant after cover screw removal for 2 weeks before impression was taken (figures 3,5). Smart peg tool was tightened over each implant for implant stability measurements before prosthesis fabrication (figures 3,5). Impression was taken with rubber base material after tightening of implant transfer above the dental implant. Final porcelain fused to metal crown was cemented by reinforced zinc oxide and eugenol cement (figures 3,5). Six-months' and one-year post-operative CBCTs after implant placement were done for radiographic assessment of crestal bone level of buccolingual and mesiodistal views of the two groups (figures 3, 5).

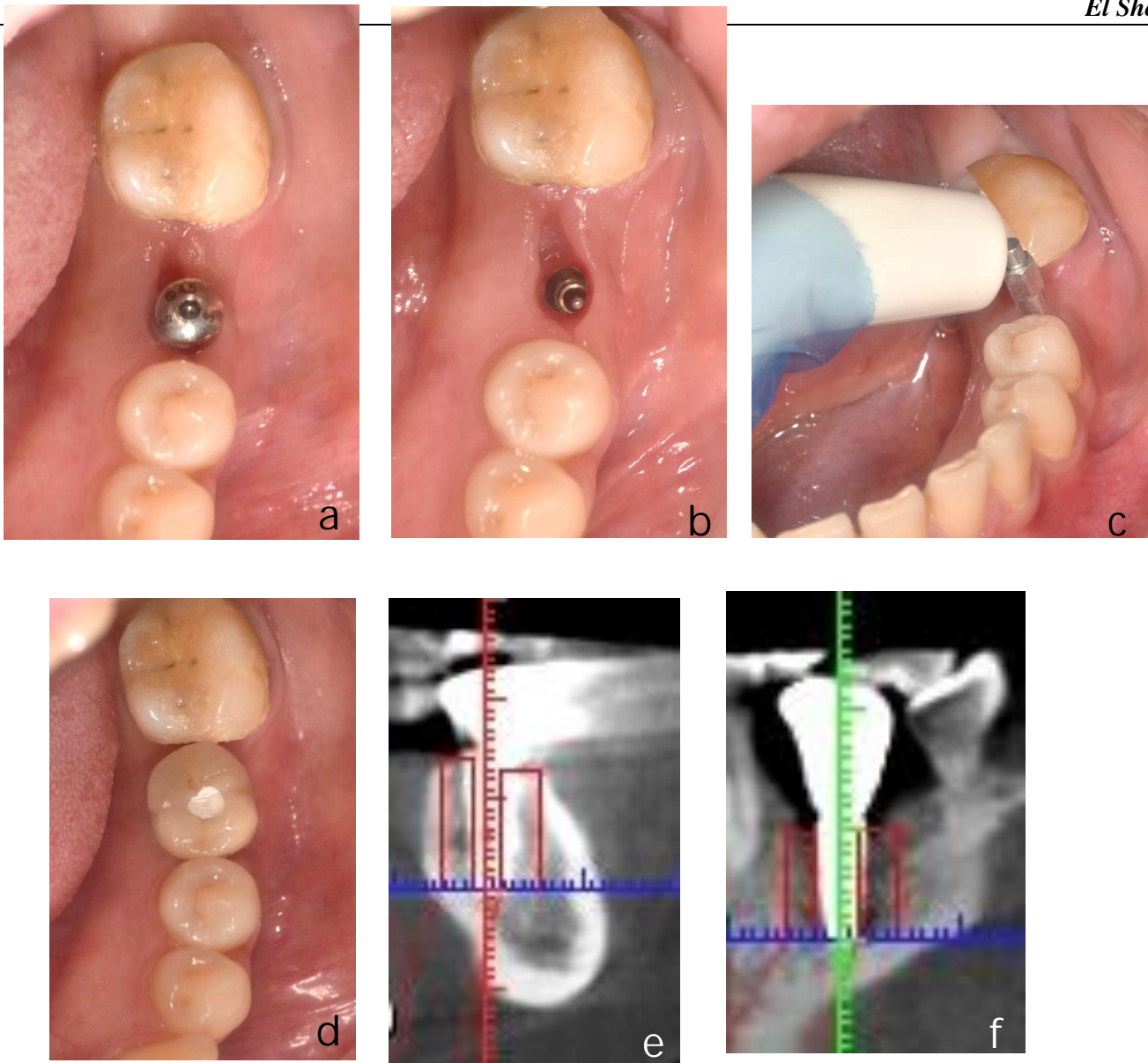


**Figure 1:**(a) Showing clinical view of badly decayed tooth no. 36 (b) Showing root separation of badly decayed tooth no.36 . (c) Showing point drill in the proper position bucco-lingually and in the inter-radicular bone of the tooth no.36 . (d) Periapical x-ray showing point drill penetrating the bifurcation of the two roots of the badly decayed tooth no. 36 (e) Showing Periosteal application for cutting surrounding periodontal ligament attachments of the tooth no.36 (f) Showing straight elevator application and final roots delivery of the tooth no.36 . (g) Showing final roots delivery of the tooth no.36 (h) Showing socket curettage using curettes to the empty socket of the tooth no.36



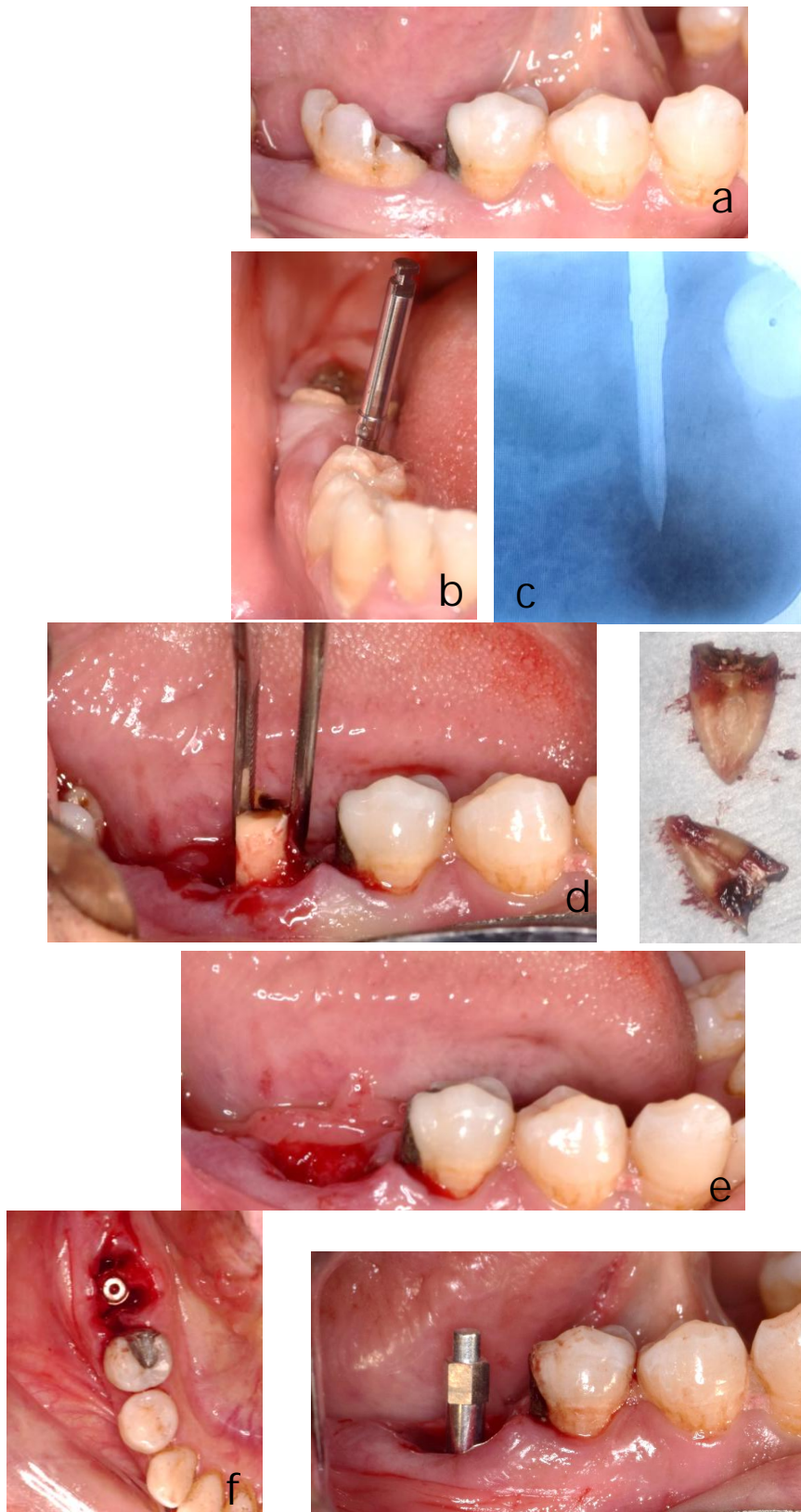


**Figure 2:** (a) Showing implant placement in the inter-radicular bone of the socket of the tooth no.36 (b) Showing smart peg application and implant stability measurements of the implant placed in the socket of the tooth no.36 (c) Showing xenograft bone application around the implant in the extraction socket of the tooth no.36 (d) Showing resorbable collagen membrane covering the extraction socket of the tooth no.36 (e) Showing horizontal mattress suture stabilizing the resorbable collagen membrane which covering the extraction socket of the tooth no.36 (f) Showing radiographic assessment of crestal bone level of buccolingual view of Postoperative CBCT immediately after implant placement replacing tooth no. 36 (g) Showing radiographic assessment of crestal bone level of mesiodistal view of Postoperative CBCT immediately after implant placement replacing tooth no. 36

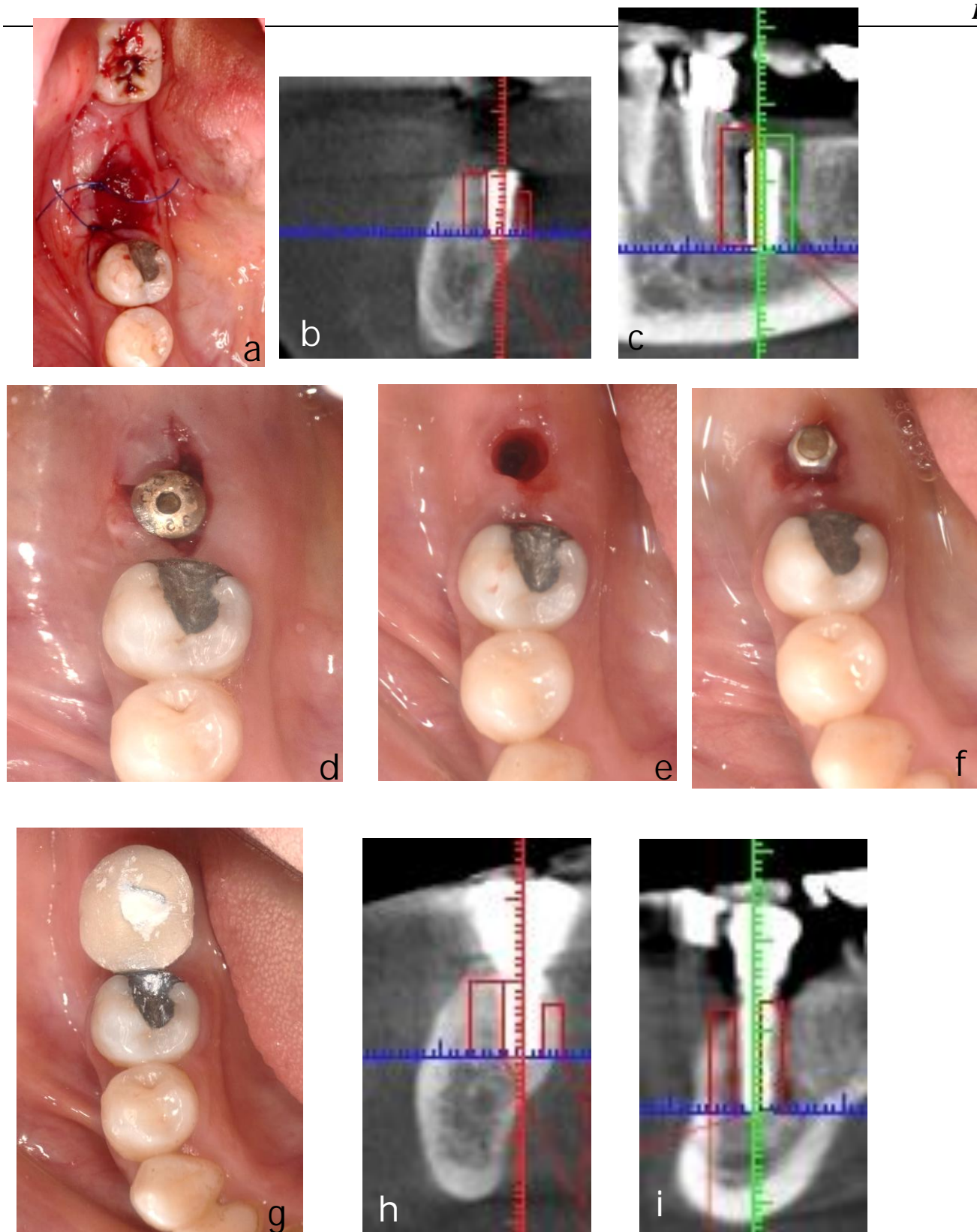


**Figure 3** (a) Showing clinical view of gingival former replacing tooth no. 36 after six months . (b) Showing clinical view of soft tissue around implant after gingival former removal replacing tooth no. 36 (c) Showing smart peg application and implant stability measurements of implant replacing tooth no. 36 (d) Showing final crown cementation over implant replacing tooth no. 36 (e) Showing radiographic assessment of crestal bone level of buccolingual postoperative cross section view of crown was cemented over implant replacing tooth no. 36 (f) Showing radiographic assessment of crestal bone level of mesiodistal postoperative cross section view of crown was cemented over implant replacing tooth no. 36





**Figure 4** (a) Showing clinical view of badly decayed tooth no. 46 . (b) Showing point drill in the proper position bucco-lingually and in the inter-radicular bone of the tooth no.46. (c) Periapical x-ray showing point drill penetrating the bifurcation bone of tooth no. 46 . (d) Showing final roots delivery of the tooth no.46 (e) Showing empty socket of the tooth no.46 after socket curettage (f) Showing implant placement in the inter-radicular bone of the socket of the tooth no.46 (g) Showing smart peg application and implant stability measurements of the implant placed in the socket of the tooth no.46



**Figure 5:** (a) Showing horizontal mattress suture stabilizing the resorbable collagen membrane which covering the extraction socket of the tooth no.46 (b) Showing radiographic assessment of crestal bone level of buccolingual view of Postoperative CBCT immediately after implant placement replacing tooth no. 46 (c) Showing radiographic assessment of crestal bone level of mesiodistal view of Postoperative CBCT immediately after implant placement replacing tooth no. 46 (d) Showing clinical view of gingival former replacing tooth no. 46 after six months (e) Showing clinical view of soft tissue around implant after gingival former removal replacing tooth no. 46 (f) Showing smart peg application and implant stability measurements of implant replacing tooth no. 46 (g) Showing final crown cementation over implant replacing teeth no. 46 (h) Showing radiographic assessment of crestal bone level of buccolingual postoperative cross section view of crown was cemented over implant replacing tooth no. 46 (i) Showing radiographic assessment of crestal bone level of mesiodistal postoperative cross section view of crown was cemented over implant replacing tooth no. 46



#### 4) Results

##### I. Demographic Characteristics:

The current study was conducted on 20 patients (15 females and 5 males). They were assigned into two equal groups. Group (A) consisted of 10 patients (8 females and 2 males) with mean age and tooth number values of  $35.3 \pm 5.29$  years and  $42.3 \pm 5.01$  respectively. Group (B) consisted of 10 patients (7 females and 3 males) with mean age and tooth number values of  $35.1 \pm 5.68$  years and  $40.8 \pm 5.13$  respectively.

##### II. Osstell assessment of implant stability:

Considering the effect of the tested group (first independent variable) on Osstell reading, unpaired t test revealed that the mean values of the " immediate implant placement " between both groups showed significant differences with their t and P-values were (t-value= 7.956,  $P=0.0001^*$ ) and this significant increase in group A in compared to group B. While, unpaired t test revealed that there was no significant difference of the mean values of the " post six months' post-operative" between both groups with their t and P-values were (t-value= 2.06,  $P=0.054$ ). (table 1, Figure 6)

##### III. Marginal bone level changes:

First measurement: between immediately and 6 months after implant placement;  
Second measurement: between 6 months and 1 year after implant placement; Third

measurement: between immediately and 1 year after implant placement.

##### a. Changes of buccal and lingual bone margins:

Multiple pairwise comparison tests (Post hoc tests) revealed that the mean values of the "First Measurement" test between both groups showed no significant differences with ( $P=0.168$ ). While there was significant reduction of the mean values of the " Second Measurement " test at study group in compared to control group with ( $p=0.006^*$ ). Additionally, there was no significant difference of the mean values of the " Third Measurement " test between both groups with ( $p=0.06$ ). (table 2, Figure 7)

##### b. Changes of mesial and distal bone margins:

Multiple pairwise comparison tests (Post hoc tests) revealed that the mean values of the "First Measurement" test between both groups showed no significant differences with ( $P=0.467$ ). While there was significant reduction of the mean values of the " Second Measurement " test at study group in compared to control group with ( $p=0.022^*$ ). Additionally, there was no significant difference of the mean values of the " Third Measurement " test between both groups with ( $p=0.173$ ). (table 3, Figure 8)

**Table (1):** Mean  $\pm$ SD and p values of Osstell reading immediate and post six months' post-operative implant placement at both groups.

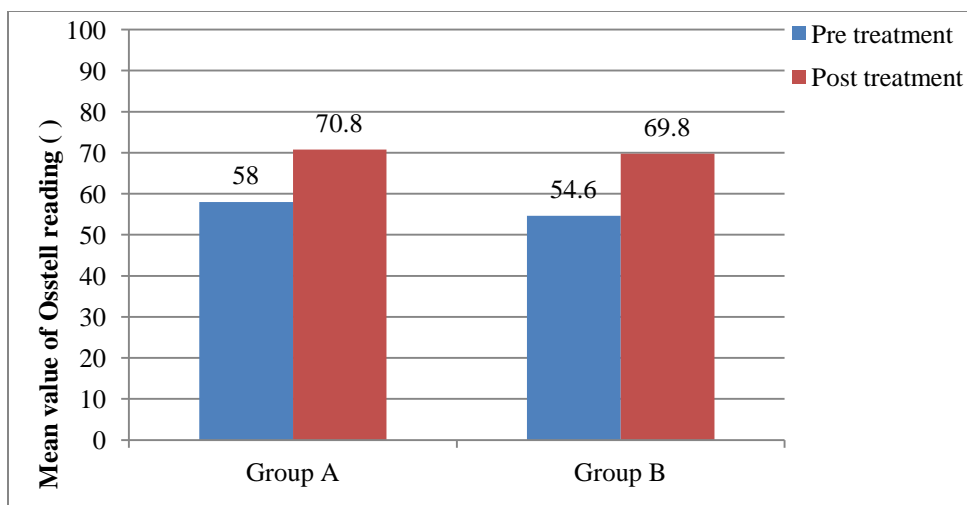
Osstell reading	Immediate	Six months
	implant placement	post-operative
	Mean $\pm$ SD	Mean $\pm$ SD
Group A	58 $\pm$ 0.81	70.8 $\pm$ 1.31
Group B	54.6 $\pm$ 1.07	69.8 $\pm$ 0.78
p- value	0.0001*	0.054

**Table (2).** Descriptive statistics and 2×3 mixed design MANOVA for Changes of buccal and lingual bone margins at different measuring periods at both groups.

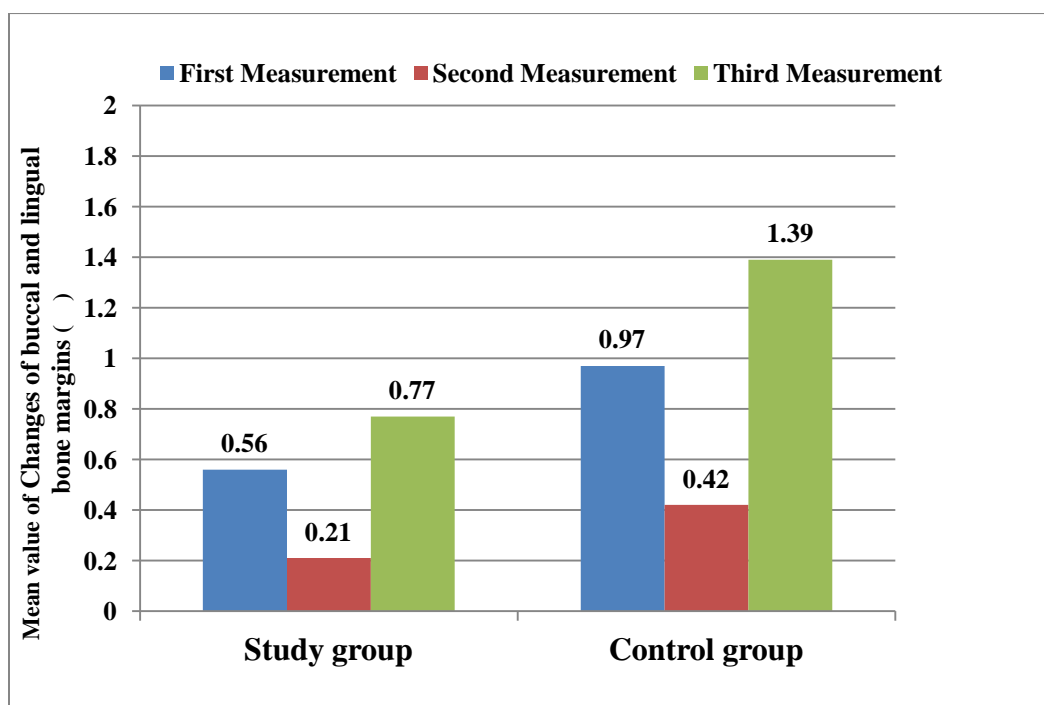
<i>Changes of buccal and lingual bone margins</i>	<i>First Measurement (Mean±SD)</i>	<i>Second Measurement (Mean±SD)</i>	<i>Third Measurement (Mean±SD)</i>
<b>Test group</b>	0.56±0.35	0.21 ±0.04	0.77±0.33
<b>Control group</b>	0.97±0.82	0.42±0.21	1.39±0.92
<i>Multiple pairwise comparison tests (Post hoc tests) for the Changes of buccal and lingual bone margins between both groups at different measuring periods</i>			
<b>Test group Vs. Control group</b>	<i>First Measurement</i>	<i>Second Measurement</i>	<i>Third Measurement</i>
<b>P-value</b>	0.168	0.006*	0.06

**Table (3).** Descriptive statistics and 2×3 mixed design MANOVA for Changes of mesial and distal bone margins at different measuring periods at both groups.

<i>Changes of mesial and distal bone margins</i>	<i>First Measurement (Mean±SD)</i>	<i>Second Measurement (Mean±SD)</i>	<i>Third Measurement (Mean±SD)</i>
<b>Test group</b>	0.73±0.48	0.21 ±0.09	0.94±0.53
<b>Control group</b>	0.88±0.41	0.37±0.17	1.25 ±0.43
<i>Multiple pairwise comparison tests (Post hoc tests) for the Changes of mesial and distal bone margins between both groups at different measuring periods</i>			
<b>Test group Vs. Control group</b>	<i>First Measurement</i>	<i>Second Measurement</i>	<i>Third Measurement</i>
<b>P-value</b>	0.467	0.022*	0.173

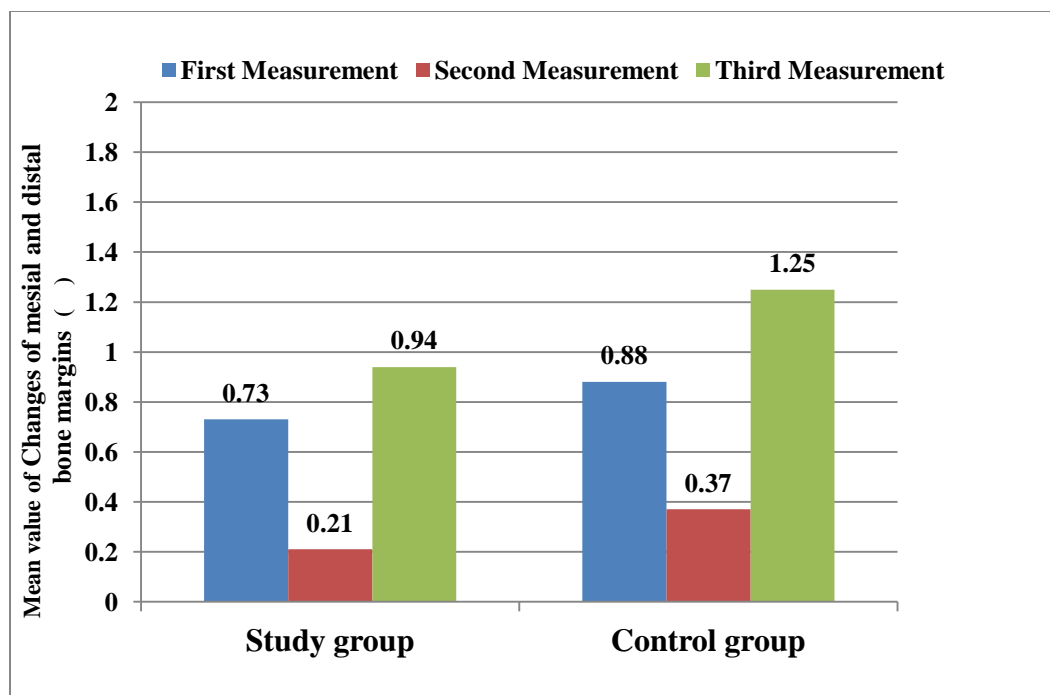


**Figure (6):** Mean values of Osstell reading immediate and post six months' post-operative implant placement in both groups.



**Figure (7):** Mean values of Changes of buccal and lingual bone margins among different measuring periods at both groups.





**Figure (8):** Mean values of Changes of mesial and distal bone margins among different measuring periods at both groups.

## 5 ) Discussion

Immediate treatment approaches are gaining popularity in implant dentistry. A series of advancements, particularly regarding innovations in implant design and surface characteristics, have allowed for immediate implants to become a well-accepted alternative to conventional treatment protocols in implant dentistry.

Various technical approaches are available to provide optimal implant positioning through use of surgical templates that are either based on conventional radiographic templates or on cone beam computed tomography and computer-assisted three-dimensional implant planning. In this study, pre-extractive interradicular implant bed preparation may be additional tool to template-guided implant surgery.

This study demonstrated a novel approach that allowed for improved guidance during implant bed preparation for immediate implants at multirooted molar sites. With the osteotomy drills stabilized and guided by the retained root aspects, this new technique allows for precise positioning and angulation of the implant bed preparation in the presence of

interradicular bone at multirooted extraction sockets.

This novel form of implant bed preparation may be regarded as an uncomplicated but useful modification of the standard procedure that allows for ideal implant positioning during immediate implant placement at multirooted extraction sites.

In the present study, immediate implants placement was done in the test group (pre-extractive implant bed preparation) which were similar to Rebele et al., (2013)<sup>45</sup>, Hamouda et al., (2015)<sup>51</sup>, Scarano, (2017)<sup>10</sup> and Ekta Rohra et al., (2017)<sup>46</sup> in comparison to the control group (post-extractive implant bed preparation) that were similar to Urban et al., (2011)<sup>49</sup>, Atieh et al., (2012)<sup>42</sup>, Hayacibara et al., (2012)<sup>44</sup> and Marco et al., (2016)<sup>39</sup>.

Hamouda et al., (2015)<sup>51</sup> discussed a sulcular buccal incision, with releasing periosteal incisions were made around the mandibular molar to be replaced. However, in this study, both groups were done without flap elevation which is similar to Rebele et al., (2013)<sup>45</sup>, Scarano, (2017)<sup>10</sup> and Ekta Rohra et al., (2017)<sup>46</sup>. This could be aimed for preservation of buccal plate blood supply with a minimal degree of bone changes after roots

extraction and implant placement plus preservation of keratinized mucosa for elimination of second stage free gingival graft augmentation.

Rebele et al., (2013)<sup>45</sup> recommended using a sharp new drills to drill through the dentin and cementum at the furcation region and claimed that drilling through the dentin and retained root aspects appeared to be similar to drilling through tissues however it is slightly harder than dense cortical bone on the other hand Hamouda et al., (2015)<sup>51</sup>, Scarano, (2017)<sup>10</sup> and Ekta Rohra et al., (2017)<sup>46</sup> recommended drilling after roots separation in order to make the drilling process easier. In the present study, we prefer to drill after roots separation for the following: allow easier drilling through tissues, preserve the drills from being dullness, minimize heat generation during drilling in addition to prevention of a deleterious reaction risk caused by drill debris in the osteotomy.

Hamouda et al., (2015)<sup>51</sup> placed the root-form dental implant into the socket after drilling the osteotomy without extraction of the remaining roots remnants, however reported about difficulty of removal of the remaining roots remnants especially in case of ankylosed roots which might endanger the threads engaging the bone, the bone implant contact, the implant stability with the vibration of the drill and surface treatment of the implant and this technique was similar to Ekta Rohra et al., (2017)<sup>46</sup>. On the other hand, Rebele et al., (2013)<sup>45</sup> and Scarano, (2017)<sup>10</sup> recommended to place the implant after roots extraction and this was the protocol that followed in the present study to allow for easier and minimize the complications in countered with the pre-extractive implant placement.

With the great controversy in the literature regarding the implant design that should be used in the immediate implant placement in the mandibular molar region. Rebele et al., (2013)<sup>45</sup> and Scarano, (2017)<sup>10</sup> used a cylindrical implant design while Hamouda et al., (2015)<sup>51</sup> and Ekta Rohra et al., (2017)<sup>46</sup> used tapered implant design. Urban et al., (2011)<sup>49</sup> used a cylindrical body with tapered end implant which was similar to the design of

the implant used in this study with 100% implant success and minute marginal bone changes and this could be attributed to the surface treatment of the implant design and the initial stability is not a great importance in the final implant stability and implant success however the surface treatment is of greater importance in implant success.

Several grafting materials have been recommended to augment the gaps of the mesial and distal bony sockets surrounding the implants. Urban et al., (2011)<sup>49</sup> used autogenous particulates with fifteen implants failed before prosthetic procedures. Hamouda et al., (2015)<sup>51</sup> used synthetic bone substitute  $\beta$ -Tricalcium phosphate with one implant failed after 4 weeks of implant placement. Hayacibara et al., (2012)<sup>44</sup> Marco et al., (2016)<sup>39</sup> Scarano, (2017)<sup>10</sup> used bovine xenograft particles that was used in this study with 100% implant success and marginal bone loss ( $0.77\pm 0.33$  mm) in the study group and ( $1.39\pm 0.92$  mm) in control group after one-year of buccolingual bone margin with zero bone graft loss and this support the hypothesis that the particulate graft of low resorption rate is better to be used to augment the jumping gap in order to preserve the surrounding bony walls and to minimize the possibility of marginal bone loss.

Coverage of the socket after immediate implant placement with simultaneous grafting of the jumping gap is crucial factor for successful consolidation of the graft around the implant. Several recommendations had been introduced in the literature for the management of socket seal including the use of the non-resorbable polytetrafluoroethylene (PTFE) membranes to seal the socket after immediate implant placement. Hoffmann et al., (2008)<sup>58</sup> used the non-resorbable polytetrafluoroethylene (PTFE) membranes to cover the socket with a significant regeneration of the volume of socket but its complications are exposure and dehiscence. Urban et al., (2011)<sup>49</sup> used ossix cross linked collagen membrane which is resorbable collagen membrane however chemically treated in order to prolong the period without resorption.

The survival rate of the test group was 100% with no implant failure which was

different at Hamouda et al., (2015)<sup>51</sup> with 95% survival rate. This could be also attributed to careful selection of patients, accurate clinical procedures and the sandblasted and acid etched (SLA) implant treated surface that aimed in high bone implant contact (BIC) between implant and surrounding bone and better implant osseointegration.

Moreover, implant stability results between groups were ( $58 \pm 0.81$  ISQ units) for the test group and ( $54.6 \pm 1.07$  ISQ units) for the control group at immediate implant placement which show significant differences ( $p < 0.001$ ) that increase in the test group in compared to the control group and were similar to Scarano, (2017)<sup>10</sup> with ( $56.8 \pm 7$  ISQ units) in the test group and ( $49 \pm 9$  ISQ units) in the control group and with statistical difference ( $p < 0.001$ ). This could be attributed to improved guidance during pre-extractive implant bed preparation that led to better implant positioning and high primary implant stability.

But on the contrary, it was different at Hamouda et al., (2015)<sup>51</sup> with no significant differences between groups after using periosteal measurements (PTM). This could be attributed to implant cylindrical design, SLA (sandblasted and acid etched) surface treatment of the implant and implant placement into the prepared sites through the interseptal/interradicular bone after separation of the two roots and their extraction while Hamouda et al., (2015)<sup>51</sup> roots extraction were done after implant placement also some ankylosed roots were removed in small pieces using surgical burs that had a negative impact on the implant stability.

Moreover, marginal bone loss results of mesial and distal bones between one-year and six-months' post-operative implant placement were ( $0.21 \pm 0.09$  mm) in the test group and ( $0.37 \pm 0.17$  mm) in the control group and marginal bone loss results of buccal and lingual bones between same periods were ( $0.21 \pm 0.04$

mm) in the test group and ( $0.42 \pm 0.21$  mm) of the control groups with significant differences of ( $p = 0.022^*$ ) in mesial and distal bone loss and ( $p = 0.006^*$ ) in buccal and lingual bone loss between groups. This might be attributed to the inaccurate site preparation and consequently malalignment implant position of the control group in relation to the test group which had a high influence on the stress distribution over the implant and consequently much degree of marginal bone loss in control group in relation to the test group.

## 6) Conclusions

- The use of the modified pre-extractive inter-radicular implant bed preparation could provide satisfactory primary implant stability with ideal implant positioning and enhanced implant success.
- Implants that placed by pre-extractive inter-radicular implant bed preparation had a high primary stability than that placed by post-extractive inter-radicular implant bed preparation.
- Implants that placed by pre-extractive inter-radicular implant bed preparation had a less marginal bone loss in both bucco-lingual and mesio-distal dimensions from six-months to one-year than post-extractive inter-radicular implant bed preparation.
- The use of bone graft and membrane coverage in the bony sockets has a positive impact on the bone level changes after roots extraction.

## Conflict Of Interest

The authors declare that they have no conflict of interest with the contents of this article.



## References

1. Fugazzotto PA. Implant Placement at the Time of Mandibular Molar Extraction: Description of Technique and Preliminary Results of 341 Cases. *J Periodontol.* 2008;79(4):737-747. doi:10.1902/jop.2008.070293.
2. Atieh MA, Payne AGT, Duncan WJ, de Silva RK, Cullinan MP. Immediate placement or immediate restoration/loading of single implants for molar tooth replacement: a systematic review and meta-analysis. *Int J Oral Maxillofac Implants.*2010;25(2):401-415. www.ncbi.nlm.nih.gov/pubmed/20369102.
3. Greenstein G, Tarnow D. The Mental Foramen and Nerve: Clinical and Anatomical Factors Related to Dental Implant Placement: A Literature Review. *J Periodontol.* 2006;77(12):1933-1943. doi:10.1902/jop.2006.060197.
4. Annibali S, Gherlone E, Grassi FR. Immediate transmucosal implant placement in molar extraction sites: a 12-month prospective multicenter cohort study. 2008;476-482. doi:10.1111/j.1600-0501.2008.01541.x.
5. Block MS. Placement of implants into fresh molar sites: Results of 35 cases. *J Oral Maxillofac Surg.* 2011;69(1):170-174. doi:10.1016/j.joms.2010.07.040.
6. Chen ST, Wilson TG, Hämmerle CHF. Immediate or early placement of implants following tooth extraction: review of biologic basis, clinical procedures, and outcomes. *Int J Oral Maxillofac Implants.* 2004;19 Suppl:12-25.
7. Araújo MG, Lindhe J. Dimensional ridge alterations following tooth extraction. An experimental study in the dog. *J Clin Periodontol.* 2005;32(2):212-218. doi:10.1111/j.1600-051X.2005.00642.x.
8. Javed F, Romanos GE. The role of primary stability for successful immediate loading of dental implants. A literature review. *J Dent.* 2010;38(8):612-620. doi:10.1016/j.jdent.2010.05.013.
9. Atieh MA, Alsabeeha NHM, Duncan WJ. Immediate single implant restorations in mandibular molar extraction sockets: A controlled clinical trial. *Clin Oral Implants Res.* 2013;24(5):484-496. doi:10.1111/j.1600-0501.2011.02415.x.
10. Scarano A. Traditional Postextractive Implant Site Preparation Compared with Pre-extractive Interradicular Implant Bed Preparation in the Mandibular Molar Region, Using an Ultrasonic Device: A Randomized Pilot Study. *Int J Oral Maxillofac Implants.* 2017;32(3):655-660. doi:10.11607/jomi.5342.
11. Sato I, Ueno R, Kawai T, Yosue T. Rare courses of the mandibular canal in the molar regions of the human mandible: A cadaveric study. *Okajimas Folia Anat Jpn.* 2005;82(3):95-102. doi:10.1016/j.nimb.2005.06.095.
12. Levine MH, Goddard AL, Dodson TB. Inferior Alveolar Nerve Canal Position: A Clinical and Radiographic Study. *J Oral Maxillofac Surg.* 2007;65(3):470-474. doi:10.1016/j.joms.2006.05.056.
13. Hu KS, Yun HS, Hur MS, Kwon HJ, Abe S, Kim HJ. Branching Patterns and Intraosseous Course of the Mental Nerve. *J Oral Maxillofac Surg.* 2007;65(11):2288-2294. doi:10.1016/j.joms.2007.06.658.
14. Watanabe H, Abdul MM, Kurabayashi T, Aoki H. Mandible size and morphology determined with CT on a premise of dental implant operation. *Surg Radiol Anat.* 2010;32(4):343-349. doi:10.1007/s00276-009-0570-3.
15. Kim IS, Kim SG, Kim YK, Kim JD. Position of the mental foramen in a Korean population: A clinical and

- radiographic study. *Implant Dent.* 2006;15(4):404-411. doi:10.1097/01.id.0000243319.66845.15.
16. Song WC, Kim SH, Paik DJ. Location of the infraorbital and mental foramen with reference to the soft-tissue landmarks. *Plast Reconstr Surg.* 2007;120(5):1343-1347. doi:10.1097/01.prs.0000279558.86727.5a.
  17. Uchida Y, Yamashita Y, Goto M, Hanihara T. Measurement of Anterior Loop Length for the Mandibular Canal and Diameter of the Mandibular Incisive Canal to Avoid Nerve Damage When Installing Endosseous Implants in the Interforaminal Region. *J Oral Maxillofac Surg.* 2007;65(9):1772-1779. doi:10.1016/j.joms.2006.10.015.
  18. Uchida Y, Noguchi N, Goto M. Measurement of Anterior Loop Length for the Mandibular Canal and Diameter of the Mandibular Incisive Canal to Avoid Nerve Damage When Installing Endosseous Implants in the Interforaminal Region: A Second Attempt Introducing Cone Beam Computed Tomography. *J Oral Maxillofac Surg.* 2009;67(4):744-750. doi:10.1016/j.joms.2008.05.352.
  19. Schropp L, Isidor F. Timing of implant placement relative to tooth extraction. *Journal of Oral Rehabilitation.* 2008;35(2). doi:10.1111/j.1365-2842.2007.01827.x.
  20. Caplanis N, Lozada JL, Kan JY. Extraction Defect: Assessment, Classification and Management. *Int J Clin Implant Dent with DVD.* 2009;1(June):1-11. doi:10.5005/jp-journals-10004-1001.
  21. Elian N, Cho S-C, Froum S, Smith RB, Tarnow DP. A simplified socket classification and repair technique. *Pract Proced Aesthet Dent.* 2007;19(2):99-104; quiz 106.
  22. Barone A, Borgia V, Alfonsi F, Toti P, Covani U. Immediate versus delayed restorations for implants placed in fresh extraction sockets: a 1-year comparative cohort study. 2013;1(3).
  23. Blus C, Szmukler-Moncler S. Atraumatic tooth extraction and immediate implant placement with Piezosurgery: evaluation of 40 sites after at least 1 year of loading. *Int J Periodontics Restorative Dent.* 2010;30(4):355-363. <http://www.ncbi.nlm.nih.gov/pubmed/20664837>.
  24. Muska E, Walter C, Knight A, Taneja P, Bulsara Y. Atraumatic vertical tooth extraction: a proof of principle clinical. *OOOO.* 2013;116(5):e303-e310. doi:10.1016/j.oooo.2011.11.037.
  25. Peñarrocha M, Uribe R, Balaguer, José. University of Valencia, Valencia S. Implantes inmediatos a la exodoncia . Situación actual. *Med Oral.* 2004;9(1):234-242..
  26. Jung U-W, Choi J-Y, Kim C-S. Evaluation of Mandibular Posterior Single Implants With Two Different Surfaces: A 5-Year Comparative Study. *J Periodontol.* 2008;79(10):1857-1863. doi:10.1902/jop.2008.070632.
  27. Fugazzotto PA. Simplified Technique for Immediate Implant Insertion into Extraction Sockets: Report of Technique and Preliminary Results. *Implant Dent.* 2002;11(1):79-82. doi:10.1097/00008505-200201000-00018.
  28. Walker LR, Morris GA, Novotny PJ. Implant insertional torque values predict outcomes. *J Oral Maxillofac Surg.* 2011;69(5):1344-1349. doi:10.1016/j.joms.2010.11.008.
  29. Düzeyde İ, Yerleştime İ, Greenberg AM. S77. 2017;51:76-89. *J Istanbul Univ Fac Dent.* 2017;51(3 Suppl 1):S76-S89. <http://dx.doi.org/10.17096/jiufd.17594>.
  30. Bettach R, Taschieri S, Mortellaro C, Del

- Fabbro M. Immediate implant placement into fresh extraction sites using single-drilling bur and two loading procedures: Follow-up results. *J Craniofac Surg.* 2018;29(8):2135-2142. doi:10.1097/SCS.0000000000004675.
31. Kim HM, Cho J yong, Ryu J. Evaluation of implant stability using different implant drilling sequences. *J Dent Sci.* 2019;14(2):152-156. doi:10.1016/j.jds.2019.03.006.
32. Rabel A, Köhler SG, Schmidt-westhausen AM. Clinical study on the primary stability of two dental implant systems with resonance frequency analysis. 2007:257-265. doi:10.1007/s00784-007-0115-2.
33. Shokri M, Daraeighadikolaei A. Measurement of primary and secondary stability of dental implants by resonance frequency analysis method in mandible. *Int J Dent.* 2013;2013. doi:10.1155/2013/506968.
34. Kokovic V, Jung R, Feloutzis A, Todorovic VS, Jurisic M, Hämmerle CHF. Immediate vs. early loading of SLA implants in the posterior mandible: 5-year results of randomized controlled clinical trial. *Clin Oral Implants Res.* 2014;25(2):114-119. doi:10.1111/clr.12072.
35. Romanos GE, Delgado-Ruiz RA, Sacks D, Calvo-Guirado JL. Influence of the implant diameter and bone quality on the primary stability of porous tantalum trabecular metal dental implants: an in vitro biomechanical study. *Clin Oral Implants Res.* 2018;29(6):649-655. doi:10.1111/clr.12792.
36. Velloso G, Moraschini V, dos Santos Porto Barboza E. Hydrophilic modification of sandblasted and acid-etched implants improves stability during early healing: a human double-blind randomized controlled trial. *Int J Oral Maxillofac Surg.* 2019;48(5):684-690. doi:10.1016/j.ijom.2018.09.016.
37. Polizzi G, Grunder U, Goené R. Immediate and delayed implant placement into extraction sockets: A 5-year report. *Clin Implant Dent Relat Res.* 2000;2(2):93-99. doi:10.1111/j.1708-8208.2000.tb00111.x.
38. Schropp L, Isidor F, Kostopoulos L, Wenzel A. Patient experience of, and satisfaction with, delayed-immediate vs. delayed single-tooth implant placement. *Clin Oral Implants Res.* 2004;15(4):498-503. doi:10.1111/j.1600-0501.2004.01033.x.
39. Tallarico M, Xhanari E, Pisano M, De Riu G, Tullio A, Meloni SM. Single post-extractive ultra-wide 7 mm-diameter implants versus implants placed in molar healed sites after socket preservation for molar replacement: 6-month post-loading results from a randomised controlled trial. *Eur J Oral Implantol.* 2016;9(3):263-275. <http://www.ncbi.nlm.nih.gov/pubmed/27722224>.
40. Levin L, Laviv A, Schwartz-arad D. Long-Term Success of Implants. *J Periodontol.* 2006;77(9). doi:10.1902/jop.2006.060005.
41. Zafiroopoulos G-G, Kasaj A, Hoffmann O. Immediate Implant Placement in Fresh Mandibular Molar Extraction Socket: 8-Year Results. A Case Report. *J Oral Implantol.* 2010;36(2):145-151. doi:10.1563/aaid-joi-d-09-00030.
42. Atieh M, Secondary CA, Author C, Atieh M, Shahmiri RA, Atieh M. Journal of Oral Implantology The evaluation of optimal taper of immediately loaded wide-diameter implants : A finite element analysis The evaluation of optimal taper of immediately loaded wide- diameter implants : A finite element analysis Sir John Walsh . *Clin. Oral Impl. Res.* , 2012, 1–13 doi: 10.1111/j.1600-0501.2011.02415.x.



43. Smith RB, Tarnow DP. Classification of Molar Extraction Sites for Immediate Dental Implant Placement: Technical Note. *Int J Oral Maxillofac Implants*. 2013;28(3):911-916. doi:10.11607/jomi.2627.
44. Hayacibara RM, Gonçalves CS, Garcez-Filho J, Magro-Filho O, Esper H, Hayacibara MF. The success rate of immediate implant placement of mandibular molars: A clinical and radiographic retrospective evaluation between 2 and 8 years. *Clin Oral Implants Res*. 2013;24(7):806-811. doi:10.1111/j.1600-0501.2012.02461.x.
45. Rebele SF, Zuhr O, Hürzeler MB. Pre-extractive Interradicular Implant Bed Preparation: Case Presentations of a Novel Approach to Immediate Implant Placement at Multirooted Molar Sites. *Int J Periodontics Restor Dent*. 2013;33(1):88-95. doi:10.11607/prd.1444.
46. Rohra D. E, Mistry DG, Joshi DT, Khanvilkar DU. Implant Bed Preparation for Immediate Implantation in Molar Region: An Alternative Approach. *IOSR J Dent Med Sci*. 2017;16(05):48-50. doi:10.9790/0853-1605064850.
47. DVS, Callens A, Geers L, The JR. The clinical use of deproteinized bovine bone mineral on bone regeneration in conjunction with immediate implant installation. 2000;d:210-216.
48. Covani U, Cornelini R, Barone A. Case Series Bucco-Lingual Bone Remodeling Around Implants Placed into Immediate Extraction Sockets: A Case Series Case Series. 74(2):268-273. doi:10.1902/jop.2003.74.2.268.
49. Urban T, Kostopoulos L, Wenzel A. Immediate implant placement in molar regions: A 12-month prospective, randomized follow-up study. *Clin Oral Implants Res*. 2012;23(12):1389-1397. doi:10.1111/j.1600-0501.2011.02319.x.
50. Araújo MG, Linder E, Lindhe J. Bio-Oss® Collagen in the buccal gap at immediate implants: A 6-month study in the dog. *Clin Oral Implants Res*. 2011;22(1):1-8. doi:10.1111/j.1600-0501.2010.01920.x.
51. Hamouda NI, Mourad SI, El-Kenawy MH, Maria OM. Immediate implant placement into fresh extraction socket in the mandibular molar sites: A preliminary study of a modified insertion technique. *Clin Implant Dent Relat Res*. 2015;17(S1):e107-e116. doi:10.1111/cid.12135.
52. Draenert FG, Coppentrath E, Herzog P, Müller S, Mueller-Lisse UG. Beam hardening artefacts occur in dental implant scans with the NewTom® cone beam CT but not with the dental 4-row multidetector CT. *Dentomaxillofac Radiol*. 2007;36(4):198-203. doi:10.1259/dmfr/32579161.
53. Froum S, Casanova L, Byrne S, Cho SC. Risk Assessment Before Extraction for Immediate Implant Placement in the Posterior Mandible: A Computerized Tomographic Scan Study. *J Periodontol*. 2010;82(3):395-402. doi:10.1902/jop.2010.100360.
54. Dawood A, Brown J, Sauret-Jackson V, Purkayastha S. Optimization of cone beam CT exposure for pre-surgical evaluation of the implant site. *Dentomaxillofac Radiol*. 2012;41(1):70-74. doi:10.1259/dmfr/16421849.
55. Ibrahim N, Parsa A, Hassan B, van der Stelt P, Aartman IHA, Wismeijer D. Accuracy of trabecular bone microstructural measurement at planned dental implant sites using cone-beam CT datasets. *Clin Oral Implants Res*. 2014;25(8):941-945. doi:10.1111/clr.12163.
56. Lin MH, Mau LP, Cochran DL, Shieh

- YS, Huang PH, Huang RY. Risk assessment of inferior alveolar nerve injury for immediate implant placement in the posterior mandible: A virtual implant placement study. *J Dent.* 2014;42(3):263-270. doi:10.1016/j.jdent.2013.12.014.
57. Parsa A, Ibrahim N, Hassan B, van der Stelt P, Wismeijer D. Bone quality evaluation at dental implant site using multislice CT, micro-CT, and cone beam CT. *Clin Oral Implants Res.* 2015;26(1):e1-e7. doi:10.1111/clr.12315.
58. Hoffmann O, Bartee BK, Beaumont C, Kasaj A, Deli G, Zafiroopoulos G-G. Alveolar Bone Preservation in Extraction Sockets Using Non-Resorbable dPTFE Membranes: A Retrospective Non-Randomized Study. *J Periodontol.* 2008;79(8):1355-1369. doi:10.1902/jop.2008.070502.