



Phenotypic and pathological characterizations of different *Sarcocystis* species in donkeys

Mona Mohammed I.
Abdel Rahman¹ and
Heba M. Abdel-Ghany²

¹Parasitology and
²Pathology Dept.,
Faculty of Vet. Med.,
Zagazig University.
Zagazig, Egypt

Corresponding author:
mona_111_para@yahoo.com
m
01124983310

Abstract:

This study aimed to record the prevalence of different *Sarcocystis* spp., demonstrate their morphological characters by laboratory, histopathological and immunohistochemical techniques, also to investigate the pathological lesions in esophagus, heart, and brain samples collected from naturally infected donkeys in Egypt. The current study identified four *Sarcocystis* spp. (*S. bertrami*, *S. equicanis*, *S. asinus* and *S. fayeri*) in meat samples and *S. neurona* in the brain of the examined donkeys. Examination of meat samples showed macroscopic tissue cysts of *S. bertrami* and microscopic tissue cysts of *S. equicanis*/*S. asinus* and *S. fayeri*. According to the thickness of the cyst wall, *Sarcocystis* spp. were divided into smooth thin walled *S. bertrami*, ciliated thin walled *S. equicanis*/*S. asinus* and striated thick walled *S. fayeri*. Also, immunohistochemical (IHC) examination showed strong labeled schizonts and cyst wall of *S. neurona*, while the bradyzoites appeared negative staining. Pathological examination revealed degeneration of muscles with intermuscular edema and few mononuclear inflammatory cells, but brain tissue showed perivascular lymphocytic cuffing and satellitosis with developing schizonts. The current study concluded that the accurate recognition about *Sarcocystis* spp. in donkeys would be helpful in their treatment, prevention and control measures.

Keywords: *bertrami*, donkey, *equicanis*, *fayeri*, immunohistochemical, *neurona*.

INTRODUCTION

Sarcocystis spp. cysts were noticed by Miescher (1843) for the first time in mouse muscles in Switzerland. Such nomenclature was derived from finding them encysted (cyst) and localized in the

muscles (sarco) of the intermediate hosts **Dubey et al. 2016a; Dubey et al. 1989**. The cysts were formed through endodyogeny of merozoites and could reproduce through endodyogeny (production of merozoites with a pair of

daughter nuclei) and endopolygony (production of multinucleated merozoites) **Slapeta et al. 1999**. *Sarcocystis* spp. is a common protozoan parasite and distributed worldwide in muscles of mammals and birds. Four species; *S. bertrami*, *S. equicanis*/*S. asinus*, *S. fayeri* and *S. neurona* were recorded in equine **Levine and Tadros 1980**. Dogs act as final hosts for *S. bertrami*, *S. equicanis*/*S. asinus*, and *S. fayeri*, while opossums act as final hosts for *S. neurona* **Dubey et al. 2016a**.

S. neurona investigated in a wide range of hosts. If their schizonts were detected in the host, it is considered as an aberrant host, while if the mature cysts were investigated, the host is considered intermediate **Dubey et al. 2015**. The schizonts had been found only in brain **Dubey et al. 2001**, but their cysts might be found in brain, cardiac or skeletal muscles **Miller et al. 2009**. *S. neurona* is the most pathogenic species in equine where it induce equine protozoal myeloencephalitis (EPM). The manifested clinical signs vary according to the involved area in CNS from weakness, facial paralysis, dysphagia, and gait abnormalities to seizures **Dubey et al. 2001; Dubey et al. 2015**. Also, **Aleman et al. 2015** reported that *S. fayeri* infection in equine induced eosinophilic myositis and cardiomyopathy, which manifested by weight losses, stiffness, lethargy, muscle pain, swollen tongue and dysphagia.

Determination of different *Sarcocystis* spp. in equines is still confused **Dubey et al. 2016a**. They included *S. bertrami*, *S. equicanis*, *S. fayeri* and *S. neurona*. **Zeng et al. 2018** found that *Sarcocystis* spp. in horses and donkeys were closely related based upon their phenotypic characters and *cox1* sequences and so they suggested both horses and donkeys had the same *Sarcocystis* spp. Many authors studied sarcocystosis in horses, but little data was known about donkeys and so this study is dealing with *Sarcocystis* spp. prevalence, morphological characterization of different *Sarcocystis* spp., and pathological findings in meat and brain samples of naturally infected donkeys in Egypt.

MATERIAL AND METHODS

1. Samples collection

Meat and brain samples were collected from 80 and 20 slaughtered donkeys, respectively in Giza Zoo, Giza Governorate, Dokki, Egypt. Samples were transported in an ice tank to Zagazig University, Faculty of Veterinary Medicine, Parasitology Department for further examinations. This study was approved with number ZU-IACUC/2/F/75/2018 by ZU-IACUC Committee, Zagazig University, Egypt

2. Laboratory examination

By naked eye, meat samples were examined for macroscopic cysts. Small pieces of meat were crushed between two glass slides

and examined under the light microscope to detect microscopic cysts. Also, small pieces of brain were squeezed on glass slides and then stained with Giemsa stain to observe the released bradyzoites or metrocytes under the oil immersion lens.

3. Pathological examination

Meat and brain samples were collected from slaughtered donkeys for detection of *Sarcocystis* spp. The collected specimens were fixed in 10% buffered neutral formalin solution, processed, stained and prepared for microscopical examination according to the descriptions of **Suvarna et al. 2013**.

4. Immunohistochemical (IHC) examination

The de-paraffinized sections of brain and meat samples were incubated with polyclonal goat-antibodies against *S. neurona* (VMRD, Inc. Pullman, WA) **Soldati et al. 2004** and A streptavidin-immunoperoxidase labeling (Sigma Chemicals, St. Louis, US) was used to distinguish positive immune reactions **Kiupel et al. 2003**. Positive control was prepared from positively infected tissue sections incubated with polyclonal antibodies against *S. neurona*, while the negative control was prepared from sections incubated with non-immune sera. The procedures were completed as the description of **Dubey et al. 2016a**. The measurements of length, width, and cyst wall thickness of *Sarcocystis* spp. were performed

by a calibrated eye piece micrometer.

RESULTS

1. Prevalence

Visual and light microscopical examination of fresh and stained sections (H&E or IHC) of meat and brain samples showed detection of *S. bertrami*, *S. equicanis/S. asinus*, *S. fayeri*, and *S. neurona*. Their prevalence were listed in Tables (1-3).

2. Morphological identification

Examination of meat samples showed macroscopic tissue cysts of *S. bertrami* and microscopic tissue cysts of *S. equicanis/S. asinus* and *S. fayeri*. The mature cysts appeared septated, spindle-shaped, contained numerous bradyzoites and surrounded by cyst wall. According to the thickness of the cyst wall, *Sarcocystis* spp. were divided into smooth thin walled *S. bertrami*, ciliated thin walled *S. equicanis/S. asinus* and striated thick walled *S. fayeri*. In *S. fayeri*, the immature cysts contained numerous metrocytes and surrounded by granular cyst wall. The stained brain smears showed developed metrocytes with granular basophilic nucleus. The morphological identification of *Sarcocystis* spp. in donkey's meat was recorded during light microscopical examination of fresh and stained sample sections with H&E (Fig. 1&2).

3. Immunohistochemical (IHC) examination

The deparaffinized brain samples from donkeys are the only

Sarcocystis spp. positive immune reactions against polyclonal antiserum of *S. neurona*. The irregular-shaped schizonts, the cyst wall and the septa of mature cysts appeared strongly labeled, while the bradyzoites showed negative staining (Fig. 2). The measurements of different *Sarcocystis* spp. in the examined samples from brain and meat of donkeys were recorded and showed in Table 4.

4. Pathological examination

The heart exhibited multiple basophilic mature cross and elongated intra muscular cysts containing banana shape bradyzoites. Few mononuclear inflammatory cells were present around some cysts. Acute degeneration of the cardiac muscle and intermuscular edema were detected. Hyaline thickening of the blood vessel with endotheliosis were observed (Fig. 3).

The examined oesophagus tissues showed microscopic, elongated and cross cysts containing basophilic bradyzoites. Immature cysts were also observed between the muscles. Degeneration of muscles with intermuscular edema was detected (Fig. 4).

The examined brain tissues revealed perivascular lymphocytic cuffing with scattered glia cells in the white and gray matter (Fig. 5A). Satellitosis and demyelination were detected in the white matter (Fig. 5B). Encéphalomalacia represented by depletion of certain part of brain tissue with gliosis were observed (Fig. 5C). Developing schizonts were noticed (Fig. 5D).

Table 1: Total prevalence of *Sarcocystis* spp. in the examined donkeys

| Item | Examined numbers | Positive numbers | Positive % |
|---------------|------------------|------------------|----------------|
| Meat samples | 80 | 67 | 83.75% (67/80) |
| Brain samples | 20 | 6 | 30% (6/20) |
| Total | 100 | 73 | 73% (73/100) |

Table 2: Prevalence of single and mixed infections with muscular *Sarcocystis* spp. in donkeys

| Item | Positive % | Single | Mixed |
|----------------|---------------|----------------|---------------|
| Infection type | 83.75 (67/80) | 25.37% (17/67) | 74.63%(50/67) |

Table 3: Prevalence of different *Sarcocystis* spp. in the examined donkeys

| Item | <i>S. bertrami</i> | <i>S. equicanis</i> | <i>S.fayeri</i> | <i>S. neurona</i> |
|-----------------------|--------------------|---------------------|-----------------|---|
| Prevalence% (numbers) | 80.60% (54/67) | 85.07% (57/67) | 50.75% (34/67) | 30 % (6/20) for schizonts 5 % (1/20) for cysts |

Table 4: Measurements of different *Sarcocystis* spp. in the examined donkeys

| Item | <i>S. bertrami</i> | <i>S. equicanis</i> | <i>S.fayeri</i> | <i>S. neurona</i> |
|---------------------|-------------------------------|-------------------------------|---------------------------------|-------------------|
| Length | 5-8mm (6.5mm) | 0.5-2.3 mm (1.2mm) | 450.8-600 μ m (467 μ m) | 175 μ m |
| Width | 0.4-1mm (0.7mm) | 50- 150 μ m (100 μ m) | 47.2-75.5 μ m (467 μ m) | 40 μ m |
| Cyst wall thickness | 0.3-0.8 μ m (0.5 μ m) | 0.7-1.5 μ m (0.9 μ m) | 3.4-6.5 μ m (5.5 μ m) | 0.5 μ m |

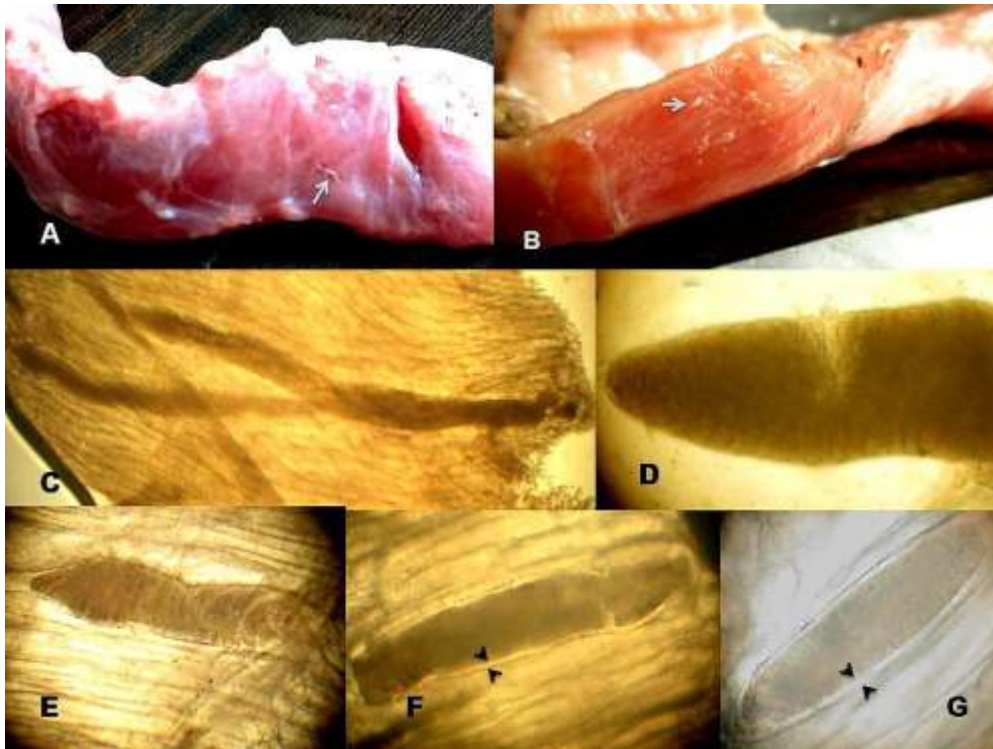


Fig. 1: A&B: Photographs showing macroscopic cysts of *S. bertrami* in donkey esophagus (arrow); C: Fresh cysts of *S. bertrami* under light microscope (X40); D: higher magnification of *S. bertrami* showing well developed septa (X100); E: Fresh cysts of *S. equicani*/*S. asinus*(X100) and F&G: Fresh cysts of *S. fayeri* demonstrated the thick cyst wall (arrowheads, X100, Digital camera).

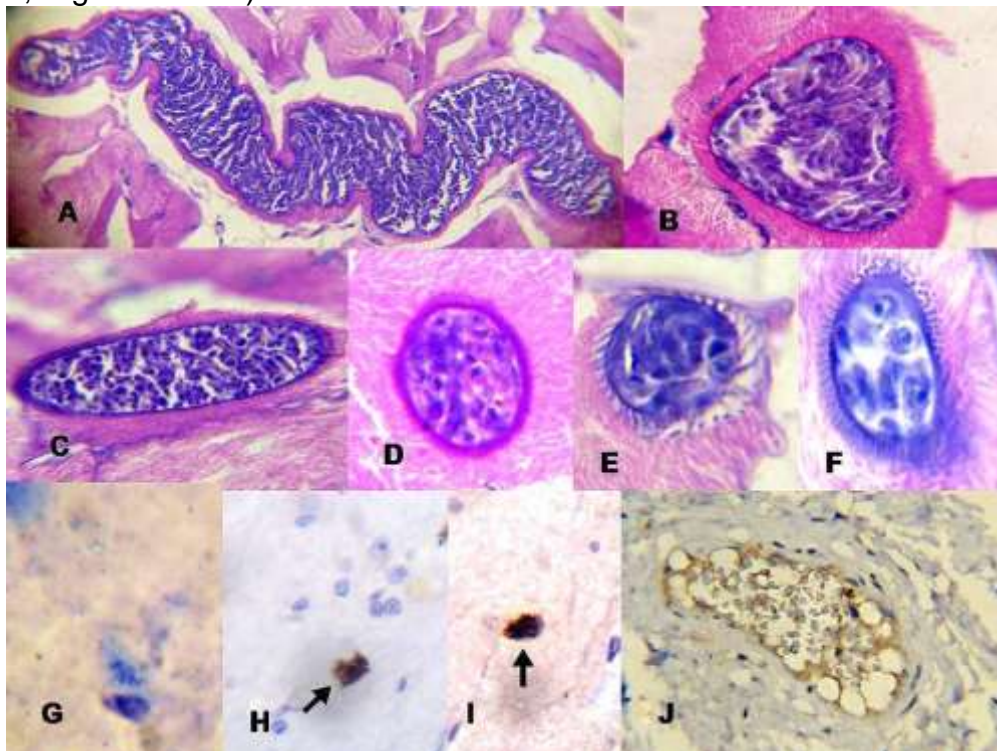


Fig. 2: Histopathological sections stained with H&E for *Sarcocystis* spp. in donkeys. A: longitudinal section of *S. bertrami* with clear septa and thin walled

cyst (X100); B: Cross section of *S. equicanis* showing ciliated and thin walled cyst (X100); C: Longitudinal section of *S. fayeri* mature cyst in meat samples showing thick and striated cyst wall (X100); D: Cross section of *S. fayeri* mature cyst (X100); E: Cross section of *S. fayeri* developed cyst (X400); F: Cross section of *S. fayeri* immature cyst contained metrocytes and surrounded by granular cyst wall (X400); G: stained brain smear with Giemsa showing developed metrocytes with granular basophilic nucleus (X1000); H&I: Strong labeled schizonts of *S. neurona* obtained by IHC (X400) and J: IHC stained brain section showed strong labeled cyst wall and negative stained bradyzoites of *S. neurona* in donkeys ((X1000, Digital camera).

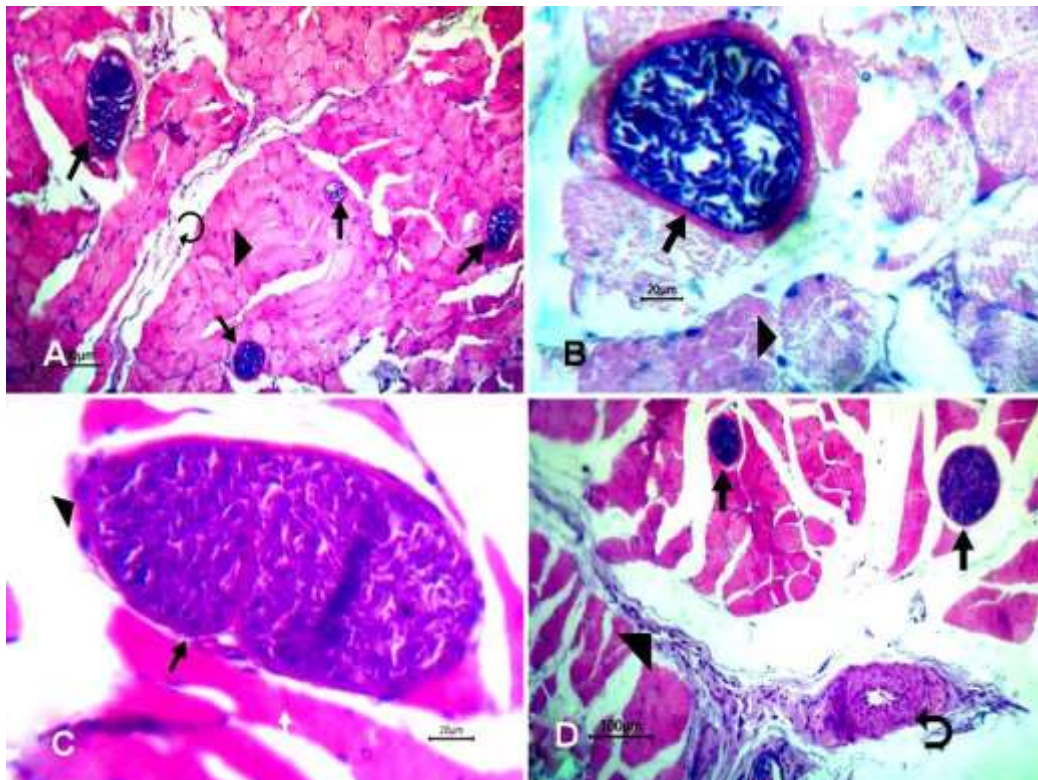


Fig.3: A: Heart showing multiple basophilic mature intramuscular cysts (arrow) between degenerated cardiac muscle (arrow head) with intermuscular edema (oblique arrow, bar=100); B: Heart showing cross section of *S. fayeri* (arrow) with acute muscle degeneration (arrow head, bar=20); C: Heart showing *S. equicanis* (arrow) among degenerated muscles (white arrow) with few number of mononuclear cells around cyst (arrow head, bar=20) and D: Heart showing two thin walled *S. equicanis* intramuscular cyst (arrow) with intermuscular edema (arrow head) and hyaline thickening of blood vessel wall together with endotheliosis (oblique arrow, bar =100).

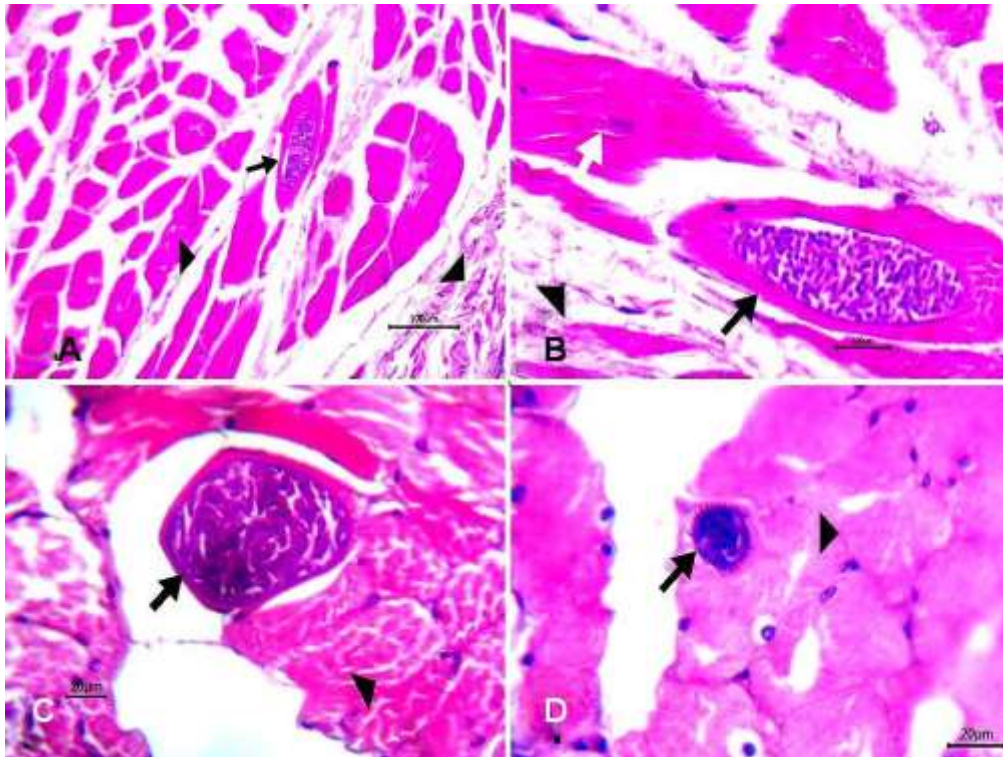


Fig. 4: A: Oesophagus showing elongated *S. equicanis* between muscle fibers (arrow) with intermuscular edema (arrow head, bar=100); B: Higher magnification of *S. equicanis* cyst (arrow) with degenerated muscle fibers (white arrow) and intermuscular edema (arrow head, bar=20); C: Oesophagus showing *S. equicanis* (arrow) with myofiber degeneration (arrow head, bar=20) and D: Oesophagus showing small sized developed cyst of *S. fayeri* (arrow) among degenerated muscles (arrow head, bar =20).

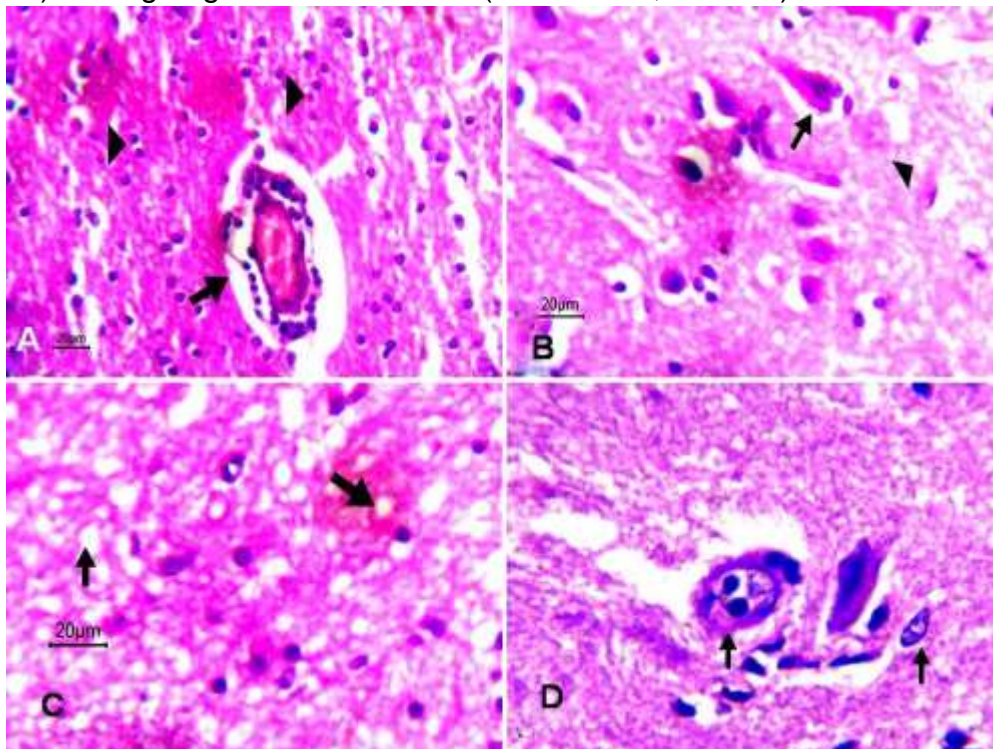


Fig. 5: A: Brain showing perivascular lymphocytic cuffing (arrow) with scattered gliosis in white and gray matter (arrow head, bar=20); B: Brain

showing satellitosis (arrow) and demyelination in the white matter of brain tissue (arrowhead, bar=20); C: Brain showing encophalomalacia (arrow) with gliosis bar=20 and D: Brain showing developed merozoites (arrow

Discussion

The current study revealed that the total prevalence of *Sarcocystis* spp. in donkeys reached 73% by laboratory and IHC examination, while that obtained by **Abdel- Maogood et al. 2015** reached 12% and 32% by PM examination and ELISA technique, respectively in Egypt. Also, it reached 66.66 % in Egypt by **Attia et al. 2018**, 16.6% in Ethiopia by **Woldemeskel and Gebreab, 1996**.

Regarding *S. bertrami*, the recorded prevalence was 80.60%, while in Italy it was 28.57% **Passantino et al. 2019**. The current study showed prevalence of 85.07% for *S. equicanis*, nearly similar rate was previously recorded in Egypt by **Hilali and Nassar 1987** to be 90%. This study is considered the first record of the prevalence of *S. fayeri* in donkeys which reached 50.75%. In addition, the current study showed that the prevalence of 30% for *S. neurona* by IHC technique, while it was 2.5% by ELISA in Mexico **Alvarado-Esquivel et al. 2017**, 61.1% by immunoblot in USA by **Saville et al. 1997**, 3% and 21% by indirect fluorescent antibody test (IFAT) and direct agglutination tests, respectively by **Gennari et al. 2016** in Brazil.

The differences in the prevalence rates is not only due to different diagnostic methods (PM examination, ELISA, IFAT or IHC) or climatic changes, but also due to the differences in intermediate host species (horse or donkey), host

susceptibility to infection, and exposure to the final hosts (dogs for *Sarcocystis* spp. in meat or opossums for *S. neurona*). The more opportunity of donkeys became in contact with final hosts, the more chance to acquire infection with *Sarcocystis* spp. **Alvarado-Esquivel et al. 2017; Dubey et al. 2016a**.

The obtained morphological descriptions for *S. bertrami*, *S. equicanis*/*S. asinus*, *S. fayeri* were similar to those noticed by **Aleman et al. 2015; Dubey et al. 1989; Hilali and Nassar 1987; Saville et al. 2004; Zeng et al. 2018**.

Zeng et al. 2018 found that horses and donkeys had the same *Sarcocystis* spp. They had been included *S. bertrami*, *S. equicanis*, *S. fayeri* and *S. neurona*. The previous study of **Dubey et al. 2016b** on donkey's sarcocytosis in Egypt recorded only *S. bertrami* in their meat, while the current study recorded four *Sarcocystis* spp. The current study described *S. bertrami* in donkeys as macroscopic cysts in spite of the previous description of *S. bertrami* in donkeys by **Dubey et al. 2016b** in Egypt as microscopic cysts. They also stated that smooth and ciliated parts were noticed in the same cyst of *S. bertrami*, while the currently studied appeared smooth thin walled macroscopic cysts in *S. bertrami*, ciliated microscopic thin walled cysts in *S. equicanis*/*S. asinus* and striated

thick walled microscopic cysts in *S. fayeri*. *S. equicanis* cysts were noticed in the esophageal and cardiac muscles of donkeys, however inability of **Sakran et al. 2013** to detect them in the cardiac muscles of horses in Egypt. **Zeng et al. 2018** described 2 types of *S. bertrami* in horses and donkeys in China, where Type I cysts were large without protrusions (smooth) and Type II cysts were smaller with protrusions (ciliated) and referred that to the Type I might be aged cysts. However, **Sheffield et al. 1977** stated that *Sarcocystis* spp. cysts increased in size with age, but their wall structure remained stable once the cysts become mature (contained bradyzoites). This confirmed our record for *S. bertrami* and *S. equicanis* as different species and they have not the same description as the previous ones **Dubey et al. 2016a; Odening et al. 1995; Rommel and Geisel 1975**. Also, we suggested that the previously described *S. equicanis* in horses is a synonym to the currently obtained *S. asinus* in donkeys depending upon their similarity with morphological characters.

In the current study, the cysts in brain were difficult to be identified in sections stained with H & E, but it was more easily noticed in sections reacted against polyclonal *S. neurona* antibody. Also, the schizonts were more easily identified in sections reacted against polyclonal *S. neurona* antibody than those in histological sections. These findings were similar to those of **Lindsay et al. 2000**. The noticed morphological features of *S. neurona* in brain were agreed with those described by **Seguel et al. 2019** in California sea lions. The observed

variability in staining pattern between *S. neurona* cyst wall and bradyzoites resembled the recorded observations of **Butcher et al. 2002** in domestic cats and **Miller et al. 2009** in southern sea otters. **Sakran et al. 2013** reported that *S. neurona* schizonts were observed only within the neural cells of brain in horses, while the current study observed both schizonts and cyst in brain of donkeys by IHC technique. **Alvarado-Esquivel et al. 2017** reported the seroprevalence (2.5%) of *S. neurona* in donkeys in Mexico, while the current study reported them for the first time in the brain of donkeys in Egypt. As mentioned in a previous study by **Dubey et al. 2015** that the presence of mature cysts and schizonts in the brain of the same host indicated it as I.H. and not an aberrant host and so from our obtained results, the donkeys were considered I.H. for *S. neurona*, however horse considered an aberrant host **Ma et al. 2020**.

Sarcocystis spp. had been associated with myocarditis reaction. Hyaline thickening of the blood vessel with endotheliosis were observed due to localization of their schizonts in the endothelia of blood vessels (Yarim et al. 2004). In the current study, the heart and esophagus exhibited multiple basophilic mature round and elongated intra muscular cysts containing banana shape bradyzoites. Some cysts had thin wall and other had thick wall. These findings were completely agreed with **Faghiri et al. 2019** who observed thin and thick walled cysts inside the cardiac and esophageal muscles. Also the obtained results detected few mononuclear inflammatory cells were present around the cysts. Acute

degeneration of the cardiac muscle and intermuscular edema were detected. These findings were completely agreed with **Caspari et al. 2011** who observed multifocal degeneration and necrosis of myocardial fibers with interstitial edema. Microscopical features of the brain revealed perivascular lymphocytic cuffing with scattered glia cells in the white and gray matter. Satellitosis and demyelination were detected in the white matter. Encéphalomalacia represented by depletion of certain part of brain tissue with gliosis were observed. The developing schizonts of *Sarcocystis* spp. were also detected. These findings were partially agreed with (Özmen et al. 2009) where their histopathological examinations showed focal areas of perivascular cuffing in the brainstem, cerebellum, and medulla spinalis with presence of *Sarcocystis* spp. schizonts.

The current study concluded that the donkeys were considered I.H. for *S. neurona* in brain and for *S. bertrami*, *S. equicanis*/*S. asinus*, and *S. fayeri* in meat. Also, *S. equicanis* in horses is a synonym for *S. asinus* in donkeys. As the donkeys had great economic importance in Africa, the accurate recognition about *Sarcocystis* spp. in donkeys would be helpful in performance of prevention and control measures against future infections.

References

- Abdel- Maogood, S.Z.; Abdel-Wahab, A.M. and Lilian, N.M. (2015):** Improved dot ELISA technique for diagnosis of some tissue parasites infecting donkeys. *Int. J. Chem.Tech. Res.*, 8 (12):94-103.
- Aleman, M.; Shapiro, K.; Siso, S.; Williams, D.C.; Rejmanek, D.; Aguilar, B. and Conrad, P.A. (2015):** *Sarcocystis fayeri* in skeletal muscle of horses with neuromuscular disease. *Neuromuscul. Disord.*, 26 (1):85-93.
- Alvarado-Esquivel, C.; Howe, D.K.; Yeargan, M.R.; Alvarado-Esquivel, D.; Zamarripa-Barboza, A.J. and Dubey, J.P. (2017):** Seroepidemiology of *Sarcocystis neurona* and *Neospora hughesi* infections in domestic donkeys (*Equus asinus*) in Durango, Mexico. *Parasit.*,24:27.doi:10.1051/parasite/2017030
- Attia, M.M.; Khalifa, M.M. and Atwa, M.T. (2018):** The prevalence and intensity of external and internal parasites in working donkeys (*Equus asinus*) in Egypt. *Vet. World*, 11 (9):1298-1306.
- Butcher, M.; Lakritz, J.; Halany, A.; Branson, K.; Gupta, G.D.; Kreeger, J. and Marsh, A.E. (2002):** Experimental inoculation of domestic cats (*Felis domesticus*) with *Sarcocystis neurona* or *Sarcocystis neurona*-like merozoites. *Vet. Parasitol.*, 107:1–14.
- Caspari, K.; Grimm, F.; Kuhn, N.; Caspari, N.C. and Basso W. (2011):** First report of naturally acquired clinical sarcocystosis in a pig breeding stock. *Vet. Parasitol.*,177 (1-2):175-178.
- Dubey, J.P.; Calero-Berna, I R.; Rosenthal, B.M.; Speer, C.A. and Fayer, R. (2016a):** *Sarcocystosis of animals and humans* 2nd edn., CRC Press. Boca Raton, FL, USA.
- Dubey, J.P.; Howe, D.K.; Furr, M.; Saville, W.J.; Marsh, A.E.; Reed, S.M. and Grigg, M.E. (2015):** An

update on *Sarcocystis neurona* infections in animals and equine protozoal myeloencephalitis (EPM). *Vet. Parasitol.*, 209 (1-2):1-42.

Dubey, J.P.; Lindsay, D.S.; Saville, W.J.A.; Reed, S.M.; Granstrom, D.E. and Speer, C.A. (2001): A review of *Sarcocystis neurona* and equine protozoalmyeloencephalitis (EPM). *Vet. Parasitol.*, 95:89–131.

Dubey, J.P.; Speer, C.A. and Fayer, R. (1989): *Sarcocystosis of animals and man*. 1st edn., CRC Press, Boca Raton, Florida.

Dubey, J.P.; Wilp,e E.V.; Verma, S.K. and Hilali, M. (2016b): Ultrastructure of *Sarcocystis bertrami* sarcocysts from a naturally infected donkey (*Equus asinus*) from Egypt. *Parasitol.*, 143:18–33.

Faghiri, E.; Davari, A. and Nabavi, R. (2019): Histopathological survey on sarcocystis species infection in slaughtered cattle of Zabol-Iran. *Turki parazitolo. dergisi.*, 43 (4):182-186.

Gennari, S.M.; Pena, H.F.; Lindsay, D.S.; Lopes, M.G.; Soares, H.S.; Cabral, A.D.; Vitaliano, S.N. and Amaku, M. (2016): Prevalence of antibodies against *Neospora spp.* and *Sarcocystis neurona* in donkeys from northeastern Brazil. *Revista Brasil. de Parasitol. Vet.*, 25 (1):109–111.

Hilali, M. and Nassar, A.M. (1987): Ultrastructure of *Sarcocystis spp.* from donkeys (*Equus asinus*) in Egypt. *Vet. Parasitol.*, 23:179-183.

Kiupel, M.; Simmons, H.A.; Fitzgerald, S.D.; Wise, A.; Sikarskie, J.G.; Cooley, T.M.; Hollamby, S.R. and Maes, R. (2003): West Nile virus infection in eastern fox squirrels (*Sciurus niger*). *Vet. Pathol.*, 40:703–707.

Levine, N.D. and Tadros, W. (1980): Named species and hosts of *Sarcocystis* (Protozoa: Apicomplexa: Sarcocystidae). *Syst. Parasitol.*, 2:41-59.

Lindsay, D.S.; Thomasb, N.J. and Dubey, J.P. (2000): Biological characterisation of *Sarcocystis neurona* isolated from a Southern sea otter (*Enhydra lutris nereis*). *Int. J. Parasitol.*; 30:617-624.

Ma, C.L.; Ye, Y.L.; Wen, T.; Huang, Z.M.; Pan, J.; Hu, J.J.; Tao, J.P. and Song, J.L. (2020): Prevalence and morphological and molecular characteristics of *Sarcocystis bertrami* in horses in China. *Parasitol.*, 27:1. doi:10.1051/parasite/2019078

Miller, M.A.; Barr, B.C.; Nordhausen, R.; James, E.R.; Magargal, S.L.; Murray, M.; Conrad, P.A.; Toy-Choutka, S.; Jessup, D.A. and Grigg, M.E. (2009): Ultrastructural and molecular confirmation of the development of *Sarcocystis neurona* tissue cysts in the central nervous system of southern sea otters (*Enhydra lutris nereis*). *Int. J. Parasitol.*, 39 (12):1363-1372.

Odening, K.; Wesemeier, H.H.; Walter G. and Bockhardt, I. (1995): Ultrastructure of sarcocysts from equids. *Acta. Parasitol.*, 40:12–20.

Özmen, Ö.; Şahinduran, Ş.; Haligür, M.; Yukari, B.A. and Dorrestein, G.M. (2009): Encephalitic sarcocystosis and its prophylactic treatment in sheep. *Turk. J. Vet. Anim. Sci.*, 33 (2):151-155.

Passantino, G.; Lia, R.P.; Latrofa, S.; Annoscia, G.; Slapeta, J.; Otranto, D.; Rossi, R. and Zizzo, N. (2019): *Sarcocystis bertrami* in skeletal muscles of donkeys (*Equus africanus asinus*) from Southern Italy. *Vet.*

Parasitol. Reg. Stud. Reports, 16:100283.doi:10.1016/j.vprsr.2019.10 0283

Rommel, M. and Geisel, O. (1975): Untersuchungen über die verbreitung und de lebenszyklus einer sarkosporidienart des pferdes (*Sarcocystis equicanis* n. spec.). Berl. und München. Tierärztl. Wochensch., 88:468-471

Sakran, T.; Al- Hroub, A. and Ahmed, A. (2013): Studies on *Sarcocystis* infecting domestic horse. Am. J. Res. Commun., 1 (6):39–35.

Saville, W.J.; Dubey, J.P.; Oglesbee, M.J.; Sofaly, C.D.; Marsh, A.E.; Elitsur, E.; Vianna, M.C.; Lindsay, D.S. and Reed, S.M. (2004): Experimental infection of ponies with *Sarcocystis fayeri* and differentiation from *Sarcocystis neurona* infections in horses. J. Parasitol., 90 (6):1487-1491.

Saville, W.J.; Reed, S.M.; Granstrom, D.E.; Hinchcliff, K.W.; Kohn, C.W.; Wittum, T.E. and Stamper, S. (1997): Seroprevalence of antibodies to *Sarcocystis neurona* in horses residing in Ohio. J. Am. Vet. Med. A., 210 (4):519–524.

Seguel, M.; Colegrove, K.M.; Field, C.; Whoriskey, S.; Norris, T. and Duignan, P. (2019): Polyphasic rhabdomyositis in California Sea Lions (*Zalophus Californianus*): Pathology and potential causes. Vet. Pathol.,56 (4):619-629.

Sheffield, H.G.; Frenkel, J.K. and Ruiz, A. (1977): Ultrastructure of the cyst of *Sarcocystis muris*. J. Parasitol.,63:629-641

Slapeta, J.R.; Modry, D. and Koudela, B. (1999): *Sarcocystis*

atheridis sp. nov., a new sarcosporidian coccidium from Nitsche's bush viper, *Atheris nitschei* Tornier, 1902, from Uganda. Parasitol. Res., 85:758-764

Soldati, S.; Kiupel, M.; Wise, A.; Maes, R.; Botteron, C. and Robert, N. (2004): Meningoencephalomyelitis caused by *Neospora caninum* in a juvenile fallow deer (*Dama dama*). J. Vet. Med. A., 51:280–283.

Suvarna, S.K.; Layton, C, and Bancroft, J.D. (2013): Bancroft's theory and practice of Histological techniques. 7th edn., Churchill Livingstone, Elsevier, England.

Woldemeskel, M. and Gebreab, F. (1996): Prevalence of sarcocysts in livestock of Northwest Ethiopia. J. Vet. Med. B., 43:55-58.

Yarim, M.; Yildiz, K.; Kabakci, N. and Karahan, S. (2004): Immunohistochemical localisation of 3beta-hydroxysteroid dehydrogenase in *Sarcocystis* spp. Parasitol. Res., 93 (6):457-460.

Zeng, W.; Sun, L.; Xiang, Z.; Li, N.; Zhang, J.; He, Y.; Li, Q.; Yang, F.; Song, J.; Morris, J.; Rosenthal, B.M.; Sun, L.; Liu, H. and Yang, Z. (2018): Morphological and molecular characteristics of *Sarcocystis bertrami* from horses and donkeys in China. Vet. Parasitol., 252:89–94.

المخلص العربي

الخصائص المظهرية والنسجية لمختلف أنواع الساركوسيسيتس في الحمير

*منى محمد إبراهيم عبدالرحمن - **هبة محمد عبدالغنى

*قسم الطفيليات و**الباثولوجيا -كلية الطب البيطرى- جامعة الزقازيق

درس العديد من المؤلفين السابقين طفيل الساركوسيسيتس في الخيول ، ولكن لايتوفر سوى القليل من الدراسات عنها في الحمير ولذلك فقد هدفت هذه الدراسة إلى تسجيل معدلات انتشار الانواع المختلفة من طفيل الساركوسيسيتس وتوضيح خصائصها المورفولوجية من خلال التقنيات المختبرية والفصح الباثولوجى والكيميائى المناعى وكذلك دراسه التغيرات النسيجه الباثولوجيه في عينات المريء و القلب والدماغ التى تم تجميعها من الحمير المصابة طبيعيا في مصر . وقد تمكنت الدراسة الحالية من التعرف على أربعة أنواع من ساركوسيسيتس بيرترامى و فاييرى و اكوى كانيز فى عضلات الحمير و ايضا النوع نيرونا في ادمغه الحمير المصابه وقد تم تصنيفها طبقاً لسمك جدار الحويصلات حيث كانت ذات جدران رقيقة ناعمة للنوع ساركوسيسيتس بيرترامى و رقيقة ذات اهداب فى النوع اكوى كانيز و سميكه فى ساركوسيسيتس فاييرى وقد أوضح الفحص الكيميائى المناعى للنوع نيرونا تفاعل ايجابى لكل من الشيزونت والجدار الخارجى للحويصلات بينما البراديزويت كانت ذات تفاعل سلبى . وقد اوضح الفحص النسيجى عن انحطاط العضلات ذات الودمة العضلية وعدد قليل من الخلايا الالتهابية أحادية النواة ولكن أنسجة الدماغ أظهرت تضخم للمفاويات حول الاوعيه الدمويه وداء الاقمار الصناعيه وبالتالي فان دراسه الحاليه تستخلص ان الحمير تعد عائل وسيط للنيرونا على عكس الخيول وأيضاً قد يشكل التعرف الدقيق على أنواع حويصلات الساركوسيتس اهميه كبيره فى تحديد العلاج اللازم وكذلك الوقاية منها والسيطرة عليها

