



Manuscript ID ZUMJ-1910-1606
DOI 10.21608/zumj.2020.18809.1606

ORIGINAL ARTICLE

Adjuvant diagnostic value of 128 Multi-detector computed tomography in calcaneal fracture discrimination

ElShaimaa M. Mohamed^{1*}, Sherif Maher Abolyazid², Mona Mohammed Refaat¹

(^{1*}Radiodiagnosis department, Faculty of Medicine, Zagazig University,

² Radiodiagnosis department, Faculty of Medicine, Cairo University).

Corresponding Author:

Name: ElShaimaa M. Mohamed, M.D^{1*}.

Address: Department of Radiodiagnosis, Faculty of Medicine, Zagazig University, Zagazig, Sharkia, 44519, Egypt.

Submit 2019-11-02
Date 04:39:02
Revise 2020-02-10
Date 14:36:52
Accept 2020-04-13
Date 17:04:29

ABSTRACT

Objective. To compare the diagnostic value of MDCT and single lateral X-ray foot in the differentiation of calcaneal fractures. Surgical data was used as reference standard.

Material and methods. 100 participants with suspected unilateral calcaneal fracture studied with lateral X-ray and MDCT. MPR obtained by the machine software in coronal and sagittal planes. The Axial and post processing scans analyzed.

Results. 100 patients examined by the two tools. Our work included 80 males and 20 females, their median age (33 years). The sensitivity, specificity and diagnostic accuracy of single lateral radiography were 100, 76.92 and 88%, respectively. The values for MDCT were 97.92, 96.15 and 97%, respectively.

Conclusion. We settled that MDCT imaging tool with MPR was better than the conventional lateral X-ray in differentiating and categorizing calcaneal fractures. However, the values of the lateral X-ray were not far from MDCT plus the low economic burden, low ionization exposure and easy availability, made it a first imaging tool in differentiating extra/intra-articular fractures. So, one study with a large population sample required to confirm the most accurate first imaging tool.

Abbreviations: MDCT” multidetector CT”, MPR”multiplanar reformat”

Keywords

Multi-detector computed tomography (MDCT), conventional lateral X-ray foot and calcaneal fractures.

INTRODUCTION

The most often fractured biggest bone of the tarsal bones was calcaneus. Sixty percentages of tarsal bone fractures was the calcaneal fracture [1].

The Essex-Lopresti classification system for calcaneal fractures was the most excellent known classification and depended upon conventional radiography findings [2]. It recognized extra-articular injuries and differentiated intra-articular injuries into joint depression and tongue type injuries. The articular fragment kept connected to a tuberosity fragment, diagnosed as a tongue-type fracture. If the articular fragment separated from the adjacent tuberosity, a joint depression-type fracture existing. This

classification offered minor prognostic outcome. Several other authors described fracture patterns and classifications, but Essex-Lopresti classification remains the standard one of them [3].

Advanced evaluation of calcaneal fractures by MDCT, which permitted excellent reorganization and description of fracture lines and fragment displacement for the choice of suitable management [4], also image reformation let traumatic victims to be scanned while they were in more comfortable, non-anatomic positions devoid of altering scan characteristics [5].

MDCT can be supportive for preoperative planning, choosing either surgical fixation or primary fusion and also, intra-operative

management with concern to fracture reduction.

Reconstructed images are obtained in coronal, axial, and sagittal planes [6]. The coronal scans afforded detailed data about the posterior facet articular surface, the sustentaculum and the location of the peroneal and flexor hallucis tendons. The anatomical data about the calcaneocuboid joint, the posterior facet's anteroinferior aspect and sustentaculum provided by axial scans. Sagittal reconstruction scans provided detailed anatomical features for the posterior facet, the calcaneal tuberosity, and the anterior process [3].

Intra-articular calcaneal fracture *Fig. (1, 2&3)* represented seventy five percentages of all calcaneal fractures in adults [1]. Numerous classification systems developed, of which the Sander's system was the most frequently applied, with many researches had settled this system to associate with management [7]. According to the fracture line position at the posterior facet, Sander's categorized intra-articular fractures into four types [8].

- Type I; was displaced fracture (displacement less than two mm) in spite of fracture lines.

- Type II displaced fracture included two articular fragments which performed by a solitary intra-articular fracture line and further categorized into lateral (IIA), central (IIB), or medial (IIC) as the fracture line anatomical site recognized .

- Type III displaced fracture enclosed three articular fragments which produced by two fracture lines and subdivided into IIIAB, IIIAC and IIIBC.

-Type IV fractures with more than three intra-articular fracture lines and presented as comminuted fractures [7].

Extra-articular calcaneal fracture was illustrated as calcaneal fracture without subtalar joint posterior facet involvement [7]. The proportion of extra-articular calcaneal fractures in adults stated to be around 25 % [9]. The general categorization of extra-articular calcaneal fracture based upon anatomical background discussed as following [7]:

Fracture of anterior process (Type A) represented 8 to 13% of the entire calcaneal

fractures [10]. About five percentages of cases with an ankle-sprain history obtained an anterior process fracture, with high proportion in females [11]. *Fig. (4)*.

Mid calcaneal fractures (Type B) involved the sustentaculum tali, lateral process and peroneal tubercle fractures. Unique sustentaculum tali fractures were unusual. Its frequency varied from 0.3 to 4 percentage. The sustentaculum tali fracture described as an intra-articular type by Essex-Lopresti , though the rest of other classifications categorized the sustentacular fractures as extra-articular [7] *Fig. (5)*.

Posterior calcaneal fractures (Type C) incorporated the posterior calcaneal tuberosity and the medial tubercle [7]. These types of fractures embrace 12 to 40% of all calcaneal fractures included. A collapse from altitude or hitting the heel on a shelf was the chief reason of the tuberosity fractures [12] *Fig. (6)*.

Avulsion fractures at extensor muscle insertion may elicit with an aggressive inversion of feet [13]. Old females mainly the target of these avulsion fractures, in whom osteoporosis described as the principal reason [14].

PATIENTS AND METHODS

Methods

Prospective cross-sectional study enrolled one hundred patients referred from Emergency department to Radio-diagnosis department in the period between February 2016 to January 2018.

Inclusion criteria in our study include participants had unilateral foot injury due to traumatic cause. Pregnant ones, participants who had prior calcaneal surgery that modified normal anatomy, combined intra and extra-articular in the same foot or non co-operative patients were the exclusion criteria.

All our participants subjected to the clinical assessment in form of full clinical history taking and clinical examination as patients assessed by the emergency physician then redirected to the radiology unit.

Radiological assessment included

Conventional lateral X-ray foot projection: all the hundred patients in our study assessed with plain radiography including lateral view of the hind-foot. Patient and cassette position,

patient lied supine and rotated on to the traumatic leg. The medial and lateral malleoli overlaid each other vertically by leg rotation. A 15-degree pad was positioned beneath the anterior of the knee and the lateral border of the forefoot for holding up. The cassette sited with the lower edge just under the plantar aspect of the heel. The X-ray beam center and direction was 2.5 cm caudal to the medial malleolus located the centre, with the vertical central ray at a 90 degree 55 angle to the cassette[7].

Bohler's angle: which is an angle between a line drawn from the posterior end to the anterior end of its superior articular facet and a second line from the latter point to the posterosuperior border of the calcaneus It is normally 25 – 40 °, with an angle less than 20 ° occurring when there is significant structural damage to the bone[8].

2-MDCT examination:

-Examination Technique:

MDCT examination of the calcaneus performed for all patients included in this study. All MDCT examinations performed with a 128-channel MDCT scanner (Philips ingenuity 128) using the subsequent parameters: detector row configuration, 128 x 1 mm; collimation, 1 mm; slice thickness, 0.90 mm; pitch, 1.375; reconstruction interval, 0.45 mm; 300 mAs; 120 kVp.

To obtain direct axial scans, patients scanned in supine position with patient's feet towards the gantry without gantry tilt. No specific patient preparation required. MDCT protocol consists of volumetric data acquisition starting from above ankle joint and ending when the calcaneus ends.

Intra-operative data and results were used as reference standard for both MDCT and conventional lateral X-ray foot.

Written informed consent was obtained from all participants, the study was approved by the research ethical committee of Faculty of Medicine, Zagazig University. The study was done according to The Code of Ethics of the World Medical Association (Declaration of Helsinki) for studies involving humans.

Statistical Analysis

The entire collected tabulated data statistically analyzed by SPSS 24.0 for windows.

Continuous data represented as the mean \pm SD, median, range, or frequencies and the categorical data represented as a number (percentage). Evaluation of the sensitivities, specificities, +ve , -ve predictive, and diagnostic accuracies were done.

RESULT

Our work included 100 feet (42% right and 58% left foot fracture); exhibiting 80% males and 20% females of all participants, their median age (33 years) as result of traumatic hitting from altitude or vehical accident. 57% fall from height and 43% road traffic accident as the distribution of cause of trauma . We had 48 extra-articular calcaneal fractures and 52 intra-articular fractures. **Table (1) and (2)** represented the frequencies of different types of extra-articular and intra-articular calcaneal fractures as detected by 128-MDCT. **Table (3)** clarified extra-articular and intra-articular calcaneal fracture cases diagnosed by 128-MDCT and conventional lateral X-ray in comparison to intraoperative data (reference standard). One case diagnosed as intra-articular type I by MDCT. However, it was extra-articular type A with calcaneo-cuboid joint involvement by surgery.

Two cases diagnosed as extra-articular by MDCT but they were intra-articular in surgery.

128-MDCT revealed 97.92% sensitivity, 96.15% specificity and 97% diagnostic accuracy in differentiating extra/intra-articular calcaneal fractures. Conventional single lateral X-ray foot showed 100% sensitivity, 76.92% specificity and 88% diagnostic accuracy in differentiating extra/intra-articular calcaneal fractures. In our work fifty cases had associated soft tissue edema with percentage (50%) and 15 cases had subcutaneous emphysema with percentage (15%).

Table (1): Extra-articular calcaneal fractures types categorized by 128-MDCT (n=49) frequency.

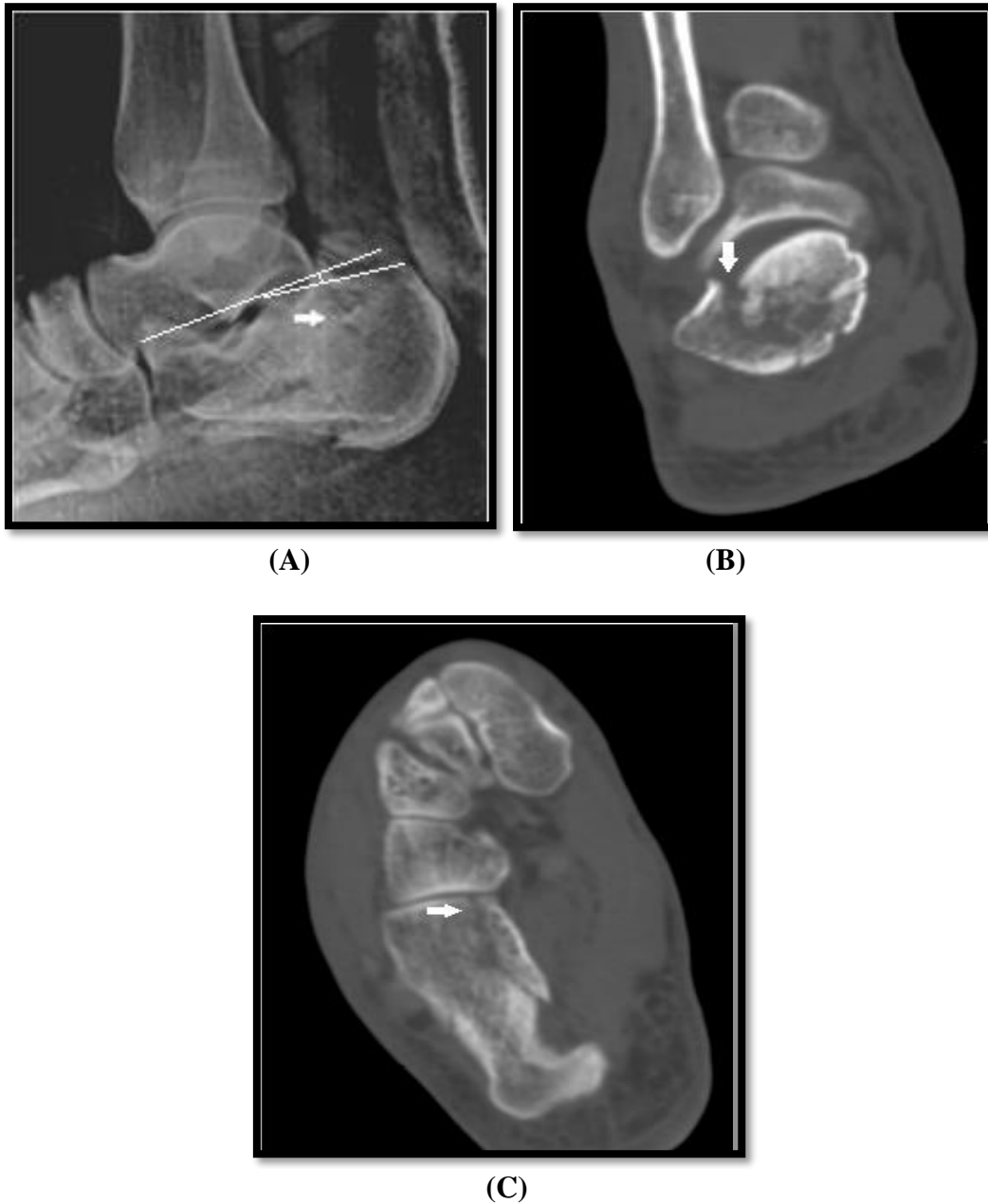Fracture type	Frequency	Percentage
Type A	27	55.1 %
Type B	9	18.4%
Type C	13	26.5%

Table (2): Intra-articular fracture types frequency and percentage according to Sanders classification (MDCT) (n=51).

Sanders Types	Frequency	Percentage
Type I	7	13%
Type II	20	39.1%
Type III	11	21.7%
Type IV	13	26.1%

Table (3): Extra-articular and intra-articular calcaneal fracture cases diagnosed by MDCT and conventional lateral X-ray in comparison to intraoperative data (reference standard):

Pathology	MDCT/Lateral X-ray	Intraoperative findings and results(reference standard)
Extra-articular Fracture	MDCT+	47
	MDCT-	1
	Lateral X-ray+	48
	Lateral X-ray-	0
Intra-articular Fracture	MDCT+	50
	MDCT-	2
	Lateral X-ray+	40
	Lateral X-ray-	12

**Figure (1):**

(A) Lateral radiograph showed a fractured calcaneus (arrow), Bohler's angle (defined by white lines) measures 11.5 (normally >20). (B) Coronal MDCT scan showed a calcaneal fracture with single primary fracture line located lateral (arrow) to the posterior facet of the subtalar joint dividing the calcaneus into two articular fragments. (C) Axial MDCT scan showed the lateral fracture line and the extent of the fracture into calcaneocuboid joint (arrow). **Diagnosed as Intra-articular calcaneal fracture Sander's type IIA.**

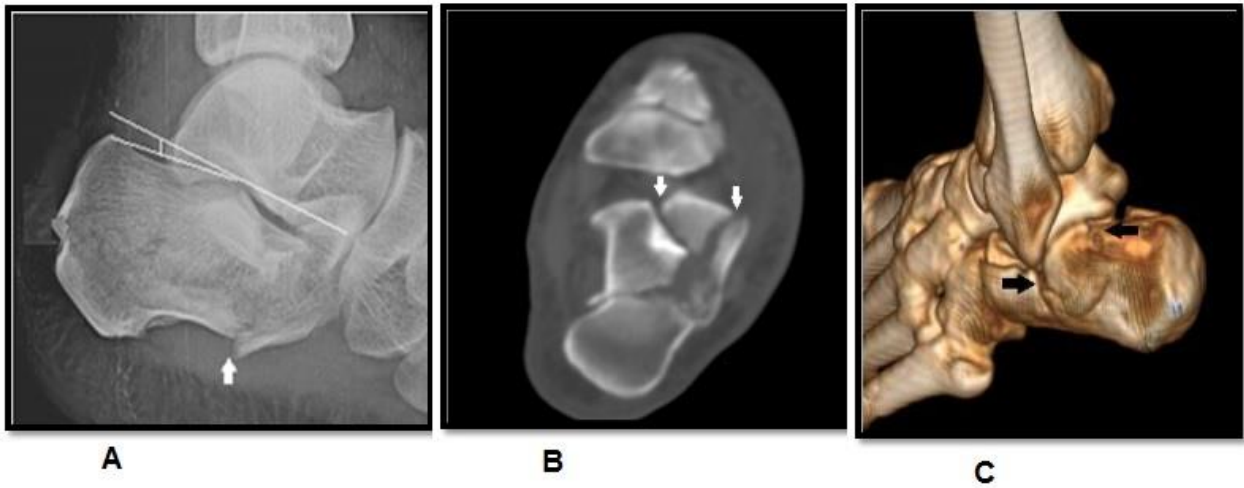
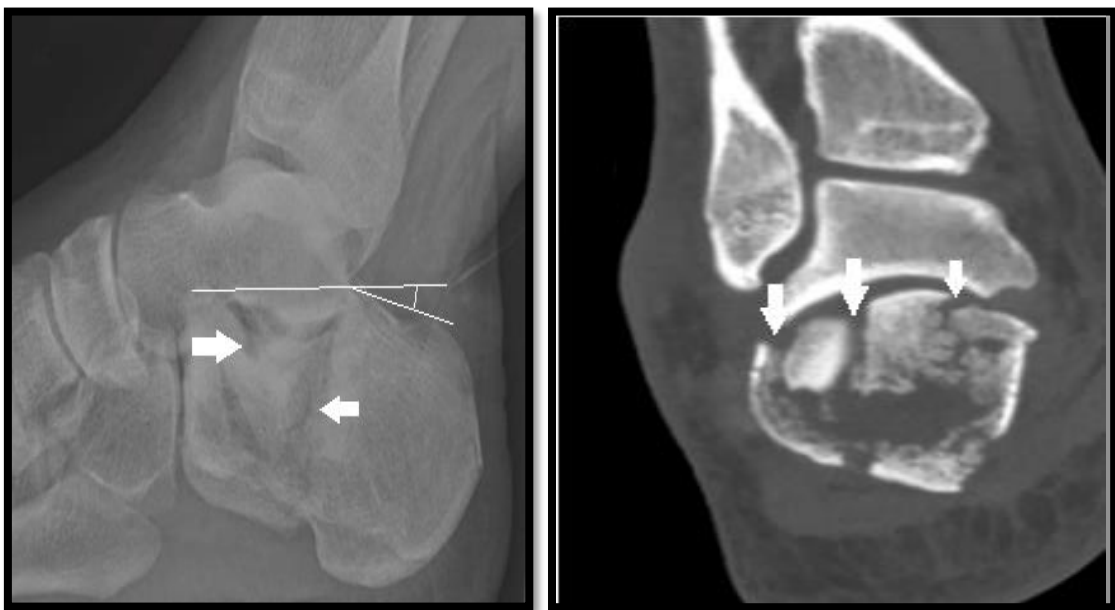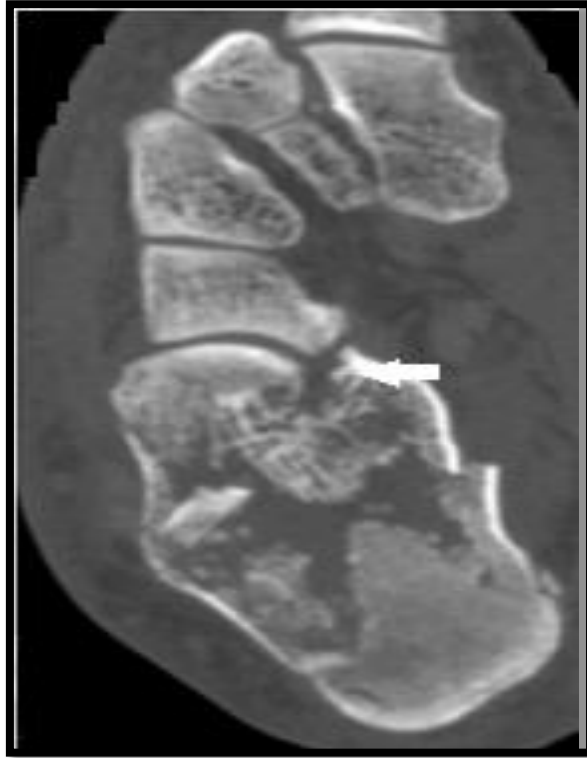


Figure (2):

(A) Lateral radiograph showed a fractured calcaneus (arrow), Bohler`s angle (defined by white lines) measures 10.3 (normally >20). (B) Axial MDCT scan showed the lateral and central fracture lines (arrows). (C) 3D sagittal oblique image showed the extent of the fracture type through subtalar joint (black arrow). **Diagnosed as Intra-articular Sander`s type IIIAB fracture.**



(A)(B)



(C)

Figure (3):

(A) Lateral radiograph showed a fractured calcaneus (arrow), Bohler`s angle (defined by white lines) measures 13.5 (normally >20). (B) Coronal MDCT scan showed a calcaneal fracture with multiple fracture lines (arrows) involving the posterior facet of the subtalar joint. (C) Axial MDCT scan showed the comminuted fracture (arrow). According to Sander`s classification diagnosed as **comminuted Intra-articular type IV fracture**.

DISCUSSION

Tim et al. [15] stated that extra-calcaneal fractures frequently occur in younger age male than female, which is similar to our results. The most frequent cause of fracture was a fall from a height, exhibiting (57%), which is like to those mentioned by Pillai et al. [8]. Regarding associated injuries with calcaneal fractures, in our study, 50 cases (50%) with soft tissue edema were found and 15 cases (15%) had subcutaneous emphysema. Soft tissue injuries were more pronounced with intra-articular fracture type, Berberian et al. [16] affirmed that intra-articular calcaneal fractures had bad end result with nearly 40% complication rate mostly due to the related soft tissue harm that highly accompanied the comminuted fractures. Bad functional outcomes of calcaneal fracture related to accompanied soft tissue injury. Because of limited occurrence frequency of extra-articular fractures, only retrospective case series and single prospective study concerning management established [15].

In our study, we had 48 patients with extra-articular and 52 patients with intra-articular fractures representing 48% and 52% respectively which disagreed with the results reached by Moussa KM et al. [5]. This could be explained by large sample number of ours.

With Sanders classification system of intra-articular fracture (MDCT) were; type I was 7 cases (13%), type II was 20 cases (39.1%), type III 11 cases (21.7%) and type IV 13 cases (26.1%). Our outcome did not agree with Bhattacharya et al. [17], this clarified by some variability and discrepancy among observers.

With extra-articular fracture MDCT classification were; type A was 27 cases (55.1%), type B was 9 cases (18.4%) and type C was 13 cases (26.5%). Our results agreed with the findings achieved by

Tim et al. [15], affirmed that the most frequently happened anterior process (type A) extra-articular calcaneal fracture.

In our study, Conventional single lateral X-ray foot illustrated 100% sensitivity, 76.92% specificity and 88% diagnostic accuracy in differentiating extra/intra-articular calcaneal fractures. Madadi et al. [18] approved that sensitivity of variable conventional X-ray varied from 0% for foot posteroanterior to 100% for combined lateral and axial calcaneal X-ray. Also, they agreed with our results as their specificity of lateral calcaneal X-ray was about 72%. Zhang et al. [19] affirmed that the sensitivity value and specificity value of single lateral view group were 94.85% and 79.07% respectively for calcaneal fracture evaluation, whereas in discriminating intra and extra-articular fractures, the two values were 69.62% and 94.44% in single lateral X-ray foot. Absolutely, skills of physician for evaluation of radiography as a confounder variable had a chief role in outcome of researches [18]. In our work, 128-MDCT revealed 97.92% sensitivity, 96.15% specificity and 97% diagnostic accuracy in differentiating extra/intra-articular calcaneal fractures. Madadi et al. [18] agreed with us in considering CT as high sensitive and specific imaging modality for categorization of calcaneal fractures. Vannier et al. [20] affirmed that higher accuracy, sensitivity and specificity of plain radiography compared to CT scan (90.7%, 85.7% and 97%, respectively). However, CT was greatest for recognizing comminuted fractures, followed by plain film [20]. Tanyu et al. [21] agreed with our results and confirmed the enhanced diagnostic value of CT scan for calcaneal fracture.

Limitations of our study:

The diagnostic values of the conventional lateral X-ray were not far from MDCT plus the low economic burden, low ionization exposure and easy availability, made it a first imaging tool in differentiating extra/intra-articular fractures. So, one study with a large population sample required to compare diagnostic value of different imaging tools and confirmed the advantage of one imaging tool to others.

CONCLUSION

We settled that MDCT imaging tool with MPR was better than the conventional lateral X-ray in differentiating and categorizing calcaneal fractures.

Acknowledgments

The authors showed appreciation for all staff members and colleagues of the Radio-diagnosis department, for their helpful cooperation and all the study participants for their patience and support.

REFERENCES

- (1) Stoller DW, Tirman PF, Bredella M. Ankle and foot, osseous fractures, calcaneal fractures. *Diagnostic imaging: Orthopedics*. 2004;70-4.
- (2) Tornetta III P. The Essex-Lopresti reduction for calcaneal fractures revisited. *J Orthop Trauma*. 1998; 12(7):469-73.
- (3) Heckman JD, McQueen MM, Ricci WM, Tornetta P, McKee MD, editors. *Rockwood and Green's fractures in adults*. Wolters Kluwer Health. 2015.
- (4) Lawendy AR, Bihari A, Sanders DW, McGarr G, Badhwar A, Cepinskas G. Contribution of inflammation to cellular injury in compartment syndrome in an experimental rodent model. *J Bone Joint Surg*. 2015; 97(4):539-43.
- (5) Moussa KM, Hassaan MA, Moharram AN, Elmahdi MD. The role of multidetector CT in evaluation of calcaneal fractures. *Egyptian J Radiol Nuclear Med*. 2015; 46(2):413-21.
- (6) OrthopaedicsOne. 12 Calcaneal fracture. *Orthopedics*. 2014;76-85.
- (7) Badillo K, Pacheco JA, Padua SO, Gomez AA, Colon E, Vidal JA. Multidetector CT evaluation of calcaneal fractures. *Radiographics*. 2011; 31(1):81-92.
- (8) Stephanie Ryan. *Diagnostic imaging*. Vol. 3RD, Anatomy for Diagnostic imaging. 2011.p.220-223.
- (9) Atkins RM, Allen PE, Livingstone JA. Demographic features of intra-articular fractures of the calcaneum. *Foot Ankle Surg*. 2001; 7(2):77-84.
- (10) Golder WA. Anterior process of the calcaneus: a clinical-radiological contribution to anatomical vocabulary. *Surgical and Radiologic Anatomy*. 2004; 26(3):163-6.
- (11) Ouellette H, Salamipour H, Thomas BJ, Kassarian A, Torriani M. Incidence and MR imaging features of fractures of the anterior process of calcaneus in a consecutive patient population with ankle and foot symptoms. *Skeletal Radiol*. 2006; 35(11):833-7.
- (12) Pillai A, Arora J, Williams C, Ferdinand RD. The sprain fracture of the calcaneus revisited. *The Foot*. 2005; 15(4):198-201.
- (13) Hall FM. Calcaneal avulsion fractures. *AJR Am J Roentgenol* 1999; 173(3):854-855.
- (14) Squires B, Allen PE, Livingstone J, Atkins RM. Fractures of the tuberosity of the calcaneus. *J Bone Joint Surg Br* 2001; 83(1):55-61.
- (15) Schepers T, Ginai AZ, Van Lieshout EM, Patka P. Demographics of extra-articular calcaneal fractures: including a review of the literature on treatment and outcome. *Archives of orthopaedic and trauma surgery*. 2008; 128(10):1099-106.
- (16) Berberian W, Sood A, Karanfilian B, Najarian R, Lin S, Liporace F. Displacement of the sustentacular fragment in intra-articular calcaneal fractures. *JBJS*. 2013; 95(11):995-1000.
- (17) Bhattacharya R, Vassan UT, Finn P, Port A. Sanders classification of fractures of the os calcis: an analysis of inter-and intra-observer variability. *J Bone Joint Surg Br*. 2005; 87(2):205-8.
- (18) Madadi F, Madadi F, Moghaddam AS. Diagnostic Value of Imaging Modalities for Suspected Calcaneal Fracture: A Systematic Review of Literatures. *Clin Res Foot Ankle*. 2016; 4:186.
- (19) Zhang T, Chen W, Su Y, Wang H, Zhang Y. Does axial view still play an important role in dealing with calcaneal fractures?. *BMC surgery*. 2015; 15(1):19.
- (20) Vannier MW, Hildebolt CF, Gilula LA, Pilgram TK, Mann F, Monsees BS, Murphy WA, Totty WG, Offutt CJ. Calcaneal and pelvic fractures: diagnostic evaluation by three-dimensional computed tomography scans. *J Digit Imaging*. 1991; 4(3):143-52.
- (21) Tanyu MO, Vinée P, Wimmer B. Value of 3D CT imaging in fractured os calcis. *Comput Med Imaging Graph*. 1994; 18(3):137-43.

To Cite

Mohamed, E., Abolyazid, S., Refaat, M. Adjuvant diagnostic value of Multi-detector computed tomography in calcaneal fracture discrimination. *Zagazig University Medical Journal*, 2022; (26-34): -. doi: 10.21608/zumj.2020.18809.1606