



Manuscript ID ZUMJ-2001-1716 (R4)

DOI 10.21608/zumj.2020.23224.1716

ORIGINAL ARTICLE

Diagnostic accuracy of magnetic resonance imaging in pregnancies with placenta previa for assessment of abnormal placentation

Mona Mohammed Refaat^{1*}, Ahmed Fekry Salem¹, Mostafa Mohamad Assy¹
Abdelrazik Elsayed Abdelrazik²

1: Department of Radiodiagnosis, Zagazig University, Zagazig, Egypt.

2 : Department of Obstetrics and Gynecology, Zagazig University, Zagazig, Egypt.

*Corresponding author:

Ahmed Fekry Salem

Lecturer of Radiodiagnosis,
Zagazig University, Zagazig,
Egypt

Radahmedfs@hotmail.com

Submit Date 08-02-2020

Revise Date 13-04-2020

Accept Date 2020-04-15

ABSTRACT

Background: To evaluate the accuracy of magnetic resonance imaging in assessment and characterization of placental implantation disorders in pregnant females with placenta previa. **Methods:** This research was carried out during period from July 2017 to June 2019 incorporated 90 pregnant females with placenta previa. The findings of MR imaging in abnormal placentation were compared with post-operative information and our results from statistical analysis were proportionated to those from the literature. **Results:** Out of 90 pregnant women with placenta previa, 21 cases had abnormal placentation at MRI and post-operatively, 8 cases with placenta accreta, 3 with increta and 10 with percreta. MRI has 100 % sensitivity, specificity, positive predictive value (PPV) and negative predictive value (NPV). **Conclusion:** MRI was highly accurate in recognition of myometrial invasion and type of anomalous placentation with high sensitivity in diagnosis of abnormal placentation, proper assessment in pre-operative diagnosis of placental invasion and thus reducing morbidity rate and improving outcome.

Keywords: Magnetic Resonance Imaging; Placenta Accreta; Placenta Previa; Placentation.

INTRODUCTION

Placenta previa is an obstetric problem where the placenta is partly or entirely inserted into the inferior uterine segment and it is a major reason for prepartum bleeding. Placenta accreta (PA) happens if a decidua basalis defect enables chorionic villi to be invaded into the myometrium. PA is categorized based on myometrial invasion depth. In placenta accreta, the simplest form of abnormal placentation, villi are connected to the myometrium but the muscle is not intruded. Villi incompletely invade the myometrium in placenta increta. The major serious type is placenta percreta, where the whole thickness of the myometrium is

invaded or even extends beyond the serosa [1].

The chief risk related to that unusual placental placement mainly arises from considerable bleeding occurring at delivery time necessitating maternal hospital stay for a longer period and transfusion of blood [2].

Furthermore, there are other complications frequently seen in cases of placenta accreta as pulmonary embolism, injury of the urinary bladder or ureters, need to use the ventilator, repetition of surgery and admission to intensive care unit (ICU) [3].

Placenta accreta risk variables consist of previous cesarean delivery, uterine instrumentation and intrauterine synechiae, which can all be accompanied by decidua

basalis damage or lack. Additional significant issues are smoking, placenta previa, mother's age above 35 years, multiparity and repeated abortions [4-5].

A more recent study found that mortality was significantly lower if abnormal placentation was suspected prior to delivery [6]. Maternal mortality is also significantly decreased when cautious peripartum scheduling is carried out [6-8]. A 37 weeks scheduled hysterectomy or a conservative method is prearranged for the suggested management of assumed placental infiltration, while surgical management may be personalized [9]. A precise prenatal diagnosis is essential for the assumed consequences and for treatment [10].

In evaluating the placenta, ultrasound is assumed to be the first imaging method where the features suggestive of placental invasion are loss of the retroplacental hypoechoic clear zone, loss of the bladder wall-uterine interface, presence of placental lacunae (vascular spaces), and presence of hypervascularity of the interface between the uterine serosa and the bladder wall on color doppler imaging. Recently, however, MRI has become a developing method for diagnosing and characterizing placenta accreta in suspected pregnancies with strong clinical doubt of abnormal placentation or when the diagnosis of ultrasound is equivocal [11-12]. The aim of the study is to assess role of MRI in diagnosis of abnormal placentation in patients with placenta previa.

METHODS

Subjects:

The current study included 90 pregnant females presented with placenta previa, referred from obstetrics and gynecology department to radiology department, the study was done during period from July 2017 to June 2019. The age of patients ranged from 19 to 44 years old with mean age of 31 years.

All of these women had an elevated threat of unusual placentation (placenta accrete, increta or percreta) concerning their clinical history in either one or all of the following: placenta previa, prior uterine surgeries (e.g. cesarean deliveries, dilation &

curettage and myomectomy and parental age of 35 years or older [13-14].

Twenty three patients out of 90 had abnormal placentation; the remaining 67 cases had placenta previa without placental invasion of the myometrium. All patients had previous US examination revealed placenta previa with features suggested anomalous placentation as loss of clear retroplacental space, increase number of lacunae with increased vascularity on doppler study and loss of the bladder wall-uterine interface.

Inclusion criteria: All pregnant females with placenta previa having previous US examination suspicious of placental invasion. **Exclusion criteria:** The patients without full postpartum records were not included in our statistical results. Also patients with contraindication for MRI examination as those having artificial cardiac pacemaker or metallic prosthesis or those with severe claustrophobia, all were excluded from the research.

MRI scanning protocol

Pelvis MRI was carried out on a 1.5-T (Philips achieva) MRI device in the 3rd trimester for all patients using a phased coil. Placental MRI assessment was performed for site of the placenta, previa type, and signs of abnormal placement, even if the US was inconclusive. The studies were carried out with patients in supine position and with full urinary bladder during examination. The delivery plans were made according to the suggested degree of placenta previa on imaging and presence or absence of abnormal placentation and in most of cases elective delivery at 36 weeks gestation was done.

The following sequences have been used: T2-weighted fast spin echo images (FSE) were obtained in the sagittal, axial and coronal planes using the following parameters (TR=3500-4800 ms, TE=90-100 ms, Flip angle =90°, FOV ranging from 250-323 mm, 208x205 matrix and section thickness:5 mm intersection gap 1mm). T1-weighted spin echo images were performed with the following parameters: (TR=420-635 ms, TE=10 ms, 320x320 mm (FOV), 272x202 matrix, Flip angle (FA)= 90°, section thickness 5 mm, intersection gap 1 mm),

T1WI were obtained in the axial and sagittal planes. T2 single shot spin echo images (SSh-SE) were obtained in sagittal plane using the following parameters: TR=1500 ms, TE=309ms, FA=90°, 250x250 mm FOV, 224x127 matrix and section thickness 4-6 mm, intersection gap 1mm. No contrast was used in all cases.

Image analysis

MRI features for placenta accreta/percreta in keeping with Varghese et al [11] and Baugham et al [15], additionally of being previa in our study, are the following:

(a) uterine bulging, (b) heterogeneity in the placental signal pattern, (c) hypointense T2-WI intraplacental bands, (d) focal interruptions of myometrial wall, (e) bladder tenting and (f) placental tissue that invades pelvic structures. Cesarean section data were the reference.

Written informed permission was obtained from every participant and the study was permitted by the research ethical committee of Faculty of Medicine, Zagazig University. The job has been done in harmony with The Code of Ethics of the World Medical Association (Declaration of Helsinki) for studies involving humans.

Statistical analysis

Data collected from history, clinical and radiological examinations then statistical analysis was performed using Statistical Social Science Package (SPSS version 20.0).

RESULTS

Table 1. MRI findings of abnormal placentation in patients with placenta previa

MRI signs of abnormal placentation	Number of positive cases	Percent from positive cases
Focal myometrial interruption	13	61.9%
Loss of clear retroplacental space	16	76%
Heterogeneous placenta	18	85.7%
Dark intraplacental bands on T2WI	17	80.9%
Neighboring organs invasion	10	47.6%
Tenting of urinary bladder	2	9.5%

Twenty three patients out of 90 had abnormal placentation by previous US examination, by MRI 21 cases only had abnormal placentation with placenta accreta was 8, increta was 3 and percreta was 10 cases.

History of previous operations was found to be (100 %) in 90 cases with previous cesarean section, 2 cases with previous myomectomy (2.2 %) and 5 cases with history of dilatation and curettage (5.5 %).

The frequency of MRI signs of abnormal placentation in cases with placenta previa were demonstrated as following: focal myometrial interruption in 13 cases (61.9%), loss of clear retroplacental space in 16 cases (76%), heterogeneous placenta in 18 cases (85.7%), dark intraplacental bands on T2WI in 17 cases (80.9%), neighboring organs invasion in 10 cases (47.6%) and tenting of urinary bladder in 2 cases (9.5%), (Table 1). The examples of MRI findings are demonstrated in (Figures 1-3).

Abnormal placentation types demonstrated by MRI and confirmed by operative findings are shown in (Table 2).

The occurrence of true negative, true positive, false positive and false negative results in MRI and surgical assessments are demonstrated in (Table 3).

The sensitivity, specificity, positive predictive value (PPV) and negative predictive value (NPV) of MRI were all 100% (Table 4).

Table 2. Abnormal placentation type demonstrated by MRI and confirmed by operative findings

Abnormal placentation type	Surgical diagnosis	MRI diagnosis
Accreta	8 (38%)	8 (38%)
Increta	3 (14%)	3 (14%)
Percreta	10 (47.6%)	10 (47.6%)
Total	21 (100%)	21 (100%)

Table 3. Statistical evaluation of MRI and surgical assessment

	MRI	Post-surgical
True positive	21 (23.3%)	21 (23.3%)
True negative	69 (76.6%)	69 (76.6%)
False positive	0 (0%)	0 (0%)
False negative	0 (0%)	0 (0%)
Total	90 (100%)	90 (100%)

Table 4. Statistical evaluation of MRI in diagnosis of abnormal placentation

Imaging procedure	sensitivity	Specificity	PPV	NPV
MRI	100%	100%	100%	100%

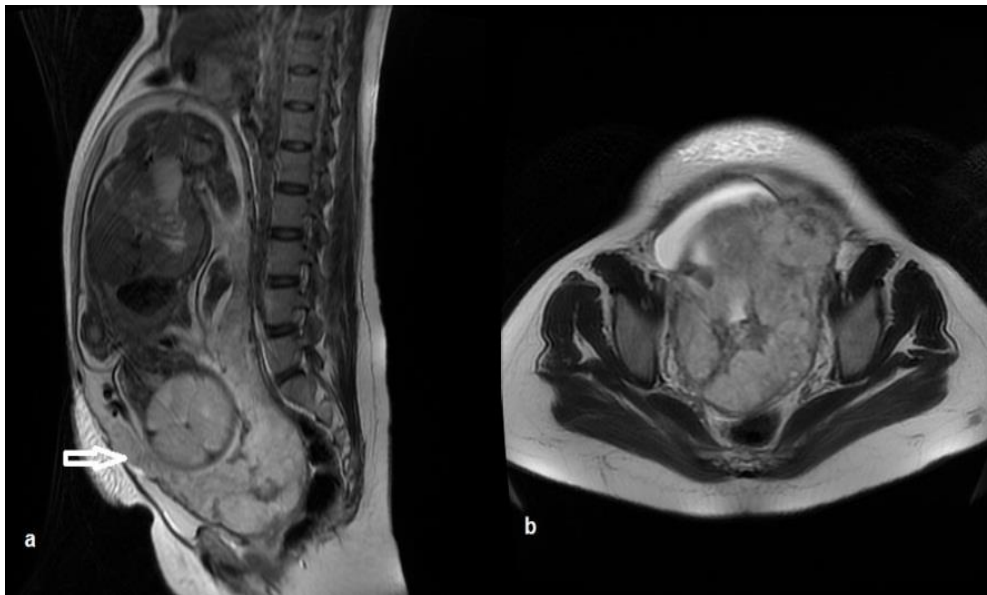

Figure 1. Female, 28 years old, pregnant at 33 weeks, presented with pelvic pain with a history of previous cesarean delivery. Placenta accreta (a) sagittal T2WI, (b) axial T2WI showing anteriorly located placenta completely covering internal os and adherent to myometrium in the lower anterior segment (arrow in a) without invasion and with preserved interface between uterus and UB. Operative findings and pathology: Placenta accreta

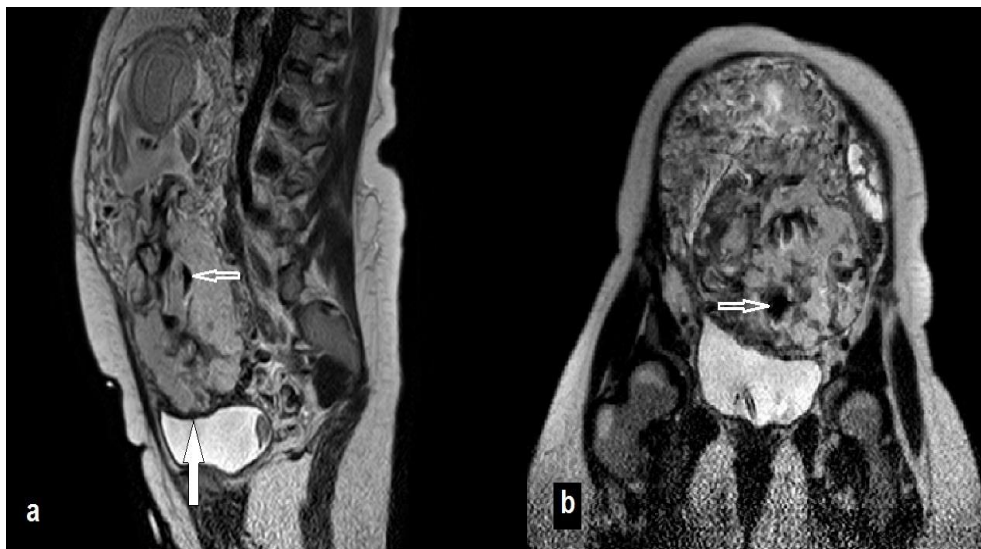

Figure 2. Female, 32 years old, pregnant at 30 weeks, presented with vaginal bleeding with a history of two cesarean deliveries. Placenta percreta (a) sagittal T2WI (b) coronal T2WI, showing anteriorly located placenta completely covering internal os with heterogeneous signal intensity, multiple low signal intensity bands (thin arrow in a and b) and markedly interrupted myometrium with loss of fat plane between placenta and urinary bladder (thick arrow in a). Operative findings and pathology: Placenta percreta

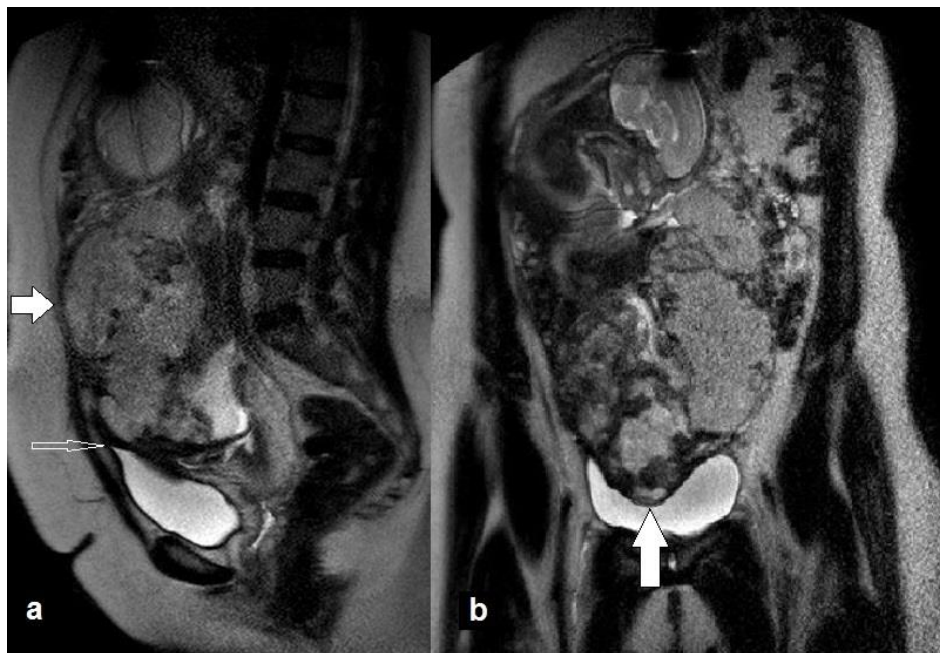


Figure 3. Female, 38 years old, pregnant at 32 weeks, presented with pelvic pain and vaginal bleeding with a history of four cesarean deliveries. Placenta percreta (a) sagittal T2WI, (b) coronal T2WI showing anteriorly located placenta completely covering internal os, heterogeneous with multiple intraplacental hypointense bands, invading full thickness of myometrium with loss of interface with anterior abdominal wall (thick arrow in a), tenting of the urinary bladder (thin arrow in a) and bulged irregular uterine contour with loss of fat plane with urinary bladder (thick arrow in b). Operative findings and pathology: Placenta percreta.

DISCUSSION

The frequency of placental invasion has increased proportionally to the increased cesarean delivery rate [16]. It is important to diagnose abnormal placentation correctly, as it reduces both mother and fetal morbidity and death rates (which increase as the invasion deepens) [17].

Maternal morbidity reduces when placental invasion is detected early. The recent guidelines are to scan with ultrasound early in the second trimester for detection of placental invasion, which is regularly done to all pregnant females [18]. Yet, as Leyendecker et al. have said [19]: The most favorable time or temporal window of the MRI examination with respect to gestational age has not been obviously recognized in the literature.

In the majority of cases, the timing of the MRI examination is determined by timing of the ultrasound examination, which raises the opportunity of abnormal placentation. Most of the researches documented that the

sonographic and MRI characteristics of placental invasion were performed in the third trimester [20,21].

In the current study, the main MRI features of abnormal placentation were: heterogeneous placenta (85.7%), dark intraplacental bands (80.9%), loss of retroplacental obvious space (76%), and focal interruption of myometrium (66.6%), this was in agreement with Algebally et al [26] who stated that MRI features of abnormal placentation were uterine bulge (87%), heterogeneity of placenta (87%) and dim intraplacental bands (75%). Also in agreement with Balcacer et al [27] who found that most common MRI criteria with invasion were intraplacental dark T2 bands, bulging of the uterus, and loss of the dark T2 edge between the placenta and the myometrium.

Catanzarite et al [28] stated that the findings of MRI for the diagnosis of placenta accreta were incorporated as through placental invasion of the uterus that tend to be as reducing or obscurity of the myometrium,

loss of T2 hypointense boundary between the uterus and placenta or even direct revelation of the placental tissue either within or outside surface the myometrium. Maldajian et al [29] reported that early diagnosis of placenta accreta established by MRI findings of direct placental penetration into the uterus by revelation of placental tissue either within or at exterior surface of the myometrium.

In the present study, MRI revealed 100% sensitivity, specificity, PVP and NPV for detection of abnormal placentation, this is going with Algebally et al [26] who stated that MRI had 100% sensitivity, specificity, PVP and NPV for detection of placental invasion. In the research done by Hemisa et al [30], they stated that adding magnetic resonance imaging to ultrasound raises the sensitivity to 100% for diagnosis of abnormal placentation. Masselli et al [31] stated that MRI had perfectly recognized the diagnosis of placental adhesive disorders in the whole cases with 100% sensitivity, specificity, PVP and NPV and this is in concordance with the results of our work.

Mansour and Elkhayat [32] revealed that MRI sensitivity and specificity for diagnosis of placenta accreta were 93.3% and 85% respectively. Warshak et al [13] established that sensitivity and specificity of MR imaging in a research of 42 patients for placental adhesion disorders were 88% and 100% respectively. MRI is an excellent imaging method for precise localization of abnormal placental implantation and deepness of myometrial invasion, and therefore deciding the ideal surgical managing plane, so it is supposed to be used routinely [33].

Despite the fact that ultrasound is still the prime method for assessing invasion of the placenta, interest has been shown in utilization of MR imaging in recent years. several authors have recommended routine use of MR imaging in assessment of placental implantation owing to its multiplanar imaging capabilities and good resolution of soft tissues, so it is able to accurately outline extents of abnormal placentation, recognize depths of invasion, and eventually modify surgical managements [22,23]. Others have proposed that MR imaging is most obviously

recommended when the placenta is located posteriorly or when there is uncertainty in the results of ultrasound. In some cases, MRI has been shown to be useful when ultrasound results are vague or not conclusive [24,25].

However there were some obstacles during the study that limit the use of MRI such as fetal movements, unclear safety considerations for the fetus and its expenses, and the limitation of our study is that we had a relatively small sample size and given the rarity of placental abnormalities and diseases.

CONCLUSION

MRI has elevated sensitivity and specificity in detection of placental invasion, it is usually used when diagnosis by US is unsatisfactory, however, routine examination by MRI increases diagnostic accuracy of abnormal placentation so decreases maternal morbidity, reduces hospital stay and improves outcome.

We recommend doing pelvic MRI for all cases with placenta previa having suspicious US features of abnormal placental myometrial invasion to accurately diagnose placental invasion and so properly managing the case.

Conflict of interest: Nothing to declare.

Funding information: Nothing to declare.

REFERENCES

- 1-ACOG Committee Opinion. Placenta accreta.No. 266. January 2002. American College of Obstetricians and Gynecologists. *ObstetGynecol*, 2002; 99: 169–70.
- 2-Usta IM, Hobeika EM, Musa AA, Gabriel GE, Nassar AH: Placenta previa–accreta: risk factors and complications. *Am J ObstetGynecol*, 2005; 193: 1045–49
- 3-Silver RM: The MFMU cesarean section registry: maternal morbidity associated with multiple repeat cesarean deliveries. *ObstetGynecol*, 2006; 107: 1226–32
- 4-Clark SL, Koonings PP, Phelan JP: Placenta previa/accreta and prior cesarean section. *ObstetGynecol* 1985; 66: 89–92
- 5-Gielchinsky Y, Rojansky N, Fasouliotis SJ, Ezra: Placenta accreta: summary of 10 years: a survey of 310 cases. *Placenta*, 2002; 23: 210–14.
- 6-Jennifer L. Bailit, William Grobman, Madeline Murguia Rice, Uma M. Reddy, Ronald J. Wapner, Michael W. Varner et al. *Morbidity*

- adherent placenta treatments and outcomes. *ObstetGynecol* 2015; 125:683–89.
- 7-Ng MK, Jack GS, Bolton DM, Lawrentschuk N. Placenta percreta with urinary tract involvement: the case for a multidisciplinary approach. *Urology* 2009; 74:778–82.
- 8-Allahdin S, Voigt S, Htwe TT. Management of placenta praevia and accreta. *ObstetGynaecol* 2011; 31:1–6.
- 9-Palacios-Jaraquemada JM. Diagnosis and management of placenta accreta. *Best Pract Res Clin ObstetGynaecol* 2008; 22:1133–48.
- 10- Eller AG, Bennett MA, Sharshiner M, Masheter C, Soisson AP, Dodson M, et al : Maternal morbidity in cases of placenta accreta managed by a multidisciplinary care-team compared with standard obstetric care. *ObstetGynecol* 2011; 117:331–37.
- 11-Binoj Varghese, Navdeep Singh, Regi AN George, Sareena Gilvaz : Magnetic resonance imaging of placenta accrete. *Indian J Radiol Imaging* 2013;23(4):379–85.
- 12-Lax A, Prince MR, Mennitt KW, Schwebach JR, Budorick NE. The value of specific MRI features in the evaluation of suspected placental invasion. *MagnResonImag*, 2007;25:87–93.
- 13-Warshak CR, Eskander R, Hull AD, Scioscia AL, Mattrey RF, Benirschke K, et al: Accuracy of ultrasonography and magnetic resonance imaging in the diagnosis of placenta accreta. *ObstetGynecol*, 2006; 108: 573–81.
- 14-Dwyer BK, Belogolovkin V, Tran L, Rao A, Carroll I, Barth R, et al: Prenatal diagnosis of placenta accreta: sonography or magnetic resonance imaging? *J Ultrasound Med*, 2008; 27: 1275–81.
- 15-Baughman WC, Corteville JE, Shah RR. Placenta accreta: spectrum of US and MR imaging findings. *RadioGraphics* 2008;28:1905–16.
- 16- Esakoff T, Sparks T, Kaimal A, Kim L, Feldstein V, Goldstein R, et al. Diagnosis and morbidity of placenta accreta. *Ultrasound ObstetGynecol* 2011; 37:324–27.
- 17-Balayla J, Bondarenko HD. Placenta accreta and the risk of adverse maternal and neonatal outcomes. *J Perinat Med* 2013; 41:141–49.
- 18-Stirnemann JJ, Mousty E, Chalouhi G, Salomon LJ, Bernard JP, Ville Y. Screening for placenta accreta at 11–14 weeks of gestation. *Am J ObstetGynecol* 2011; 205:547.e1–547.e6.
- 19-Leyendecker John, Melinda DuBose, Keyanoosh Hosseinzadeh, Ryan Stone, John Gianini, David D. Childs, et al. MRI of pregnancy related issues: abnormal placentation. *AJR Am J Roentgenol* 2012; 198:311–20.
- 20-D’Antonio F, Iacovella C, Bhide A. Prenatal identification of invasive placentation using ultrasound: systematic review and meta-analysis. *Ultrasound ObstetGynecol* 2013; 42:509–17.
- 21- D’Antonio F, Iacovella C, Palacios-Jaraquemada J, Bruno CH, Manzoli L, Bhide A. Prenatal identification of invasive placentation using magnetic resonance imaging: systematic review and meta-analysis. *Ultrasound ObstetGynecol* 2014; 44:8–16.
- 22-Palacios Jaraquemada JM, Bruno CH: Magnetic resonance imaging in 300 cases of placenta accreta: surgical correlation of new findings. *Acta ObstetGynecol Scand*, 2005; 84: 716–24.
- 23- Seet EL, Kay HH, Wu S, Terplan M: Placenta accreta: depth of invasion and neonatal outcomes. *J Matern Fetal Neonatal Med*, 2012; 25:2042–45.
- 24-Levine D, Hulka A, Ludmir J, Li W, Edelman R. Placenta accreta: evaluation with color Doppler US, power Doppler US, and MR imaging. *Radiology*, 1997; 205: 773–76.
- 25-Derman Y, Nikac V, Haberman S, Zelenko N, Opsha O, Flyer M, et al: MRI of placenta accreta: a new imaging perspective. *AJR Am J Roentgenol*, 2011; 197:1514–21.
- 26- Algebally A.M., Yousef R.R., Badr S.S., Obeidly A., Szmigielski W., Al Ibrahim A.A. The Value of Ultrasound and Magnetic Resonance Imaging in Diagnostics and Prediction of Morbidity in Cases of Placenta Previa with Abnormal Placentation. *Pol J Radiol*, 2014; 79: 409-16.
- 27- Balcacer P, Pahade J, Spektor M, Staib L, Copel J, McCarthy S: Magnetic Resonance Imaging and Sonography in the Diagnosis of Placental Invasion. *J Ultrasound Med* 2016; 35:1445–56.
- 28-Catanzarite VA, Stanco LM, Schrimmer DR, Conroy C. Managing placenta previa/accreta. *Contemp ObstetGynecol* 1996;41:66–95.
- 29-Maldjian C, Adam R, Pelosi M, Pelosi M III, Rudelli R, Maldjian J. MRI appearance of placenta percreta and placenta accreta. *MagnReson Imaging* 1999;17:965–71.
- 30- Hamisa M, Mashaly E, Fathy S, Tawfeek A: Role of Doppler US and MRI in diagnosis of placenta accrete. *Alexandria Journal of Medicine* 2015;225–30.
- 31-Masselli G, Brunelli R, Casciani E, Poletini E, Piccioni M, Anceschi M, et al. Magnetic

resonance imaging in the evaluation of placental adhesive disorders: correlation with color Doppler ultrasound. *Eur Radiol*2008;18:1292–9.

32-Mansour SM, Elkhayat WM. Placenta previa–accreta. Do we need MR imaging? *EJRN*2011;42:433–43.

33-Oyelese Y, Smulian JC. Placenta previa, placenta accreta and vasaprevia. *ObstetGynecol* 2006;107:927–41.

Cite This Article

Refaat, M., Salem, A., Assy, M., Abdelrazik, A. Diagnostic accuracy of magnetic resonance imaging in pregnancies with placenta previa for assessment of abnormal placentation. *Zagazig University Medical Journal*, 2021; (184-192): -. doi: 10.21608/zumj.2020.23224.1716