

COMPUTER-ASSISTED SURGERY IN MANAGEMENT OF MANDIBULAR FRACTURE USING A CUSTOM-MADE TITANIUM MESH TRAY

Ahmed M. Helmy ^{1*} BDS, Nagy H. El Prince ² PhD, Riham M. Fliefel ³ PhD.

ABSTRACT

INTRODUCTION: The mandible is the second most common facial fracture due to its prominence and position. Continuous clinical and biomechanical studies implemented in order to improve the techniques and materials used, leading to reduction in the immobilization period and augmentation of rigid fixation. Computer assisted surgery technology, greatly plays an important role in designing the surgery, facilitating adaptation and fixation.

OBJECTIVES: To evaluate clinical and radiographic outcomes of fixation of mandibular fractures using custom-made titanium mesh adapted on 3D model by virtual planning.

MATERIALS AND METHODS: Fifteen patients with recent mandibular fracture were treated using custom-made titanium mesh on 3D model. Clinical follow up was conducted after 24-hours, one, four, six, twelve weeks and six months. In addition, a radiographic investigation was performed immediately postoperatively and after six months to estimate the mean bone density across the fracture line.

RESULTS: All cases showed normal lower lip sensation both preoperatively and postoperatively with no statistical significance, improved occlusal and intercuspation relation in addition to stabilized intrafragmentary mobility. A statistically significant decrease in intensity of pain was detected based on the Visual Analogue Scale (VAS). Two cases showed disturbed wound healing. The mean bone density after twelve weeks showed a statistically significant increase in its values when compared to the immediately postoperative values ($p < 0.001$).

CONCLUSIONS: The use of custom-made titanium mesh adapted on a 3D model resulted in a satisfactory outcome, in terms of achieving adequate reduction and fixation.

KEYWORDS: Mandible, Fracture, Computer-assisted, Titanium mesh, 3D model.

1- Bachelor of Dental Surgery, Faculty of Dentistry, Alexandria University, Alexandria, Egypt.

2- Professor of Oral and Maxillofacial Surgery Alexandria University, Alexandria, Egypt.

3- Lecturer at the Oral and Maxillofacial Surgery Department, Faculty of Dentistry, Alexandria University, Alexandria, Egypt.

* Corresponding author:

E-mail: dr_7elmy900@yahoo.com

INTRODUCTION

The role of the mandible is crucial in maintaining facial esthetics and functional occlusion. The prominence of the lower jaw, its position and the fact of being the only mobile bone in the face, makes mandibular fractures represent the most common fractures of the facial skeleton. The incidence of mandibular fractures constitutes about 59% of all maxillofacial fractures (1).

Although, the mandible is one of the largest and strongest facial bones, it is one of the most often injured bones in the body (1). The site and pattern of injury vary according to the mode of trauma and the magnitude of the force (2). The angle and the condylar region contribute the majority of mandibular fractures (3).

The main concern in the management of mandibular fractures is to properly regain function and esthetics (4). The treatment of mandibular fractures involves different modalities such as closed reduction with intermaxillary fixation, open reduction with wire osteosynthesis and open reduction with rigid intermaxillary fixation (5).

With modern surgical advances, modalities for the treatment of mandibular fracture depend on scientific facilities and the need of early, or preferably, immediate mobilization, in order to reduce the need of maxillo-mandibular fixation (MMF). Whereas MMF is to blame for impairing the oral hygiene, masticatory efficiency and

mouth opening besides it causes pain, phonetic disturbance and weight loss (6).

Nowadays computer technology represents an important role in our daily life. It provides many diagnostic imaging procedures that help in proper diagnosis of many disorders. Regarding the oral and maxillofacial field, it plays a major role in treatment planning. The computer technologies become not only limited for treatment planning, but also dealing with surgical interventions. The Era of three-dimensional (3D) imaging technology provides many tools determining the preoperative planning (7).

The application of 3D-virtual environment provides a guide for the surgical planning and simulation of the mandibular fractures. Computer Aided Surgical Simulation (CASS) provides surgeons with the best possible scenario for preoperative treatment planning. The possibility of generating a three-dimensional model from CT scans was first mentioned in 1987 (8).

Thus, the objective of this study was to evaluate the use of virtual planning in management of mandibular fracture using custom-made titanium mesh on 3D model as well as healing of the mandibular fracture from a clinical and radiographic perspective.

MATERIALS AND METHODS

Appropriate ethical clearance was obtained from the ethical committee of Alexandria Dental University. This study was a prospective clinical randomized controlled clinical trial conducted on patients selected from the Emergency Ward of Alexandria University Teaching Hospital. All patients met the inclusion criteria, signed an informed consent before going on surgical operation at the Oral and Maxillofacial Surgery Department, Faculty of Dentistry, Alexandria University.

Patients

Fifteen patients with mandibular fracture have been included in this study suffering from recent, uninfected unfavourable mandibular fracture that demands open reduction and internal fixation, with an age range of 20-50 years with no gender predilection that agreed to present for follow-up visits for a minimum postoperative period of six months. Patients were excluded if they are (a) medically compromised contradicting the surgery, (b) existence of infection at the fracture line, (c) patient could not wait 3–5 days for a design to be created, (d) presence of lacerations and soft tissue loss, (e) pathological fracture, (f) an old fracture and edentulous patient.

Methods

Titanium mesh & screws used were purchased (Anton Hipp GmbH, Fridingen, Germany) and accurately adapted on a 3D model that was fabricated from liquid resin (E-Den stone). The model was fabricated from OnDemand3D™ software (310 Goddard Way, Suite 250 Irvine, CA USA, <https://www.ondemand3d.com>) that allows DICOM data storage and conversion to STL files. Exocad software (DentalCAD 2.3, Darmstadt Germany) was used for the reduction and relocalization of the fracture.

A full history taking was performed to collect the demographic data of the patients, including name, age, sex, occupation, address, and etiological factor of the fracture. Followed by a thorough clinical intraoral and extra oral examination was performed to record swelling, facial deformity, bleeding, ecchymosis, jaw deviation during function and soft tissue laceration by inspection in addition to condylar movements during opening and closing, and altered lip sensation by palpation.

Preoperatively, routine orthopantomograms (OPG) were done for all patients which gave a general survey about the fracture line. After which, Computerized tomograms (CT) were obtained for all patients to show the extent of fracture line, reveal the degree and direction of displacement, examine number and pattern of concurrent fracture lines, help in the localization of inferior alveolar nerve, measure the extent of the fractured bone segments, and for 3d model fabrication as shown in Figure (1).

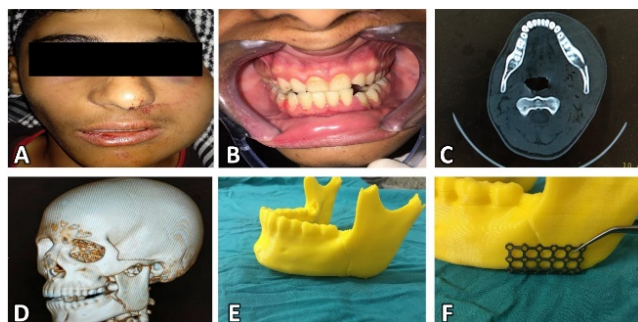


Figure (1): Shows a presentation of a case with left angle fracture preoperatively.

Surgically, all patients were operated under general anaesthesia using nasotracheal intubation. Povidone-iodine (Betadine 7.5%; Purdue Products L.P) solution was used to scrub the surgical field, extra oral then intraoral, followed by draping of the patient with sterile towels revealing only the surgical field. Teeth in the fracture line were managed either by extraction or preservation as each case indicated. Maxillo-mandibular fixation (MMF) was temporarily secured to provide proper occlusion that served as a guide for fracture reduction. Fracture line/s were exposed through either intra-oral or extra-oral approach. The fracture was curetted to remove any soft tissue entrapment and the fractured segments were reduced into proper anatomical position, with the aid of bone reduction forceps. Titanium mesh was applied on the fracture site and fixed using screws. The surgical field was irrigated with Povidone-iodine and saline in preparation for wound closure. Intraoral wound was closed using Vicryl 3/0 resorbable suture material (90% glycolide and 10% L-lactide: Ethicon, USA) while extra oral incision was managed in layers using Vicryl sutures for the deep layers and Prolene sutures (polypropylene: Ethicon part of Johnson & Johnson Int, US) for the skin Figure (2).

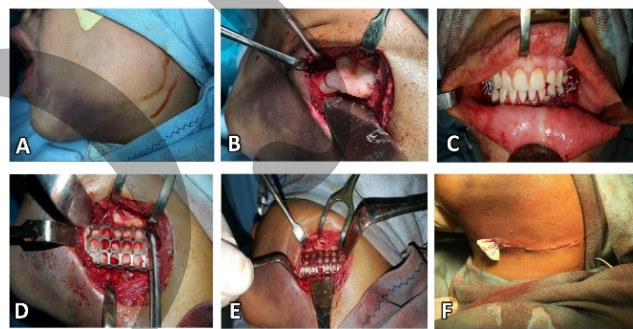


Figure (2): Shows the intraoperative reduction and fixation of the fracture using the custom made titanium mesh.

All the patients received post-operatively, intravenous cefotaxime 1 gm/12 hours for the first day and followed by oral administration of Augmentin 1 gm tablets (Amoxicillin 875 mg + Clavulanic acid 125 mg: GlaxoSmithKline, UK.) twice daily for 5 days, Flagyl 500 mg tablets (metronidazole 500mg: GlaxoSmithKline, UK.) every eight hours, Alphintern as anti-oedematous once daily (Amoun pharmaceutical, Egypt) and Cataflam 50 mg tablets (Novartis, Switzerland) as analgesic every eight hours. All patients were instructed to rinse their mouth using chlorhexidine antiseptic mouth wash. Patients were radiographically assessed using an immediate postoperative digital orthopantomogram (OPG) to evaluate the condition of the tooth/teeth in the fracture line/s in addition to postoperative CT-scan to evaluate the accuracy of reduction, another scan was taken after six months to show fracture healing progression and estimate the mean bone density at the fracture line in comparison with the immediate postoperative scan. All of the measurements were in Hounsfield Units (HU) Figure (3).

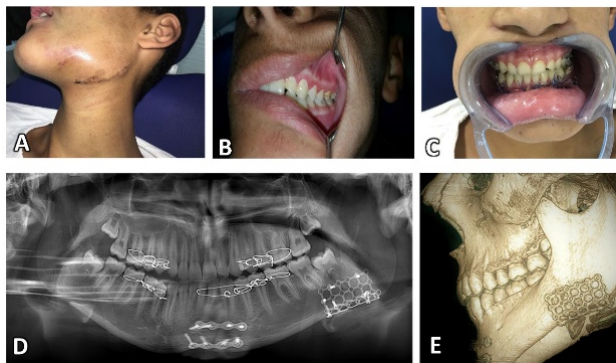


Figure (3): Shows a 6 months postoperative follow up both clinically and radiographically.

Statistical analysis

The data were documented, tabulated and statistically analyzed utilizing the IBM SPSS software package version 20.0 (Armonk, NY: IBM Corp). The data were presented by using range (minimum and maximum), mean, standard deviation and median. The ANOVA with repeated measures test was used for normally distributed quantitative variables, to compare between more than two periods or stages, and the Friedman test for the abnormally distributed quantitative variables. The significance of the obtained results was judged at the 5% level (P<0.05).

RESULTS

All the patients in this study (n=15) were treated with open reduction and direct internal skeletal fixation using a custom made titanium mesh adapted on a 3D model. They consisted of nine males (60%) and six females (40%). Their age ranged from 20 -50 years with a mean age of 31.60 ± 9.19 years. The most common etiological factor was found to be Road Traffic Accidents (RTA) (60%, n = 9) the remaining fractures were the result of Intra personal violence (26.7% n= 4), and sports-related injury (13.3%, n=2) (Table 1).

Table (1): Showing the distribution of the studied cases according to demographic data (n= 15).

Characteristic	% (n=15)
Gender	
Male	60% (n=9)
Female	40% (n=6)
Age (years)	
Min. – Max	21.0 – 48.0
Mean ± SD	31.60 ± 9.19
Median	31.0
Cause	
RTA	60.0%(n=9)
IPV	26.7%(n=4)
Sports related injuries	13.3%(n=2)

Out of the fifteen patients in this study; eight patients had mandibular angle fracture (53.3%) (three left side fractures and five in the right side), three patients had mandibular body fracture (two in the right side and one in the left side) (20.1 %), and two patients had fracture anterior to the mental foramen (four symphyseal) (26.6%).

Clinically, a thorough follow-up was done for all the patients after 24-hours, one week, four weeks, six weeks, twelve weeks and six months. Through the follow up period, all cases experienced a decrease in level of pain

intensity score based on the Visual Analogue Scale (VAS). The postoperative pain completely disappeared at the sixth week and continued with no pain till the end of the follow up period. The decrease in pain intensity across the follow up period was statistically significant (P value < 0.001) (Table 2). All of the patients reported normal lower lip sensation using pin prick test. A normal occlusal and intercuspal relation were reported for all patients upon their occlusal examination with no need for selective grinding in any case during the follow up period. 13.3% (n=2) of the cases showed postoperative wound infection at the first postoperative week, which was treated by antibiotic course and wound care. Regarding the intra-fragmentary mobility, the postoperative values in all follow up phases showed a statistical significant difference compared to the preoperative values.

Table (2): Comparison between the different studied periods according to pain (n=15)

Pain (0-10)	Preop	24 hours	1 Week	4 Weeks	6 Weeks	12 Weeks	6 Months	Fr (p)
Min. – Max.	8.0 – 10.0	7.0 – 10.0	5.0 – 7.0	0.0 – 2.0	0.0 – 0.0	0.0 – 0.0	0.0 – 0.0	87.0 63* (<0.001*)
Mean ± SD.	9.47 ± 0.64	8.47 ± 0.99	6.0 ± 0.85	0.40 ± 0.63	0.0 ± 0.0	0.0 ± 0.0	0.0 ± 0.0	
Median	10.0	8.0	6.0	0.0	0.0	0.0	0.0	
p1		0.398	0.020*	<0.001*	<0.001*	<0.001*	<0.001*	

Fr: Friedman test, Significant between Periods was done using Post Hoc Test (Dunn's).

p: p value for comparing between the different periods.

p1: p value for comparing between preoperative and each other periods.

*: Statistically significant at p ≤ 0.05.

A radiographic appraisal was performed by determining the mean bone density in the vicinity of the fracture line through a preoperative and 6 months postoperative CT scans. The calculated mean bone density in the immediate postoperative scans was 983.6 ± 19.63, while that in the 6 months postoperative CT scans was 1184.3 ± 36.15. when comparing the bone density outcomes between both radiographic assessments, a statistically significant increase in mean bone density was recorded (p<0.001), which is coherent with fracture healing progress (Table 3).

Table (3): Comparison between the three studied periods according to bone density (n=15).

Bone density	Post-operative		t	p
	Immediate	6Months		
Min. – Max.	953.9 – 1021.3	1136.8 – 1258.2	28.373*	<0.001*
Mean ± SD.	983.6 ± 19.63	1184.3 ± 36.15		
Median	988.1	1181.2		

DISCUSSION

The regaining of functional stability and the pre morbid state of occlusion are the fundamental issues for the maxillofacial surgeon during the management of mandibular fractures, as

these cases represent a very demanding and continuously evolving scope of work. The utilization of titanium mesh as an internal fracture-fixative device has been known to be practiced in the orthopedic field for several years with refinement of the utilized technique over time (9-11).

The modern innovation of virtual surgery and computer-aided design have left a great impact on the surgical fields, and the maxillofacial trauma field is no exception (12).

The titanium mesh gives the fracture line a significantly better stability than the conventional miniplates, owing to its excellent physical and biomechanical properties along with the presence of extra vertical support that effectively counter torque forces from acting on the fracture line, thus decrease the probability of fracture line infection, mal-union or non-union (9, 13). Furthermore, the mesh's malleability, semi-rigidity and lack of elastic memory features, prevent subsequent stress shielding in the fractured area (14).

The indexed modern maxillofacial trauma literature falls short in providing sufficient data about the prospective outcomes of titanium mesh fixation in non-comminuted mandibular fractures. Henceforth, this study was conducted to clinically and radiographically evaluate the performance of titanium mesh fixation in mandibular fracture.

During the follow up period, all the patients experienced a progressive and statistically significant decrease in level of pain intensity score based on the Visual Analogue Scale (VAS) till it virtually disappeared completely at the sixth week ($p < 0.001$). The recorded values assumed that adequate stabilization of the bone fragments across the fracture line eliminated pain and discomfort of the patient.

Regarding the postoperative intra-fragmentary mobility, it was significantly detected preoperatively but after the operation it was no more encountered in any of the 15 cases across the follow up period, hence a self-explanatory statistically significant difference was found when compared to the preoperative records ($p < 0.001$).

A similar outcome was reported by Mittal et al, in their study about three-dimensional plates in mandibular fracture, and also by Goyal et al, in their study about three-dimensional locking plate and regular miniplates. These results demonstrate the comparative ability of the titanium mesh osteosynthesis with the certified and routinely utilized fixation devices (15, 16).

Concerning the state of the postoperative occlusion, all the subjects upon their occlusal examination exhibited a normal intercuspal centric occlusal relation and there was no need for elastic traction, selective grinding or even selective extraction in any case during the follow up period. A similar result was disclosed by Cobetto et al, while Kaur et al, reported 5 cases with disturbed postoperative occlusion which required elastic traction or occlusion adjustment through selective grinding or extraction, and regained normal occlusion by the 6th postoperative week (11, 17).

All of the treated cases reported, subjectively and objectively, a normal postoperative lower lip sensation using the pin prick test. This outcome was in accordance with that of Chhabaria et al, (18). On the other hand, Guimond et al, reported a 25% of the cases with lower lip sensory deficiency and paraesthesia, which regained normal sensation after three months (19). As stated by Singh et al, sustaining a postoperative paraesthesia rather depends more

on the degree of the preoperative displacement and aggressive fracture manipulation than the proximity of the fixative device to the nerve (20). In cases where bone exposure around the mental nerve area was needed, a proper adaptation and freeing space were performed in order to avoid unjustified iatrogenic nerve injury during the placement of the titanium mesh. Furthermore, meticulous intraoperatively nerve identification and dissection from its housing sheet was performed to relieve tension and give chance to its gentle tension free retraction. All of these precautions may have contributed to the favourable outcomes in this study.

Two out of the treated 15 cases experienced postoperative wound infection after the first postoperative week (13.3%). Wound care was performed and an antibiotic course was prescribed and infection subsided in both patients by the beginning of the third postoperative week. A roughly similar percentage of postoperative infection following open reduction and internal fixation (ORIF) was reported by Shridharani, (1.1%) (21). The great cutback in the reported percentage of wound infection following ORIF procedures occurred as a result of the advances in the medical field, the strict infection control protocol, aseptic intraoperative techniques, and the prescription of postoperative antibiotics.

None of the treated case showed neither postoperative wound dehiscence nor hardware exposure. A similar outcome was reached by Pattar et al, (22). Kaur et al, who reported one patient with wound dehiscence and mesh exposure after the first postoperative week (6.66%) (11).

A radiographic appraisal was performed by determining the mean bone density in the vicinity of the fracture line through a preoperative and 6 months postoperative CT scans. The calculated mean bone density in the immediate postoperative scans was 983.6 ± 19.63 , while that in the 6 months postoperative CT scans was 1184.3 ± 36.15 . when comparing the bone density outcomes between both radiographic assessments, a statistically significant increase in mean bone density was recorded ($p < 0.001$), which is coherent with fracture healing progress in consistent with the study that was carried out in 2004 by Doblal et al who stated a similar significant increase in bone density as an indicator for primary bone healing after the utilization of miniplates (23).

The variations in X-ray exposure, the positional restriction in trauma patients and the limited two dimensional fracture line perspective make the use of the conventional radiographs inconvenient in maxillofacial trauma patients.

Schulze et al pointed out that the multiple number of views needed for actual detection of a fracture line (24). A preoperative CT-scan provided a multi-planar 2D images with the availability of a rapid 3D view which give surgeons a fast initial view of the fracture sites and their extent of displacement. This preoperative scan was mandatory for the fabrication of the stereolithographic model and in the processes of preoperative titanium mesh customization (25). Another important feature of CT scans is their ability to correctly determine bone density in Hounsfield unit, where several studies managed to utilize it as a baseline for bone density assessment and help in evaluating the fracture healing progression (26, 27).

CONCLUSION

Although it is a technique sensitive treatment modality that necessitates surgical skills and considerations during placement, the use of custom made titanium mesh using computer assisted surgery for mandibular fractures management revealed acceptable wound and bone healing outcomes.

CONFLICT OF INTEREST

The authors declare that they have no conflicts of interest.

REFERENCES

- Ghodke MH, Bhojar SC, Shah SV. Prevalence of mandibular fractures reported at C.S.M.S.S Dental College, aurangabad from february 2008 to september 2009. *J Int Soc Prev Community Dent.* 2013;3:51-8.
- Fasola A, Obiechina A, Arotiba J. Incidence and pattern of maxillofacial fractures in the elderly. *Int J Oral Maxillofac Surg.* 2003;32:206-8.
- Singh S, Fry RR, Joshi A, Sharma G, Singh S. Fractures of angle of mandible: A retrospective study. *J Oral Biol Craniofac Res.* 2012;2:154-8.
- Koshy JC, Feldman EM, Chike-Obi CJ, Bullocks JM. Pearls of mandibular trauma management. *Semin Plast Surg.* 2010;24:357-74.
- El-Anwar MW, Sayed El-Ahl MA, Amer HS. Open reduction and internal fixation of mandibular fracture without rigid maxillomandibular fixation. *Int Arch Otorhinolaryngo.* 2015;19:314-8.
- Bhatnagar A, Bansal V, Kumar S, Mowar A. Comparative analysis of osteosynthesis of mandibular anterior fractures following open reduction using 'stainless steel lag screws and mini plates'. *J Maxillofac Oral Surg.* 2013;12:133-9.
- Marchetti C, Bianchi A, Bassi M, Gori R, Lamberti C, Sarti A. Mathematical modeling and numerical simulation in maxillofacial virtual surgery. *J Craniofac Surg.* 2007;18:826-32.
- Pickering RS, Hattery RR, Hartman GW, Holley KE. Computed tomography of the excised kidney. *Radiology.* 1974;113:643-7.
- Schug T, Rodemer H, Neupert W, Dumbach J. Treatment of complex mandibular fractures using titanium mesh. *J Craniofac Surg.* 2000;28:235-7.
- Kuttenberger JJ, Hardt N. Long-term results following reconstruction of craniofacial defects with titanium micro-mesh systems. *J Cranio Maxillofac Surg.* 2001;29:75-81.
- Kaur N, Kaur T, Kaur J, Kaur Y, Kapila S, Sandhu A. Efficacy of Titanium Mesh Osteosynthesis in Maxillofacial Fractures. *J Maxillofac Oral Surg.* 2018;17:417-24.
- Novelli G, Tonellini G, Mazzoleni F, Bozzetti A, Sozzi D. Virtual surgery simulation in orbital wall reconstruction: integration of surgical navigation and stereolithographic models. *J Craniofac Surg.* 2014;42:2025-34.
- Sadhvani BS, Anchlia S. Conventional 2.0 mm miniplates versus 3-D plates in mandibular fractures. *Ann Maxillofac Surg.* 2013;3:154-9.
- Patel MF, Langdon JD. Titanium mesh (TiMesh) osteosynthesis: a fast and adaptable method of semi-rigid fixatio. *Br J Oral Maxillofac Surg.* 1991;29:316-24.
- Mittal G, Dubbudu R, Cariappa K. Three dimensional titanium mini plates in oral & maxillofacial surgery: A prospective clinical trial. *J Maxillofac Oral Surg.* 2011;11:152-9.
- Goyal M, Marya K, Chawla S, Pandey R. Mandibular osteosynthesis: A comparative evaluation of two different fixation systems using 2.0 mm titanium miniplates and 3-D locking plates. *J Maxillofac Oral Surg.* 2011;10:32-37.
- Cobetto GA, McClary SA, Zallen RD. Treatment of mandibular fractures with malleable titanium mesh plates: a review of 120 cases. *J Oral Maxillofac Surg.* 1983;41:597-600.
- Chhabaria G, Halli R, Chandan S, Joshi S, Setiya S, Shah A. Evaluation of 2.0-mm titanium three-dimensional curved angle strut plate in the fixation of mandibular angle fractures – A prospective clinical and radiological analysis. *Craniofac Trauma Reconstr.* 2014;7:119-25.
- Guimond C, Johnson JV, Marchena JM. Fixation of mandibular angle fractures with a 2.0-mm 3-dimensional curved angle strut plate. *J Oral Maxillofac Surg.* 2005;63:209-14.
- Singh R, Pal U, Singh P, Singh G. Role of fixation in posttraumatic nerve injury recovery in displaced mandibular angle fracture. *Natl J Maxillofac Surg.* 2016;7:29-32.
- Shridharani SM, Berli J, Manson PN, Tufaro AP, Rodriguez ED. The role of postoperative antibiotics in mandible fractures: A systematic review of the literature. *Ann Plast Surg.* 2015;75:353-7.
- Pattar P, Shetty S, Degala S. A prospective study on management of mandibular angle fracture. *J Maxillofac Oral Surg.* 2014;13:592-8.
- Doblar M, Garcia JM. Modelling bone tissue fracture and healing. *Omez Engine Frac Mech* 2004;71:1809-10.
- Schulze D, Heiland M, Thurmman H, Adam G. Radiation exposure during midfacial imaging using 4-and 16-slice computed tomography, cone beam computed tomography systems and conventional radiography. *Dentomaxillofac Radiol.* 2004;33:83-6.
- Ma J, Ma L, Wang Z, Zhu X, Wang W. The use of 3D-printed titanium mesh tray in treating complex comminuted mandibular fractures. *Medicine (Baltimore).* 2017;96:e7250.
- Schreiber JJ, Anderson PA, Rosas HG, Buchholz AL, Au AG. Hounsfield units for assessing bone mineral density and strength: a tool for osteoporosis management. *JBSJ.* 2011;93:1057-63.
- Hopper KD, Wang MP, Kunselman AR. The use of clinical CT for baseline bone density assessment. *J Comput Assist Tomogr.* 2000;24:896-9.