

Early Fixation in the Management of Cervical Spine Injuries

HESHAM A. ABU EISHA, M.D.*; IBRAHIM M. IBRAHIM, M.D.**;
HESHAM M. ABD EL-SAMAD, M.D.* and MOHAMED S. ABDEL AZIZ, M.D.***

The Departments of General Surgery and Neurosurgery**, Faculty of Medicine, Cairo University and
The Department of Neurosurgery, Faculty of Medicine, Beni-Suef University****

Abstract

Background: Cervical spine injury is considered one of the most dangerous injuries. Clinical presentation ranges from neck pain, radiculopathy to cord injury whether partial or complete. Management includes initial resuscitation together with immobilization. The decision of surgery is directed to maintenance of vertebral column stability and neurological function, based on the radiological investigation and the patient's clinical condition.

Aim of Study: To evaluate the role of lateral mass fixation and best indications in patients with lower cervical spine injury.

Patients and Method: Retrospective study of twenty cases of cervical spine injuries. Patients were admitted and operated upon in the Neurosurgical Departments in Cairo University Hospitals.

Results: Lateral mass fixation is best indicated in cases of subluxation, locked facet as well as cases with straightened curve.

Conclusion: Regarding lateral mass fixation, there seems a general agreement that the screw trajectory should be at least 10 degrees laterally and oriented no more rostral the articular surface of the facet joint to minimize the risk of inadvertent injury to the nerve root or vertebral artery.

Key Words: *Cervical vertebra – Cervical spine injuries – Lateral mass fixation.*

Introduction

ANATOMICALLY, the cervical spine consists of seven cervical vertebrae aligned with a prominent cervical lordosis. The 3rd, 4th, 5th and 6th cervical vertebrae are typical while the 1st, 2nd and 7th vertebrae present special features [1].

The vast majority of traumatic vertebral column injuries involve the cervical spinal segment. The level and extent of vertebral column injury will

determine the likelihood of underlying neurological deficit [2].

The most important factor associated with the genesis of significant cervical spine injury is concomitant occurrence of serious head or trunk injury

Optimal, treatment of patients with cervical spine injuries relies on an accurate radiological assessment of the traumatic lesions. Both with respect to existing abnormalities and the underlying mechanism of injury. Failure to recognize a cervical fracture may results in the subsequent development of severe neurological sequelae [3].

General management principles of acute cervical spinal column injury include, rigid immobilization, aggressive treatment of hypoxia and shock when present, early reduction of vertebral column fracture dislocation and spinal cord decompression

To evaluate the role of lateral mass fixation and best indications in those patients.

Patients and Methods

Retrospective study of fifteen to twenty cases of cervical spine injuries. Patients were admitted and operated upon in the Neurosurgical Departments in Cairo University Hospitals from December 2009 to December 2010.

Lateral mass fixation will be discussed as will as patients' best indicated for it.

Inclusion criteria: Cervical trauma, cervical spondylosis at three or more motion segments, the patients must have a straight or lordotic cervical spine, and clinical findings consistent with myelopathy.

Correspondence to: Dr. Mohamed S. Abdel Aziz,
[E-Mail: saad1652@gmail.com](mailto:saad1652@gmail.com)

Exclusion criteria: Patients who underwent anterior cervical decompression, those who experienced neurological deterioration after trauma, contraindication to general anesthesia, ossification of posterior longitudinal ligament, osteoporosis and kyphotic angulations of cervical curve.

Evaluation:

Pre-operatively: All patients were evaluated by a member of senior and junior staff & subjected to:

- **Clinical history:** With stress on age, sex, job and history of systemic illness such as DM, Vasculopathy, Atherosclerosis, etc.
- **Clinical examination:** Complete general and neurological examination, it should include the following:
 - **Motor system examination:** With a special attention to muscle tone, wasting, motor power, cloni, jerks, abdominal and planter response. Strength in individual muscle groups was graded using the British Medical Research Council 0 to 5 strength scale.

Table (1): The Medical Research Council (MRC) grading system for muscle strength.

Grade	Finding
Grade 0	• No voluntary muscle contraction.
Grade 1	• Flicker or trace of muscle contraction, no joint motion.
Grade 2	• Active movement but only with gravity eliminated.
Grade 3	• Active movement against gravity, but not against resistance.
Grade 4-	• Active movement against minimal resistance.
Grade 4	• Active movement against moderate resistance.
Grade 5	• Normal strength.

- **Sensory system examination:** With a special attention to sensory level, radicular hypothesia or hyperthesia and deep sensation.
- **Local examination:** Important to assess range of neck movement and muscle spasm.
- **Investigations:**
 - **Routine laboratory investigation:** CBC, random blood sugar, PT, PC, clotting time liver and kidney function.
 - **Radiological assessment:**
 - Plain X-ray (lateral, anterior, posterior, right and left oblique views flexion extension study.
 - CT cervical spine.
 - MRI using T1 & T2 images, axial cuts as well as sagittal plane.

Operative technique:

The procedure was done under general anesthesia with the patient placed prone in a three-pin head holder position.

- **The incision:** The incision is centered over the affected level and a linear midline skin incision at the affected level.
- **Exposure of the interspace:** The musculature was dissected from the midline laterally, and self-retaining retractors were placed to expose the facet joint. The level of the exposure can usually be established correctly by intraoperative lateral radiograph to confirm the level. After exposure of the posterior elements, an awel was used to make a shallow holes 1-mm medially and above center of lateral mass then the drill was used to drill a hole 1cm deep in the lateral masses bilaterally with the technique described by Magerl with 20 degree to 25 degree lateral and cranial angulations parallel to the joint line to avoid injury to the vertebral artery and spinal nerve root. Axis bone plates of appropriate size were selected and bent to match the contour of the lateral masses. The bone plates were then secured to the lateral masses by use of 14-mm-long screws, 3.5mm in diameter, and laminectomy was done by the same technique described before and the wound was closed in standard fashion. A cervical collar was used for patient comfort for 2 to 8 weeks.
- **Post-operative follow-up:**
 - **Clinical follow-up:** Post-operatively, grade of motor power was evaluated immediately after operation and every six months. The final outcome was determined after at least 24 months.
 - **Radiological follow-up:** Radiological follow-up plain X-rays were done to check screw position or any developing kypus within 72 hours post-operatively then every 6 months.

Results

The data collected from the 20 cases, that were operated upon during the study were analyzed, and the results were concluded, compared and evaluated.

Sex:

The study included 12 males and 8 females.

Table (2): Showing sex distribution.

Total No.	Male	Female	M/F ratio
20	12 (60%)	8 (40%)	1.5:1

Symptoms:

Heaviness in the upper limbs was the commonest presenting symptom occurring in patients (80%) followed by neck pain and brachialgia occurring in 70% and 60% of patients, respectively.

Table (3): Showing the presenting symptoms.

Symptoms	No.	Percentage
Brachialgia	12	60.0%
Neck pain	14	70%
Numbness	10	50%
Heaviness in U.L	16	80%
Heaviness in L.L	5	25%
Sphincters	5	25%

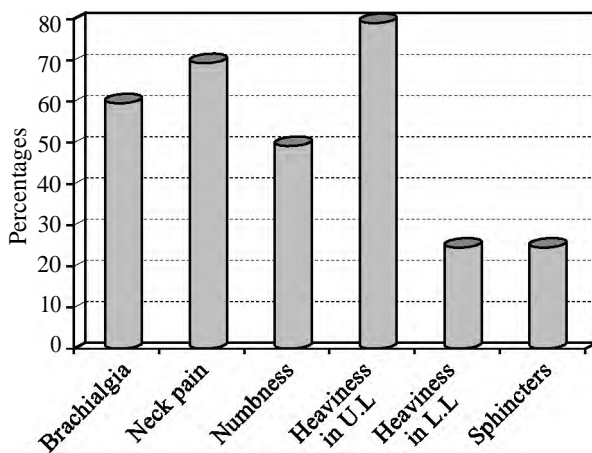


Fig. (1): Showing the presenting symptoms.

Signs:

Motor deficit involving the upper limbs in 75% of examined patients and in both upper and lower limbs in 25% of cases.

Table (4): Showing the clinical signs.

Signs	No.	Percentage
UL weakness	15	75%
UL & LL weakness	4	20%
Hypothesia	20	100%
Hyperreflexia	20	100%
Babnski sign	8	40%

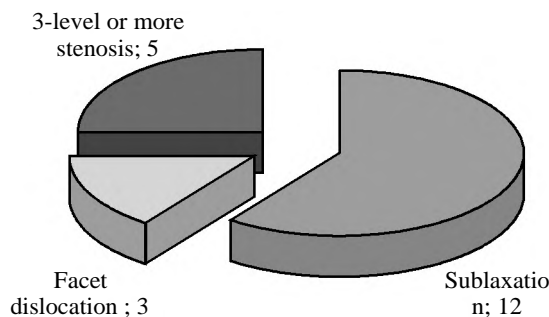


Fig. (2): Showing the radiological findings.

Table (5): Showing the radiological findings.

MRI	Cases
Subluxation	12
Facet dislocation	3
Three level or more stenosis	5

Table (6): Complications.

Complication	Cases
Wound CSF leakage	0
Wound infection	3
Nerve root injury	0
Vertebral artery injury	0
Screw break dawn	0

Table (7): Showing the operative procedures.

Total No.	Laminectomy & fixation
20	20

Table (8): Showing symptoms post-operatively.

Symptoms	Improved	Worsened	No change
Neck pain (14)	12	—	2
Brachialgia (12)	12	—	—
Numbness (10)	9	—	1
Gait (5)	3	—	2
Sphinteric (5)	2	—	3

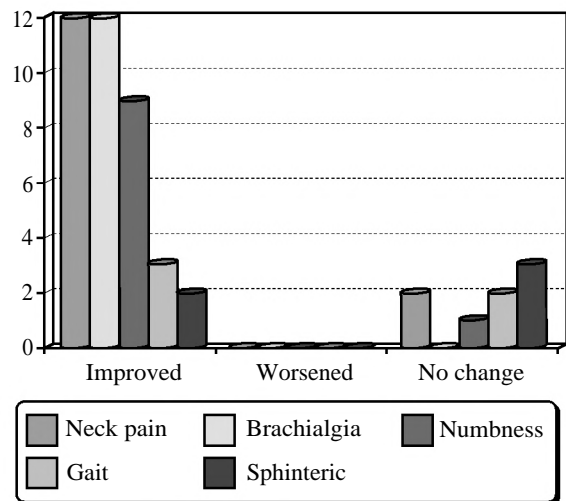


Fig. (3): Showing symptoms post-operatively.

Discussion

In our study, we are aiming to discuss lateral mass fixation, as well as patients' best indicated for it, in both trauma and degenerative cases. Also the early lines of treatment in the field and in the hospital of the cervical trauma patient are discussed, for early evaluation and proper management.

In this study twenty patients are operated upon out of them five are degenerative patients and

fifteen are traumatic cases. All of the cases are operated upon by laminectomy and lateral mass fixation. The post-operative complications in our study occurred in three patients in the form of wound infection, and treated with antibiotics.

In a case series of Barry D Brich et al., [5] for posterior cervical stabilization using lateral mass screw-rod fixation. A total of 212 screws were implanted in 21 patients. When compared with plating techniques, screw-rod fixation appeared to offer several advantages. First, unlike plates, rods proved to be amenable to multiplanar contouring, which is often needed for deformities associated with cervical spondylosis. Second, lateral mass screw placement was more precise because it was not constrained by the hole spacing of the plate. Third, screw back-out and other types of implant failure were not seen. Fourth, the screw-rod system was more easily extended to the occiput and across the cervicothoracic junction. Fifth, the screw-rod system permitted the application of compression, distraction and reduction forces within the construct, to a greater extent than plate systems. The incidence of post-operative radiculopathy was similar to that seen with plate systems.

In a case series of Lali H.S & Sekhon [6] to evaluate the results and complications of 1026 consecutive lateral mass screws inserted in 143 patients by a single surgeon.

All screws were placed by a modification of the Anderson technique, but 20 screws were converted to Roy-Camille trajectories because of screw pullout. No patients experienced neural injury or vertebral artery injury as a result of screw placement. Three patients had screw pullouts using the axis system, which did not require reoperation. Most patients had 14-mm screws placed.

Post-operative CT scanning showed no compromise of the foramen transversarium or neural foramen. A total of 94 C7 lateral mass screws were placed without the need for pedicle screws at this level. Forty-four cases were performed with a screw/plate construct with the remainder performed using a polyaxial screw/rod construct. One patient had a symptomatic adjacent-level disc herniation that required surgical intervention. One patient required extension of laminectomy for residual compression.

Conclusion:

Regarding lateral mass fixation, there seems a general agreement that the screw trajectory should be at least 10 degrees laterally and oriented no more rostral the articular surface of the facet joint to minimize the risk of inadvertent injury to the nerve root or vertebral artery. Lateral mass fixation is best indicated in cases of subluxation, locked facet as well as cases with straightened curve.

References

- 1- COOPER H.M. and YEAGER V.L.: Surgical anatomy of the cervical spine and surrounding structures, in microsurgery of the cervical spine. Chapter (1): 1-16, 2001.
- 2- HADLEY M.N. and ARGIERI P.J.: The acute/emergent management of vertebral column fracture/dislocation injuries. Park Ridge, IL: American Association of neurosurgical Surgeon, 2005.
- 3- STILLERMAN C.B., ROY R.S., and WEISS M.H.: Cervical spine injuries. Diagnosis and management in neurosurgery Wilkins RH, Rengchary SS, 285: 2875-904, 2005.
- 4- SONNTAG V.K.H., DICKMAN C.A., PAPADOPOULOS S.M. and HADLEY M.N.: The interspinous method of method of posterior atlantoaxial arthodesis. J. Neurosurgery, 74: 190-189, 2003.
- 5- BARRY D. BRICH and H. GORDON DEEN: The Spine Journal Volume (3), Issue (6) November 2003.
- 6- LALI H.S. and SEKHON: Spine Disord. Tech., 2005.

التثبيت المبكر في علاج إصابات الفقرات العنقية

تتكون الفقرات العنقية من سبع فقرات والتي تتميز بوجود فتحة (ثقب) في النتوء المستعرض ما عدا الفقرة السابعة لا يوجد بها. وتتميز الفقرات الثالثة والرابعة والخامسة والسادسة بتمائلها في الصفات بينما تتميز الفقرات الأولى والثانية والسابعة بصفات مميزة لكل منها وتعتبر إصابات الفقرات من أخطر الإصابات ومن أهم أسبابها حوادث الطريق وتمثل إصابات الفقرات العنقية من ٢٨ إلى ٥٠ حالة لكل مليون مواطن في الولايات المتحدة في العام الواحد. ومن أهم أعراضها هي الألم العنقية وشلل في الأطراف أو إحتباس في البول بالإضافة إلى كسور الفقرات وفي حالة الشك بوجود هذه الإصابات لابد من عدم تحريك المريض إلا بعد إرتدائه رقبة صلبة ووضع المريض على اللوحة الصلبة ولابد من عمل الإشعاعات الأولية للمريض وعلاج الصدمة إن وجدت ثم يتم نقل المريض إلى عمل الإشعاعات والفحوصات الطبية. ومن الفحوصات الطبية التي يتم عملها هي الإشعاعات العادية والإشعاعات المقطعية والرنين والمغناطيسي والفحوصات الطبية الأخرى على حسب حالة المريض وبعد عمل الإشعاعات والفحوصات الطبية يتم تحويل المريض إلى العمليات لعمل العملية الجراحية على حسب نوع الإصابة.

وهذا البحث يتضمن عشرين حالة وفي جميع الحالات تم عمل تثبيت للكتلة الجانبية.

ومن أهم نتائج البحث هي إن هذا النوع من التثبيت (تثبيت الكتلة الجانبية للفقرات العنقية) هي أفضل في حالات خلع في مفصل الفقرة أو تزحزح في الفقرات، وفي الحالات المرضية التي تكون فيها الفقرات العنقية مستقيمة (تفقد إنحنائها العنقي).