

## Possible Ameliorating Effect of Curcumin on the Pancreas of Experimentally Induced Hypothyroidism in Rat: Histological, Immunohistochemical and Biochemical Study

MOGEDA M. NASRALLA, M.D.\* and MOHAMED F. EL SHAFIE, M.D.\*\*

*The Department of Anatomy & Embryology, Faculty of Medicine, Cairo University\* and  
The Department of Pharmacology & Toxicology, Faculty of Pharmacy, Al-Azhar University\*\**

### Abstract

**Background:** Hypothyroidism is reported as the most common thyroid disease in humans which is caused by thyroid hormones deficiency.

**Aim of Study:** To evaluate the role of curcumin in prevention of the possible histopathological, immunohistochemical, and biochemical changes on the pancreas of experimentally induced hypothyroidism in adult male rat.

**Material and Methods:** Forty adult male albino rats weighing (150-200gm) were allotted in four groups, ten animals each. Group I (control group) received no medication, Group II (curcumin group) were given curcumin 100mg/kg/b.w orally by gastric gavage for 6 weeks Group III: (Hypothyroid group) was rendered hypothyroid by administration of propylthiouracil (PTU) (Thyrocil) 15mg/kg b.w orally by gavage for 6 weeks. Group IV (hypothyroid and curcumin treated group) received the same dose of PTU for 6 weeks with the addition of curcumin starting 2 weeks after PTU administration (after confirmation of the hypothyroidism state) to the sixth week. The pancreas was dissected out and subjected to histological and immunohistochemical study.

**Results:** The pancreas of hypothyroid rats showed histological changes in the form of pale small size islets. Inside the islets the cells appeared vacuolated with pyknosis of their nuclei. Immunohistochemical study showing a decreased number of insulin-immunoreactivity. Biochemical results revealed a significant decreased pancreatic tissue Superoxide dismutase, reduced glutathione, Catalase, Glutathione-S-transferase and Glutathione peroxidase as well as increased pancreatic tissue Malondialdehyde compared with those of controls. Hypothyroid and curcumin group revealed an improvement in these histological, immunohistochemical and biochemical changes.

**Conclusion:** Data so far obtained indicated that Curcumin has antioxidant effect that could possibly account for its potential in the current study to ameliorate all the histological, immunohistochemical and biochemical parameters altered by hypothyroidism.

**Key Words:** Antioxidants – Histology – Immunohistochemistry – Propylthiouracil – Pancreas biochemical curcumin.

### Introduction

**THYROID** gland hormones have a major role in metabolism, growth and development throughout life [1]. A hyperactivity of thyroid gland (hyperthyroidism) occurs if the thyroid gland make more hormones. A hypoactivity of thyroid gland (hypothyroidism) is where the gland doesn't make enough hormones [2]. In the liver and skeletal muscle, glycolysis, gluconeogenesis and glycogenolysis are stimulated by thyroid hormones [3]. Thyroid dysfunction have been accompanied by disturbance of glucose metabolism, which might lead to alteration in insulin secretion [4,5]. Also, thyroid hormones are necessary for the postnatal maturation of functional  $\beta$ -cells [6,7]. Crunkhorn & Patti, 2008 [8] reported that insulin secretion is regulated by thyroid hormones and the imbalance of these hormone levels increase the risk of diabetes. Several researches reported that hyperthyroidism increase insulin level in the plasma in human and animals [9]. Oxidative cellular damage and oxidative stress with free radicals generation are hallmarks of thyroid dysfunction [10].

The medical uses of natural herbs are gradually increasing due to their anti-oxidant, anti-inflammatory, anti-bacterial and anti-cancer properties [11]. The yellow pigment curcumin is one of natural polyphenols which is extracted from turmeric [12]. In several studies curcumin was used as hypolipidemic, anti-infectious, anticancer [13], anti-inflammatory due to antioxidant properties [14]. Also, Pandya et, (2000) [15] reported that the antioxidant effect of curcumin was several times

**Correspondence to:** Dr. Mogada M. Nasralla,  
[E-Mail: mogedam@yahoo.com](mailto:mogedam@yahoo.com)

more potent than vitamin E. In addition Somanawat et al. (2013) [16] revealed that it is pharmacologically safe for humans and animals with extremely good tolerance.

The aim of the present work was conducted to study the histopathological, immunohistochemical, and biochemical changes caused by experimentally induced hypothyroidism in the pancreas of adult rats and assess the ameliorating effect of curcumin.

## Material and Methods

### Drugs:

1- *Propylthiouracil (Thyrocil)*: Which obtained from Amoun Pharmaceutical Company, Cairo, Egypt, in the form of tablets, each containing 50mg. The required daily dose (for the 10 rats of the group) was weighted, dissolved in 5ml distilled water. A dose of 15mg/kg b.w was given orally through gastric gavage [17].

2- *Curcumin*: Which obtained from Sigma-Aldrich chemical company (Cairo, Egypt). The bottle containing 10gm of yellow powder, (Catalogue number C1386). The required daily dose (for the 10 rats of the group) was weighted, suspended in 5ml corn oil. A dose of 100mg/Kg/b.w was given orally through gastric gavage [18].

### Animals:

A total of forty adult male albino rats weighing (150-200) gm were conducted in this study. The rats were obtained from the Animal House Faculty of Medicine, Cairo University, during 2018. The animals were maintained in spacious wire mesh cages, each contained four rats with direct day light and natural ventilation at room temperature and allowed water and food ad libitum. All the animals were treated accordance to the Institutional guidelines for the care and use of laboratory animals.

*The animals were allotted in four groups ten animals each. Treatment regimens were assigned as such:*

- *Group I:* (Control group) received no medications.
- *Group II:* (Curcumin group) were given curcumin orally through gastric gavage at a dose of 100 mg/kg/bw, for 6 weeks.
- *Group III:* (Hypothyroid group) was rendered hypothyroid by administration of propylthiouracil (Thyrocil) 15mg/kg b.w orally by gavage for 6 weeks.
- *Group IV:* (Hypothyroid and curcumin treated group) received the same dose of PTU for 6

weeks with the addition of curcumin starting 2 weeks after PTU administration (after confirmation of the hypothyroidism state) to the sixth week.

At the end of experiment, under an over dose of anesthesia by intraperitoneal injection of phenobarbital sodium (40mg/kg), retro-orbital blood samples were withdrawn from rats of each group for biochemical evaluation. Thereafter, animals were euthanized by cervical dislocation. The clear sera were separated after centrifugation and kept at  $-30^{\circ}\text{C}$  until use. The pancreas was dissected out, washed in saline. Fresh specimens were taken for histochemical investigations to measure the oxidative tissue marker in tissue homogenate. The other part was fixed in 10% buffered formol saline, prepared for paraffin blocks. Using microtome, serial sections of 5  $\mu\text{m}$  thick were obtained from each block and spread on clean slides. Sections for immunohistochemical study were mounted on charged slides to avoid falling down during immunostaining. The sections were subjected to:

### Histological study:

Hematoxylin and Eosin stain (H & E) [19].

### Immunohistochemical study:

*Primary antibody:* Insulin Ab-6 (INS04 + INS05): It is a mouse monoclonal antibody (Lab Vision Corporation laboratories, CA 94539, USA, catalogue number MS-1379-P). It was supplied as 1.0ml of antibody (200ug/ml) purified from ascites fluid by protein G chromatography, prepared in 10mM PBS, pH 7.4, with 0.2% BSA and 0.09% sodium azide. It was stored at  $2-8^{\circ}\text{C}$ . No special pretreatment was required for immuno-histochemical staining of formalin-fixed tissues.

*Detection system for antibody:* UltraVision Detection System Anti-Polyvalent, HRP/AEC kit (LAB-SA system, Lab Vision Corporation laboratories, CA 94539, USA, catalogue number TP-015-HA). It is a detection system that reacts with mouse and rabbit primary antibody. This kit includes Hydrogen Peroxide Block, Ultra V Block, Biotinylated Goat Anti-Polyvalent, a horseradish peroxidase streptavidin and AEC Substrate and AEC Chromogen to demonstrate antigen in cells and tissues [20].

### Histomorphometric study:

Data were obtained using "Leica Qwin 500C" image analyzer computer system Ltd. (Cambridge, England). Area percent was measured for immune reaction to anti-insulin in all pancreatic sections immunostained with anti-insulin using an objective

lens X 10 i.e. a total magnification X 100 in 10 non overlapping fields in each section, inside a standard measuring frame of area (118476.6  $\mu\text{m}^2$ ). The total and mean values were obtained.

#### Biochemical study:

- 1- Level of blood glucose: O-toluidine method was done using the modified reagent [21].
- 2- The following tests were used to assess the thyroid functions: Free triiodothyronine (T3). Free thyroxine (T4) and Thyroxin stimulating hormone (TSH).
- 3- Measurement of pancreatic oxidative tissue markers:

- *Superoxide dismutase (SOD)*: Prior to dissection, tissues were perfused with a PBS (phosphate buffered saline) solution, pH 7.4. containing 0.16mg/ml heparin to remove any red blood cells and clots. The tissues were homogenized in 10ml cold buffer (i, e, 50mM potassium phosphate, pH 7.5, 1mM EDTA) per gram tissue. Then centrifuged at 10,000 x g for 15 minutes at 4°C. The supernatant was removed for assay and store on ice [22].

- *Glutathione peroxidase (GPx)*: The tissues were homogenized in buffer containing a freshly added reducing agent to maintain GPx enzyme activity. For homogenization buffers 2 – mercaptoethanol or dithiothreitol were added at a final concentration of 1mM. Buffers were freshly made and used the same day. There is abundant c-GPx in erythrocytes. Red blood cells were washed from tissue samples by perfusion with isotonic saline prior to homogenization [23].

- *Malondialdehyde (MDA)*: The tissue homogenate was perfused with a PBS (phosphate buffered saline) solution, pH 7.4 containing 0.16mg/ml heparin to remove any red blood cells and clots. The tissues were homogenized in 5-10ml cold buffer (ie 50mM potassium phosphate, pH 7.5.) per gram tissue. Samples were centrifuge at 4000r.p.m for 15 minutes. The supernatants were removed for assay and store on ice. In case of not doing the assay on the same day, freeze the sample at -80°C [24].

- *Reduced glutathione (GSH)*: 10% (w/v) homogenate prepared by added 5% trichloroacetic acid solution. Centrifugation at 3500rpm for 10min was done, 50 $\mu\text{L}$  supernatant was mixed with 0.32mol/L disodium hydrogen phosphate and 0.04% 5, 5-dithiobis 2-nitrobenzoic acid (DTNB) solution. The yellow-colored substance formed by the reaction of GSH and DTNB was measured at 412nm. The results were expressed as GSH mg/g tissue weight [25].

- *Catalase (CAT)*: In a 3ml quartz cuvette, 100  $\mu\text{L}$  of tissue homogenate (10%) were added to 2.9ml of 19mmol/L H<sub>2</sub>O<sub>2</sub> solution prepared in potassium phosphate buffer (0.1M, pH 7.4). The reaction was monitored by continuous recording of the change in the absorbance at 240nm everymin for 2min using Shimadzu spectrophotometer (UV 1201, Japan). Enzyme activity was expressed as unit per g tissue [26].

- *Glutathione-S-transferase (GST)*: It was measured as reported by Habig et al., 1974 [27].

#### Statistical analysis:

Quantitative data were summarized as means and standard error and compared using one-way analysis-of-variance (ANOVA). Any significant ANOVA was followed by Tukey-Kramer post ANOVA to detect which pairs of groups caused the significant difference. *p*-values <0.05 were considered statistically significant. Calculations were made on SPSS software version 21.

## Results

#### Histological results:

##### Hematoxylin and eosin (Hx & E) stain:

Control group (group I) and Curcumin group (group II) showed normal appearance of acini and well-defined islets containing  $\beta$ -cells and blood capillaries. The islet revealed acidophilic large cells and basophilic small cells Fig. (1A, B). Regarding the hypothyroid group (group III) the sections stained with (Hx & E) revealed small size islets and its cells appeared vacuolated with pyknosis of their nuclei. Some islet cells have dark nuclei while others have pale nuclei with acidophilic cytoplasm Fig. (1C). Section of the pancreas of group IV demonstrated large islets with small vacuolated areas some islet cells appeared with dark nuclei while others showed pale nuclei with acidophilic cytoplasm Fig. (1D).

##### Immunohistochemical staining:

Immunohistochemical staining sections of control and curcumin groups showed +ve insulin immunorexpression among most of the islet cells which appeared as dense brownish cytoplasmic immunoreactivity Fig. (2A,B). On the other hand sections in the pancreas of rats of hypothyroid group, demonstrated shrunken islets with minimal +ve insulin immunorexpression Fig. (2C). Regarding the group IV (PTU and Curcumin group) revealed increased immunoreactivity in the most of the islet Fig. (2D).

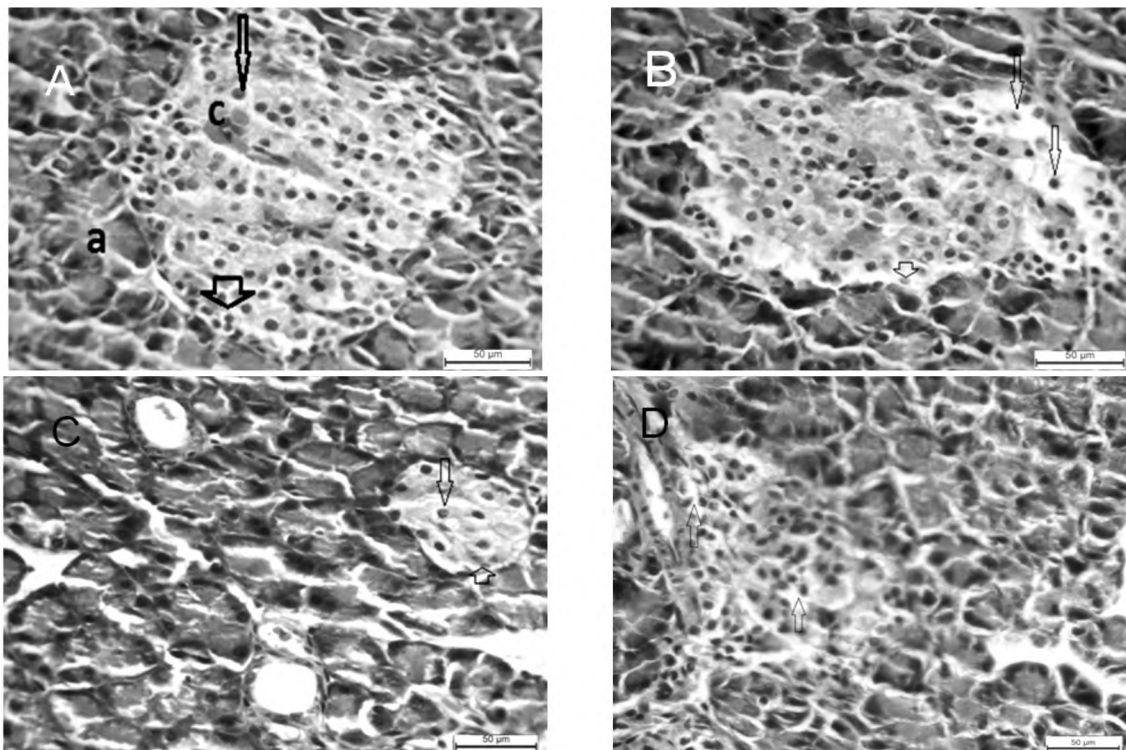


Fig. (1): Photomicrographs of rat's pancreatic section (H & E X400) showing: A) Control group: A large islet rich in capillaries (c) surrounded by well defined acini (a). Acidophilic large cells (arrowhead) and basophilic small cells (arrow) appeared inside the islet. B) Curcumin group showing deeply stained islet with capillaries (c) between islet cells. Some islet cells have dark nuclei (arrow) while others have paler nuclei with acidophilic cytoplasm (arrowhead). C) Hypothyroid group showing shrunken islets with vacuolation and degeneration in the cytoplasm of many cells of an islet of Langerhans (arrow). D) PTU and curcumin group showing large size islets with vacuolation in the cytoplasm of some cells of an islet of Langerhans (arrow).

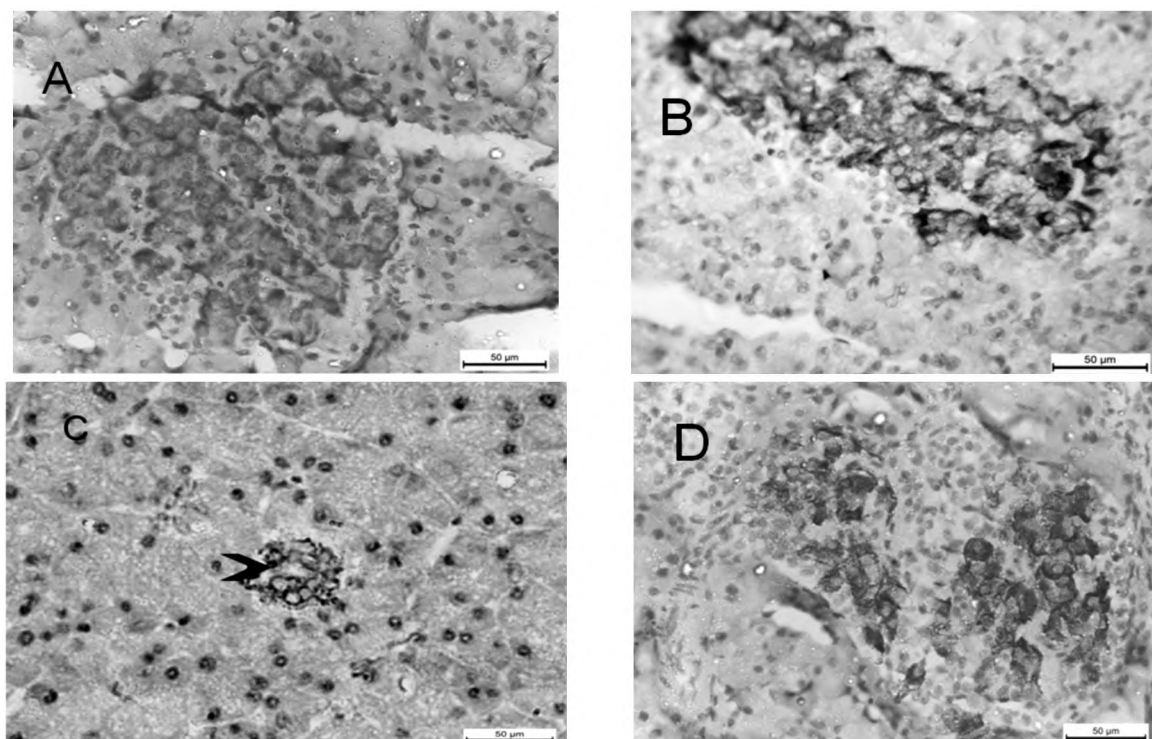


Fig. (2): Photomicrographs of rat's pancreatic section (anti-insulin immunostaining X400) showing: A) Control group showing dense brownish cytoplasmic immunoreactivity in most of islet cells. B) Curcumin group showing dense brownish cytoplasmic immunoreactivity in the islet of Langerhans. C) Hypothyroid group showing marked decreased immunoreactivity in the shrunken islet of Langerhans. D) PTU and curcumin treated group showing increased cytoplasmic immunoreactivity in one islet of Langerhans.

**Histomorphometric results:** Measuring the mean area percent of anti insulin immune-histochemical staining sections showed a significant decrease in group III compared to other groups. Group IV revealed a significant increase in the mean area percent of anti insulin compared to group III and showed a significant decrease as compared to control group Fig. (3).

**Biochemical results:**

**1- Blood glucose level:** The hypothyroid group showed significantly increased blood glucose level, as compared with the controls. On the other hand, group IV (PTU and curcumin group) revealed significantly decreased blood glucose level as compared with hypothyroid group Fig. (4A) & (Table 1).

**2- Serum total T3, T4, and TSH levels:** In hypothyroid rats (group III) T3 and T4 levels were significantly decreased and there was a significant elevation in TSH levels, compared with control levels. Treatment with curcumin along with PTU (group IV) significantly increased T3 and T4 levels as well as significantly decreased TSH levels compared to those of the group receiving PTU alone Fig. (4B-D) & (Table 1).

**3- Oxidative tissue markers:** In hypothyroid group the oxidative tissue markers showed a significant decreased pancreatic tissue Superoxide dismutase, reduced glutathione, Catalase, Glutathione-S-transferase and Glutathione peroxidase as well as increased pancreatic tissue Malondi-

aldehyde compared with those of controls. In the PTU + curcumin group (group IV), there was a significant decrease in pancreatic tissue Malondialdehyde as well as a significant increase in pancreatic tissue Superoxide dismutase, reduced glutathione, Catalase, Glutathione-s-transferase and Glutathione peroxidase compared with the PTU treated group. On the other hand group IV showed a significant decrease in pancreatic tissue Superoxide dismutase and Catalase as well as a significant increase in Malondialdehyde levels compared to the control Fig. (5A-F) & (Table 2).

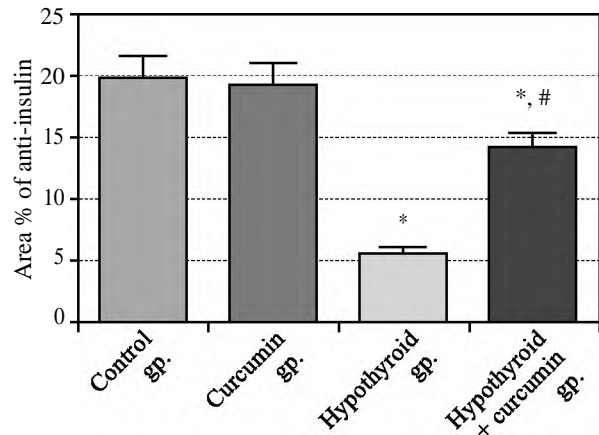


Fig. (3): Effect of Curcumin and/or Hypothyroidism on area% of anti-insulin stained sections of male Sprague dawley rats.

Values are expressed as mean ± SE, n=10.  
 \*: Significantly difference from control at  $p<0.05$ .  
 #: Significantly difference from Hypothyroid group at  $p<0.05$ .  
 ANOVA followed by Tukey-Kramer post ANOVA.

Table (1): Serum levels of Glucose, T3, T4 and TSH in different groups.

Treatment	Parameters			
	Glucose (mg/dL)	T3 (ng/ml)	T4 (µg/dL)	TSH (IU/ml)
Group I (Control)	83.64±5.42	73.85±6.41	4.81±0.45	1.53±0.12
Group II (Curcumin)	79.75±5.13	69.75±5.32	4.29±0.42	1.38±0.13
Group III (Hypothyroid)	190.22±10.55*	20.50±1.48*	1.30±0.12*	12.86±0.93*
Group IV (Hypothyroid + Curcumine)	96.55±6.42#	56.50±4.46#	3.91±0.33#	2.66±0.21 #

Values represented as mean ± SE, n=10.  
 \*: Statistically significant different from control at  $p<0.05$ .  
 #: Statistically significant different from Hypothyroid group at  $p<0.05$ .  
 ANOVA followed by Tukey-Kramer post ANOVA.

Table (2): Oxidative tissue markers in different groups.

Treatment	Parameters					
	GSH (µmol/g)	MDA (nmol/g)	SOD (U/g)	CAT (U/g)	GPx (U/g)	GST (ng/g)
Group I (Control)	11.56±1.07	25.80±2.28	15.32±1.13	82.17±6.64	4.12±0.32	0.74±0.04
Group II (Curcumin)	12.09±1.13	23.50±2.19	14.85±1.11	73.29±6.22	3.97±0.22	0.73±0.05
Group III (Hypothyroid)	6.72±0.45 *	75.31±5.78*	6.83±0.53 *	43.70±3.59*	2.18±0.17*	0.32±0.02*
Group IV (Hypothyroid + Curcumine)	10.22±0.88#	36.54±3.45*#	11.71±1.09*#	67.16±4.77*#	3.32±0.21#	0.68±0.06#

Values represented as mean ± SE, n=10.  
 \*: Statistically significant different from control at  $p<0.05$ .  
 #: Statistically significant different from Hypothyroid group at  $p<0.05$ .

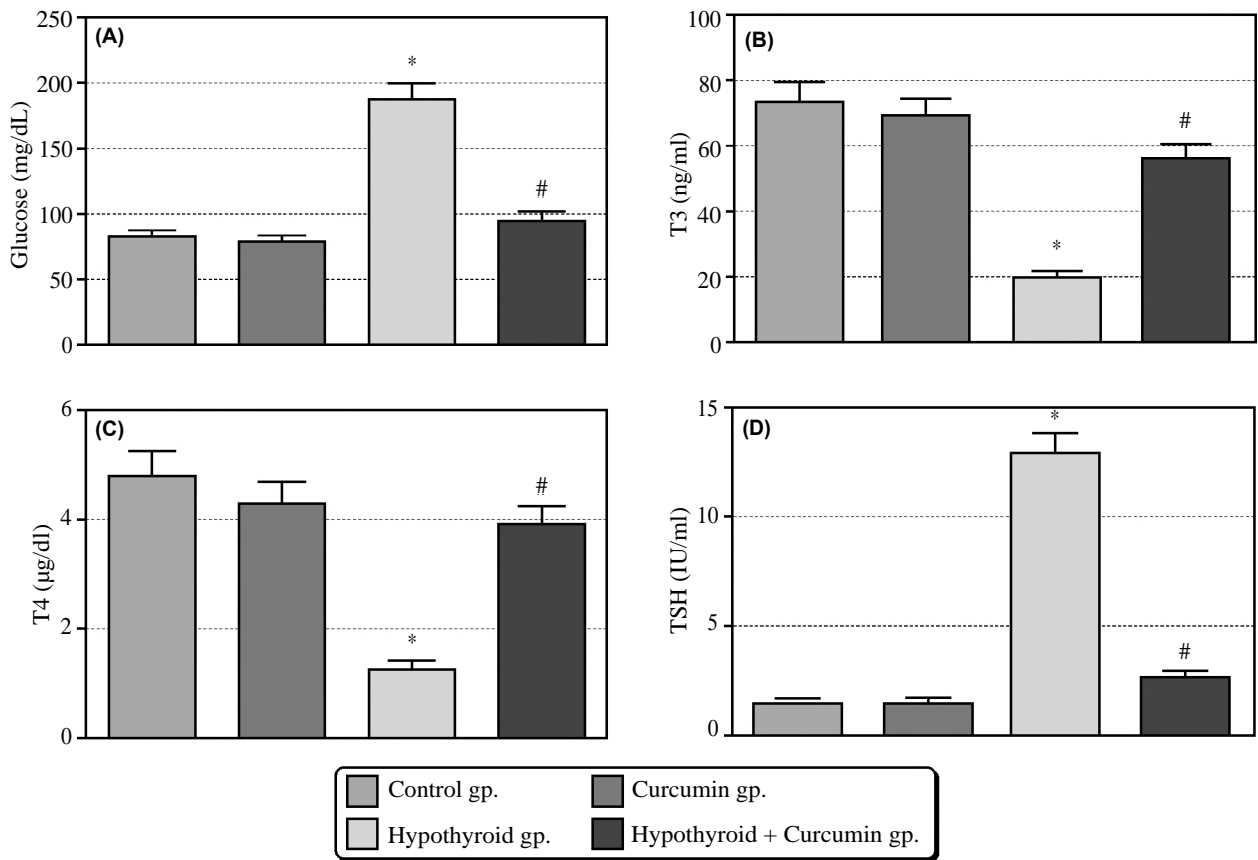


Fig. (4): Serum levels of: A) Glucose, B) T3, C) T4 and D) TSH in different groups.

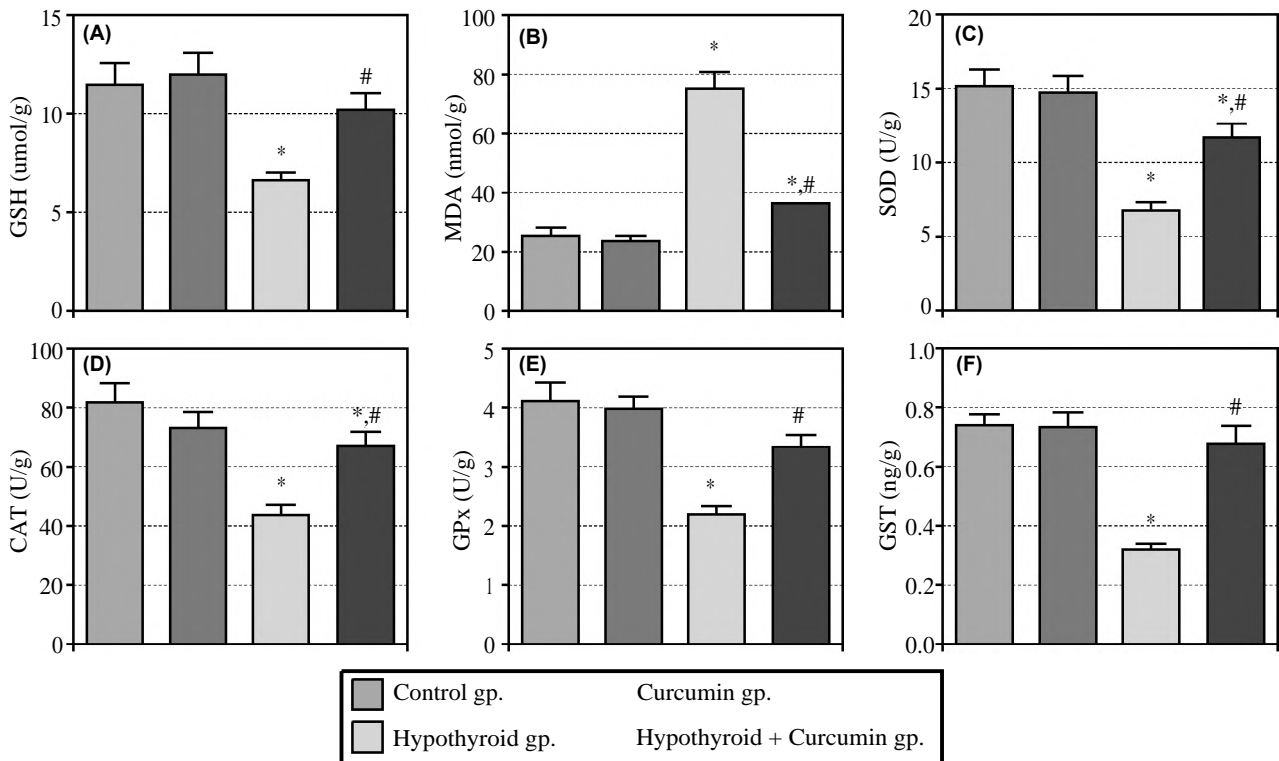


Fig. (5): Oxidative tissue markers in different groups: A) Reduced glutathione (GSH), B) Malondialdehyde (MDA), C) Superoxide dismutase (SOD), D) Catalase CAT, E) Glutathione peroxidase (GPx) and Glutathione-S-Transferase (GST).

## Discussion

Hypothyroidism is one of the most common endocrine diseases mainly caused by abnormalities in the thyroid gland which lead to decrease in production and secretion of the thyroid hormones [28]. Although histological analysis of pancreas after administration of a variety of drugs and pathological conditions had been carried out in a number of studies [29,30], information on the histology of pancreas in hypothyroidism is sparse and fragmentary. Therefore, the present work was designed to explore the role of Curcumin in prevention of the possible biochemical, histopathological and immunohistochemical, changes in the pancreas of hypothyroid rat.

As evidenced in our results, histological examination of pancreatic sections of the hypothyroid rats showed small and shrinkage inlets with some degenerated cells with vacuolated cytoplasm. These results is in accordance with the findings of Safayee et al., 2016 [31] who found that the size of the pancreatic islets and the total number of the beta cells were significantly decreased in the hypothyroid group as compared with the control group. And Rodríguez-Castelán et al., 2015 [32] who reported that the number of cells in large and medium islets was decreased in hypothyroidism. Also Farahani et al., 2013 [3] added that neonatal hypothyroidism retards growth and decreases the size of the islets which are associated with a long-lasting effect on carbohydrate metabolism and reduced insulin secretion, effects which may increase the susceptibility for development of Type 2 diabetes later in adult life.

In the current study, there was a significant decrease in area percentage of anti insulin stained pancreatic section in hypothyroid group (group) as compared with the control group. This in agreement with Safayee et al., (2016) [30] who showed a decline in insulin antibody positivity in hypothyroid group. In addition Goulart-Silva et al., 2011 [5] explained that the decreased insulin secretion in hypothyroidism was due to the reduction of proinsulin gene expression.

In our study, the hypothyroid group revealed a significant decrease in the serum glucose level as compared with control group. Potenza et al., (2009) [33] explained that thyroid hormones stimulate intestinal glucose absorption, enhancing hepatic glycogenesis, altering oxidative and non-oxidative glucose metabolism, and increasing renal insulin clearance.

In the current study, group III revealed a significant decrease in serum T3 and T4 levels and a significant increase in TSH level, so the hypothyroid state was established compared with control rats. This result coincides with study of Sajadian et al., (2016) [10]. By contrast, the mean values of T3 and T4 were significantly increased and the mean value of TSH was significantly decreased in group IV compared to groups III. This result is in harmony with previous studies that reported similar finding Feng et al., (2015) [34] and Meghana et al., (2007) [35].

In the present study the hypothyroid group (group III) showed that tissue MDA formation (a product of lipid peroxidation) was significantly increased. On the other hand there were significant decrease in SOD, GSH, CAT, GST and GPx activities. Increased MDA formation suggested enhancement of oxidative stress in hypothyroidism and this is in line with the results of Safayee et al., (2016) [30] who stated that Hypothyroid induced a significant increase in lipid peroxidation, and decrease in the antioxidant enzyme activity. Also Nasra, (2016) [36] reported the same results in serum but controversial with Sajadian et al., [10] who reported normal level of these parameters in pancreatic tissue except GSH level which was significantly decreased in the hypothyroid group compared with control groups.

These results suggested better improvement in the thyroid function and blood glucose with Curcumin. Moreover, there was an obvious histological, biochemical and immunohistochemical improvement in group IV compared to group III. This results was established by histomorphometric study that revealed a significant increase in degree of immune reaction of insulin in anti-insulin stained sections in group IV as compared with group III.

Kang et al., (2010) [37], explained that Curcumin enhance insulin sensitivity in muscle cell and also Rodríguez-Castelán et al., (2015) [38] added that it stimulate insulin production. In addition Meghana et al., 2007 [39] reported that administration of Curcumin could ameliorate the hyperlipidemia in type 2 diabetic rats.

The anti-inflammatory effect of Curcumin was linked to its ability to interact with many molecular components concerned with inflammation. The inflammatory response was modulated by these structures through down-regulation of the activity of specific enzymes. Also, the production of the inflammatory cytokines, tumor necrosis factor-

alpha, interleukins and monocyte chemoattractant protein were inhibited [40].

### Conclusion:

Data so far obtained indicated that Curcumin has antioxidant effect that could possibly account for its potential in the current study to ameliorate all the histological, immunohistochemical and biochemical parameters altered by hypothyroidism.

### References

- 1- HAMOULI-SAID Z., TAHARI F., HAMOUDI F., et al.: Comparative study of the effects of pre and post natal administration of a thyroid drug on testicular activity in adult rat. *Folia Histochem. Cytobiol.*, 45 (Suppl): S51-7, 2007.
- 2- AMERION M., TAHAJJODI S., HUSHMAND Z., et al.: The effect of maternal thyroid disorders (hypothyroidism and hyperthyroidism) during pregnancy and lactation on skin development in wistar rat newborns. *Iran J. Basic Med. Sci.*, 16: 665-74, 2013.
- 3- FARAHANI A., GHASEMI M., ROGHANI S., et al.: Effect of neonatal hypothyroidism on carbohydrate metabolism, insulin secretion, and pancreatic islets morphology of adult male offspring in rats *J. Endocrinol. Invest.*, 36: 44-9, 2013.
- 4- SILVA F.G., GIANNOCCO G., LUCHESSI A.D., et al.: T3 acutely increases GH mRNA translation rate and GH secretion in hypothyroid rats. *Mol. Cell. Endocrinol.*, 317: 1-7, 2010.
- 5- GOULART-SILVA F., De SOUZA P.B. and NUNES M.T.: T3 rapidly modulates TSHbeta mRNA stability and translational rate in the pituitary of hypothyroid rats. *Mol. Cell Endocrinol.*, 332: 277-82, 2011.
- 6- AGUAYO-MAZZUCATO C., ZAVACKI A.M., MARINELARENA A., et al.: Thyroid hormone promotes postnatal rat pancreatic P-cell development and glucose-responsive insulin secretion through MAFA. *Diabetes*, 62: 1569-80, 2013.
- 7- ETO K., NISHIMURA W., OISHI H., et al.: MafA is required for postnatal proliferation of pancreatic  $\beta$ -cells. *PLoS ONE* 9, e104184, 2014.
- 8- CRUNKHORN S. and PATTI M.E.: Links between thyroid hormone action, oxidative metabolism, and diabetes risk? *Thyroid*, 18: 227-37, 2008.
- 9- BRENTA G.: Why can insulin resistance be a natural consequence of thyroid dysfunction? *J. Thyroid. Res.*, 152850, 2011.
- 10- SAJADIAN M., HASHEMI M., SALIMI S., et al.: Nakhae 1,2 The Effect of Experimental Thyroid Dysfunction on Markers of Oxidative Stress in Rat Pancreas Drug Development Research, 77: 199-205, 2016.
- 11- EL SAIED A.A., FETOUH F.A. and ALBASHA M.O.: Nephro-protective effects of curcumin, rosemary and propolis against gentamicin induced toxicity in guinea pigs: Morphological and biochemical study. *Am. J. Clin. Exp. Med.*, 2: 28-35, 2014.
- 12- KIM S.K., SEOK H., PARK H.J., et al.: Inhibitory effect of curcumin on testosterone induced benign prostatic hyperplasia rat model. *BMC Complement. Altern. Med.*, 15: 27-35, 2015.
- 13- EPSTEIN J., SANDERSON I.R. and MACDONALD T.T.: Curcumin as a therapeutic agent: The evidence from in vitro, animal and human studies. *Br. J. Nutr.*, 103: 1545-57, 2010.
- 14- DARVESH A.S., AGGARWAL B.B. and BISHAYEE A.: Curcumin and liver cancer: A review. *Curr. Pharm. Biotechnol.*, 13: 218-28, 2012.
- 15- PANDYA U., SAINI M.K., JIN G.F., et al.: Dietary curcumin prevents ocular toxicity of naphthalene in rats. *Toxicol Lett.*, 115: 195-204, 2000.
- 16- SOMANAWAT K., THONG-NGAM D. and KLAIKEAW N.: Curcumin attenuated paracetamol overdose induced hepatitis. *World J. Gastroenterol.*, 19: 1962-7, 2013.
- 17- JASSIM M.A., SARAH J.S. and ALZERJAWI M.H.: Effect of propylthiouracil-induced hypothyroidism on reproductive efficiency of adult male rats *Bas.j.vet. Res.*, Vol. 12, No. 2, 2013.
- 18- PAPIEZ M.A., KAJA M. and GEBAROWSKA A.: Age-dependent different actions of curcumin in thyroid of rat. *Folia Histochem. Cytobiol.*, 46: 205-11, 2008.
- 19- BANCROFT J.D. and GAMBLE M.: *Theory and Practice of Histological Techniques*, 5th ed., Churchill Livingstone, London. p. 85-107, 2002.
- 20- BANCROFT and COOK: *Manual of histological techniques and their diagnostic applications* Edinburgh; New York: Churchill Livingstone, 1994.
- 21- SASAKI T. S. and MASTSY A. S.: Effect of acetic acid concentration on the colour reaction in the O-toluidine boric acid method for blood glucose estimation, *Rinsho Kagaku*, 1: 346-53, 1972.
- 22- NISHIKIMI M., RAO N.A. and YAGI K.: The occurrence of superoxide anion in the reaction of reduced phenazine methosulfate and molecular oxygen. *Biochemical and Biophysical Research Communications*, 46 (2): 849-54, 1972.
- 23- PAGLIA D.E. and VALENTINE W.N.: Studies on the quantitative and qualitative characterization of erythrocyte glutathione peroxidase. *The Journal of laboratory and clinical medicine*, 70 (1): 158-69, 1967.
- 24- OHKAWA H., OHISHI N. and YAGI K.: Assay for lipid peroxides in animal tissues by thiobarbituric acid reaction. *Analytical Biochemistry*, 95 (2): 351-8, 1979.
- 25- BEUTLER O., DURON B.M. and KELLY: Improved method for the determination of blood glutathione, *J. Lab. Clin. Med.*, 61: 882-90, 1963.
- 26- CLAIBORNE A.: Catalase activity. In Greenwald, R.A., Ed., *CRC Handbook of Methods for Oxygen Radical Research*, CRC Press, Boca Raton, 283-4, 1985.
- 27- HABIG W., PABST M. and JAKOBY M.: Glutathione transferase: A first enzymatic step in mercapturic acid formation', *J. Biol. Chem.*, 249: 7130-9, 1974.
- 28- DORAFSHANI M.M., JALALI M., NIKRAVESH M.R., et al.: Study of the effect of hypothyroidism on the apoptotic index in rat ovarian follicles, using the tunel technique. *A.S.J.*, 10: 25-35, 2013.



- 29- YOGESH C.Y.: Effect of cisplatin on pancreas and testies in Wistar rats: Biochemical parameters and histology Heliyon 5, e02247, 2019.
- 30- MARWA A., AHMED1 and KHALED M.A. HASSA-NEIN 2: Effects of estrogen on hyperglycemia and liver dysfunction in diabetic male rats Int. J. Physiol. Pathophysiol. Pharmacol., 4 (3): 156-66, 2012.
- 31- SAFAYEE S.I, KARBALAEI N., NOORAFSHAN A., et al.: Nduction of oxidative stress, suppression of glucose-induced insulin release, ATP production, glucokinase activity, and histomorphometric changes in pancreatic islets of hypothyroid rat. Eur. J. Pharmacol., Nov. 15; 791: 147-56, 2016.
- 32- BEST L., ELLIOTT A.C. and BROWN P.D.: Curcumin induces electrical activity in rat pancreatic beta-cells by activating the volumeregulated anion channel. Biochem. Pharmacol., 73: 1768-75, 2007.
- 33- POTENZA M., VIA M.A. and YANAGISAWA R.T.: Excess thyroid hormone and carbohydrate metabolism. Endocr. Pract., 15: 254-62, 2009.
- 34- ROUSE M., YOUNES A. and EGAN J.M.: Resveratrol and curcumin enhance pancreatic beta-cell function by inhibiting phosphodiesterase activity. J. Endocrinol., 223: 107-17, 2014.
- 35- LI J.M., LI Y.C., KONG L.D., et al.: Curcumin inhibits hepatic protein-tyrosine phosphatase 1B and prevents hypertriglyceridemia and hepatic steatosis in fructose-fed rats. Hepatology, 51: 1555-66, 2010.
- 36- NASRA N.: Histological and immunohistochemical study on the possible ameliorating effects of thymoquinone on the salivary glands of rats with experimentally induced hypothyroidism The Egyptian Journal of Histology, 39: 125-35, 2016.
- 37- KANG C. and KIM E.: Synergistic effect of curcumin and insulin on muscle cell glucose metabolism. Food Chem. Toxicol., 48: 2366-73, 2010.
- 38- RODRÍGUEZ-CASTELÁN J.L., NICOLÁS S. and MORIMOTO E.C.: The Langerhans islet cells of female rabbits are differentially affected by hypothyroidism depending on the islet size Endocrine, 48: 811-7, 2015.
- 39- MEGHANA K.I, SANJEEV G. and RAMESH B.: Curcumin prevents streptozotocin-induced islet damage by scavenging free radicals: A prophylactic and protective role. Eur. J. Pharmacol., Dec. 22, 577 (1-3): 183-91, 2007.
- 40- GOEL A., KUNNUMAKKARA A.B. and AGGARWAL B.B.: Curcumin as "curecumin": From kitchen to clinic. Biochem. Pharmacol., 75: 787-809, 2008.

## التأثير المُحسن المحتمل للكرمين على البنكرياس في حالة قصور الغدة الدرقية في الفئران؛ دراسة نسيجية، كيميائية مناعية، وكيميائية حيوية

قصور الغدة الدرقية هو واحد من أكثر أمراض الغدد الصماء شيوعاً التي تسببها بشكل رئيسي تغيرات في الغدة الدرقية.

وقد أجريت هذه الدراسة لتقييم التغيرات النسيجية، المناعية، والكيمياء الحيوية الناجمة عن قصور الغدة الدرقية في بنكرياس الفئران البالغة وتقييم تأثير الكركمين.

أجريت هذه الدراسة على أربعين من ذكور الفئران البيضاء البالغة وزنها (١٧٠-٢٠٠) جم، قسمت الحيوانات إلى أربع مجموعات، المجموعة الأولى: (المجموعة الضابطة (مجموعة الكركمين) تم إعطاء المجموعة الكركمين عن طريق الفم من خلال القناة المعوية بجرعة ١٠٠مغ/كغ/وزن الجسم، لمدة ٦ أسابيع، المجموعة الثالثة: (مجموعة الغدة الدرقية) إعطاء البروبييل ثيوراسيل (هرمون الغدة الدرقية) ١٥مغ/كغ من وزن الجسم عن طريق الفم خلال ٦ أسابيع. تلقت المجموعة الرابعة (مجموعة الغدة الدرقية ومجموعة الكركمين المعالجة) نفس جرعة من البروبييل ثيوراسيل لمدة ٦ أسابيع مع إضافة الكركمين تبدأ ٢ أسابيع بعد إدارة البروبييل ثيوراسيل (بعد تأكيد حالة قصور الغدة الدرقية) إلى الإِسبوع السادس. تمت إزالة البنكرياس وأجريت الدراسة النسيجية، المناعية والكيمياء الحيوية.

أظهرت مجموعة قصور الغدة الدرقية تغيرات نسيجية في شكل جزر منقوصة شاحبة تحتوي على خلايا تحتوي على السيتوبلازم المقطوع ونواة الحويصلات وتظهر جزيرة صغيرة من لانجرهانس مع عدد ضئيل من الأنسولين؛ بالإضافة إلى إنخفاض كبير في كل من SOD و GPx وكذلك زيادة في مستويات Malondialdehyde في نسيج البنكرياس مقارنة مع المجموعة الضابطة. كشفت مجموعة قصور الغدة الدرقية المعالجة بالكرمين تحسناً في هذه التغيرات النسيجية والكيميائية الحيوية.

الكرمين له تأثير تحسين على البنكرياس في قصور الغدة الدرقية الناجم عن البروبييل ثيوراسيل. يبدو أن تأثير الكركمين يكون من خلال تقليل تكوين MDA، وزيادة إنتاج GSH و SOD. وبالتالي، فإنه يعد التوازن مؤكسد/مضادات الأكسدة.