

# The Diagnostic Performance of Contrast Enhanced Spectral Mammography in Detecting Occult Breast Lesions in Patients with Dense Breasts

NIVINE CHALABI, M.D. and NOHA M. OSMAN, M.D.

The Department of Radiodiagnosis, Faculty of Medicine, Ain Shams University

## Abstract

**Background:** Contrast Enhanced Spectral Mammography (CESM) is an evolving imaging technique using contrast media to enhance the sensitivity for breast cancer detection and to extend the capability of mammography.

**Aim of Study:** To evaluate the added benefit of Contrast Enhanced Mammography (CESM) in detecting occult breast lesions that escaped conventional Digital Mammography (DM).

**Patients and Methods:** 68 female patients (121 breasts) with dense breasts were enrolled in this study. CESM was performed after conventional DM which was negative. CESM results were compared to sonography and histopathologic results. Diagnostic accuracy of CESM in differentiating malignant from benign lesions was determined.

**Results:** By using CESM, 18 cancers were detected in 68 patients with negative conventional mammographic studies. CESM had sensitivity 88.9%, specificity was 100%, PPV was 100%, NPV was 60% while the overall diagnostic accuracy of CESM was 85.7% in cancer detection.

**Conclusion:** CESM has the potential to increase breast cancer detection rate over conventional DM especially in women with dense breasts. CESM has high specificity and positive predictive value in identifying malignant breast lesions. CESM is a promising tool for screening women with dense breasts and high risk for breast cancer.

**Key Words:** Contrast enhanced spectral mammography – Breast cancer detection – Digital mammography – Dense breast.

## Introduction

**THE** accuracy of breast cancer diagnosis depends directly on its detection. Mammography remain the modality of choice for cancer detection and follow-up despite the availability of various other breast imaging modalities [1]. One of the most important limitations of mammography is due to

the superimposition of dense breast fibroglandular tissues, dense background may obscure an underlying mass reducing its sensitivity and hence its diagnostic performance [2].

Sonography is superior to mammography in women with dense breasts, however, it has been reported to be operator dependent [3].

Over the last few years, new techniques have been evolving using contrast media to enhance the sensitivity for breast cancer detection and to extend the capability of mammography. These techniques are based on the principle of rapid formation of tumoral microvessels which makes malignancy associated vessels more permeable to contrast agent than normal tissue, resulting in lesion enhancement [4].

Contrast Enhanced Spectral Mammography (CESM) is an evolving imaging technique. Its principle lies behind acquisition of dual-energy breast images; a Low-Energy (LE) and a High-Energy (HE) image for each breast in the standard views. The LE image provides the highest soft tissue contrast and is similar to a conventional mammography image. The HE image is used for post-processing purposes only. Both images are processed to create a subtracted image which highlights enhancing lesions thus increase cancer detection [5].

Our study aimed at evaluating the added benefit of CESM in detecting, thus characterizing occult breast lesions that escaped conventional Digital Mammography (DM).

## Patients and Methods

This study was conducted between April 2018 and May 2019 in Ain Shams University Hospitals,

**Correspondence to:** Dr. Nivine Chalabi, The Department of Radiodiagnosis, Faculty of Medicine, Ain Shams University

Cairo, Egypt. Sixty-eight female patients (121 breasts) with dense breasts (ACR BI-RADs breast density categories C & D) and negative conventional mammography were enrolled in this study. Patients were clinically referred for undergoing standard sonomammographic breast examinations for breast screening and diagnostic purposes. Patients' age ranged from 27-46 years old. Our participants were further subjected to CESH to enhance the performance of mammography in cancer detection. In terms of breast lesions detection, conventional DM results were compared to those of CESH considering sonography as a proof for lesions detection, then diagnostic accuracy of CESH in characterizing detected breast lesions was studied having the histopathologic results as a gold standard. Histopathologic data were obtained in 18 out of 21 lesions detected by CESH, the remaining 3 lesions were subjected to 3 months short interval follow-up by ultrasound.

The added benefit of the CESH and the possible associated risks and complications of IV contrast media were fully explained to all patients who agreed to receive CESH. Patients having contraindications for the use of iodine-based contrast agents such as an increased risk of developing contrast-induced nephropathy or known contrast allergies were excluded. All patients were consented to undergo contrast enhanced spectral mammography as a complementary study to conventional DM in order to enhance the detection of occult breast lesions by mammography. Our study was approved by the Ethical Committee of Ain Shams University Hospitals.

#### *CESH technique:*

Contrast enhanced mammography studies were performed using Senographe Pristina, GE healthcare contrast enhanced mammography device. A single shot of 1.5ml/kg body weight, iodinated non-ionic contrast agent (ultravist 300) was administered using manual intravenous injection. Maximum allowed dosage was 120mL. Two minutes after the initiation of contrast agent administration; a pair of LE (Low Energy) and HE (High Energy) exposures were obtained. The breast without a suspected lesion was imaged first, followed by the breast with the suspected lesion, to increase the likelihood of contrast uptake in the breast of interest. LE and software-derived SI are automatically sent to the VP workstation to be viewed on the monitor.

They were immediately reviewed by a radiologist for the presence of abnormal contrast enhancement and for the need of additional views. The

mean examination duration was approximately 10 mins (ranging from 6 to 12 mins).

#### *Imaging analysis and interpretation:*

Conventional DM studies of our participants were negative studies. CESH examinations were interpreted by a consultant radiologist with expertise in breast imaging. Reader was asked to report the presence or absence of enhancing breast lesions in CESH films and to describe the pattern of enhancement in terms of homogenous, heterogeneous or ring pattern. Then to state the level of suspicion for cancer in the present lesion according to the enhancement pattern and the morphologic characters based on the Breast Imaging Reporting and Data System (BI-RADS) lexicon designed by the American College of Radiology (ACR) [6].

#### *Statistical analysis:*

In reference to final diagnosis of detected breast lesions by CESH through histopathologic results in 18 lesions and follow-up in 3 lesions, true positive, true negative, false positive and false negative results were determined. The diagnostic sensitivity, specificity, positive predictive value, negative predictive value and accuracy were defined. Statistical analyses were done using SPSS software (version 20.0).

## **Results**

Our study included 68 dense breasts female patients (121 breasts) with negative DM films. Their CESH revealed 21 enhancing breast lesions which were all (100%) depicted thus approved by US. Histopathology was carried out for 18 lesions while 3 lesions were subjected to short term 3 months follow-up by ultrasound and showed no interval changes. Morphological analysis according to BI-RADs and enhancement patterns of CESH detected lesions differentiated them into 5 (23.8%) benign and 16 (76.1 %) malignant lesions Figs. (1-5). All malignant lesions (100%) by CESH and 2 out of 5 (40%) benign lesions by CESH were proven for malignancy by biopsy results (Table 1). Thus, the sensitivity of CESH in detecting breast cancer was 88.9%, specificity was 100%, PPV was 100% while NPV was 60%. The overall diagnostic accuracy of CESH was 85.7%.

Statistically significant difference <0.05 was found as regards the pattern of enhancement and the margins of suspicious lesions by CESH. Most of suspicious lesions showed heterogeneous enhancement (88.9%) and their margins were mostly irregular (55.5%) or spiculated (33.3%) (Table 2).

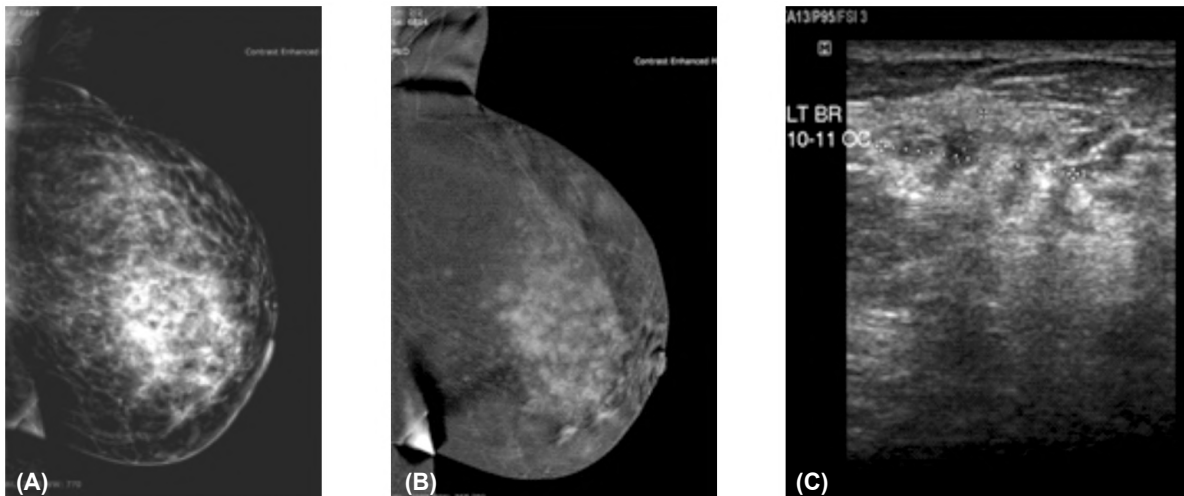


Fig. (1): 45-year-old patient, left breast lump. (A) LE image: ACR C breast density. (B) CESM: Irregular margin shaped mass showing heterogenous enhancement. (C) US: Multiple areas of architectural distortion & small irregular shaped hypoechoic lesions with irregular margins. Histopathology: IDC with multicentric disease.

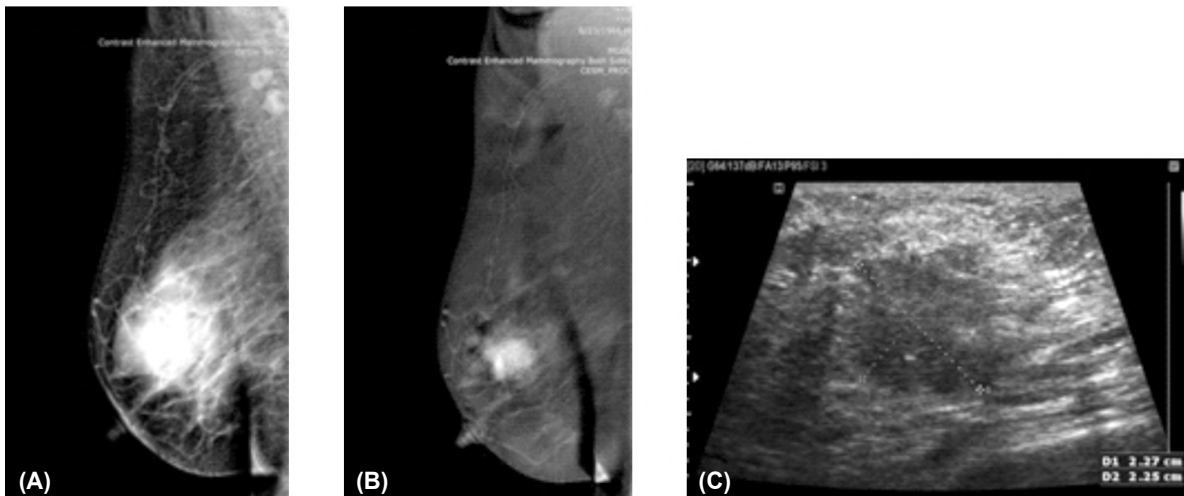


Fig. (2): 42-year-old patient, right breast lump. (A) LE image: ACR D breast density. (B) CESM: Irregular shaped enhancing mass lesions with irregular margins, intensely enhancing with heterogenous pattern. (C) US: Hypoechoic irregular shaped masses with posterior acoustic shadowing & calcific foci. Histopathology: Invasive mammary carcinoma.

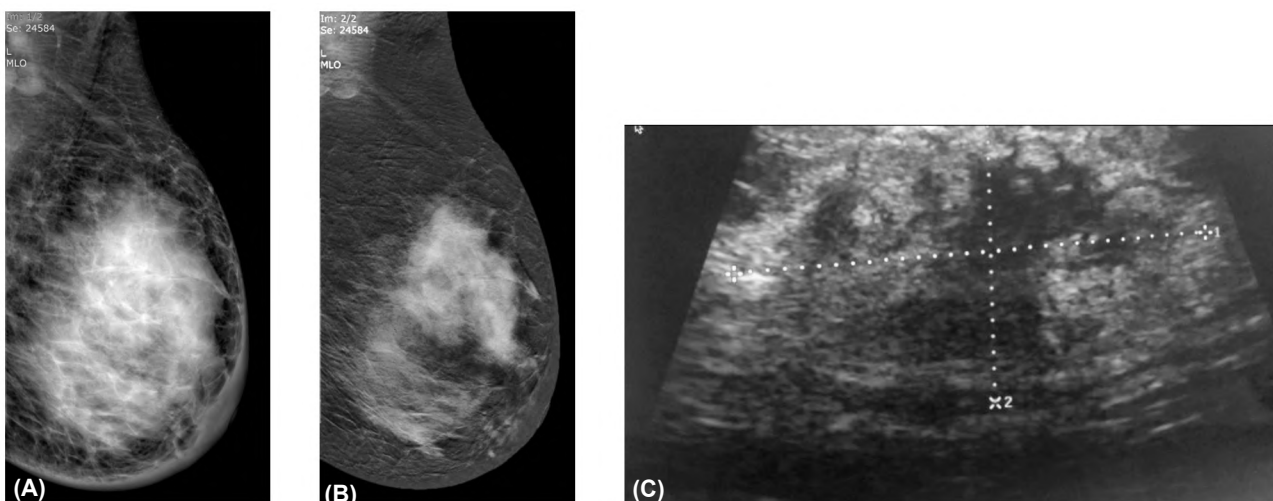


Fig. (3): 27-year-old patient, left breast tenderness. (A) LE image: ACR D breast density. (B) CESM: Large irregular margin shaped mass homogeneously enhancing (C) US: Large island of hypoechoic non circumscribed mass lesion. Histopathology: Invasive ductal carcinoma.

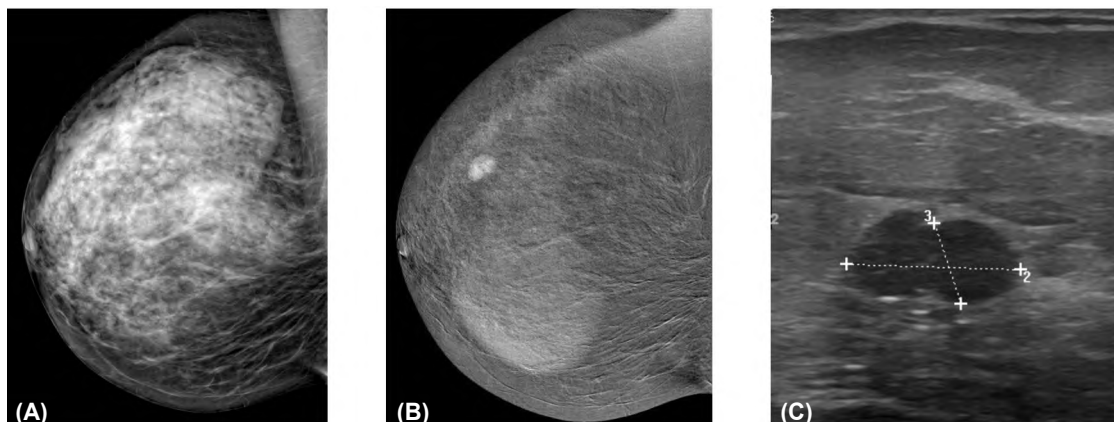


Fig. (4): 40-year-old patient. High risk, routine screening. (A) LE image: ACR C breast density. (B) CESH: Right well oval well circumscribed strongly enhancing mass with small non enhancing areas, (C) US: Well circumscribed oval lobulated hypoechoic mass lesion. Histopathology: Mixed pericanalicular and intracanalicular fibroadenoma.

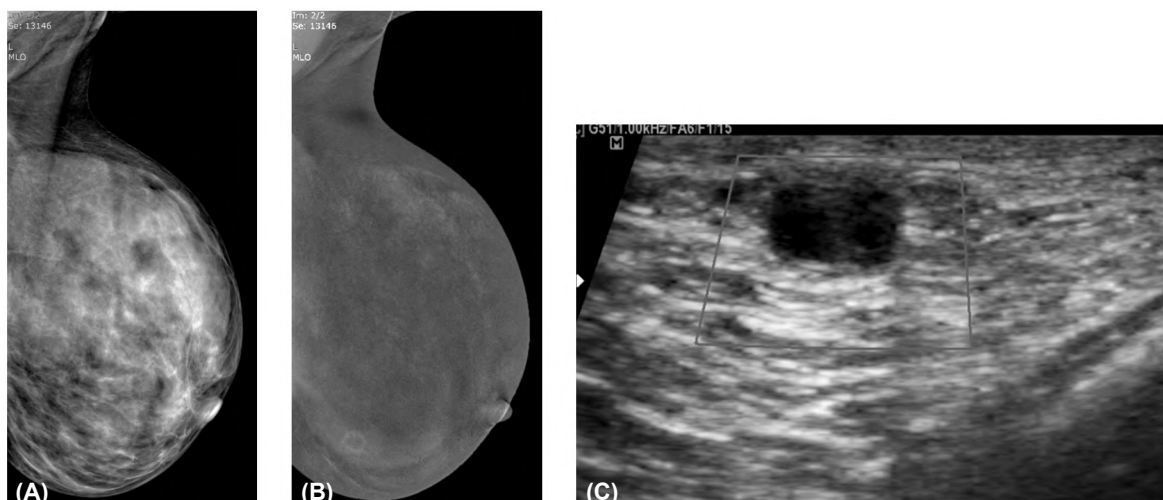

Fig. (5): 30-year-old patient, bilateral mastalgia. (A) LE image: ACR D breast density. (B) CESH: Rounded regular thin ring enhancement, (C) US: Rounded thick walled complicated cyst. Final diagnosis after 3 months interval: Inflamed cyst.

Table (1): Diagnostic performance of CESH in breast lesions detection and characterization.

| CESH                    | Benign (5)         | Malignant (16)     |
|-------------------------|--------------------|--------------------|
| <i>Final diagnosis:</i> |                    |                    |
| Benign (3)              | 3 (true negative)  | 0 (true negative)  |
| Malignant (18)          | 2 (false negative) | 16 (true positive) |

Table (2): The most statistically significant morphological characteristics and enhancing patterns in CESH detected lesions in correlation to histopathology results.

|                              | Benign    | Malignant  |
|------------------------------|-----------|------------|
| <i>Enhancement patterns:</i> |           |            |
| Homogeneous                  | 2 (66.7%) | 2 (12.5%)  |
| Ring                         | 1 (33.3%) | 0          |
| Total                        | 3 (100%)  | 18 (100%)  |
| <i>Margins:</i>              |           |            |
| Circumscribed                | 3 (100%)  | 2 (12.5%)  |
| Irregular                    | 0         | 10 (55.5%) |
| Spiculated                   | 0         | 6 (33.3%)  |
| Total                        | 3 (100%)  | 18 (100%)  |

### Discussion

CESH is an evolving imaging dual-energy technique to detect breast cancer. It is based on lesion contrast enhancement due to newly formed proliferating tumor vessels which are leaky. CESH is performed with high-energy and low-energy acquisitions after the injection of iodine contrast medium, then a subtracted images of both breasts are obtained. The LE image presents the morphological information is similar to that of digital mammography, whereas the HE image displays the enhancement pattern [7].

Several studies were done to evaluate the diagnostic performance of CESH in breast cancer detection. In these studies, the mean sensitivity of CESH ranged from 77.8 to 100.0%. Whereas the mean specificity varied from 41 to 87.7% [8-18]. Our study revealed CESH sensitivity, specificity,

PPV and NPV of 88.9%, 100%, 100% and 60% respectively.

In our study, we found out a statistically significant difference  $<0.05$  as regards the pattern of enhancement and the margins of suspicious lesions by CESM. Most of suspicious lesions showed heterogenous enhancement (88.9%). This agrees with Tohamey et al., [19] and Helal et al., [20] where 84% and 93% of malignant mass lesions displayed heterogenous internal enhancement pattern respectively. Most of CESM detected malignant lesions showed irregular (55.5%) or spiculated (33.3%) margins. This coincides with Tohamey et al., [19], Helal et al., [20] and Kamal et al., [21] who reported 98.7%, 93.8% and 96.3% malignant lesions showing irregular/spiculated margins respectively.

### Conclusion:

CESM has the potential to increase breast cancer detection rate over conventional DM especially in women with dense breasts. CESM has high specificity and positive predictive value in identifying malignant breast lesions. CESM is a promising tool for screening women with dense breasts and high risk for breast cancer.

### References

- 1- SIEGEL R., NAISHADHAM D. and JEMAL A.: Cancer statistics. CA. Cancer J. Clin., 63 (1): 11-30, 2013.
- 2- CARNEY P.A., MIGLIORETTI D.L., YANKASKAS B.C., et al.: Individual and combined effects of age, breast density, and hormone replacement therapy use on the accuracy of screening mammography. Ann. Intern. Med., 138: 168-75, 2003.
- 3- ABDULLAH N., MESUROLLE B., EL-KHOURY M., et al.: Breast imaging reporting and data system lexicon for US: Interobserver agreement for assessment of breast masses. Radiology, 252: 665-72, 2009.
- 4- TAGLIAFICO A.S., et al.: Diagnostic performance of contrast-enhanced spectral mammography: Systematic review and meta-analysis. The Breast, 28: 13-9, 2016.
- 5- LALJI U.C., JEUKENS C.R.L.P.N., HOUBEN I., et al.: Evaluation of low-energy contrast-enhanced spectral mammography images by comparing them to full-field digital mammography using EUREF image quality criteria. Eur. Radiol., Oct., 25 (10): 2813-20, 2015.
- 6- SICKLES E.A., D'ORSI C.J., BASSETT L.W., et al.: ACR BI-RADS® mammography. ACR BIRADS® Atlas 5th edition, Breast Imaging Reporting and Data System. Reston, VA: American College of Radiology, 2013.
- 7- BHIMANI C., MATTA D., ROTH R.G., et al.: Contrast-enhanced spectral mammography: Technique, indications, and clinical applications. Acad. Radiol., 24: 84-8, 2017.
- 8- DROMAIN C., THIBAUT F., MULLER S., et al.: Dual-energy contrast-enhanced digital mammography: Initial clinical results. Eur. Radiol., 21: 565-74, 2011.
- 9- JOCHELSON M.S., DERSHAW D.D., SUNG J.S., et al.: Bilateral contrast-enhanced dual-energy digital mammography: Feasibility and comparison with conventional digital mammography and MR imaging in women with known breast carcinoma. Radiology, 266: 743-51, 2013.
- 10- LUCZYNSKA E., HEINZE-PALUCHOWSKA S., DYCZEK S., et al.: Contrast-enhanced spectral mammography: Comparison with conventional mammography and histopathology in 152 women. Korean J. Radiol., 15: 689-96, 2014.
- 11- LOBBES M.B.I., LALJI U., HOUWERS J., et al.: Contrast-enhanced spectral mammography in patients referred from the breast cancer screening programme. Eur. Radiol., 24: 1668-76, 2014.
- 12- FALLENBERG E.M., DROMAIN C., DIEKMANN F., et al.: Contrast enhanced spectral mammography: Does mammography provide additional clinical benefits or can some radiation exposure be avoided? Breast Cancer Res. Treat., 146: 371-81, 2014.
- 13- LEWIN J.M., ISAACS P.K., VANCE V. and LARKE F.J.: Dual-energy contrast-enhanced digital subtraction mammography: Feasibility. Radiology, 229: 261-8, 2003.
- 14- DROMAIN C., THIBAUT F., DIEKMANN F., et al.: Dual-energy contrast-enhanced digital mammography: Initial clinical results of a multireader, multicase study. Breast Cancer Res., 14: R94, 2012.
- 15- FALLENBERG E.M., DROMAIN C., DIEKMANN F., et al.: Contrast enhanced spectral mammography versus MRI: Initial results in the detection of breast cancer and assessment of tumour size. Eur. Radiol., doi:10.1007/s00330-013-3007-7, 2013.
- 16- CHEUNG Y.C., LIN Y.C., WAN Y.L., et al.: Diagnostic performance of dual-energy contrast-enhanced subtracted mammography in dense breasts compared to mammography alone: Interobserver blind-reading analysis. Eur. Radiol., doi:10.1007/s00330-014-3271-1, 2014.
- 17- CHEUNG Y.C., TSAI H.P., LO Y.F., et al.: Clinical utility of dual energy contrast-enhanced spectral mammography for breast microcalcifications without associated mass: A preliminary analysis. Eur. Radiol., doi:10.1007/s00330-015-3904-z, 2015.
- 18- LUCZYNSKA E., HEINZE-PALUCHOWSKA S., HENDRICK E., et al.: Comparison between breast MRI and contrast-enhanced spectral mammography. Med. Sci. Monit., 21: 1358-67, 2015.
- 19- TOHAMEY Y.M., S.W. YOUSSEY and A.I. ABD EL AZIZ: Interpretation of patterns of enhancement on contrast-enhanced spectral mammography: An approach to a standardized scheme. The Egyptian Journal of Radiology and Nuclear Medicine, 49 (3): p. 854-68, 2018.
- 20- HELAL M., et al.: Accuracy of CESM versus conventional mammography and ultrasound in evaluation of BI-RADS 3 and 4 breast lesions with pathological correlation. The Egyptian Journal of Radiology and Nuclear Medicine, 48 (3): p. 741-50, 2017.
- 21- MOHAMED KAMAL R., et al.: Contrast-enhanced spectral mammography: Impact of the qualitative morphology descriptors on the diagnosis of breast lesions. European Journal of Radiology, 84 (6): p. 1049-55, 2015.

## الأداء التشخيصى لفحص الماموجرام بالصبغة فى الكشف عن آفات الثدي الخفية فى المرضى ذوى نسيج ثدى عالى الكثافة

يعتبر فحص الماموجرام بالصبغة للثدى (CESM) هو تقنية تصوير متطورة تستخدم وسائط تباين لتعزيز الحساسية للكشف عن سرطان الثدي ولتوسيع قدرة التصوير الإشعاعى للثدى.

تهدف الدراسة إلى تقييم الفائدة المضافة فحص الماموجرام بالصبغة (CESM) فى إكتشاف آفات الثدي الخفية التى لم تكتشف بالماموجرام التقليدى (DM).

أجريت الدراسة على ٦٨ مريضاً (١٢١ ثدى) ذوى كثافة عالية. وتم إجراء فحص ماموجرام بالصبغة بعد أشعة الماموجرام التقليدى والتى كانت سلبية. وتمت مقارنة نتائج الفحصين بالموجات فوق الصوتية على الثدي والنتائج الباثولوجية للعينات مع تحديد دقة التشخيص لفحص الماموجرام بالصبغة فى التمييز بين الآفات الخبيثة والحميدة.

تم الكشف عن ١٨ ورماً سرطانياً فى ٦٨ مريضاً بواسطة الماموجرام بالصبغة مما أعطى حساسية ٨٨.٩٪، وخصوصية ١٠٠٪ فى حين أن دقة التشخيص العام للفحص كانت ٨٥.٧٪ فى الكشف عن السرطان مما أشار أن الماموجرام بالصبغة يعتبر أداة واعدة لفحص السيدات ذوات الثدي عالى الكثافة والمرضى الأكثر عرضه للإصابة بسرطان الثدي.