



## Histological Effect of Coq10 on Liver and Buccal Mucosa in Mice

Ghasaq A. Dawood<sup>1</sup>, Ghada A. Taqa<sup>2\*</sup>, Manar M. Alnema<sup>3</sup>

<sup>1</sup>Ministry Of Health-Nineveh Health Directorate, Mosul, Iraq.

<sup>2</sup>Department of Dental Basic Science, College of Dentistry, University of Mosul, Mosul, Iraq.

<sup>3</sup>Department of Oral and Maxillofacial Surgery, College of Dentistry, University of Mosul, Mosul, Iraq.

\* Corresponding author: Ghada A. Taqa; email: [ghada.abd.taqa@gmail.com](mailto:ghada.abd.taqa@gmail.com)

### ABSTRACT

The goal of the present study is to evaluate the histological effect of Coenzyme Q10 (CoQ10) in the liver and buccal mucosa in mice. After acclimatization to the laboratory conditions, Twenty-four mice were randomly assigned to three experimental groups and housed as eight animals/cage, and each group was treated as follows: Group A: this served as a control group and was given daily olive oil orally. Group B and C were given once daily CoQ10 in dose (100mg /kg) and (200mg/kg) respectively. All groups were treated for 15 days and at the last of the experiment, all animals of each group were sacrificed and liver in addition to buccal mucosa was excised and placed in 10% buffered formalin for histological examination. In CoQ10 treated groups a normal histological structure similar to control group in liver and buccal mucosa sections were noticed at the CoQ10 (100mg/kg) group while mild histological changes were noticed at the CoQ10 (200mg/kg) group included slightly congested portal vein and sinusoids, mild centric lobular vacuolar swelling in the hepatic lobule and buccal mucosa sections showed normal structure as control group. CoQ10 at a dose (100mg/kg) not produce any histological changes in the liver and buccal mucosa in mice but when increasing the dose to (200mg/kg) produce mild histological changes in liver but not in the buccal mucosa.

**Keywords:** Buccal mucosa, Coenzyme Q10, histology, liver, mice.

### INTRODUCTION

Coenzyme Q10 or CoQ10 or ubiquinone is a vitamin-like substance that is an oily-soluble in nature, exist in most eukaryotic cells. CoQ10 is a 1, 4-benzoquinone, with a quinone chemical group, and 10 isoprenyl chemical subunits in its tail (Sharma, *et al.*, 2016). It is an important component of the electron transport chain (ETC) producing aerobic energy by changing ADP to ATP.

CoQ10 is found in highest concentrations in organs such as liver that associated with the highest energy requirements. It is found primarily in mitochondria due to its role in the ETC as well as in reacting with Reactive Oxygen Species (ROS) (Crane, 2001).

Ubiquinol is the most commonly existed form of Coenzyme Q10 (Quinzii, *et al.*, 2008). In the reduced form it can give electrons, which makes it an antioxidant by protecting the plasmatic membrane against peroxidation, Oxidative stress harms cell membranes and is known as lipid peroxidation. This oxidative stress is occurred due to Reactive Oxygen Species (ROS) that made during exercise or at very low levels during rest (Mancuso, *et al.*, 2010). Ubiquinol can avoid the damage from occurring by giving electrons to the ROS (Hodgson and Watts, 2003). Besides, that CoQ10 can regenerate the oxidized form of  $\alpha$ -tocopherol by giving the essential hydrogen molecule to vitamin E to recycle it (Ayer and Stocker, 2015).

Coenzyme Q10 is a relatively well-known supplement today and it has a big interest in the areas

### Original Article:

DOI: [HTTPS://DX.DOI.ORG/10.21608/JA.2020.85543](https://dx.doi.org/10.21608/JA.2020.85543)

Received: 22 Jan., 2020

Accepted :23 Feb., 2020

Published: April 2020

This is an open access article under the terms of the Creative Commons Attribution 4 (CC-BY) International License . To view copy of this license, visit: <http://creativecommons.org/licenses/by/4.0/>

*J. Appl. Vet. Sci.*, 5(2) : 1-5.

of vitality, heart health, as an antioxidant, anti-inflammatory and analgesic effect (Al-Jureisy, *et al.*, 2020). The present study aims to investigate the histological changes of CoQ10 on the liver and buccal mucosa in mice.

## MATERIALS AND METHODS

### Laboratory animals

This study was done at the pharmacology laboratory of Department of basic sciences at the College of Dentistry / University of Mosul / Iraq. Twenty-four adult healthy male albino mice weighing (25-30) gm. Purchased from the Animal House of Experimental Research Unit, College of Veterinary Medicine, University of Mosul, Iraq. Animals allowed adapting for 1 week before the experiments in the Animal House of the College of Dentistry, University of Mosul, Iraq. They housed at (22 ±2) °C, 12hr light /12 hr. dark cycle and fed standard laboratory chow and provided with water.

### Experimental Design

After acclimatization to the laboratory conditions, twenty-four mice were randomly assigned to three experimental groups and housed as eight animals per cage, and each group was treated as follows: Group A: this served as normal control group and was given once daily (5ml/kg) vehicle (olive oil by oral intake through gavage tube). Groups B and C were given once daily CoQ10 in dose (100 mg /kg) and (200 mg/kg) respectively (Zhang, *et al.*, 2013). The dose of CoQ10 was dissolved in olive oil and the solution was placed in a water bath at 37°C before oral administration by gavage tube. All groups were treated for 15 days, at the last of experimental animals of each group were sacrificed and liver in addition to buccal mucosa was excised and placed in 10% buffer formalin for histological examination.

### Tissue preparation for histological study

Liver and buccal mucosa of each mouse were prepared for histological study by placing them in a solution of 10% buffered formalin for 24 hours for fixation, after that the tissues were dehydrated using a gradual concatenation of alcohol (30%-100%) for (5 min.) each. Following that the tissue samples were cleared in 2 separated xylene changes before placing them in paraffin wax for final sectioning. Then the samples were cross-sectioned at 5 µm thickness, stained later by hematoxylin and eosin (H&E) stain to investigate the histological changes (Luna, 1968) then

compared to the control group by using a light microscope.

Histological changes of liver sections in mice in the control group showed normal cellular and architectural details encompassing normal portal areas, normal hepatic cord cells around the central vein (Figure 1). In CoQ10 treated groups a normal view similar to control was noticed at the CoQ10 (100mg/kg) group (Figure 2) and mild changes were noticed at the CoQ10 (200mg/kg) group included slightly congested portal vein and sinusoids, mild centric lobular vacuolar swelling in the hepatic lobule (Figure 3,4). While histological changes of buccal mucosa sections in mice in control group sections revealed normal squamous epithelial lining, normal mucous- salivary glands, normal ducts opening normal vasculature and underline tissue (Figure 4). The same of what mentioned above were observed at the CoQ10 (100mg/kg) treated group with active mucous -salivary glands (Figure 5). In CoQ10 (200mg/kg) treated group showed active mucous-salivary glands with slightly hyperemic in blood vessels and normal epithelial (Figure 6).

## RESULTS

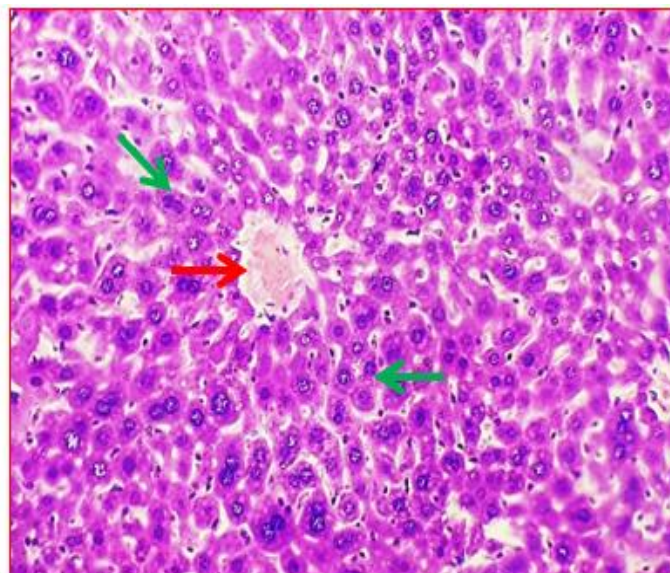


Fig. 1: Photomicrograph of mouse liver section from the control group showing normal cellular and architectural details of the central vein (→) and hepatic cords (→). Staining H&E X 200.

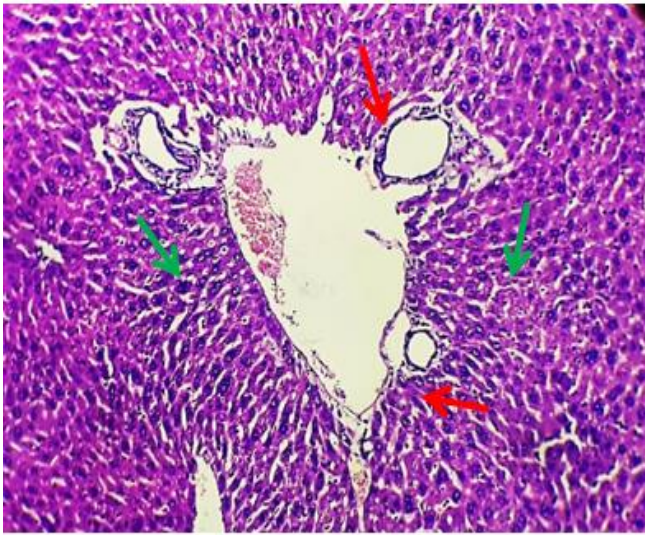

Fig. 2: Photomicrograph of mouse liver section from CoQ10 (100mg/kg) treated group showing normal cellular and architectural details of the Portal area (→) and hepatic cords (→). H&E X115.

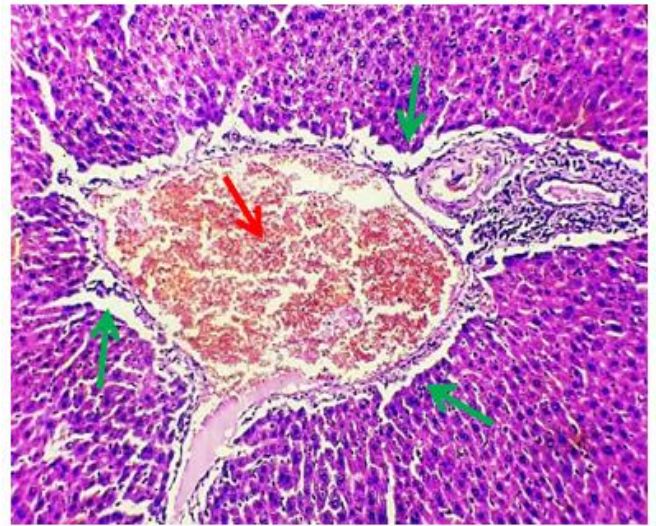


Fig. 3: Photomicrograph of mouse liver section from CoQ10 (200mg/kg) treated group showing moderately congested portal vein (→) Mild periportal oedema (→). H&E X200.

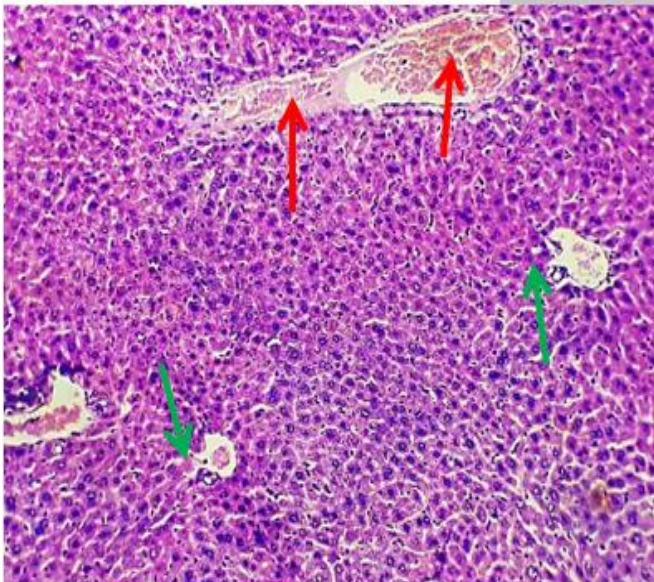


Fig. 4: Photomicrograph of mouse liver section from CoQ10 (200mg/kg) treated group showing moderately congested sinuses (→) Mild centrilobular hepatic cell swelling (→). H&E X 145

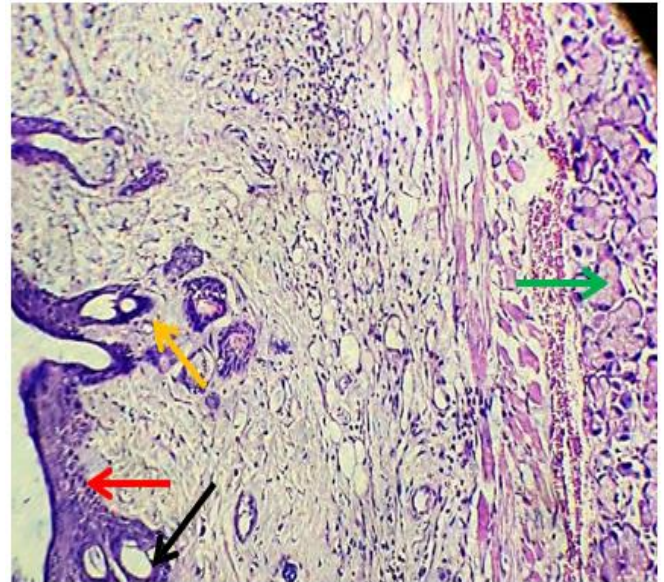


Fig. 5: Photomicrograph of mouse buccal mucosa section from control group showing normal epithelium (→) normal salivary glands (→) normal mucous glands (→) and normal ducts (→). H&E X 115

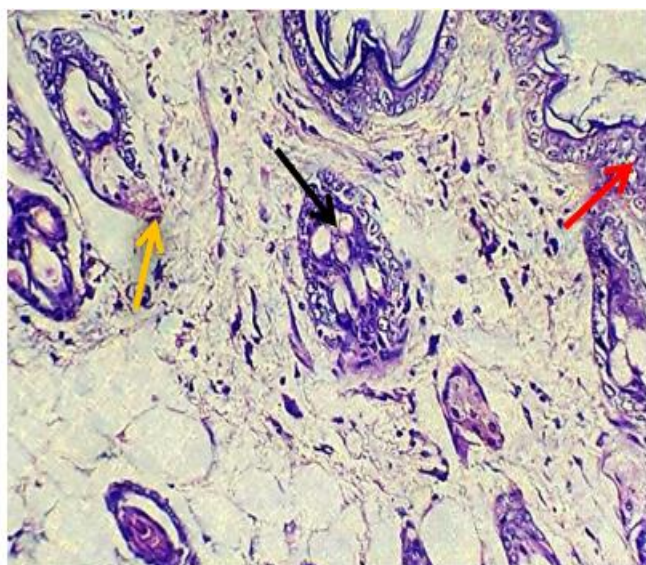


Fig. 6: Photomicrograph of mouse buccal mucosa section from CoQ10 (100mg/kg) treated group showing normal epithelium (→) normal mucous glands (→) and normal lobular ducts (→). H&E X265.

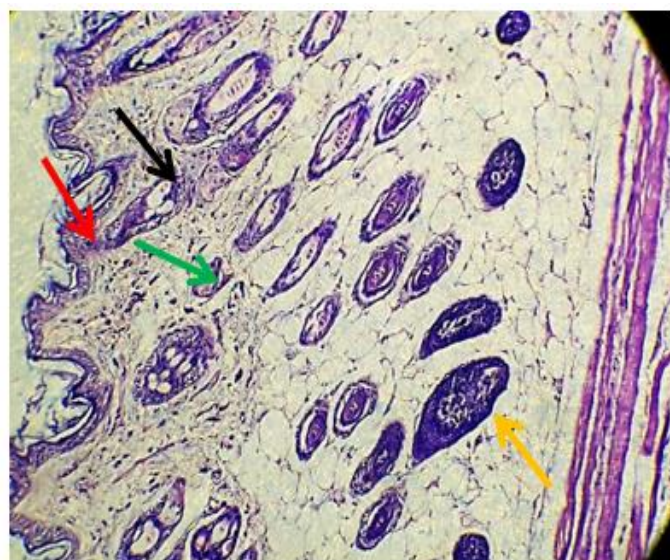


Fig. 7: Photomicrograph of mouse buccal mucosa section from CoQ10 (200mg/kg) treated group showing normal epithelium (→) active mucous glands (→) dilated lobular ducts (→) and slightly hyperemic blood vessels (→). H&E X115.

## DISCUSSION

Histology of liver sections showed normal view similar to control group where noticed at the CoQ10 (100mg/kg) group and mild changes in liver were noticed at the CoQ10 (200mg/kg) group included slightly congested portal vein and sinusoids, mild centric lobular vacuolar swelling in the hepatic lobule these changes related to treatment adverse effect. This result may be explained by opinion mentioned by **Gutierrez-Mariscal *et al.*, (2018)** that exogenous administration of CoQ10 does not elevate tissue levels above normal in healthy young individuals, except for two tissues (liver and spleen) and this result may be indeed due to the side effect of drug on liver that explained as a result of excess uptake of CoQ10 that is greater than the capacity of adaptive response. Also, some antioxidants were suggested to have pro-oxidant effects at higher doses, as the flavonoids that lead to the initiation of reactive oxygen species at high concentration. Some studies reported a similar prooxidant effect for CoQ10 in vitro (**Linnane, *et al.*, 2007**).

This result in line with **Deshmukh *et al.*, (2019)** who mentioned that ubiquinol Acetate at dose (150mg/kg) not produce significant histopathological changes in liver sections of rats while high doses of CoQ10(300 mg/kg and 600mg/kg) showed small white to yellow irregular areas with gross necropsy

resulted from treatment adverse effect and in line with **Kitano *et al.*, (2008)** who mentioned that there is histopathological alterations of liver in rats appeared as fine vacuolation of hepatocytes in groups of CoQ10 at dose 200 mg/kg and above and considered it as not cytotoxic modifications. As well as in agreement with **Mohammed and Al-Okaily, (2017)** and **Abdel-Hady and Abdel-Rahman, (2013)** who mentioned that histopathological effect of CoQ10 at a low dose (10 mg/kg) on liver sections of rats showed the normal structure of hepatic tissue that resembled to control group. While regarding the histopathological result of the current study of CoQ10 groups on buccal mucosa showed normal appearance as in the control group with no foci of apoptosis. This result in line with **Deshmukh *et al.*, (2019)** who studied the histopathological effect of ubiquinol Acetate at doses (150 mg/kg, 300mg/kg and 600mg/kg) on various organs and concluded no any abnormality noticed in salivary glands. As well as in agreement with **Arafat *et al.*, (2016)** who mentioned that no significant histological effect of CoQ10 at a dose (22 mg/kg/subcutaneously injected) on submandibular salivary glands in compared with the control group.

## CONCLUSION

CoQ10 at a dose (100mg/kg) does not produce any histological changes in the liver and buccal mucosa in mice but when increasing the dose

to (200mg/kg) produce only mild histological changes in liver-related to drug side effects.

## ACKNOWLEDGEMENT

The authors are very grateful to the University of Mosul \ College of Dentistry for their provided facilities, which helped improve the quality of this work.

## REFERENCES

- LINNANE A. W., M. KIOS, and L. VITETTA, 2007.** Coenzyme Q10- Its role as a prooxidant in the formation of superoxide anion/hydrogen peroxide and the regulation of the metabolome, Mitochondrion, vol. 7, pp. S51–S61.
- AYER A.M.P. and STOCKER R. 2015.** Function and role in heart failure and ischemic heart disease. *Annu. Rev. Nutr.* (35):175–213.
- CRANE, F. L. 2001.** Biochemical Functions of Coenzyme Q10. *Journal of the American College of Nutrition*, 20(6), 591-598.
- DESHMUKH, G., VENKATARAMAIAH, S. B., DORESWAMY, C. M., UMESH, M. C., SUBBANNA, R. B., PRADHAN, B. K. and SHIVARUDRAIAH, P. 2019.** Safety assessment of ubiquinol acetate: Subchronic Toxicity and Genotoxicity Studies. *Journal of Toxicology*, 1–25.
- EETMAD A ARAFAT, FATMA M GHONEIM, HANAA A KHALAF and AYMAN Z ELSAMANOUDY, 2016.** Anti-senescence role of coenzyme Q10 and 17  $\beta$ -estradiol on the submandibular gland of ovariectomized rats: histological, immunohistological and molecular studies. *Int J Clin Exp Pathol* 9(11):10853-10870.
- ELSAIED K. ABDEL-HADY and GAMAL H. ABDEL-RAHMAN 2013.** Protective role of Coenzyme Q10 against Paraquat induced hepatotoxicity in male rats. *Life Science Journal* 10(1):1933-1940.
- GUTIERREZ-MARISCAL F.M., YUBERO-SERRANO E.M., VILLALBA J.M. and LOPEZ-MIRANDA J. 2018.** Coenzyme Q10: From bench to clinic in ageing diseases, a translational review. *Crit. Rev. Food Sci. Nutr.*  
DOI:10.1080/10408398.2018.1442316
- HODGSON, J. M., and WATTS, G. F., 2003.** Can coenzyme Q10 improve vascular function and blood pressure Potential for effective therapeutic reduction in vascular oxidative stress? *Biofactors*, 18(1-4),129-136.
- IBTISAM T. AL-JUREISY1, WAEL T. AL-WATTAR and GHADA A. TAQA., 2020.** evaluation of the analgesic activity of coenzyme q10 ointment in mice. *Journal of Applied Veterinary Sciences* 5 (1): 11-16.
- IMTITHAL ALI MOHAMMED and BARAA NAJIM AL-OKAILY, 2017.** Effect of sodium fluoride on liver functions of rats and amelioration by CoQ10. *Journal of Entomology and Zoology Studies* 5(5): 887-893.
- KITANO, M., WATANABE, D., ODA, S., KUBO, H., KISHIDA, H., FUJII, K. and HOSOE, K. 2008.** Subchronic Oral Toxicity of Ubiquinol in Rats and Dogs. *International Journal of Toxicology*, 27(2): 189–215.
- LUNA, L.G. 1968.** Manual of Histologic Staining Method of the Armed Forces Institute of Pathology. 3rd Edn. McGraw Hill Co., USA; Pp. 1-46.
- MANCUSO M., ORSUCCI D., VOLPI L., CALSOLARO V. and SICILIANO G. 2010.** Coenzyme Q10 in neuromuscular and neurodegenerative disorders. *Curr. Drug Targets*.11(1):111–121.
- QUINZII C.M., LOPEZ L.C., and VON-MOLTKE J., 2008.** Respiratory chain dysfunction and oxidative stress correlate with severity of primary COQ10 deficiency. *FASEB J.* 22(6):1874–1885.
- SHARMA A., FONAROW G.C., BUTLER J., EZEKOWITZ J.A. and FELKER G.M.2016.** Coenzyme Q10 and heart failure: A state-of-the-art review. *Circ Heart Fail.* 9(4):e002639.
- ZHANG, Y. P., EBER, A., YUAN, Y., YANG, Z., RODRIGUEZ, Y., LEVITT, R. C. AND CANDIOTTI and K. A.2013.** Prophylactic and Antinociceptive Effects of Coenzyme Q10 on Diabetic Neuropathic Pain in a Mouse Model of Type 1 Diabetes. *Anesthesiology*, 118(4), 945–954.

How to cite this article:

Ghasaq A. Dawood, Ghada A. Taqa, Manar M. Alnema.2020.Histological Effect Of Coq10 On Liver And Buccal Mucosa In Mice. *Journal of Applied Veterinary Sciences*, 5(2): 1-5.

**DOI:**

<https://dx.doi.org/10.21608/javs.2020.85543>