



The Role of HSP70, CD34 and Ki 67 Expression in Liver Cirrhosis and Hepatocellular Carcinoma, Immunohistochemical Study

Sayed Abdel Raheem, Abdel Naby Saied, and Emadeldin R Mater

Department of Pathology, Faculty of Medicine, Al Azhar University, Cairo

E.Mail: Sayedabdelrahim8@gmail.com – drshamy61@yahoo.com
– emad-rshde61@hotmail.com

ARTICLE INFO

Article History

Received: 16/11/2018

Accepted: 15/12/2018

Keywords:

HSP70, CD34, Ki-67,
liver cirrhosis and HCC

ABSTRACT

Background: Liver cirrhosis is an important risk factor for hepatocellular carcinoma (HCC).

Aim: To evaluate the expression of HSP70, CD34, and Ki 67 in liver cirrhosis and early HCC.

Methods: 60 liver biopsies were classified into 3 groups; Group 1 (Control; 10 biopsies), Group 2 (Liver Cirrhosis; 25 cases), and Group 3 (HCC; 25 cases). All biopsies were stained by (H&E), Heat Shock Protein 70 (HSP70), CD34, and Ki67.

Results: HSP70 was negative in 10 out of 10 control cases (100%), low expressed (+) in 2 out of 25 cirrhotic cases (8%), and positive in 25 out of 25 HCC cases (100%); low expressed (+) in 5 cases (5 out of 5 well-differentiated HCC) (20%); intermediate expressed (++) in 13 cases (11 out of 11 moderately differentiated HCC and 2 out of 9 poorly differentiated HCC) (52%), and high expressed (+++) in 7 cases (7 out of 9 poorly differentiated HCC) (28%). CD34 was negative in all control cases, while in cirrhotic cases, it is minimally expressed in 5 cases (20%) and diffuse in 6 cases (24%) and positive in all cases of HCC; focal in one case (4%) and diffuse in 24 cases (96%). KI67 was negative in all control cases, isolated positively in one cirrhotic case (4%) while in HCC, it was negative in 2 cases (8%), isolated positive in 9 cases (36%), focal positive in 10 cases (40%) and diffusely positive in 4 cases (16%).

Conclusion; there is a role of HSP70, CD34, and Ki-67 in differentiation between non-neoplastic cirrhotic lesions and early HCC.

INTRODUCTION

In Egypt, hepatocellular carcinoma (HCC) is the second most common malignancy in males and the fifth in females. There was almost a twofold increase of HCC among chronic liver disease patients in Egypt in the past ten years with a significant decline of HBV and a slight increase of HCV as risk factors (El-Zayadi *et al.*, 2005). Liver cirrhosis is an important risk factor of (HCC) with more than 80% of cases arising in the background of cirrhosis (Amarapukar *et al.*, 2008). Distinguishing small HCC from other types of small focal lesions that occur in a cirrhotic liver can be difficult on the basis of morphologic features alone (Libbrecht *et al.*, 2006). Hepatocyte proliferation in the cirrhotic liver promotes the development of HCC.

A few studies have explored the possibility of the use of proliferation markers as predictors of the development of HCC in the cirrhotic liver (Mary *et al.*, 2006). Hepatocellular carcinoma (HCC) is the 6th most common cancer worldwide and the 3rd most frequent cause of death of cancer (Aileen, 2011). Hepatocellular carcinoma typically has a poor prognosis, because it is often diagnosed at an advanced stage (Ragagopal *et al.*, 2008). Early diagnosis of HCC greatly improves its prognosis. However, the distinction between benign and malignant tumors is often difficult and novel immunohistochemical markers are necessary (Masanori *et al.*, 2008). Expression of HSP70 increases under conditions of environmental cellular stress and overexpression of HSP70 also leads to significant protection against cell apoptosis (Amal *et al.*, 2013). The expression of HSP70 has been routinely associated with cancer progression, therapy responses, and poor prognosis in multiple cancers and it can be used as a novel biomarker for early detection of cancers (Yang *et al.*, 2012). Ki67 expression was found to be in close relation to tumor growth rate, which was the most widely used proliferation-associated marker (Cezar *et al.*, 2008). Early detection with appropriate therapy is still the optimal approach that offers the patient the best prognosis (Aileen, 2011). Overexpression of endothelial cell marker CD34 with gradual progression was found from normal liver to cirrhosis to HCC and metastasis. Understanding of this process of angiogenesis might help in the design of efficient and safe anti-angiogenic therapy for these liver disorders (Amarapukar *et al.*, 2008). The aim of this work: to evaluate of expression of HSP70, CD34 and Ki 67

in liver cirrhosis and early detection of hepatocellular carcinoma

MATERIALS AND METHODS

This work included 60 liver biopsies obtained from Al Azhar University hospitals as paraffin blocks. Four-micron thick sections were cut from paraffin blocks of all cases and stained with haematoxylin and eosin (H&E). All cases were re-evaluated and classified into 3 groups; Group 1: Control (10 biopsies), Group 2: Liver Cirrhosis (25 cases), and Group 3: HCC (25 cases). The primary antibodies were as follows:

Heat Shock Protein 70 (HSP70) monoclonal antibody SPA810, clone C92 (StressGen Biotechnologies) at a final concentration of 10 mg/ml. Biotinylated secondary antibody, an avidinbiotin complex (Vector Laboratories; Burlingame, CA), and 3,3'-diaminobenzidine (Sigma Biochemicals; St Louis, MO) as a chromogen were applied for visualization of the immunoreactions. According to (Luca *et al.*, 2007), HSP70 positivity (nuclear & cytoplasmic) evaluated as follows: + (5-10% reactive cells); ++ (11-50% reactive cells); +++ (>50% reactive cells).

CD34 (Monoclonal Mouse Anti-Human Class II, code No. M7165) was used at a dilution range of 1:25-1:50. CD34 staining was scored into four grades according to (De Boer *et al.*, 2000): Negative; (When no capillaries were stained except those in the portal tracts), Minimal; (when only a few scattered individual capillaries were stained away from the portal tracts), Focal; (When some grouped capillaries were stained away from the portal tracts), and Diffuse; (When there was strong positivity throughout the capillaries all over).

Ki-67 (Monoclonal Mouse Anti-Human Antigen, Code M7240), was

used at a dilution range of 1:75-1:150. According to Elena *et al.*, (2012), Ki 67 positivity evaluated according to percentage of positive cells into four-degree: (-) < 24%, (+) 25-50 % (Isolated), (++) 51-74% (Focal), (+++) > 75 % (Diffuse).

Statistical Analysis: Patients' data were tabulated and processed using SPSS (10.0) statistical package for Windows XP. Qualitative data were expressed by frequency and percent and were analyzed using Chi-square.

RESULTS

This study consisted of 60 liver biopsies; 10 cases as a control and 50 cases of hepatic lesions

I. Immunohistochemical results:

A. HSP70: (Fig 1 and tables 1&2).

HSP70 was negative in 10 out of 10 control biopsies (100%). Low expressed (+) in 2 out of 25 cirrhotic biopsies (8%) (Fig 6), and positive in 25 out of 25 HCC biopsies (100%); low expressed (+) in 5 out of 5 well-differentiated HCC) (20%), intermediate expressed (++) in 13 cases (11 out of 11 moderately differentiated HCC and 2 out of 9 poorly differentiated HCC) (52%), and high expressed (+++) in 7 out of 9 poorly differentiated HCC) (28%).(Fig 7).

Table 1: HSP70 Expression among studied groups

Expression	Control		Cirrhosis		HCC	
	No,	%	No,	%	No,	%
Negative	10	100.00%	23	92.00%	0	0.00%
Low expression	0	0.00%	2	8.00%	5	20.00%
Intermediate expression	0	0.00%	0	0.00%	13	52.00%
High expression	0	0.00%	0	0.00%	7	28.00%

HSP70 was highly significant ($X^2 = 54.497$; $p = 0.000$) among studied groups

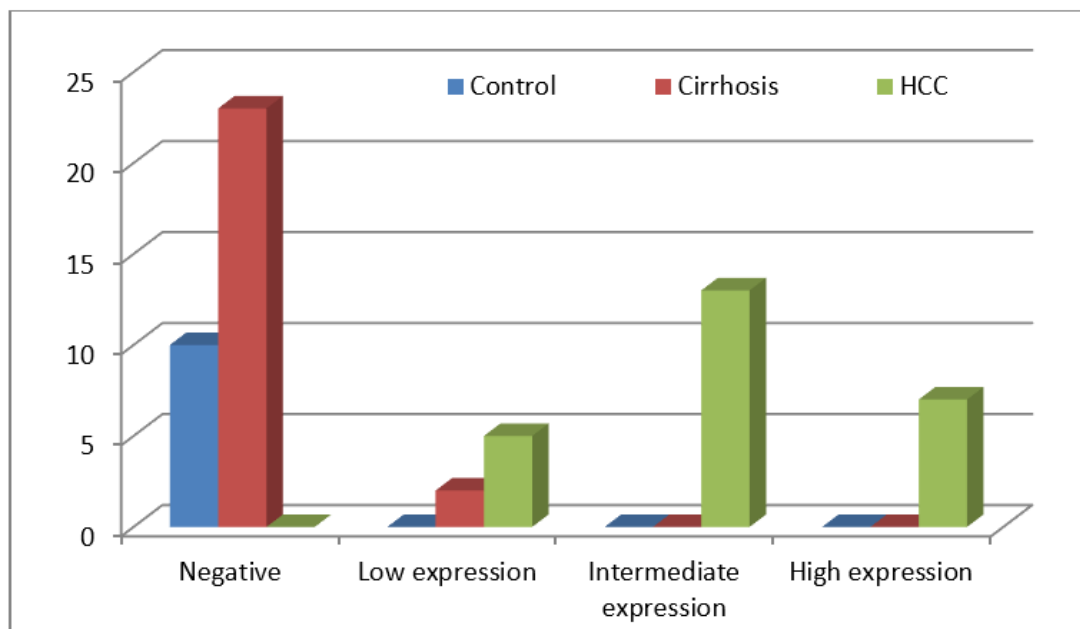


Fig. 1: Comparison of HSP70 among studied groups

Table 2: HSP70 expression in relation to tumor grade

Expression	Well Differentiated		Moderately Differentiated		Poorly differentiated	
	No.	%	No.	%	No.	%
Low expression	5	100	0	0	0	0
Intermediate expression	0	0	11	100	2	22.2
High expression	0	0	0	0	7	77.8

HSP70 was highly significant ($\chi^2 = 41.453$; p -value < 0.01) with tumor grade

B. CD34: (Fig 2 and tables 3&4)

CD34 was negative in all control biopsies. In cirrhotic biopsies, expression was in the portal and periportal sinusoids of the nodules (Fig 8). It is minimal in 5 out of 25 (20%)

and diffuses in 6 out of 25 (24%). It was positive in all cases of HCC (100%); focal in one case (4%) and diffuse in sinusoidal spaces throughout the lesion in 24 cases (96%) (Fig 9).

Table 3: CD34 Expression among studied groups

Expression	Control		Cirrhosis		HCC	
	No.	%	No.	%	No.	%
Negative	10	100.00%	0	0.00%	0	0.00%
Minimal	0	0.00%	5	20.00%	0	0.00%
Focal	0	0.00%	0	56.00%	1	4.00%
Diffuse	0	0.00%	6	24.00%	24	96.00%

CD34 was highly significant ($\chi^2 = 92.480$; $p = 0.000$) among studied groups

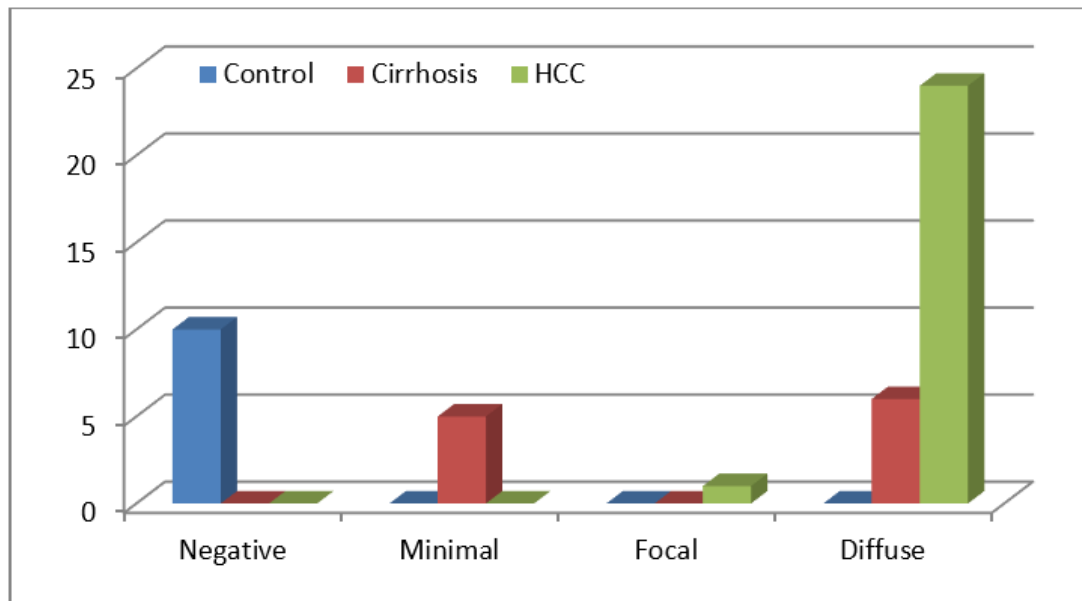
**Fig. 2:** Comparison of CD34 among studied groups

Table 4: CD34 expression in relation to tumor grade

Expression	Well Differentiated		Moderately Differentiated		Poorly differentiated	
	N	%	No.	%	No.	%
Focal	0	0	0	0	1	11.1
Diffuse	5	100	11	100	8	88.9

CD34 was insignificant ($X^2= 1.852$; p-value = 0.398) with tumor grade.

C.Ki 67: (Fig 3 and tables 5&6)

Ki67 was negative in all control biopsies, isolated positive in one cirrhotic case (4%), while in HCC, it was negative in 2 cases (8%) (Fig 10),

isolated positive in 9 cases (36%), focal positive in 10 cases (40%) and diffusely positive in 4 cases (16%). (Fig 11).

Table 5: Ki 67 Expression among studied groups

Expression	Control		Cirrhosis		HCC	
	No.	%	No.	%	No.	%
Negative	10	100.00%	23	92.00%	2	8.00%
Isolated positive	0	0.00%	1	4.00%	9	36.00%
Focal Positive	0	0.00%	0	0.00%	10	40.00%
Diffuse Positive	0	0.00%	1	4.00%	4	16.00%

Ki67 was highly significant ($X^2 = 45.531$; p = 0.000).among studied groups

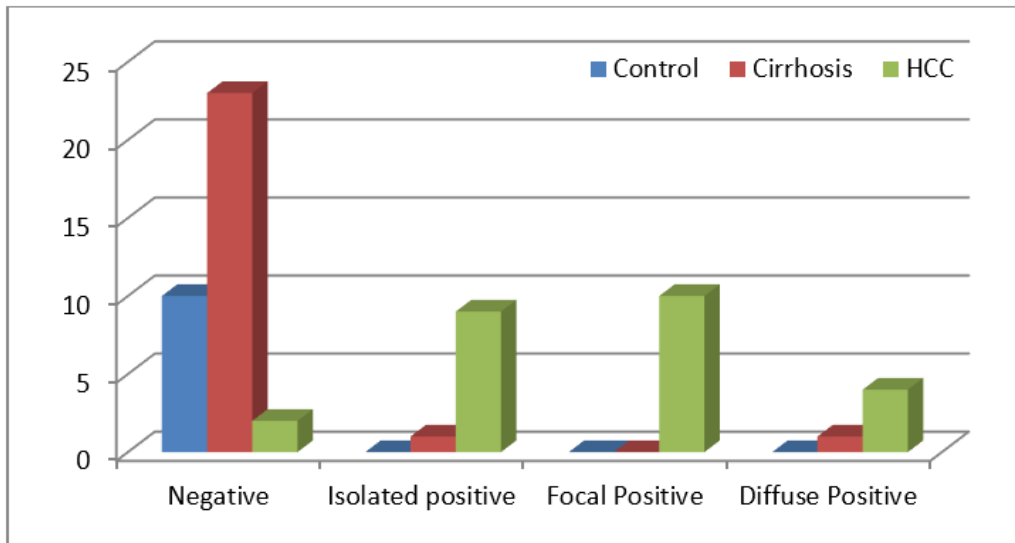


Fig. 3: Comparison of Ki 67 among studied groups

Table 6: Ki 67 expression in relation to tumor grade

Expression	Well Differentiated		Moderately Differentiated		Poorly differentiated	
	No.	%	No.	%	No.	%
Negative	2	40	0	0	0	0
Isolated positive	3	60	6	54.5	0	0
Focal Positive	0	0	5	45.5	5	55.6
Diffuse Positive	0	0	0	0	4	44.4

From the previous table it was shown that 60% of well differentiated tumors showed isolated positive expression, and moderately differentiated tumors ranged between isolated and focal positive expression (54.5% and 45.5% respectively), while poorly differentiated tumors ranged between focal and diffuse positive expression (55.6% and 44.4% respectively). On comparison of KI67 with tumor grade, it was found

statistically highly significant ($X^2=22.828$; $p\text{-value}<0.01$).

II. Histopathological results:

Ten biopsies of the control group, 25 biopsies of liver cirrhosis (12; with no dysplastic changes (Fig 4), 9; with low-grade dysplasia, and 4; with high-grade dysplasia), and 25 biopsies of HCC (9; acinar type (Fig 5), 12; trabecular type, and 4; poorly differentiated type).

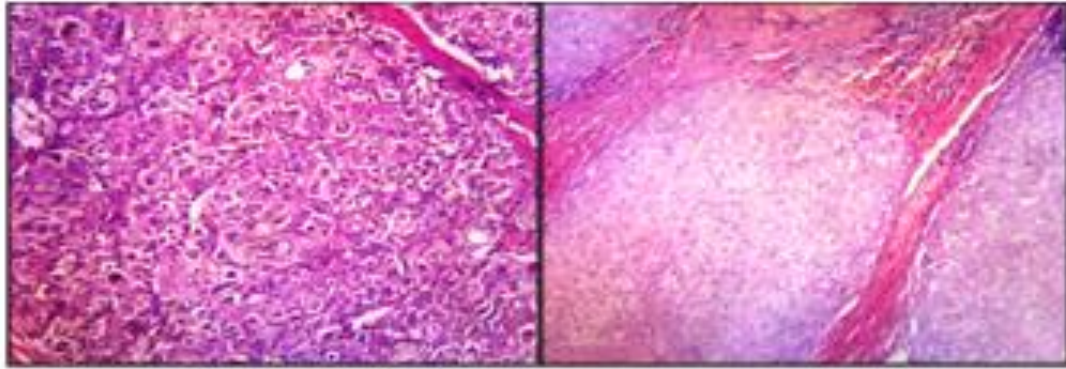


Fig 4: Liver showing regenerative nodules separated by fibrous bands (H&E X 150)

Fig 5: HCC: malignant hepatocytes arranged in acinar pattern (H&E X 360)

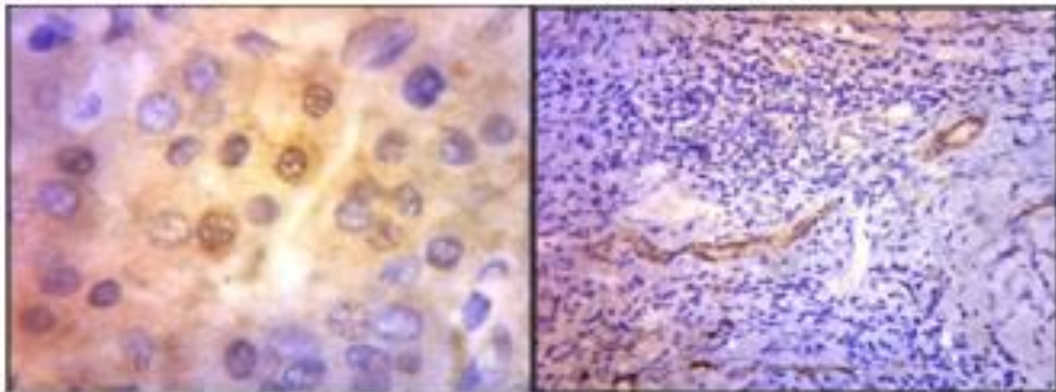


Fig 6: Liver cirrhosis negative for HSP70 (Immunostain X 200)

Fig 7: HCC showing intermediate positivity for HSP70 (Immunostain X 400)

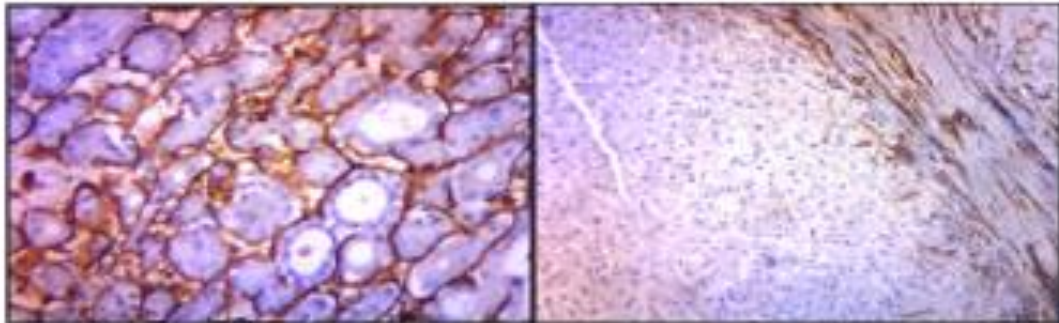


Fig 8: cirrhosis showing CD34 positivity in the portal and periportal sinusoids (Immunostain X 200)

Fig 9: HCC showing diffuse positivity for CD34 throughout lesion (immunostain X 200)

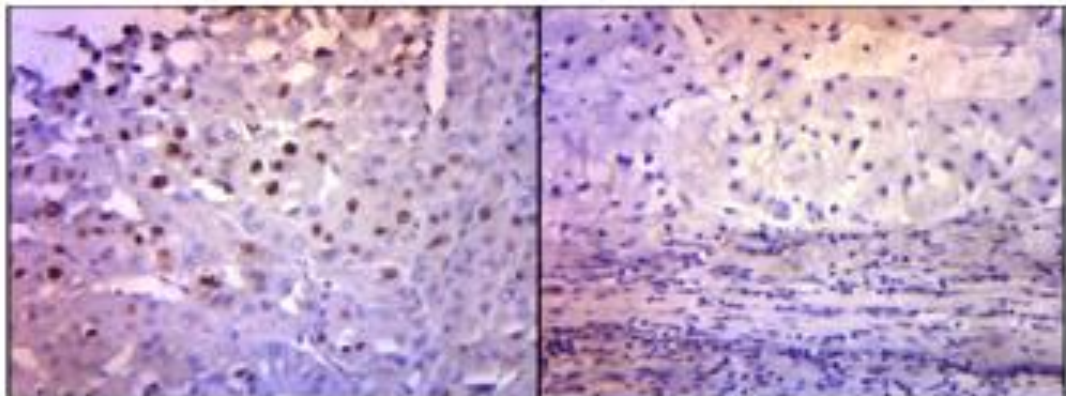


Fig 10: cirrhosis negative for Ki 67 (immunostain X 200)

Fig11: HCC showing Ki 67 nuclear positivity (immunostain X 200)

DISCUSSION

In this study, HSP70 was negative in all control biopsies (100%), low expression in 2 of 25 (4%) of cirrhotic biopsies, while it is positive in all biopsies of hepatocellular carcinoma as low expression in 5 cases (20%), intermediate expression in 13 biopsies (52%) and high expression in 7 biopsies (28%).

Our findings are in agreement with Shin *et al.*, (2011) who found that HSP70 staining in 282 of 392 HCC samples (71.9%), and with (Luca *et al.*, 2007) who found that HSP70 immunoreactivity was seen in the vast majority of HCCs (39 of 53 cases, 73.58%), including 9 of 10 cases of HCC (90%) and 16 of 22 (72.7%) for G1 HCC, and with Effendi & Sakamoto (2010) who detected immunoreactivity of HSP70 ranging up to 80% in most cases of early HCC, while no or only focal and faint nuclear staining was observed in the noncancerous background liver tissue, and with (Amal *et al.*, 2013) who found that overexpression of HSP70 detected in 92.86% of early Hepatocellular carcinoma cases, while the expression was noticed in 2.94% of liver cirrhosis cases without hepatocellular carcinoma.

According to the Mee *et al.*, (2005), HSP70 may play an important role in hepatocarcinogenesis, and can contribute tumor progression by promoting tumor cell proliferation in HCC, so its expression can contribute to not only hepatocarcinogenesis but also tumor

Our findings are in agreement with (Di Tommaso *et al.*, 2007) that use a panel of markers on HCC samples. Heat shock protein 70 (HSP70), glypican 3 (GPC-3), and glutamine synthetase (GS) were shown to offer a sensitivity of 70% and a specificity of 100% (for 2 markers)

Even for very well differentiated and grade 1 HCC, the accuracy was 57% (3 markers) and 72.9% (2 markers) and a 100% specificity

In our study, HSP70 was expressed in all HCC patients with different degrees of expression, although this comes in contrast with *El-Din et al.*, (2010) who found that HSP70 was not associated with high risk of future development of HCC in Egyptian population. Our findings are in disagreement with Chuma *et al.*, (2003) who reported HSP70 as the most abundantly up-regulated gene in early HCC and significantly over expressed in advanced HCC as compared to early HCC and precancerous lesions

In this study, CD34 was observed as negative in all normal cases, while in cirrhotic cases, it expressed as minimal in 5 cases (20%) and diffuse in 6 cases (24%), whereas it is positive in all cases of hepatocellular carcinoma as focal in one case (4%) and diffuse in 24 cases (96%)

Our findings are in agreement with (Yang *et al.*, 2010; Ding *et al.*, 2011) who reported that CD34 staining is one of the important markers of tumor angiogenesis and microvascular density in HCC and is closely associated with HCC prognosis, and with Wang *et al.* (2012) who study liver thin-core biopsy specimens, and found that the sensitivity and specificity of CD34 expression in small HCC nodules (≤ 3 cm) were 94% and 89%, respectively, and with (Wee A& Sampatanukul P, 2004) who reported that the positive rate of CD34 expression in HCC cases were 100%, and with Paschoal *et al.*, (2014) who observed that, CD34 endothelium markers were positive in all types of hepatocellular nodules, although with variable intensity, and with *Du et al.*, (2011) who found the positive expression rates of CD34 in advanced

HCC and well-differentiated HCC ranged from 25% to 100% [and strongly positive in 76% (38/50) and 70% (21/30), respectively

CD34 expression in the capillaries and sinusoids of noncancerous hepatic tissue is a risk factor for multicentric recurrence of HCC and histologic assessment of hepatic tissue with CD34 immunohistochemistry might be useful for the prognostic evaluation of HCC patients after surgery (Tsuji *et al.*, 2013).

In liver carcinogenesis, CD34 antibody is one of the most studied vascular markers. It is important for the prognostic evaluation of patients and also has diagnostic value (Yao *et al.*, 2007).

In this study, Ki 67 staining was observed as negative in all normal cases, isolated positive in one cirrhotic case (4%) while in cases of hepatocellular carcinoma expressed as negative in 2 cases (8%), isolated positive in 9 cases (36%), focal expression in 10 cases (40%) and diffuse positive in 4 cases (16%).

Our findings are in agreement with (Mary *et al.*, 2006) who found that, there was a statistically significant trend of increasing Ki67 expression from large regenerative nodule, dysplastic nodule to hepatocellular carcinoma, and with (Quaglia *et al.*, 2006) who reported that Ki67 could represent a valuable tool in the understanding of HCC progression in cirrhosis

Conclusion

We concluded that, there is a role of HSP70, CD34 and Ki-67 in differentiation of non-neoplastic liver cirrhotic lesions and early HCC and these markers can be used as predictors of biologic behavior of HCC. We recommended performing prospective studies with clinical correlation between these markers and the

progression of HCC with large series of patients.

REFERENCES

- Aileen Wee. (2011): Fine-Needle Aspiration Biopsy of Hepatocellular Carcinoma and Related Hepatocellular Nodular Lesions in Cirrhosis: Controversies, Challenges, and Expectations. 587936:17.
- Amal Fawzy, Hatem Attia, Fatma A Khalaf, Eman Abd El Sameea, Mahmoud A El Tahawy4, Mohamed Fara and Fatma Younis (2013): Heat Shock Protein-70 and -27 Expressions as Parameters of Early Diagnosis and Disease Progression in Hepatocellular Carcinoma. Life Science Journal 10(1):262-268
- Amarapurkar AD, Vibhav, Kim V (2008): Angiogenesis in liver cirrhosis and hepatocellular carcinoma. Indian Journal of Pathology and Microbiology. Jul-Sep; 51(3):323-8.
- Cezar Stroescu, Adrian Dragnea, Bogdan Ivanov, Catalin Pechianu, Vlad Herlea, Olivia Sgarbura, Andria Popescu and Irinel Popescu (2008): Expression of P53, Bcl2, VEGF, Ki67 and PCNA and prognostic significance in hepatocellular carcinoma. Journal of Gastrointestin Liver Disease; 17 (4): 411-417.
- Chuma M, Sakamoto M, Yamazaki K, Ohta T, Ohki M, Asaka M and Hirohashi S (2003): Expression profiling in multistage hepatocarcinogenesis: identification of HSP70 as a molecular marker of early hepatocellular carcinoma. Hepatology; 37: 198-207.
- De Boer M.B.B.S, W. Bastiaan M.B.B.S. *, Amanda Segal M.B.B.S., Felicity A Frost

- M.B.B.S. and Gregory F. Sterrett M.B.B.S (2000): Cancer Cytopathology Volume 90, Issue 5, pages 273–278, 25
- Di Tommaso L, Giada Franchi, Young Nyun Park, Barbara Fiamengo, Annarita Destro, Emanuela Morengi, Marco Montorsi, Guido Torzilli, Maurizio Tommasini, Luigi Terracciano, Luigi Tornillo, Raffaella Vecchione and Massimo Roncalli (2007): Diagnostic value of HSP70, glypican 3, and glutamine synthetase in hepatocellular nodules in cirrhosis. *Hepatology*; 45:725–734
- Ding T, Xu J, Zhang Y, (2011): Endothelium-coated tumor clusters are associated with poor prognosis and micrometastasis of hepatocellular carcinoma after resection [published online ahead of print April 8, 2011]. *Cancer*. 117:4878–4889. DOI 10.2478/v10307-012-0006-x 33 – 37
- Du JL1, Wei LX, Wang YL (2011): [Expression and clinicopathologic significance of GPC3 and other antibodies in well-differentiated hepatocellular carcinoma]. *Zhonghua Bing Li Xue Za Zhi*. 40(1):11-6.
- Effendi K and Sakamoto (2010): M Molecular Pathology in Early Hepatocarcinogenesis. *Oncology* 78:157–160.
- El-Din HG, Ghafar NA, Saad NE, Aziz M, Rasheed D, Hassan EM (2010): Relationship between codon 249 mutation in exon 7 of p53 gene and diagnosis of hepatocellular carcinoma. *Archives of Medical Science*. 30; 6(3):348-55.
- Elena Mocanu1, V. Broască2, Beatrice Severin (2012): Ki-67 Expression In Hepatocellular Carcinoma Developed On A Liver Cirrhosis *ARS Medica Tomitana* 1;(68):
- El-Zayadi AR, Badran HM, Barakat EM, Attia Mel-D, Shawky S, Mohamed MK, Selim O, Saeid A (2005): Hepatocellular carcinoma in Egypt: a single center study over a decade. *World Journal of Gastroenterology*, 7; 11(33):5193-8.
- Libbrecht L, Severi T, Cassiman D, Vander Borcht S, Pirenne J, Nevens F, Verslype C, Van Pelt J, and Roskams T (2006): Glypican 3 expression distinguishes small hepatocellular carcinomas from cirrhosis, dysplastic nodules and focal nodular hyperplasia – like nodules. *American Journal of Surgical Pathology* 30 (11): 1405-1411.
- Luca Di Tommaso, Giada Franchi, Young Nyun Park, Barbara Fiamengo, Annarita Destro, Emanuela Morengi, Marco Montorsi, Guido Torzilli, Maurizio Tommasini, Luigi Terracciano, Luigi Tornillo, Raffaella Vecchione and Massimo Roncalli (2007): Diagnostic value of HSP70, glypican 3, and glutamine synthetase in hepatocellular nodules in cirrhosis. *Hepatology*; 45:725–734
- Mary Macstay, Stoeber K, Loddo M, Caplin M, Fanshawe T, and Dhillon A (2006): Novel markers of cell kinetics to evaluate progression from cirrhosis to hepatocellular carcinoma. *Liver international*; 26(4): 424-432.

- Masanori S, Takeshi T, Kazuyuki M, Mazahiko S, Masamichi O, Yoshio K, Tadakazu M, Shigetsugu T, Akira T, Hideyuki Y, Msayuki O, Mazakazu Y, Mazayuki N, Masaru M, and Fumio N (2008): Identification of Novel Immunohistochemical Tumor Markers for primary hepatocellular carcinoma. *Hepatology*; 48: 519-530
- Paschoal JP, Bernardo V, Canedo NH, Ribeiro OD, Caroli-Bottino A, Pannain VL1 (2014): Microvascular density of regenerative nodule to small hepatocellular carcinoma by automated analysis using CD105 and CD34 immunoexpression. *BMC Cancer*. Feb 7; 14:72.
- Quaglia A, McStay M, Stoeber K, Loddo M, Caplin M, Fanshawe T, Williams G, Dhillon A (2006): Novel markers of cell kinetics to evaluate progression from cirrhosis to hepatocellular carcinoma. *Liver International* 26(4):424-32.
- Rajagopal N, Ravalli, Clifford J. Steer, and Erik N.K. Cressman (2008): Molecular mechanisms of Hepatocellular Carcinoma. *Hepatology*; 48: 2047-2063.
- Shin E, Ryu HS, Kim SH, Jung H, Jang JJ, Lee K (2011): The clinicopathological significance of heat shock protein 70 and glutamine synthetase expression in hepatocellular carcinoma. *Journal of Hepatobiliary Pancreatic Sciences* 18(4):544-50.
- Tsuji N1, Ishiguro S, Sasaki Y, Kudo M (2013): CD34 expression in noncancerous liver tissue predicts multicentric recurrence of hepatocellular carcinoma. *Dig Disease* 31(5-6):467-71.
- Wang F1, Jing X, Wang T, Li G, Li T, Zhang Q, Huang Y, Li J, Wang Y, Gao Y, Han T, Du Z (2012): Differential diagnostic value of GPC3-CD34 combined staining in small liver nodules with diameter less than 3 cm. *American Journal of Clinical Pathology* 137(6):937-45.
- Wee A and Sampatanukul P (2004): *Fine Needle Aspiration Cytology of the Liver. Diagnostic Algorithms. A Southeast Asian Perspective*, Year Book Publisher, Bangkok, Thailand.
- Yang X, Wang J, Zhou Y, Wang Y, Wang S, Zhang W (2012): Hsp70 promotes chemoresistance by blocking Bax mitochondrial translocation in ovarian cancer cells. *Cancer Letters*. 13:137-143.
- Yang XR, Xu Y, Yu B (2010): High expression levels of putative hepatic stem/progenitor cell biomarkers related to tumor angiogenesis and poor prognosis of hepatocellular carcinoma. *Gut*. 59:953-962.
- Yao Y, Pan Y, Chen J, Sun X, Qiu Y, Ding Y (2007): Endoglin [CD105] expression in angiogenesis of primary hepatocellular carcinomas: analysis using tissue microarrays and comparisons with CD34 and VEGF. *Annals of Clinical Laboratory Science* 14:39-48.