

# Role of Magnetic Resonance Imaging in Diagnosis and Staging of Uterine Cervical Carcinoma

Ahmed F Abdel Ghany, Mona A Abdel Wahed, Waleed K AL-Habash

Radiodiagnosis, Faculty of Medicine – Ain Shams University

Corresponding author: Waleed K Al-Habash; Mobile: 01140213300; Email: [waleedhabash63@gmail.com](mailto:waleedhabash63@gmail.com)

## ABSTRACT

**Background:** MRI examination is a useful modality for staging and evaluation of gynecologic malignancy. The diffusion-weighted MR imaging (DW-MRI or DWI) method has been introduced to cancer diagnostics, and has widened the diagnostic capabilities of MRI. Functional information from DWI and DCE-MRI can supplement morphologic information obtained with conventional cross-sectional imaging methods.

**Aim of the Work:** The aim of the present study is to evaluate the role of MRI in the diagnosis & staging of uterine cervical cancer & to assess the value of apparent diffusion coefficient (ADC) in the studied individuals.

**Patients and Methods:** This prospective study included twenty two patients with clinically suspected cervical cancer and twenty two apparently healthy women with normal MRI appearance of the cervix. It was conducted in El-Demerdash Hospital. The patients were referred from the Gynecology Department to the Radiology Department (Women's Imaging Unit) for further MRI assessment with DWIs. Ten patients were followed up after receiving chemo-radiotherapy. **Results:** There was a high statistical difference between cervical cancer patients (Before-treatment) and control group according to ADC Value. There was a high statistical difference between cervical cancer patients (post-treatment) and control group according to ADC Value. In addition, there was a high statistical difference between cervical cancer patients (pre-treatment) and (post-treatment) according to ADC Value. The comparative study between ADC values versus tumor size and between ADC values versus histopathological result (types and grading) of the tumor was statistically non-significant. **Conclusion:** DWI serves as a functional technique, which provides information about water mobility, tissue cellularity, and stability of membrane integrity that can discriminate cervical carcinoma from healthy tissue, and increasing the radiologist's confidence in image interpretation. Therefore, it implies a non-invasive technique, which can be used especially if contrast intake is avoided as in pregnancy. ADC values are reliable for differentiating cervical cancer from normal cervix with higher diagnostic accuracy when added to DWI interpretation. **Recommendations:** Further studies on a larger scale of patients are needed to confirm the results obtained by this work.

**Keywords:** MRI, uterine cervical carcinoma.

## INTRODUCTION

Cervical cancer is the third most commonly diagnosed cancer worldwide and the fourth leading cause of cancer death in women<sup>(1)</sup>.

Most women with cervical cancer are diagnosed before the age of 50 years old. However, older women remain at risk. Cervical cancer is both preventable and, treatable if identified early<sup>(2)</sup>. The staging system of the International Federation of Gynecology and Obstetrics (FIGO) which is most commonly used, accept the use of Magnetic Resonance Imaging (MRI) as an adjunct to clinical staging. Also, the guidelines from European Society of Urogenital Radiologist (ESUR) recommend using MRI for staging of cervical cancer and follow up<sup>(3)</sup>. The role of MRI in gynecological oncology has evolved over the past several years<sup>(4)</sup>. MRI with a good soft tissue contrast and multi-planar imaging capability is an optimal method for evaluation of gynecologic malignancies including cervical cancer. MRI is obviously better than computed tomography for loco-regional disease assessment, especially for primary tumor and adjacent soft tissue extension<sup>(5)</sup>. Moreover, MRI allows accurate identification of stromal and parametrial invasion, the exact volume, shape, direction of the primary lesion and nodal status, which helps the clinician in treatment planning<sup>(6)</sup>. MRI Diffusion-Weighted Image (DWI) enables

noninvasive characterization of biological tissues based on the properties of water diffusion, and thus can provide micro-structural information on the cellular level<sup>(7)</sup>. This modality is helpful in initial staging of known malignancies, differentiating benign from malignant lesions, assessing treatment response, and determining the presence of disease recurrence. Thus, DWI becomes increasingly important in the evaluation of cervical cancer patients<sup>(8)</sup>. **Lucas and Cunha**<sup>(9)</sup> suggested DWI as an excellent tool for identification of small even a few mm sized lymph nodes. Also the combination of DWI & T2-weighted image in identification of parametrial extension & recurrent disease found to be more accurate than using T2-weighted image alone. New advanced MRI techniques may be helpful for developing optimal diagnosis & therefore optimal therapy for patient with cervical cancer.

### Aim of the work

The aim of the present study is to evaluate the role of MRI in the diagnosis & staging of uterine cervical cancer & to assess the value of ADC in the studied individuals.

## PATIENTS AND METHODS

### Patients:

This prospective study included twenty two patients with clinically suspected cervical cancer and twenty

two apparently healthy women with normal MRI appearance of the cervix.

The study was conducted in El-Demerdash Hospital.

The patients were referred from the Gynecology Department to the Radiology Department (Women's Imaging Unit) for further MRI assessment with DWIs. Ten patients were followed up after receiving chemo-radiotherapy.

#### **Inclusion criteria:**

- Twenty-two cervical cancer patients aged 40 - 73 years old, presented with abnormal vaginal bleeding. The patients were diagnosed by clinical examination and by trans-vaginal ultrasound.
- Twenty-two apparent healthy patients with normal MRI of the cervix.

#### **Exclusion criteria:**

Any electrically, magnetically or mechanically activated implants such as cardiac pacemakers, cochlear implants, hearing aids, ferromagnetic surgical clips, staples, metallic foreign body in the eye.

#### **Methods:**

All women were subjected to the following:

- I. Full history taking.
- II. Clinical examination by the referring clinician.
- III. Pelvic MRI study.

#### **Protocol of MR Imaging**

##### **1. Patient preparation:**

Intravenous administration of an antispasmodic drug (Buscopan) was given immediately before MR imaging to reduce motion artifacts caused by peristalsis and to attenuate uterine contractions. All patients are requested to fast for 6 hours before the examination; no special bowel preparation is required, with moderate bladder filling to straighten an ante flexed uterus, as full bladder may lead to restlessness during the course of the examination.

##### **2. MRI technique:**

The study were performed on 1.5 T MRI machine using body coil (phased array coil), images were obtain in a supine position. The standard MRI sequences included:

##### **A. Conventional MRI:**

- Sagittal T2-weighted turbo spin-echo (TR/TE of 3500/80 ms, field of view of 350×328 mm, matrix size of 320×162, 4.5mm slice thickness, and 4.5 mm intersection gap).
- Coronal T2-weighted turbo spin-echo (TR/TE of 8630/115 ms, field of view of 220×220 mm, matrix size of 216×150, 3 mm slice thickness, and 3.0 mm intersection gap).
- Axial T2-weighted turbo spin-echo (TR/TE of 10055/115 ms, field of view of 340×406 mm, matrix size of 332×299, 3 mm slice thickness, and 3 mm intersection gap).

- Axial T1-weighted turbo spin-echo (TR/TE of 550/24 ms, field of view of 340×406 mm, matrix size of 284×266, 3 mm slice thickness, and 3 mm intersection gap).

##### **B. DW-MRI:**

DW-MRI was performed using single-shot spin-echo planar imaging, immediately after the axial T2-weighted image and before intravenous contrast injection. It was acquired in free breathing with background body signal suppression (presaturation inversion recovery fat suppression) using the following parameters: TR/TE of 1688 / 64 ms, field of view of 340×340 mm, 112×100 matrix size, 3 mm slice thickness, and 1.5 mm intersection gap. We acquired b-values at 0, 400 and 800 s/mm<sup>2</sup> in the axial plane covering 20 slices to include the entire cervical cancer. We ensured that the field of view, slice thickness and intersection gap were the same as the anatomical axial T2-weighted imaging to allow image overlay and co-registration. Regarding the quantitative analysis of DWI, we generated the ADC map, and then we selected the region of interest (ROI) manually, which was then automatically calculated on the work station to get a mean ADC value providing a measurement in square millimeters per second (mm<sup>2</sup>/sec). ADC maps should always be reviewed with diffusion-weighted images to avoid pitfalls from T2 shine-through and water restriction in normal tissues or highly cellular benign tumors<sup>(10)</sup>. ADC maps were calculated from DW images that were previously assessed. In the patient group, ADC measurements were executed on reconstructed ADC maps performed with the ROI within the tumor. Macroscopic necrotic areas (fluid signal on T2), large vessels and areas with susceptibility artifact caused by air-water interface were excluded from the ROI. The greatest dimension of the tumor was measured. ROIs were set up three times and the average of them was used for each ADC value measurement in the malignant masses.

##### **C. Dynamic study:**

Dynamic study was performed after intravenous bolus injection of 0.1 mmol/ kg body weight of Gd-DTPA at a rate of 2 ml/ s, flushed with 20 ml of sterile 0.9 % saline solution in the antecubital vein.

- Axial T1-weighted turbo-field-echo contrast-enhanced acquisition (TR/TE of 1632/7 ms, field of view of 340×403 mm, 300×301 matrix size, 3 mm slice thickness, and 3 mm intersection gap).
- Coronal T1-weighted turbo-field-echo contrast-enhanced acquisition (TR/TE of 1523 / 7 ms, field of view of 220×220 mm, 200×160 matrix size, 3 mm slice thickness, and 3 mm intersection gap).
- Sagittal T1-weighted turbo-field-echo contrast-enhanced acquisition (TR/TE of 906 / 7 ms, field of view of 250×329 mm, 228×240 matrix size, 3.5 mm slice thickness, and 3.5 mm intersection gap).

**Table (1):** The MRI sequences used in the study are listed in the following table

Sequence	TR (m/sec.)	TE (m/sec.)	FOV (mm)	Matrix	Slice thickness (mm)	Slice gap (mm)
T2 sagittal	3500	80	350x328	320x162	4.5	4.5
T2 coronal	8630	115	220x220	216x150	3	3
T2 axial	10055	115	340x406	332x299	3	3
T1 axial	550	24	340x406	284x266	3	3
DWI (b: 0, 400, 800) axial	1688	64	340x340	112x100	3	1.5
T1 axial post contrast	1632	7	340x403	300x301	3	3
T1 coronal post contrast	1523	7	220x220	200x160	3	3
T1 sagittal post contrast	906	7	250x329	228x240	3.5	3.5

**3. MRI finding analysis:**

Characterization and staging of the cervical mass by MRI: appearance of the tumor:

1. Signal intensity of the mass.
2. Enhancement of the mass.
3. Size of the lesion.
4. Involvement of other pelvic organs.
5. DWI of cervical cancer demonstrates diffusion restriction.
6. Presence of infiltrated pelvic or para aortic lymph nodes & the peritoneal or omental deposits or hydronephrosis.
7. Presence of ascites.

A combination of T2-weighted MR imaging sequence and dynamic post contrast MR imaging was used in staging of cervical carcinoma. The MRI staging followed the FIGO staging analysis.

**Histopathological analysis:**

It was done for each patient with cervical cancer which was then correlated with MRI finding.

**Statistical analysis**

Recorded data were analyzed using the statistical package for social sciences, version 20.0 (SPSS Inc., Chicago, Illinois, USA). Quantitative data were expressed as mean ± standard deviation

(SD). Qualitative data were expressed as frequency and percentage.

**The following tests were done:**

- Independent-samples t-test of significance was used when comparing between two means.
- Paired sample t-test of significance was used when comparing between related samples.
- A one-way analysis of variance (ANOVA) when comparing between more than two means.
- Chi-square ( $\chi^2$ ) test of significance was used in order to compare proportions between two qualitative parameters.
- The confidence interval was set to 95% and the margin of error accepted was set to 5%. So, the p-value was considered significant as the following:
  - Probability (P-value)
  - P-value <0.05 was considered significant.
  - P-value <0.001 was considered as highly significant.
  - P-value >0.05 was considered insignificant.

**RESULTS**

This study included twenty two cancer cervix patients with mean age 53 years, and control individual with their mean age 52 years.

**Table (2):** Statistical comparison between age (years) in patient and control groups.

Age (years)	Patients (N=22)		Control (N=22)		Chi-square test		Significance
	No.	%	No.	%	$\chi^2$	p-value	
40-49	9	40.9%	12	54.5%	1.121	0.571	N.S.
50-59	8	36.4%	5	22.7%			
≥60	5	22.7%	5	22.7%			

N.S.: non-significant difference

This table showed no statistically significant difference between patients group and control group as regards age.

**Table (3):** Descriptive data as regards tumor size distribution of cancer cervix patients group.

Tumor size /cm <sup>3</sup>	Patients (n=22)	%
<3	5	22.7%
3-6	9	40.9%
>6	8	36.4%
Range [Mean ± SD]	1.62-6.73 [4.89 ± 1.64]	

This table showed that five cancer cervix patients (22.7%) had tumor size < 3 cm<sup>3</sup>, nine cancer cervix patients (40.9%) had tumor size between 3-6 cm<sup>3</sup>, and eight cancer cervix patients (36.4%) had tumor size > 6 cm<sup>3</sup>.

**Table (4):** Descriptive data of different histopathology types and grade of cancer cervix patients group

Histopathology Result	Cancer cervix patients	
	(n= 22)	%
Adenocarcinoma GII	2	9.1%
SCC GII	6	27.3%
SCC GIII	14	63.6%

GII: moderately differentiation tumor, GIII: poorly differentiation tumor, SCC: squamous cell carcinoma

This table demonstrated that, two cancer cervix patients (9.1%) had adenocarcinoma GII, six cancer cervix patients (27.3%) had SCC GII, and fourteen cancer cervix patients (63.6%) had SCC GIII of histopathology results.

**Table (5):** Descriptive data of different MRI stages among the cancer cervix patients group according to FIGO classification.

MRI Stage	Cancer cervix patients	
	(n= 22)	%
IB	2	9.1%
IIA	3	13.6%
IIB	7	31.8%
IIIA	1	4.5%
IIIB	4	18.2%
IVA	5	22.7%

This table showed that, two cancer cervix patients (9.1%) had MRI stage IB, three cancer cervix patients (13.6%) had MRI stage IIA, seven cancer cervix patients (31.8%) had MRI stage IIB, one cancer cervix patients (4.5%) had MRI stage IIIA, four cancer cervix patients (18.2%) had MRI stage IIIB and five cancer cervix patients (22.7%) had the stage IVA.

**Table (6):** Statistical comparison between ADC value in cancer cervix patients (before treatment) and control groups.

ADC Value	patients(Before therapy) (N=22)	Control (N=22)	t-test	p-value
Mean ± SD (mm <sup>2</sup> /sec)	0.70 ± 0.09	1.60 ± 0.05	1850.76	<0.001**
Range	0.55-0.84	1.5-1.67		

\*\* Highly Significant Difference.

This table demonstrated a high statistical difference between cervical cancer patients (before treatment) and control groups according to ADC Value.

**Table (7):** Statistical comparison between ADC value in cancer cervix patients (post-treatment) and control groups.

ADC value	post-treatment patient (N=10)	Control (N=22)	t-test	p-value
Mean ± SD mm <sup>2</sup> /sec	1.02 ± 0.09	1.60 ± 0.05	557.01	<0.001**
Range	0.9-1.15	1.5-1.67		

\*\* Highly Significant Difference.

This table demonstrated a high statistical difference between cervical cancer patients (post-treatment) and control groups according to ADC Value.

**Table (8):** Statistical comparison between ADC value in cancer cervix patients (pre-treatment) and (post – treatment).

ADC value	Pre-treatment (N=10)	Post- treatment (N=10)	t-test	p-value
Mean ± SD mm <sup>2</sup> /sec	0.70 ± 0.09	1.02 ± 0.09	10.354	<0.001**
Range	0.59-0.84	0.9-1.15		

\*\* Highly Significant Difference.

This table demonstrated a high statistical difference between cervical cancer patients (pre-treatment) and (post-treatment) according to ADC Value.

**Table (9):** Correlation between ADC value in cancer cervix patients group (pre-treatment) and its tumor size

Tumor size (cm <sup>3</sup> )	ADC value Pre-treatment		ANOVA test	
	Mean mm <sup>2</sup> /sec	± SD	x2	p-value
<3	0.686	0.050	0.789	0.469
3-6	0.732	0.088		
> 6	0.685	0.099		

This table showed that the mean ADC value was 0.686 when cancer cervix size was <3 cm<sup>3</sup>, the mean ADC value was 0.732 when cancer cervix size was between (3-6 cm<sup>3</sup>) and the mean ADC value was 0.685 when cancer cervix size was >6 cm<sup>3</sup>. No statistically significant relation between ADC value and tumor size in patients (Pre-treatment) group.

**Table (10):** Correlation between ADC value in cancer cervix group (pre- treatment) and its histopathological result

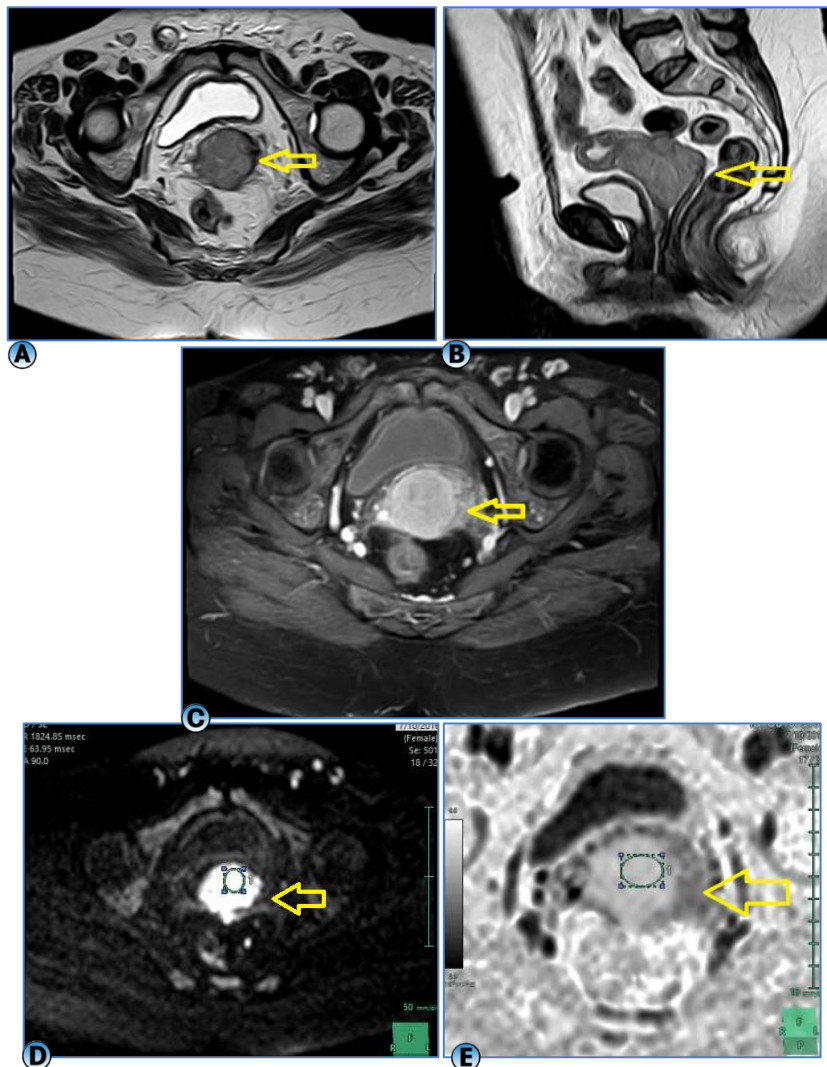
Histopathology Result	ADC value Pre-treatment		ANOVA test	
	Mean mm <sup>2</sup> /sec	±SD	x <sup>2</sup>	p-value
Adenocarcinoma GII	0.675	0.177	1.432	0.264
SCC GII	0.753	0.102		
SCC GIII	0.688	0.061		

This table demonstrated a high statistical difference between cervical cancer patients (pre-treatment) and (histopathology results) according to ADC Value.

**ILLUSTRATIVE CASES**

**CASE 1**

A 65 years old, female patient complaining of post-menopausal bleeding for more than two months. Pathologically diagnosed as cervical squamous cell carcinoma grade II. A conventional MRI/DWI displayed a malignant looking cervical mass lesion measuring of about (4.0×5.0×6.0) cm, that had grown beyond the cervix, but hasn't spread to the walls of the pelvis or the lower part of the vagina. The lesion had not spread into the tissues next to the cervix (the parametria). It has not spread to nearby lymph nodes (N0) or distant sites (M0), **stage IIA.**



**Figure (1):** MRI (A) axial T2 WI, (B) sagittal T2 WI show mass in cervix, display moderate signal intensity, there is no interruption of the low signal stream indicating no parametrial invasion, (C) axial T1 post contrast show heterogeneous contrast enhancement, (D) DWI show restricted diffusion and (E) ADC map, ADC value (0.85× 10<sup>-3</sup>mm<sup>2</sup>/s).

## DISCUSSION

According to **Duenas-Gonzalez et al.** <sup>(1)</sup>, cervical cancer is the third most commonly diagnosed cancer worldwide and the fourth leading cause of cancer death in women.

**Ferlay et al.** <sup>(2)</sup> reported that most women with cervical cancer are diagnosed before the age of 50. However; older women remain at risk. Cervical cancer is both preventable and, easily treatable if identified early. **Balleyguier et al.** <sup>(3)</sup> stated that the staging system of FIGO, which is most commonly used, accepted the use of MRI as an adjunct to clinical staging. In addition, ESUR guidelines recommend using MRI for staging of cervical cancer and follow up. **Bhosale et al.** <sup>(11)</sup> reported that MRI depicts the morphological details of the female pelvis and is useful for evaluating both benign and malignant cervical masses.

**Petsuksiri et al.** <sup>(5)</sup> reported that MRI has an important role in assessing local extent and distant spread of cancer due to its excellent soft tissue and high contrast resolution that enables differentiation between cancerous and normal tissues. Moreover, it has wide field of view by the multi cross sections (axial, coronal, and sagittal) and lack of ionizing radiation in comparison to CT scan. It is also far more reliable than physical examination in assessing tumor size. **Koh et al.** <sup>(12)</sup> stated that functional imaging had been integrated in the evaluation of cancer patients to overcome the limitations of morphological imaging. DWI as one of the valuable functional imaging technique can display information about water mobility, tissue cellularity and the integrity of the cellular membranes.

DWI is a noninvasive technique based on molecular diffusion combined with conventional T2W imaging that enables morphologic assessment with a relatively short scanning time and physiologic changes in a single examination. It also allows quantitative evaluation of ADC from images with different b-values. Furthermore, it provides tissue contrast, so it is considered an excellent choice in cases where contrast administration is not possible <sup>(13)</sup>. **Kitajima et al.** <sup>(14)</sup> reported that DWI with quantitative ADC value is an interesting approach in evaluating malignancies, which allow differentiating the normal uterine cervix from cervical cancer and benign lymph nodes from malignant ones. A combination of increased extracellular tortuosity and the ratio of intracellular to extracellular water fraction may be the best biological explanation for the decreased ADCs in the cancer tissues.

DWI has been used also to localize the tumor. DWI was useful to detect even small-volume cervical cancer of stage IA or IB compared with conventional MRI <sup>(15)</sup>. **Galbán et al.** <sup>(16)</sup> stated that DWI is very promising in evaluating early treatment response. As diffusion within tumors is impeded by

the presence of cellular membranes and macromolecular structures, treatment with radiation and/or chemotherapy can result in the loss of cell membrane integrity, which can be detected as an increase in mean diffusion value for the tumor, Thus, DW-MRI can provide microstructural information on the cellular level. Animal and clinical studies have revealed that successful treatments of a wide variety of tumor types can be detected as an increase in tumor ADC values due to the loss of cellular density.

Our study included twenty two healthy women and twenty two cervical cancer patients diagnosed clinically and by trans vaginal U/S. Pelvic MRI with DWI that were done for all subjects.

The histopathological result of twenty two patients demonstrated that two cancer cervix patients (9.1%) had adenocarcinoma GII, six cancer cervix patients (27.3%) had SCC GII, and fourteen cancer cervix patients (63.6%) had SCC GIII. Only Ten patients were followed up after completion there radio-chemo therapy. Data of present study revealed statistically significant lower ADC value in cervical cancer patients before receiving radio-chemo therapy as compared to healthy control women. This is in agreement with study conducted by **Kuang et al.** <sup>(17)</sup> to evaluate the potential value of ADC measurement in the assessment of cervical cancer on 112 patients with cervical cancer and 67 control subjects underwent DWI in addition to MR imaging at 3.0-T MRI. The ADCs of cervical cancer were significantly lower than those of normal cervix ( $P < 0.001$ ).

The underlying mechanism of quantitative measurement of ADC value in cancer cervix patients was explored in an earlier study carried out by **Kitajima et al.** <sup>(14)</sup>. They claimed that, the apparent diffusion coefficient reflects cellularity of the tissue, and may be helpful to differentiate relatively hypercellular cervical cancer from normal cervical and benign cervical lesions, in which edematous tissue and abundant cystic components may widen the extracellular space and increase the ADC. Our mean ADC value in cervical carcinoma was ( $0.70 \times 10^{-3} \text{ mm}^2/\text{sec}$ ) this is compatible with **Kitajima et al.** <sup>(14)</sup> where the mean ADC of uterine cervical cancer of 20 cases was  $0.86 \times 10^{-3} \text{ mm}^2/\text{sec}$ . Moreover, our current study revealed statistically significantly lower value of ADC in cervical cancer patients after receiving there radio-chemo therapy compared to the control. Also, a high statistically significant difference in ADC value among cervical cancer patients before and after chemo-radio therapy. Similar result was reported by **Chen et al.** <sup>(18)</sup> where 33 patients with cervical carcinoma and 20 control patients underwent diffusion-weighted imaging in addition to MR imaging. The ADC values of normal cervical tissue, cervical area before and after chemo-radiotherapy were measured and compared. The mean ADC value of cervical carcinoma ( $1.110 \times 10^{-3} \text{ mm}^2/\text{s}$ ) was



significantly lower than that of normal cervical tissue ( $1.593 \times 10^{-3} \text{ mm}^2/\text{s}$ ) ( $P < 0.001$ ). The mean ADC value of the cervical area in 22 patients treated by chemo-radiotherapy ( $1.436 \times 10^{-3} \text{ mm}^2/\text{s}$ ) was significantly higher than that before therapy ( $1.013 \times 10^{-3} \text{ mm}^2/\text{s}$ ) ( $P < 0.001$ ). The difference of ADC values between normal cervical tissue and cervical area after therapy was statistically significant ( $P < 0.01$ ). The comparative study between ADC values versus tumor size and between ADC values versus histopathological result (types and grading) of the tumor was statistically non-significant. This was consistent with finding of **Demirbaş *et al.*** <sup>(19)</sup> where their study included 25 patients who had cervical cancer proved histopathologically, and 20 patients with otherwise normal uterus. The mean ADC values of cervical cancer ( $0.96 \times 10^{-3} \text{ mm}^2/\text{sec}$ ) were statistically lower than that of the control group ( $1.65 \times 10^{-3} \text{ mm}^2/\text{sec}$ ). According to histopathological subtypes, there was no significant difference between mean ADC values of squamous cell cancer and adenocarcinoma ( $0.95 \times 10^{-3} \text{ mm}^2/\text{sec}$  and  $0.91 \times 10^{-3} \text{ mm}^2/\text{sec}$ , respectively). This is similar to our results in which the mean ADC values of cervical cancer ( $0.70 \times 10^{-3} \text{ mm}^2/\text{sec}$ ) were statistically lower than that of the control group ( $1.60 \times 10^{-3} \text{ mm}^2/\text{sec}$ ), with no significant difference between mean ADC values of different histological sub types.

## CONCLUSION

Diffusion-weighted MR imaging (DWI) serves as a functional technique, which provides information about water mobility, tissue cellularity, and stability of membrane integrity that can discriminate cervical carcinoma from healthy tissue. In addition, it increases the radiologist's confidence in image interpretation. Therefore, it implies a non-invasive technique that can be used especially if contrast intake is avoided as in pregnancy. Besides, ADC values were reliable for differentiating cervical cancer from normal cervix with higher diagnostic accuracy when added to DWI interpretation.

## REFERENCES

- 1) **Duenas-Gonzalez A, Serrano-Olvera A, Cetina L *et al.* (2014):** New molecular targets against cervical cancer. *International Journal of Women's Health*, 6: 1023-1031.
- 2) **Ferlay J, Soerjomataram I, Eevik M *et al.* (2013):** GLOBOCAN 2012 v1.0, Cancer incidence and mortality worldwide. Lyon, France: International Agency for Research on cancer, IARC Cancer Base, 136(5):359-86.
- 3) **Balleyguier C, Sala E, Da Cunha T *et al.* (2010):** Staging of uterine cervical cancer with MRI: guidelines of the European Society of Urogenital Radiology. *Eur Radiol.*, 21(5): 1102-1110.
- 4) **Patel S, Liyange SH, Sahdev A *et al.* (2010):** Imaging of endometrial and cervical cancer. *PMC US National Library of Medicine*, 1 (5-6): 309 -328.
- 5) **Petsuksiri J, Jaishuen A, Pattaranutaporn P, Chansilpa Y (2012):** Advanced imaging applications for locally advanced cervical cancer. *Asian Pacific Journal of Cancer Prevention*, 13(5): 1713-1718.
- 6) **Mahajan M, Kuber R, Chaudhari KR, Chaudhari P, Ghadage , Naik R (2013):** MR imaging of carcinoma cervix. *Indian journal of radiology and imaging*, 23(3): 274-252.
- 7) **Chilla GS, Tan CH, Xu C, Poh CL (2015):** Diffusion weighted magnetic resonance imaging and its recent trend— a survey. *Quantitative imaging in medicine and surgery*, 5(3): 407.
- 8) **Whittaker C, Coady A, Culver L *et al.* (2009):** Diffusion-weighted MR Imaging of Female Pelvic Tumors: A Pictorial Review. *Radiographics*, 29: 759-774.
- 9) **Lucas R, Dias JL, Cunha TM (2015):** Added value of diffusion-weighted MRI in detection of cervical cancer recurrence: comparison with morphologic and dynamic contrast-enhanced MRI sequences. *Diagnostic and Interventional Radiology*, 21(5): 368.
- 10) **Freeman S, Aly A, Kataoka M *et al.* (2012):** The Revised FIGO Staging System for Uterine Malignancies: Implications for MR Imaging. *Radiographics*, 32: 1805–1827.
- 11) **Bhosale PR, Iyer RB, Ramalingam P *et al.* (2016):** Is MRI helpful in assessing the distance of the tumor from the internal os in patients with cervical cancer below FIGO Stage IB2. *Clinical radiology*, 71(6): 515-522.
- 12) **Koh DM, Takahara T, Imai Y, Collins DJ (2007):** Practical aspects of assessing tumours using clinical diffusion-weighted imaging in the body. *Magnetic Resonance in Medical Sciences*, 6(4): 211-24.
- 13) **Levy A, Caramella C, Chargari C *et al.* (2011):** Accuracy of diffusion-weighted echo-planar MR imaging and ADC mapping in the evaluation of residual cervical carcinoma after radiation therapy. *Gynecol Oncol.*, 123: 110–115.
- 14) **Kitajima K, Yamasaki E, Kaji Y, Murakami K, Sugimura K (2012):** Comparison of DWI and PET/CT in evaluation of lymph node metastasis in uterine cancer. *World journal of radiology*, 4(5): 207.
- 15) **Harry VN (2010):** Novel imaging techniques as response biomarkers in cervical cancer. *Gynecol Oncol.*, 116: 253–261.
- 16) **Galbán CJ, Hoff BA, Chenevert TL, Ross BD (2017):** Diffusion MRI in early cancer therapeutic response assessment. *NMR Biomed.*, 30(3): 217-222.
- 17) **Kuang F, Yan Z, Li H *et al.* (2015):** Diagnostic accuracy of diffusion-weighted MRI for differentiation of cervical cancer and benign cervical lesions at 3.0 T: Comparison with routine MRI and dynamic contrast-enhanced MRI. *Journal of Magnetic Resonance Imaging*, 42(4): 1094-1099.
- 18) **Chen J, Zhang Y, Liang B, Yang Z (2010):** The utility of diffusion-weighted MR imaging in cervical cancer. *European journal of radiology*, 74(3): e101-6.
- 19) **Demirbaş T, Cimilli T, Bayramoğlu S, Güner NT, Hocaoğlu E, Inci E (2014):** Contribution of diffusion-weighted imaging to diagnosis and staging of cervical cancer. *Balkan Med J.*, 31: 154–157.