

Role of 320 Detector Row CT Perfusion in Assessment of Myocardial Perfusion

Fatma Salah Eldin, Omar Farouk Kamel, Ahmed Hassan Soliman, Nadin Fawzy Abd Elaziz

Radiodiagnosis Department, Ain Shams University, Cairo ,Egypt

Corresponding Author Nadin Fawzy Abd Elaziz, Email: sallyhatim2005@gmail.com.Tel.01225161312

ABSTRACT

Aim of the work: this study aimed to evaluate the coronary artery morphology and myocardial perfusion by single reproducible non-invasive contrast enhanced CT acquisition by using DECT scanners with high sensitivity and specificity as well as high diagnostic accuracy without the need to increase the contrast material or radiation dose.

Patients and Methods: this study was done during the period from October 2016 to December ,2017; age was ranged between 42 to 73 years old, were 35 patients with CAD diagnosed by cCTA underwent DECT for assessment of myocardial perfusion. The study included 35 patients referred for DECT myocardial perfusion examination in the Police Authority Hospitals, Radiodiagnosis Department in Cairo after diagnosing by cCTA. Each patient included in the study was subjected to full history taking, reviewing medical sheet, cCTA and CT myocardial perfusion examination. Technique was performed by using Aquilion one dynamic volume 320 detector rows CT, Toshiba Medical System, Tochigi-ken, Japan. **Results:** our study showed a significant correlation and good agreement between the findings of DECT myocardial perfusion defects and the findings of stenosis and its degree on cCTA on a segmental basis with 83% sensitivity, 87% specificity, 86% accuracy, 74% positive predictive value and 92% negative predictive value. **Conclusion:** DECT myocardial perfusion has high diagnostic as compared to cCTA as the gold reference standard.

Keywords: coronary CT angiography, dual energy CT (DECT) myocardial perfusion.

INTRODUCTION

Coronary artery disease (CAD) causes sudden death, nonfatal myocardial infarction, unstable angina⁽¹⁾. And it is believed to be the underlying cause in approximately two-thirds of patients with chronic heart failure (HF) and low ejection fraction (EF)⁽²⁾ where regional myocardial dysfunction leads to global ventricular dysfunction and heart failure over time⁽³⁾. Appropriate risk stratification and management of patients with acute MI required a comprehensive assessment of the coronary arteries, global and regional left ventricular (LV) function, and infarct size⁽⁴⁾. Currently, these data are acquired over several days of hospital admission, with the use of a variety of resources including echo-cardiography, cardiac magnetic resonance (MR) imaging⁽⁵⁾, invasive coronary angiography and single photon emission computed tomography (SPECT) imaging that have shown a sensitivity of 88% and specificity of 76% for the detection of CAD when compared with invasive coronary angiography⁽⁶⁾. With advances in multidetector computed tomography (CT) technology, multidetector CT scanners with sub-millimeter collimation and fast gantry rotation (330 msec), potentially permit a noninvasive assessment of coronary anatomy, global and regional LV function and perfusion defects (PDs) and delayed enhancement⁽⁶⁾ showed high sensitivity and specificity for detection of substantial coronary artery

stenosis by using multidetector CT as compared to invasive coronary angiography. While, promising reports on ventricular function and infarct imaging by using multidetector CT have been published, data on global LV function, regional wall motion (RWM), and PD assessment with multidetector CT in the acute MI setting are somewhat limited. If these assessments can be reliably obtained by using multidetector CT combined with CT coronary angiography, it may provide an excellent tool for the rapid noninvasive diagnostic and prognostic evaluation of patients with acute MI⁽⁷⁾.

PATIENTS AND METHODS

The study was conducted from October 2016 to December ,2017 ; 35 patients known to have CAD with and without ischemia. Their age ranged from 42 to 73 years. All patients were subjected to clinical examination and conventional imaging. Comprehensive explanations of the procedures were done for all patients, including the associated risks and contraindications.

Imaging:

Each patient included in the study subjected to:

- Full history taking.
- Reviewing medical sheet whenever available.

- Inclusion criteria: patients with known or suspected coronary artery disease, both sexes were included, no age predilection.
- Exclusion criteria: Patients with bad general condition needing life support, those with severe hepato-renal disease, patients known to have high serum creatinine, pregnant females, and with history of allergy to iodinated contrast material or history of reactive air way disease.
- Equipment: (320 detector rows) CT system (definition, Aquilion one dynamic volume CT; Toshiba medical system, Tochigi-ken, Japan).

Technique of DECT myocardial perfusion:

- The scan was acquired in a single breath hold during comfortable inspiration and starts with the injection of a contrast agent with a high concentration of iodine (300–400 mg/mL) at a high flow rate (4–6 mL/s). The total volume of contrast agent depended on the scan length, but typically 60–80 mL was injected, followed by a saline bolus (40–70 mL at 4–6 mL/s). Scan delay time was determined with the test bolus technique.
- After image acquisition, post processing of the angiographic and perfusion images was performed, with multi-planar reformatting (MPR), curved multi-planar reformatting (cMPR), maximum intensity projection (MIP) and volume rendering algorithms.

The study was approved by the Ethics Board of Ain Shams University.

RESULTS

This study included 35 patients with CAD with or without ischemia, ages of the patients ranged

from 42 to 73 years 30 of them had significant coronary artery stenosis. About 26% of them had significant stenosis in the RCA territory, 77% had significant stenosis in the LAD territory and 43% had significant stenosis in the LCx territory. 40% had single coronary artery significant stenosis, about 31% had two coronary arteries significant stenosis and 14% had three coronary artery significant stenosis

Correlative Analysis of DE-CT Myocardial Perfusion and cCTA Data Revealed that:

* Myocardial perfusion was defected in the inferior myocardial wall and inferior septum in cases with RCA significant affection.

* Myocardial perfusion was defected in the anterior wall and anterior septum in cases with LAD artery significant affection.

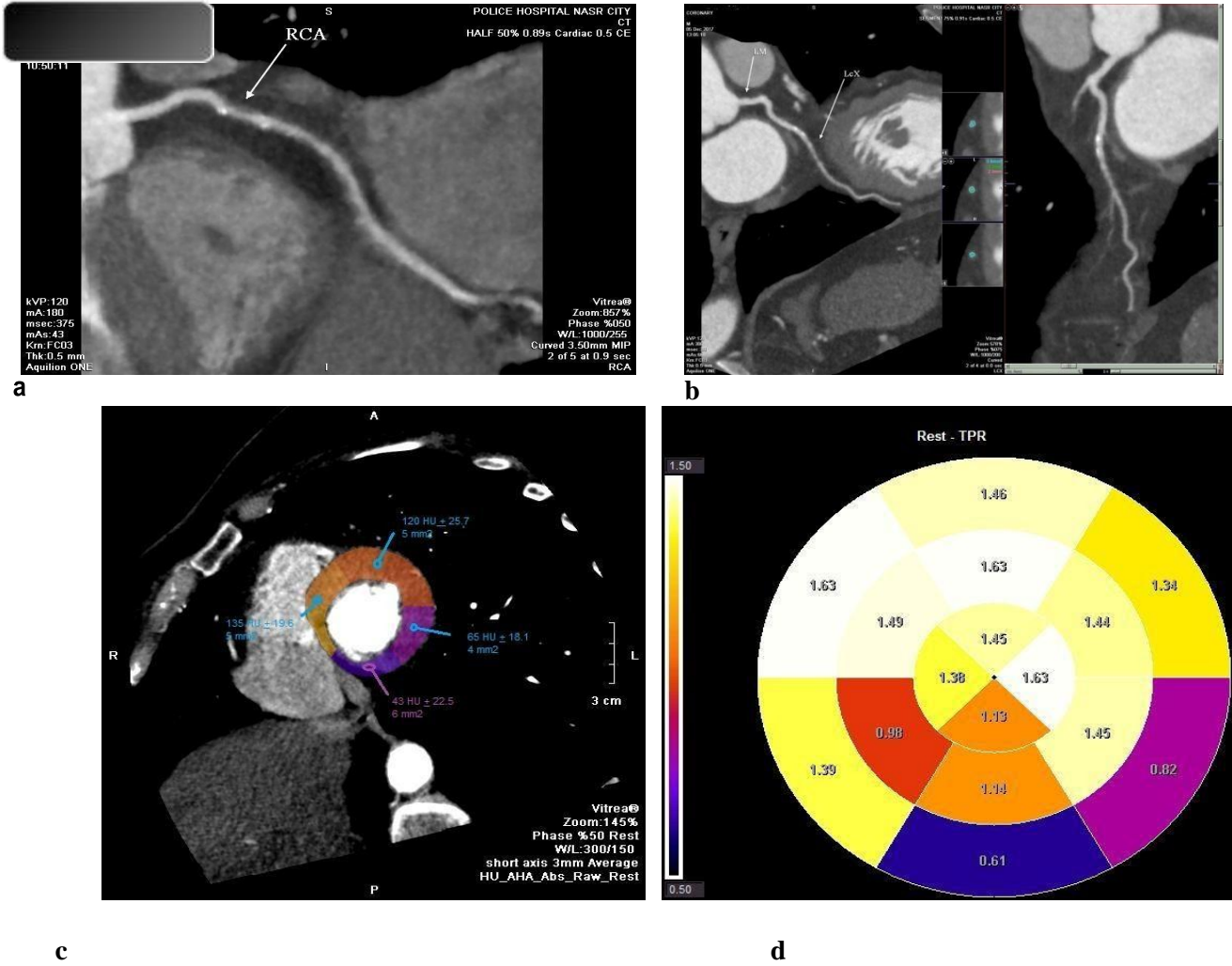
* Myocardial perfusion was defected in the lateral wall in cases with LCx artery significant affection, except for one case that showed perfusion defect in lateral as well as inferior walls in a patient with dominant LCx artery.

*The correlative data analysis on a segmental basis revealed high diagnostic value of DECT myocardial perfusion for detecting myocardial segments with perfusion defects as compared to cCTA, with overall 83% sensitivity, 87% specificity and 86% accuracy, with 74 % positive predictive value and 92 % negative predictive value.

* It also showed a good agreement with 0.67 Cohen's Kappa and 0.71 Prevalence and bias adjusted Kappa.

Illustrative cases

CASE 1



Figures 1: a & b cCTA , c and d myocardial attenuation and TPR transmural perfusion ratio respectively

Figures 1 (A to D) Clinical background:

A 67 years old diabetic and hypertensive female patient presented by chest pain

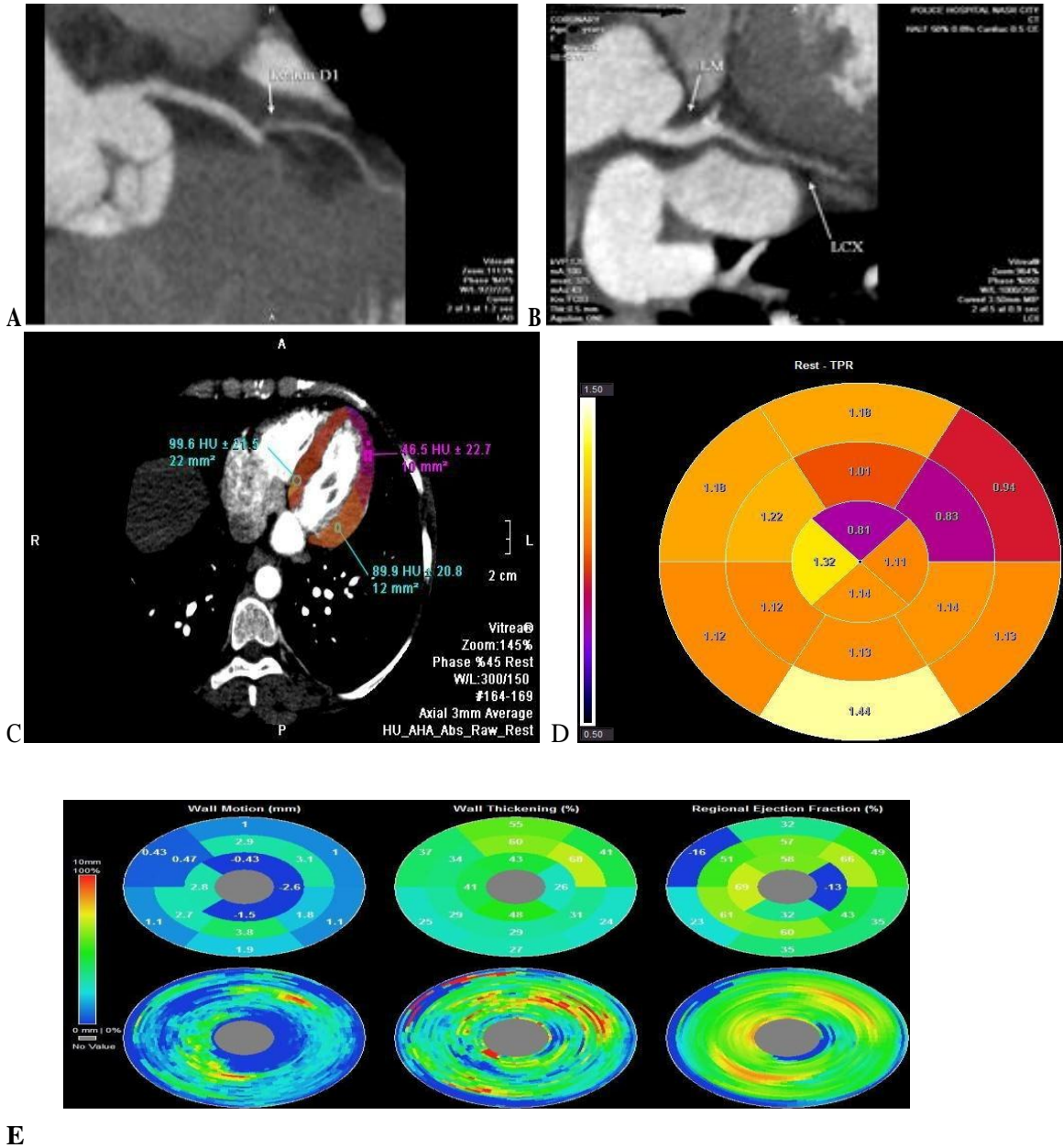
By cCTA :

- Significant stenosis (54 % luminal area reduction) as shown in cMPR.
- LCx also showed mixed plaque at its origin with 41% stenosis.

By CT myocardial perfusion:

Showing basal inferior and basal infero-lateral hypoperfusion .

CASE 2



Figures 2: a and b cCTA showing C-MPR, c and d myocardial attenuation, and TPR transmurial perfusion ratio respectively, E- Segmental and detailed map of left ventricular myocardium

Figures 2 A to E

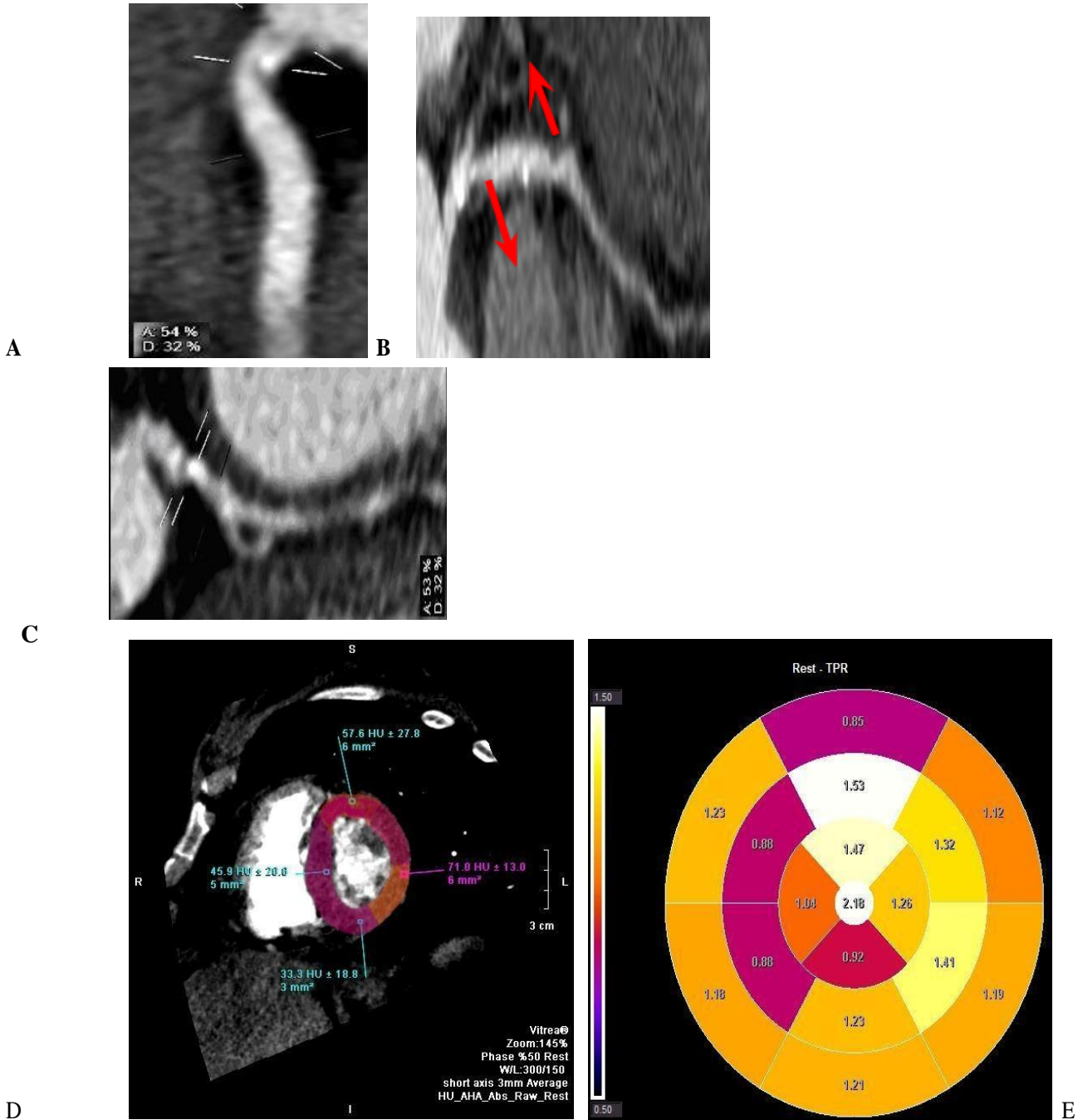
Clinical background:

42 years old male patient with dyslipidemia was complaining of typical chest pain during exertion.

By cCTA: first diagonal mid portion 58 % stenosis as shown in the cMPR.& LCx artery is atherosclerosed and shows causing 77% stenosis

By CT myocardial perfusion: revealed anterior and lateral walls hypoperfusion.

CASE 3



Figures 3 : A ,B&C are cCTA showing C-MPR ,D &E myocardial attenuation and TPR transmural perfusion ratio respectively

Figures 3 A to E

Clinical background:

A 58 years old female patient with known CAD was presented with chest pain.

By cCTA :

RCA showed osteal mixed plaque leading to 54 % stenosis. LAD artery was atherosclerosed with osteal and mid segment soft tissue plaques leading to 63% and 51 % stenoses, respectively. LCx artery was atherosclerosed and showed proximal segment calcific plaque causing 53% stenosis.

By CT myocardial perfusion: basal anterior, mid antero-septal , mid infero-septal and apical inferior wall segments hypoperfusion

DISCUSSION

Our study, in contrast to previous studies, is based on the use of one of the most recent and advanced dual energy system using 320 effective detector rows (Definition , Aquilion one dynamic volume CT; Toshiba medical system ,Tochigi-ken, Japan).

Flash Spiral scanning technology (Flash DECT; definition , Aquilion one dynamic volume CT; Toshiba medical system ,Tochigi-ken, Japan), temporal resolution was 175 msec and 320-slice volume scan offers each detector element is 0.5 mm wide , yielding 16 cm z-axis coverage of imaging area in one rotation, entire cardiac scanning could be achieved in <1 sec. Accurate determination of the degree of stenosis of the scanned coronary arteries is feasible by this technology which can depict the coronary artery and two to three branches with diameters ≥ 1.5 mm with control the heart rate of the patient. Image reconstruction goes in two pathways simultaneously, the first one for coronary analysis; dual-energy CT coronary angiography (CTA) and the other one for myocardial perfusion analysis; dual-energy CT myocardial perfusion (CTP)⁽⁹⁾. We designed our study to evaluate the clinical value of computed tomography in the assessment of myocardial perfusion status with comparison and correlation to cCTA as a gold standard technique and, hence, determine the feasibility to evaluate both myocardial perfusion and coronary artery luminal patency at the same time with single contrast enhanced CT acquisition. In our study, we interpreted and analyzed the imaging data of a similar patient population (35 patients) who had performed cardiac DECT scan at Police Authority Hospitals, Radiodiagnosis Department and was eligible to be included in the study. Post processing using various post processing algorithms and image analysis were performed on an on-line remote workstation with generation of image sets, namely coronary CT images and myocardial

perfusion images. Coronary CTA images were interpreted and analyzed for coronary artery stenosis detection and grading using the automatically generated curved multiplanar reformats of the target vessels. A semi-automated vessel analysis tool was also used for grading of stenosis severity (quantitative measurement).CT myocardial perfusion images were interpreted and analyzed to assess myocardial perfusion status and to detect myocardial perfusion defects.

Evaluation of myocardial perfusion images was based on relative difference in iodinated contrast material contained blood that is perfused into the myocardium which explains the direct relationship between the amount of perfused contrast material within the myocardium and myocardial enhancement and, subsequently, its attenuation (HU). So, hypo-perfused areas of myocardium have a remarkably lower attenuation which was named perfusion defect (PD) which could be detected visually (subjectively) and was confirmed quantitatively (objectively) by measuring attenuation in HU by placing region of interest (ROI).

Then, evaluation of the colour coded images (colour attenuation images) using the dedicated post-processing software for semi-objective detection of hypo-perfused areas which is, finally, confirmed by placing regions of interest of comparative areas in both hypo-perfused and normally perfused areas to compare between them quantitatively for objective evaluation. The results are collected and statistically analyzed.

In their study, *Ruzsics et al.*⁽⁹⁾ evaluated the coronary artery segments of the studied patients on the cCTA images to identify significant (>50%) coronary artery stenosis. They also evaluated DSCT iodine maps to identify myocardial blood pool deficits and they also compared and correlated the findings of segmental myocardial blood pool deficits on DSCT iodine maps with the findings of significant stenosis on cCTA and demonstrated that 126/593 myocardial segments had shown perfusion defect and were supplied by a coronary artery with significant (>50%) stenosis. Their study proved that detection of ischemic myocardial segments using DSCT iodine maps when compared with cCTA on a segmental basis had 80% sensitivity, 91% specificity and 89% accuracy with 67% PPV and 95% NPP. In the current study, we have also evaluated coronary artery morphology and assessed the degree of the stenosis when found .

Furthermore, we observed using perfusion index ,transmural perfusion ratio images as well as

automatic perfusion attenuation and random density using ROI revealed the hypo-perfused areas, and by color coded contrast attenuation images of the left ventricle that were created by enhancement tools that colour overlay the multi-planar reformatted images depending on the amount of iodine based contrast that was perfused to the myocardial tissue with the perfused blood. This color coded and overlaid images provided a semi-objective way to detect the hypo-perfused areas. In order to evaluate myocardial perfusion objectively, we have placed ROIs in the hypo-perfused myocardial areas as well as the segments that show normal perfusion and compared the numerical data of both. Correlation of CT myocardial perfusion finding and cCTA finding of the studied patient population revealed an overall 83% sensitivity, 87% specificity, 86% accuracy, 70% Youden's index with 74 % positive predictive value and 92% negative predictive value. In our study, the specificity, accuracy and NPV have shown subtle decrease (4, 3 and 3%, respectively). However, our study showed subtle increase in sensitivity (3%) and mild increase in PPV (7%).

The mean total radiation exposure that patients received in our study by Toshiba 320-row Aquilion One scanner that can cover the entire heart in one beat is reported of approximately 6 mSv, however lower radiation doses and dependable coronary scan using 1-beat acquisition requires heart rate reduction⁽⁹⁾. The radiation exposure in our study was much lower than that patients received in the study conducted by **Ruzsics *et al.***⁽¹⁰⁾ which was based on dual-source CT scanning while the machine is operated in dual-energy mode which is was 15.23±2.7 mSv. From their initial experience, **Ruzsics *et al.***⁽¹⁰⁾ suggested that patients with known or suspected CAD could be non-invasively evaluated using dual source CT scanners with independent operation of both tubes in dual energy mode for concomitant evaluation of their coronary arteries to confirm or rule out significant coronary disease using cCTA and evaluation of myocardial perfusion for perfusion deficits using DECT iodine maps in the same setting and single CT scan acquisition. We, also, propose that comprehensive evaluation of coronary artery morphology and myocardial perfusion could be achieved by single non-invasive contrast enhanced CT acquisition using DECT with high sensitivity and specificity as well as high diagnostic accuracy. **Techasith and Cury**⁽¹¹⁾ named 2 important CT artifacts, namely beam-hardening and

motion artifacts that may be encountered and the reader should recognize and try to minimize when performing and interpreting myocardial CT myocardial perfusion images. Beam hardening phenomenon eventually happens when X-ray beams pass through high density objects with resultant selective attenuation and absorption of beams possessing low energy and consequently the mean energy of the remaining beams increases. It appears in CT images as a region of low attenuation and should be differentiated from areas of true myocardial perfusion defect. The low attenuation region of beam-hardening artifact appears as a triangular in shape area that originates from nearby high CT density region and was not following any vascular territory⁽¹²⁾. Its common location includes the basal infero-lateral wall that originates from the nearby the densely enhancing descending aorta and the dense vertebral bodies⁽¹¹⁾. Motion artifact is the other artifact that occurs particularly in cases with high heart rate and also appears as an area of low attenuation due to myocardial wall motion during the scan. It's of low importance due to improved CT temporal resolution and is differentiated from true perfusion defect as it changes its location or disappears in the other phases of the cardiac cycle contrary to the fixed true perfusion defect. With CT technology improvements some of CT artifacts were suggested to disappear⁽¹¹⁾.

Clinical implications:

With application of the suggested technique we could evaluate both myocardial perfusion and coronary artery luminal patency at the same time with single contrast enhanced CT acquisition with the same amount of contrast material as coronary CT angiography study alone and with no additional radiation exposure.

LIMITATIONS OF THE STUDY

Our study faced many limitations that should be addressed by further studies: First of them was the relatively small number of the studied population with the need to involve larger number of patients in future studies for the validation of our findings. The second was that we didn't compare the findings of CT myocardial perfusion with any of the known studies of myocardial perfusion imaging such as SPECT or MRI as a reference; however, our primary goal was to compare and correlate the findings of CT myocardial perfusion with the coronary artery morphological assessment by cCTA as a reference. Also, the study was

acquired at rest only and so differentiating different types of ischemia from each other and differentiating ischemia from myocardial infarction was impossible. Finally, inter-observer variability was not investigated in the study because the readout was performed in consensus sessions.

We believe that correlation of our study results with the results of another CT perfusion imaging technique, namely DECT myocardial perfusion would be of value.

CONCLUSION

The suggested technique, despite the forementioned limitations, combines myocardial perfusion evaluation and coronary morphological evaluation with good correlation in a single reproducible non-invasive contrast enhanced CT acquisition without the need to increase the contrast material or radiation dose. We suggest that DECT myocardial perfusion imaging has the potential to be the first, independent and stand out imaging choice for comprehensive and correlative assessment of both myocardial perfusion status and coronary arterial morphology in patients with suspected or known to have CAD. Future validation of the suggested technique is advised to further enhance the beneficial outcomes of the CT study of the breast lesions.

REFERENCES

1. Sparrow P., Merchant N, Provost Y *et al.* (2009): CT and MR imaging findings in patients with acquired heart disease at risk for sudden cardiac death. *Radiographics*, 29:805–823.
2. Ghostine S, Caussin C, Habis M *et al.* (2008): Non-invasive diagnosis of ischemic heart failure using 64-slice computed tomography. *European Heart Journal*, 29: 2133–2140.
3. Masci PG, Dymarkowski S, Rademakers FE *et al.* (2009): Determination of regional ejection fraction in patients with myocardial infarction by using merged late gadolinium enhancement and cine MR: Feasibility Study. *Radiology*, 250: 50–60.
4. Ricardo C, Koen N, Michael DS *et al.* (2008): Comprehensive assessment of myocardial perfusion defects, regional wall motion and left ventricular function by using 64-section multidetector CT. *Radiology*, 248:466–475.
5. Mordi I, Stanton T, Carrick D *et al.* (2014): Comprehensive dobutamine stress CMR versus echocardiography in LBBB and suspected coronary artery disease. *JACC Cardiovasc. Imaging*, 7:490–498.
6. Parker MW, Iskandar A, Limone B *et al.* (2012): Diagnostic accuracy of cardiac positron emission tomography versus single photon emission computed tomography for coronary artery disease: a bivariate meta-analysis. *Circ. Cardiovasc. Imaging*, 5:700–707
7. Akos V-S, Felix G. M, Carlo N. D, Stephen R. F, Richard R. B and Joseph (2015): CT Myocardial perfusion imaging . *American Journal of Roentgenology*, 204: 487-497.
8. Zhao R, Hao Z and Song Z (2014): Diagnostic value of flash dual-source CT coronary artery imaging combined with dual-energy myocardial perfusion imaging for coronary heart disease. *Experimental and Therapeutic Medicine*, 7: 865-868.
9. Hoe J and Toh KH (2009): First experience with 320-row multidetector CT coronary angiography scanning with prospective electrocardiogram gating, to reduce radiation dose. *J. Cardiovasc. Comput. Tomogr.*, 3:257-261.
10. Ruzsics B, Lee H, Powers E R *et al.* (2008): Myocardial ischemia diagnosed by dual-energy computed tomography: correlation with single-photon emission computed tomography. *Circulation*, 117: 1244-1245.
11. Techasith T and Cury RC (2011): State of-the-Art paper. Stress myocardial CT perfusion. *JACC. Cardiovascular Imaging*, 4(8): 905–916.
12. George RT, Silva C, Cordeiro MA *et al.* (2006): Multidetector computed tomography myocardial perfusion imaging during adenosine stress. *J. Am. Coll. Cardiol.*, 48: 153– 160.