

INTRAORAL MANAGEMENT OF DISPLACED LOWER WISDOM INTO SUBMANDIBULAR SPACE: A CASE REPORT

Hussein Abdel Motelep Khalil* and Atef Mohamed Hasanen**

ABSTRACT

Displacement of an impacted third molar, either fragments or the entire tooth, is a rare complication that occurs during exodontia. The most common sites of Displacement of an impacted mandibular third molar fragment are the sublingual, submandibular, and pterygomandibular spaces. Removal of a displaced root or tooth from these spaces may be complex due to poor visualization and limited access.

Patients and methods: Referred patient was presented with a mandibular third molar roots displaced into submandibular space. Cone beam CT was performed to locate the displaced roots. The case was managed intraorally under local anesthesia by raising a lingual flap, the roots were removed and the wound was closed meticulously.

Result: the roots were removed safely without complications and wound healing was normal.

Conclusion: Wisdom tooth removal must be done by an experienced surgeon with adequate clinical and radiological assessment to avoid any inadvertent complications. If a dental fragment becomes displaced into a deep space, it is very important to determine the exact location by CT or high-quality radiography.

INTRODUCTION

Surgical Removal of impacted third molar is the most common procedure performed by dentists and oral and maxillofacial surgeons worldwide. Complications, such as pain, dry socket, swelling, paresthesia of the lingual or inferior alveolar nerve, bleeding, and infection, occur in about 1% of all cases.⁽¹⁻⁴⁾

Displacement of fragment or whole of the third molar into the sublingual, submandibular, or pterygomandibular space is a rare complication.^(5, 6) Excluding cases with atypical anatomical considerations, such as a distolingual tooth inclination or a thin lingual cortex, displacement can usually be attributed to the application of uncontrolled or excessive force, excessive manipulation, improper surgical planning, or poor clinical and/or radiological

* PhD, Consultant and Head of Department of Maxillofacial Surgery, Nasser General Hospital.

** Assistant Professor of Oral and Maxillofacial Surgery Faculty of Dental Medicine Al Azhar University.

assessment. (7) Because the incidence of third molar displacement is very low, there are only a few case reports of this condition in the Literature and there is little information about it in general. Here, we report a case of accidentally displaced mandibular third molar roots into submandibular space and the intraoral removal of the displaced roots under local anesthesia.

Case report

A 32-year-old male patient was referred by a private practitioner with the chief complaint of pain, swelling as a result of displaced roots of lower left wisdom after many trials of the dentist to retrieve them. A panoramic radiograph revealed deep-seated roots positioned below the inferior border of the mandible (Fig. 1).

The patient reported that he felt hard rocking object by pressing it against the mandible in the submandibular region from the time of trial extraction. A cone beam computed tomography (CBCT) scan was performed to locate the roots precisely. CBCT revealed a fracture in the patient’s lingual plate near the third molar region and a hyper dense fragment situated at medial edge of the submandibular space (Fig. 2).

Treatment plan with intraoral approach, under local anesthesia and potential complications was explained to the patient, who agreed. An inferior alveolar, lingual nerve block with long buccal nerve infiltration was anesthetised by injection with 4% articaine (Artinibsa, Inibsa Dental,S.L.U-Barcelona/Spain) supplemented with adrenaline (1:100,000). The patient’s mouth opening angle was increased manually under local anesthesia and a mouth prob was used to maintain opening. The displaced roots were palpated with the operator’s index finger and confirmed to be situated deep in the submandibular region. A buccal flap was raised from the mandibular first molar to the external oblique ridge distally and a lingual flap was raised mesially up to the first premolar and distally adjoined with the buccal flap. The lingual flap was reflected up to the submandib-

ular region with great care until the root fragment could be visualized with good illumination and support from an extra orally placed finger. With the help of a curette, the roots were pushed outward and removed (Fig. 3).

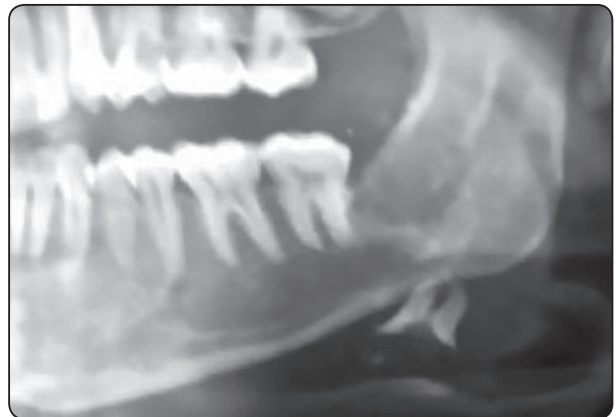

Fig. (1) Panoramic view showing the displaced wisdom roots below inferior border of the mandible

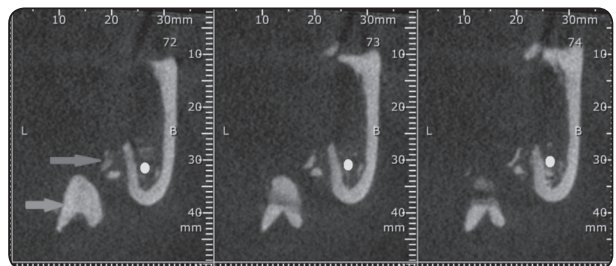


Fig. (2) Cone beam CT showing: The displaced wisdom roots in submandibular space (blue arrow) & fracture of the lingual plate (red arrow).

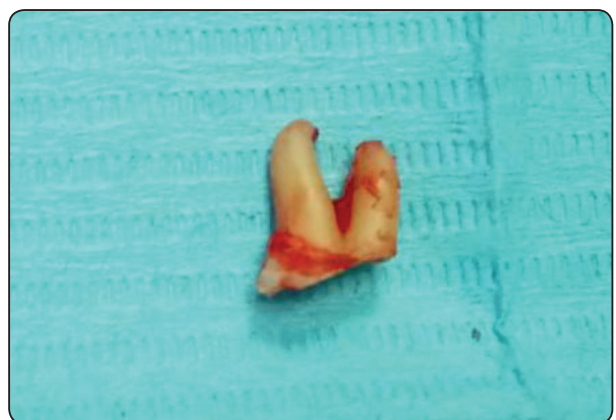

Fig. (3) The diplaced roots were removed

The wound was irrigated with normal saline and the flaps were sutured with 3–0 vicryl sutures. An antibiotic and analgesic were prescribed for 5 days. On the 7th postoperative day, the patient reported that he was not experiencing any troubling complications, his healing appeared to be satisfactory, and the sutures were removed.

DISCUSSION

Howe presented the first case of removal of a displaced tooth from the submandibular space in 1958. Since that time, there have been many case reports of displaced tooth fragments in the English literature, but displacement of a root fragment into the submandibular space has been described only rarely.⁽⁷⁾ The accidental displacement of a mandibular third molar root or root fragment during extraction is rare, nevertheless a well-recognized potential complication included in textbooks.^(8,9)

This complication is considered to be associated with various risk factors, including patient age, tooth position, the presence of a lingual plate fracture, abnormal thickness of the lingual plate, excessive or uncontrolled force, lack of operator expertise, and poor clinical and radiological assessment.^(1,2,8,9) Removal of third molars at a young age before the roots are fully developed can minimize the risk of displacement.⁽⁷⁾

The symptoms of a displaced root depend upon its size, location, and whether or not there is an associated infection. Some patients are symptom-free, whereas others experience pain, swelling, and trismus in the immediate postoperative period. According to a removal delay of >24 h may result in an inflammatory response that can lead to intense pain, swelling, trismus, infection and further migration of the root or root fracture into even deep spaces, producing a foreign body reaction.

A displaced root fragment should be removed promptly upon proper localization with radiographs or a CT scan. Manual palpation is also a useful

localization method. CT scanning is considered to be the most appropriate technique with which to determine a displaced root fragment's exact size and location. Cone-beam CT, if available, can provide the added advantage of low-radiation exposure and three-dimensional views.^(2,4,7,9) If CT is not available, panoramic and occlusal radiographs can be used.

Several approaches have been described for the intraoral removal of displaced dental root fragments in the literature. The intraoral approach under local anaesthesia is the simplest and least invasive technique for removal of displaced root pieces in the soft tissue of the lingual pouch. Local anaesthesia is used commonly because it is considered to be simple and safe and it avoids complications related to the use general anaesthesia, which is relatively costly and may involve hospital admission. In the present case, adequate visualization was achieved by way of a lingual mucoperiosteal flap raised to the premolar site. However, this approach may not provide adequate visibility and access in other situations. When a fragment is displaced within deep spaces, an extraoral approach may be indicated.^(10,11) Indeed, a combination of intraoral and extraoral approaches may be needed to retrieve tooth and root fragments.⁽¹¹⁾

Many complications, including paresthesia and hemorrhage, can occur following retrieval of a root fragment from the sublingual space due to its close proximity to the lingual nerve, inferior alveolar nerve, and blood vessels.^(2,6,8,9) To decrease the risk of complications, a thorough treatment plan should be developed before proceeding with removal.⁽¹²⁾

CONCLUSION

The present case report describes the case of a displaced third molar root in the submandibular space. A CBCT scan provided accurate localization of the root, which was then removed successfully via an intraoral approach under local anesthesia by carefully reflecting a deep lingual flap up to the

submandibular region. There were no postoperative complications.

Wisdom tooth removal must be done by an experienced surgeon with adequate clinical and radiological assessment to avoid any inadvertent complications. If a dental fragment becomes displaced into a deep space, it is very important to determine the exact location by CT or high-quality radiography.

REFERENCES

1. Susrala, S.M., Blaeser, B.F., Magalink, D., 2003. Third molar surgery and associated complications. *Oral Maxillofac. Surg. Clin. N. Am.* 15, 177–186.
2. Tumuluri, V., Punnia-Moorthy, A., 2002. Displacement of a mandibular third molar root fragment into the pterygo-mandibular space. *Aust. Dent. J.* 47, 68–71.
3. De Biase, A., Guerra, F., Giordano, G., 2005. Surgical removal of a left lower third molar root after iatrogenic displacement in soft tissue. Case report. *Minerva Stomatol.* 54, 389–391.
4. Kamburoglu, K., Kursun, S., Oztas, B., 2010. Submandibular displacement of a mandibular third molar root during extraction: a case report. *Cases J.* 3, 8–10.
5. Nusrath, M.A., Banks, R.J., 2010. Unrecognised displacement of mandibular molar root in to the submandibular space. *BDJ* 209 (6), 279–280.
6. Gay-Escoda, C., Berini-Ayete´s, L., Pinˆera-Penalva, M., 1993. Accidental displacement of a lower third molar. Report of a case in the lateral cervical position. *Oral Surg. Oral Med. Oral Pathol.* 76, 159–160.
7. Arasa, L.A., Figueiredo, R., Escoda, C.G., 2012. Iatrogenic displacement of third molar roots in to the sublingual space: report of 6 cases. *J. Oral Maxillofac. Surg.* 70, e107–e115.
8. Ertas, U., Yaruz, M.S., Tozoglu, S., 2002. Accidental third molar displacement into the lateral pharyngeal space. *J. Oral Maxillofac. Surg.* 60, 1217–1219.
9. Huang, I.Y., Wu, C.W., Worthington, P., 2007. The displaced lower third molar: a literature review and suggestions for management. *J. Oral Maxillofac. Surg.* 65, 1186–1190.
10. Ozalp, B., Kuvat, S.V., Emekli, U., 2010. Conservative treatment of displacement mandibular third molar. *J. Craniofac. Surg.* 21, 1314–1316.
11. Yeh, C.J., 2002. A simple retrieval technique for accidentally displaced mandibular third molars. *J. Oral Maxillofac. Surg.* 60, 836–837.
12. Jolly SS, Rattan V, Rai SK. Intraoral management of displaced root into submandibular space under local anaesthesia – A case report and review of literature. *Saudi Dent J.* 2014; 26:181-184.