

THREE DIMENSIONAL ACCURACY OF MANDIBULAR RECONSTRUCTION BY PRE-BENT RECONSTRUCTION PLATE USING INTRA ORAL VERSUS EXTRA ORAL APPROACHES FOLLOWING MANDIBULAR RESECTION IN PATIENTS WITH EXTENSIVE AMELOBLASTOMA

Fatma Ibrahim Mohamed*

ABSTRACT

Purpose: This prospective study aimed to compare the intraoral placement of the pre-bent reconstruction plate with that inserted via the extraoral approach, to evaluate their impact on the three-dimensional (3D) position of the proximal segment, after continuity resection of mandibular ameloblastoma.

Patients and methods: Patients were divided into two equal groups. In group 1, the mandible was reconstructed with a pre-bent reconstruction plate via an intraoral approach. In group 2, an extraoral approach was used. The primary outcome variables were the need for intraoperative plate readjustment, the time needed for plate insertion, total operation time, difficulties encountered during surgery, and the postoperative stability of the proximal segment. Distances between corresponding anatomical landmarks on the mandibular angle and condyle (A-A', B-B', C-C', B-C') as well as the intercondylar angle (ICA) and B'XC angle, were measured. The difference between the pre- and postoperative measurements was used to evaluate the reconstruction accuracy. The results of the two groups were compared and analyzed by *t*-test.

Results: Thirty patients were enrolled in this study. In group 1, four plates required minor readjustment. In group 2, only two cases required re-adaptation. The mean time for plate placement was 38 ± 5.8 and 27.5 ± 7.5 minutes in groups 1 and 2, respectively ($p = 0.0001$). The intraoral insertion of the pre-bent plates revealed a decrease in the linear measurements, resulting in mandibular compression. On contrary, the extraoral approach showed increase in the measurements, resulting in widening of the mandible. However, this width difference was statistically insignificant. Concerning the ICA and B'XC angle, no significant difference could be ascertained between the two groups.

Conclusion: Intraoral approach is more conservative procedure, thereby achieving the best esthetic outcomes and resulting in a more accurate 3D mandibular reconstruction. This approach is considered the treatment of choice for resection and reconstruction of mandibular ameloblastoma. However, if the reconstruction plate cannot be inserted intraorally, then extraoral approach is advised.

KEYWORDS: Ameloblastoma; Mandibular reconstruction; Pre-bent reconstruction plate, rapid prototyping model (RPM), computed tomography (CT) measurements

* Associate Professor of Oral and Maxillofacial Surgery, Faculty of Dental Medicine for Girls, Al Azhar University

INTRODUCTION

The mandible is the focal point of the lower 1/3 of the face, which is responsible for facial esthetics and functions. Many pathological conditions such as trauma, infection, and tumors may affect the mandible, requiring extensive ablative surgery. Ameloblastoma is one of the most common odontogenic tumors, accounting for 1% of all oral tumors.¹ It appears more frequently in the mandible (80%), particularly in the corpus and ramus.² Because of its aggressive behavior and high recurrence rate, it is usually treated by marginal or segmental resection.³

Mandibular reconstruction after such resections has always been a challenging task and time-consuming procedure for head and neck reconstructive surgeons. The primary goals of reconstruction are bridging the defect and restoring mandibular continuity. Accuracy of reconstruction plates' adaptation usually affects the three-dimensional (3D) position of the remaining mandibular segments, which plays an important role in maintaining facial esthetics and masticatory functions. In addition, preservation of the correct position of the condyles in the glenoid fossae avoids devastating postoperative malocclusion and inadequate masticatory functions.^{4,5} In recent years, pre-bending of the reconstruction plates on a rapid prototyping model (RPM) has provided superior surgical outcomes, especially when dealing with complex mandibular defects. Moreover, this technology has provided more precise and reliable reconstruction with shorter operating time and less extensive surgical exposure.^{6,7}

The traditional approach to sizeable ameloblastoma is through a large extraoral incision because it provides adequate access for tumor resection and direct approach to the proximal and distal segments of the resected mandible, facilitating plate adaptation and fixation. However, this approach results in unsatisfactory cosmetic outcomes. Recently, the intraoral approach becomes widely used in resec-

tion of extensive ameloblastoma and reconstruction of the continuity defect. This incision avoids facial scars, preserves the perioral musculature, and does not jeopardize the integrity of the facial nerve, providing optimal esthetic and functional results.⁸

Several studies^{4,7,9-12} concerning mandibular reconstruction were focused on the assessment of the 3D accuracy of reconstruction with the pre-bent reconstruction plates. Until now, there is no study explored the effect of the surgical approach to ameloblastoma on the 3D position of the proximal segment after mandibular resection and reconstruction with a pre-bent reconstruction plate. The purpose of this prospective study was to answer the following questions: 1) Does the intraoral placement of the pre-bent reconstruction plate affect the postoperative 3D position of the proximal segment, after continuity resection of ameloblastoma? 2) Does the intraoral placement of the plate require intraoperative readjustment? The author hypothesized that the intraoral plate placement would provide similar surgical outcomes as those provided via the extraoral approach. So, this study aimed to compare the intraoral placement of the pre-bent reconstruction plate with that inserted via the extraoral approach, to evaluate their impact on the 3D position of the proximal segment after continuity resection of ameloblastoma and determine which would require more intraoperative readjustment.

PATIENTS AND METHODS

Study Design and Population

To address the research purpose, a prospective comparative study was designed and performed. The study population was composed of patients presented for evaluation and management of histologically confirmed ameloblastoma. They were selected from the outpatient clinic of the Department of Oral and Maxillofacial Surgery, Faculty of Dental Medicine for Girls, Al Azhar University, between January 2016 to March 2019. Patients who fulfilled

the following inclusion criteria were included in the study: (1) patients with a biopsy-proven mandibular ameloblastoma that should be removed by segmental resection, (2) angle of the mandible of at least one side should be left intact after resection, (3) the resection should leave enough bone on both sides for the fixation of the plates, (4) presence of preoperative and postoperative computed tomography (CT), and (5) complete clinical and pathologic records. Patients were excluded if they had one of the following conditions: (1) patients with a resection affecting the condyle, (2) ameloblastoma that should be removed by marginal resection, (3) patients with incomplete clinical, radiographic, or pathologic records, and (4) medical conditions that could interfere with the healing process such as nutritional deficiency, uncontrolled diabetes, chemotherapy, radiotherapy... etc. In accordance with the Declaration of Helsinki, written informed consent was obtained from all patients, and the local ethics review committee of the Faculty of Dental Medicine for Girls at Al Azhar University approved the study.

Study variables

Demographic variables included age, gender, and the anatomical site of the lesion. The primary predictable variable was the surgical approach through which the pre-bent reconstruction plate was inserted. The patients were randomly divided into two equal groups. In group 1, ameloblastoma was approached, resected and reconstructed with a pre-bent reconstruction plate via an intraoral approach. In group 2, an extraoral approach was used for the same procedures. The primary outcome variables were the need for intraoperative plate readjustment, the time needed for plate insertion, total operation time, difficulties encountered during surgery, and the postoperative stability of the proximal segment. The secondary outcome variables were the postoperative complications as infection, wound dehiscence, hardware exposure, malocclusion of the contralateral side, soft-tissue scarring, inferior alveolar nerve (IAN) and facial nerve injuries.

Treatment protocol

Preoperative preparation

Preoperative diagnosis is made with clinical examination, orthopantomogram (OPG), and CT scan to detect the extent of the lesion. In addition, an incisional biopsy was performed under local anesthesia for histopathologic assessment, which revealed ameloblastoma for all cases.

Virtual Planning

Preoperative high-resolution CT scan of the patient's maxillofacial skeleton was performed with a slice thickness of 0.5 mm (Aquilion 64 CT, Toshiba, Tokyo, Japan). CT data was imported as DICOM (digital imaging and communications in medicine) files, which were segmented and converted into virtual 3D models, by using Mimics software (Mimics 14.1, Materialise, Belgium). As the contour of the mandible was destroyed by the tumor, mirroring tools were used to interpolate the defect span. The mirroring protocol is not possible in defects that crossing the midline of the mandible. Therefore, a database with segmented atraumatic mandibles from other patients can be imported and used as a reference mandible.¹³ After adjustment of the mandibular defect; the reconstruction data set was then converted into the Standard Tessellation Language format (STL format) and sent to a 3D printer, generating a RPM. The expected resection margins were drawn on the model, and then the 2.4 mm reconstruction plate (Leibinger plates, Stryker Howmedica GmbH) was manually contoured and adapted with pliers by the same operator until an optimal fitting was achieved. To facilitate intraoperative placement of the pre-bent plate, the outline of the plate was marked with a pen on the 3D-model. Before surgery, the pre-bent plates were sterilized by autoclave.

Surgical Procedures

All surgical procedures were performed under general anesthesia, by the same oral and maxillofacial team. All patients underwent segmental

mandibular resection and reconstruction with the pre-bent titanium reconstruction plates. Before surgical intervention, arch bars were applied for patients with remaining dentition in the upper and lower jaws. Via an intraoral approach (group 1), the buccal, labial, and lingual flaps were raised, and the entire mandible was exposed. In group 2, the mandible was approached via a transcervical or submandibular approach along a skin crease. For all patients, care was taken during tumor dissection to preserve the mucoperiosteum, except the cases where the tumor had perforated the bone; a part of that mucoperiosteum was resected along with the attached soft tissues. After exposure of the mandible, intermaxillary fixation (IMF) was performed to maintain occlusion on the unaffected side. Before resection, the osteotomy lines were drawn on the mandible and the pre-bent plate was placed and temporarily fixed in the correct position, with at least two screws on the proximal and distal seg-

ments. Subsequently, the plate was removed and the resection was performed. The plate was then perfectly repositioned according to the pre-existing screw holes, with three (2.4 mm) titanium bicortical screws on each side of the defect, and then the IMF was released (Figure 1). In cases where the tumor size made the accessibility to the mandible difficult, temporary plate fixation could not be performed and the lesion was resected first, followed by plate adjustment according to its outline that was marked on the RPM. If the symphyseal region was involved in the resection, the genioglossus and anterior belly of digastric muscles were sutured and fixed to the chin muscles. The sutures were passed through one or two holes of the reconstruction plate and then tied to the chin. The incisions were closed in the usual manner. Dentulous patients were kept in IMF by using elastics, to guide stable occlusion. These elastics were gradually loosened by time.

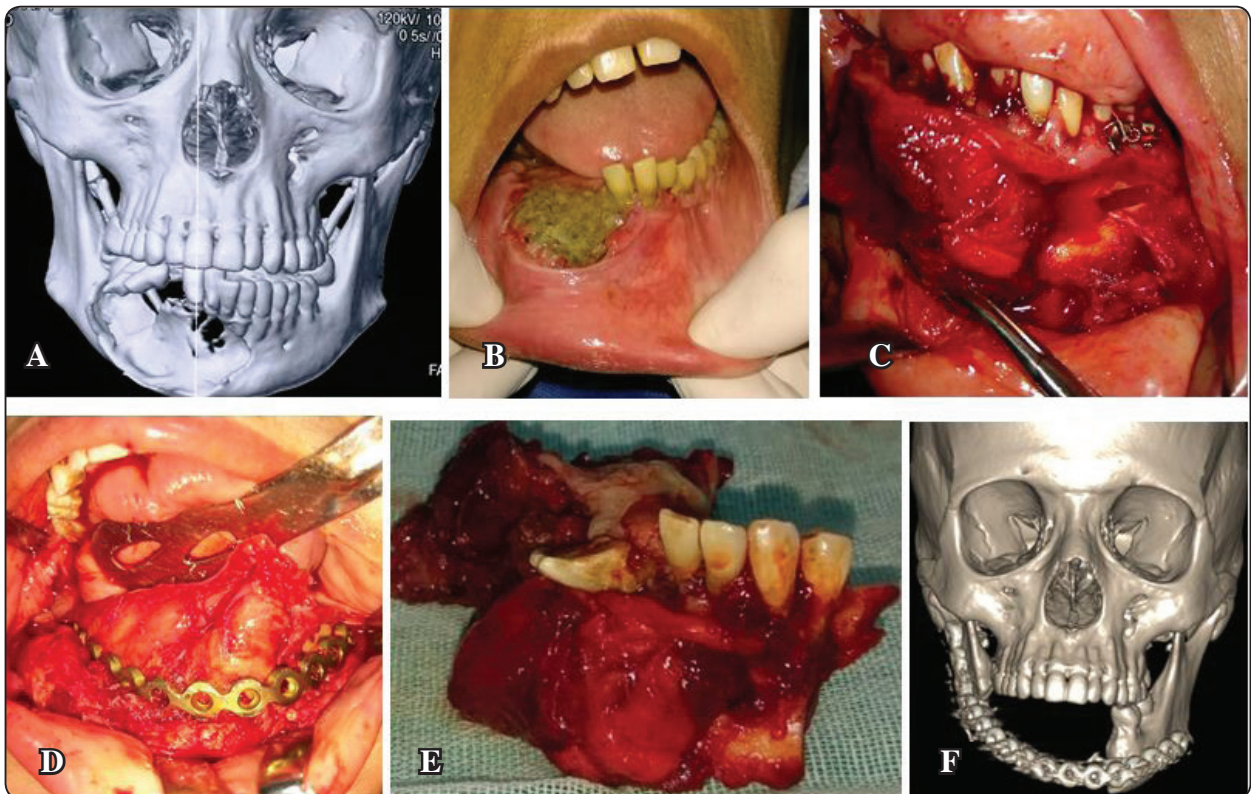


Fig. (1) (A) Preoperative 3D image showing extension of lesion and its multicystic appearance; (B) clinical appearance of the lesion; (C) intraoperative picture showing lesion approached through an intraoral incision; (D) intraoperative picture showing reconstruction with a pre-bent reconstruction plate; (E) surgical specimen; (F) postoperative 3D CT image showing reconstruction of the mandible with a pre-bent reconstruction plate

Intraoperative assessment

The surgical approaches were evaluated according to the following parameters: the need for intraoperative plate readjustment, the time needed for plate insertion and fixation, total operating time, and difficulties that encountered during surgery.

Postoperative assessment

Clinical follow-up was carried every day during the first week, every week during the first month, and at 3 and 6 months postoperatively. Postoperative complications were documented. They included infection, wound dehiscence, hardware exposure, malocclusion on the unaffected side, soft-tissue scarring, IAN, and facial nerve injuries.

Postoperative Malocclusion was evaluated according to a scale ranged from 0 to 2. The scale "2" occlusion indicates a stable occlusion with no premature contact or crossbite. The scale "1" occlusion indicates a mild derangement in which premature contact or crossbite that could be corrected by guiding elastics or spot grinding, and the scale "0" denotes a severe derangement that needs a revision surgery.

CT data analysis

According to Naros et al.¹², anatomical points, lines, and angles were identified and placed on the pre- and postoperative 3D images (Figure 2). The definitions of these anatomical landmarks are listed in Table 1. To assess the positional changes of the ipsilateral proximal segment in both groups, distances between the corresponding points were measured (A-A', B-B', C-C', B-C') on the 3D virtual model. In addition, the 'intercondylar angle'

(ICA) was measured in the axial plane. To assess the mediolateral rotation of the ipsilateral condyle, B'XC° was created and measured in this study. To evaluate the direction and amount of surgical change, the difference between the post- and preoperative measurements of each distance and angle was calculated. The smaller the deviation from the initial values the higher is the achieved accuracy. Conversely, a number far from zero indicated that the ramus and condyle positions had been changed significantly as a result of the operation. Negative and positive values mean that there were medial and lateral displacements of the proximal segment, respectively. To reduce the human error, the measurements were taken twice by the same examiner, two weeks interval, and the mean outcome of both measurements represented the final results. The amount of change of all measurements was compared among the two groups.

Statistical analysis

The collected data was recorded, tabulated, and analyzed statistically with the help of Microsoft Office XP (Excel) and SPSS (version 15.0, SPSS Inc., Chicago, IL, USA). Parametric data was expressed as the mean \pm standard deviation (SD), and non-parametric data was expressed as the number and percentage of the total. A paired sample *t*-test was used to identify a significant difference in the amount of change of the linear and angular measurements between the two groups. In addition, the pre- and postoperative mean values of those measurements were compared in every group. *P*-values below 0.05 were considered statistically significant.

TABLE (1) Anatomical landmarks and angles used in this study.

Points A, A'	The most prominent point of the lateral surface of the condyle of the normal and affected sides, respectively
Points B, B'	The most prominent point of the medial surface of the condyle of the normal and affected sides, respectively
Points C, C'	The midpoint of the angle of the mandible of the normal and affected sides, respectively
A' - B'	Condyle axis; a line connecting A' and B' of the affected side
Point X	Centre of the condyle; midpoint between A' and B' (condyle axis) of the affected side
ICA (°)	The intercondylar angle: is the intersection of the condylar axes in the axial plane
B'XC (°)	The angle between the mid-point (X) and B' on the condylar axis of the affected side and the C point of the normal side on the 3D format

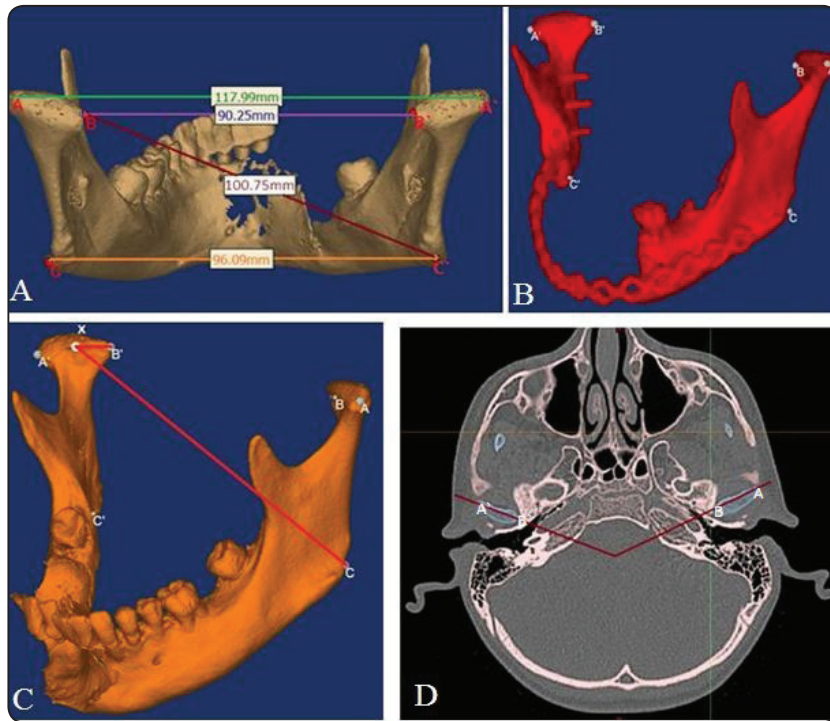


Fig. (2) (A) Measured distances in the 3D plane: A-A` (green), B-B` (purple), C-C` (orange), B-C` (dark red); (B) the same points were marked after resection and reconstruction in the 3D plane; (C) measuring of B`XC° in the 3D plane; (D) measuring of intercondylar angle (ICA) in the axial plane

RESULTS

Thirty patients with histologically confirmed mandibular ameloblastoma were included in the study. Patients' age ranged from 17 to 63 years (mean 30 ± 12.8) and comprised 13 females (43.3%) and, 17 males (56.7%) giving a female-to-male ratio of 1:1.3. Descriptive characteristics of both groups are presented in Table 2. All the patients underwent mandibular segmental resection and the defects were immediately reconstructed with pre-bent reconstruction plates, which were inserted via an intraoral approach in group 1 and extraoral approach in group 2.

Intraoperative evaluation:

All pre-bent reconstruction plates were inserted successfully without any difficulty. In group I, four plates required minor readjustment until an optimal fitting was achieved. In group 2, only two cases required readjustment. The mean time for plate placement in group I was 38 ± 5.8 minutes (range 30 to 47). In group II, it was 27.5 ± 7.5 minutes (range 18 to 41). This difference was found to be statistically significant ($p = 0.0001$). Nevertheless, the mean operative time did not differ significantly among groups. Intraoperative details are listed in Table 3.

TABLE (2) Descriptive statistics of the study population

Study variables	Group 1	Group 2
Patients number	15	15
Mean age (years)	33 ± 13	27 ± 11.8
Gender, n (%)		
Male	9 (60%)	8 (53.3%)
Female	6 (40%)	7 (46.7%)
Primary sites of tumor		
Symphysis, body	3	2
Body	5	3
Body, angle	6	8
Body, angle, ramus	1	2
Defect size (mm)	54.4 ± 6.1	57.4 ± 7.4
Histopathologic type, n (%)		
Multicystic	4 (26.7)	6 (40)
Unicystic	5 (33.3)	4 (26.7)
Follicular	3 (20)	5 (33.3)
Plexiform	2(13.3)	0 (0)
Fibroblastic	1 (6.7)	0 (0)
Radiographic appearance, n (%)		
Multilocular	10 (66.7)	11 (73.3)
Unilocular	5 (33.3)	4 (26.7)

Data presented as mean ±SD or numbers, with percentages in parentheses.

No statistically significant difference was shown, P-value > 0.05

TABLE (3) Intraoperative surgical details

	Group 1	Group 2	P-value
Duration of plate placement, min	38 ± 5.8	27.5 ± 7.5	0.0001*
Operating time (hr)	4.7 ± 0.42	4.4 ± 0.43	0.2
Plate adjustment, n (%)			0.4
Yes	4 (26.7)	2 (13.3)	
No	11 (73.3)	13 (86.7)	

*Significant value $P < 0.05$

Postoperative evaluation

None of the patients had any major postoperative complications, except one in group 2 who suffered from facial nerve injury. Wound healing was uneventful in all patients, except six (four in group 1 and two in group 2) in whom wound infection developed on the seventh to tenth postoperative day. This was associated with dehiscence of the incisions in two cases in group 1 and one case in group 2. The exposure of the hardware through the dehisced wound was noticed in one case in every group. The difference among groups regarding the infection, wound dehiscence, and plate exposure was found to be statistically insignificant (p -value > 0.05). Wound infections were successfully treated with incision and drainage, systemic antibiotics, and routine wound care. The wound granulated and the dehiscence secondarily healed without further events within four weeks. Sixteen patients suffered from permanent paresthesia because the IAN was sacrificed due to its proximity to the lesion. All patients were satisfied with their facial contour. Cosmetic outcome was excellent in the intraoral group and considered acceptable in group 2 because of the presence of an extraoral scar. Details of the postoperative complications are presented in Table 4.

TABLE (4) Postoperative complications

Postoperative complications, n (%)	Group 1	Group 2	P-value
Wound infection	4 (26.7)	2 (13.3)	0.4
Wound dehiscence	2 (13.3)	1(6.7)	0.5
Plate exposure	1 (6.7)	1 (6.7)	1
IAN injury	7	9	0.5
Facial nerve injury	0	1	0.3

No statistically significant difference was shown, $P > 0.05$

Evaluation of postoperative occlusion

In 27 patients, temporary IMF was performed during the operation since those patients still had an identifiable occlusion. In 25 of these 27 cases, a stable occlusion was achieved with no premature contacts or crossbite postoperatively (Scale 2). Two cases in group 2 presented with mild occlusal derangement in the form of premature contact on the unaffected side (scale 1). The occlusion was corrected with spot gridding and heavy elastics for 15 days; the patients' occlusion became stable and there was no functional impairment, so there was no need for surgical revision. At the end of the follow up period, the occlusion of the normal side was stable as the preoperative situation. No clinical symptoms were observed in the temporomandibular joint (TMJ).

CT data analysis

Reconstruction accuracy was evaluated on the pre- and postoperative CT imaging by the deviation of the linear and angular measurements. The pre- and postoperative mean values of these measurements were calculated and compared in every group, in order to evaluate whether the operations caused an increase or decrease in the measured parameters. The results of these measurements are shown in Table 5. The proximal segment revealed postoperative positional changes in both groups.

In group 1, the operations resulted in a minor decrease in the postoperative measurements and thus a non-significant compression of the proximal segment was observed. On the other hand, group 2 showed an increase in the measured parameters and thus a widening of the mandible was occurred, which is also considered non-significant. Similarly, postoperative angular measurements showed a non-significant difference when compared to the preoperative values in both groups.

The amount of change in both groups were calculated, analyzed, and compared (Table 6), in

order to determine the effect of the approach on the evaluated measurements. The intraoral insertion of the pre-bent plates revealed a decrease in the measurements (negative values). On contrary, the extraoral approach showed an increase in the measured parameters (positive values). However, there was a non-significant difference between these two approaches. Nevertheless, a tendency in favor of the intraoral approach cannot be denied, because there were more accurate reconstruction results for the intraoral approach in comparison with the extraoral approach.

TABLE (5) Comparison between the pre- and postoperative mean values of linear and angular measurements in the two groups

	Group 1					Group 2				
	Preoperative		Postoperative		<i>P</i> -value	Preoperative		Postoperative		<i>P</i> -value
	Mean	SD	Mean	SD		Mean	SD	Mean	SD	
A-A' (mm)	110.4	4.5	110.3	4	0.9	107.7	4.4	108.3	3.7	0.7
B-B' (mm)	78	4.4	77.6	4.4	0.8	73.6	2.5	74.1	3	0.6
C-C' (mm)	88.4	9.4	87.9	9	0.9	73.5	4.2	74.6	4.9	0.5
B-C' (mm)	92.8	4.8	92.4	2.7	0.8	91.1	3.9	92.5	4.7	0.4
B'XC (°)	42.7	4.3	42.4	4.7	0.9	39.2	1.8	40	2.3	0.3
ICA (°)	138.7	8.1	137.7	9	0.7	142.5	4.9	144.7	3.1	0.2

NOTE. Measurements are given in degrees and mm

No statistically significant difference was shown, $P > 0.05$

TABLE (6) Comparison of the amount of change of linear and angular measurements among the two groups

	Group 1		Group 2		<i>P</i> -value
	Mean	SD	Mean	SD	
A-A' (mm)	-0.2	2.4	0.6	2.3	0.4
B-B' (mm)	-0.3	1.1	0.55	1.2	0.052
C-C' (mm)	-0.48	2	1.1	2.3	0.06
B-C' (mm)	-0.4	3.3	1.4	1.5	0.07
B'XC (°)	-0.3	3.8	0.8	1.2	0.053
ICA (°)	-1.05	5.3	2.2	3.8	0.07

NOTE. Measurements are given in degrees and mm

Positive values indicate an increase and negative values a decrease in the amount of change

No statistically significant difference was shown, $P > 0.05$

DISCUSSION

Ameloblastoma usually presents as painless bony swelling that reaches a large size at the time of diagnosis. It typically affects young population. They are often diagnosed around the age of 36 years.^{14,15} In this study, the age of the patients ranged from 17 to 63 years (mean 30 ± 12.8). Regarding the sex predilection and distribution sites, many studies showed different results. Both sexes are affected equally as was reported by Akinosi and Williams¹⁶ and Reichart et al.¹⁴ On contrary, many authors observed that males are affected more than females,^{17,18} which is coincident to our results. The author observed that the posterior part of the mandible is the commonest site of the lesion as also reported by Mitchel and Mitchel,¹⁷ but it contradicts the findings of Adekeye¹⁹ and Arotiba et al¹⁸ who observed that the anterior part of the mandible is the commonest site of the lesion.

Mandibular reconstruction after resection of such lesions is a very complex procedure. Two techniques are available for mandibular reconstruction: (1) primary reconstruction by the use of bone grafts in combination with reconstruction plates and (2) staged resection and reconstruction technique, in which reconstruction plates is used in the first stage followed by secondary osseous reconstruction after confirmation of the pathological margins. In this study, the staged surgical protocol was preferred, because it simplifies the bony reconstruction, reduces the rate of positive margins and the recurrence rate.²⁰

Segmental resection and reconstruction of ameloblastoma often performed via an extraoral approach, leaving a large transcervical scar, which has a significant psychological impact on patients' appearance.²¹ Because of this disadvantage, the approach does not fulfill one of the important goals for adequate reconstruction as stated by Myers²² "Secondary cosmetic deformities should be avoided unless no other alternative is satisfactory in the situation". To overcome this drawback, multiple

investigators have reported their successful experience with the resection and reconstruction of mandibular ameloblastoma via the less invasive intraoral approach.^{23,24} This incision is considered a faster surgical procedure that allows rapid recovery, reduces postoperative pain, and provides a better cosmetic outcome. Furthermore, because of the preservation of the perioral musculature, adequate functional results are usually achieved.²³ However, this approach limits the field of exposure making the resection and reconstruction difficult and time-consuming.¹⁵ To shorten this lengthy procedure, RPM was recommended in this study to help in preoperative planning of the resection sites and to provide more accurate and easier planning of preoperative plate bending, thus facilitating its insertion through smaller surgical incision.^{13, 25, 26}

In this study, six pre-bent plates required intraoperative readjustment; four in group 1 and two in group 2. This resulted in a significant decrease in plate placement time in group 2. The author believed that, this could be due to the direct accessibility for plate insertion through the extraoral incision, making the insertion of the pre-bent plate easier without the need of readjustment. On contrary, because of the limited accessibility of the intraoral approach, the plate insertion was considered more difficult, requiring more plate readjustment, which resulted in a longer plate placement time. Another reason for the need of plate readjustment in this study was that when the tumor had perforated or destroyed the buccal bone and reached a big size, the pre-bent plate could require further intraoperative readjustment, this explanation was also stated by Naros et al.¹² However, this consumed time by the plate readjustment was outweighed by the reduced time required for making the intraoral incision. Similarly, the steps of the extraoral incision are considered a lengthy procedure, which consumed the time that was saved by the rapid plate placement without readjustment, resulting in an increase in the total operative time, which became comparable to that of the intraoral procedures with no significant

difference. It was reported that, the decrease in plate placement time plays an important role in minimizing the ischemic damage for the flap, which decreases the risk of postoperative infection.²⁷ This explaining why the rate of infection was higher in group 1 than group 2 (four versus two cases); however, the difference was considered insignificant.

Many authors reported that a disparity still exists between the postoperative results and preoperative simulation designs, even with the wide spread use of RPM and pre-bent plates, resulting in noticeable positional errors of the reconstructed segments.²⁶ Recently, 3D computer simulations and image analyses are widely used to evaluate the surgical changes concerning the 3D movement of the proximal segment following mandibular reconstruction and orthognathic surgery.²⁸ Based on many studies,^{9,10,12} the author assessed the 3D position of the proximal segment by linear and angular measurements, following mandibular reconstruction by pre-bent reconstruction plate via intraoral and extraoral approaches. It was noted that the position of the proximal segment revealed postoperative changes in both groups and these changes had a positive effect on the mandibular width. Group 1 showed a postoperative decrease in the linear measurements, as also observed by Wilde et al.¹⁰ This could be attributable to the limited accessibility of the intraoral approach through which the plate was inserted and might cause medial pushing of the proximal segment during plate fixation, leading to compression of the mandible. On the other hand, via an extraoral approach there was a greater accessibility to the mandibular segments that allowed easier insertion and fixation of the plate; nevertheless, the proximal segment showed lateral displacement, leading to increase in the width of the mandible. This increase in the mandibular width was also reported by many authors.^{9,12} Unfortunately, no comparable data was found in the literature regarding the clinical relevance of the increase or decrease in the width of the mandible as stated by Wilde et al.¹⁰

One of the main goals of mandibular reconstruction is the preservation of the condylar position in the glenoid fossa, to maintain adequate TMJ functions and overcome TMJ disorders such as pain, clicking, or malocclusion.^{29,30} During mandibular reconstruction, condylar position is usually controlled by the joint capsule, ligaments, and mandibular fossa. These anatomical structures can restore the physiological position of the TMJ without the help of pre-bent plates as reported by Naros et al.¹² This is in line with the results of this study, as there was no significant differences in the A-A` and B-B` measurements in both groups. On contrary, many authors^{12,31} reported that the condyle may show rotational error in the glenoid fossae during mandibular reconstruction. Moreover, Naros et al.¹² stated that even small deviations in this sensitive area may cause long-term effects, which may require manual therapy even years after surgery. The author observed a nonsignificant postoperative condylar rotation in both groups, as noted by the postoperative changes in B`XC° and ICA. This abnormal condylar position may result in TMJ dysfunction even years after reconstructive surgery.^{12,31,32} These outcomes have been seldom evaluated and it should be taken into consideration, when evaluating the patients in the future. Despite the changes in the position of the proximal segment after reconstruction, no patient had postoperative malocclusion; this may be because the postoperative changes are considered nonsignificant when compared to the preoperative values and due to the application of postoperative guiding elastics in all dentate patients. Huang et al.³³ stated that even when the occlusal relation is well recovered, the position of the condyle can change considerably because of the anti-displacement or rotation that may occur when the remaining mandibular segments are short after segmental resection.

Rotational errors were also observed in this study, as reflected by the change in the diagonal distance from the contralateral condyle (B) to the ipsilateral angle (C`); the proximal segment showed

mediocranial rotation in group 1 and laterocaudal rotation in group 2. Mediocranial rotational errors were also observed by Naros et al,¹² who stated that the intraoperative bending of the plate could result in a compensatory rotational error due to plate tension and inaccurate bending on the RPM. Moreover, many authors^{9,10} discussed additional factors that could lead to 3D positional changes in the proximal segment after mandibular reconstruction; first, the pre-bent plate may not be contoured accurately enough on RPM leading to the release of internal stresses, and then shift in the proximal segment.¹⁰ Second, there might be a mislocation of the pre-bent plate during fixation after bone resection, in cases where the tumor size made the accessibility to the mandible difficult and temporary plate fixation could not be performed before resection, thus the plate was only adjusted according to its outline that was marked on the RPM. Finally, if the lesion is crossing the midline and the mirroring protocol is difficult to be applied in such cases, so segmentation of a normal mandible of another person¹³ can be imported as performed in this study and used as a reference mandible to fill the defect, this might result in the production of inaccurate RPM.

There were several limitations in the present study. The sample size was small. A larger number of patients for a longer follow up period would be required to confirm the study outcomes. Strengths of this study include, the 3D information on the postoperative position of the proximal segment in mandibular reconstruction surgery using extraoral and intraoral approaches, beyond the limited 2D based access. In addition, it was a single-institution experience and evaluated multiple outcomes.

CONCLUSION

The insertion of the pre-bent reconstruction plate via intraoral and extraoral approaches provides successful surgical outcomes. The intraoral approach is more conservative thereby achieving the best esthetic outcomes and resulting in a more

accurate 3D mandibular reconstruction. Therefore, this approach is considered the treatment of choice for resection and reconstruction of mandibular ameloblastoma. However, if the reconstruction plate cannot be inserted and adapted intraorally, because of the aggressive extension of the ameloblastoma, then extraoral approach is advised. Long-term follow-up is recommended to assess the risk of development of TMJ disorders.

Funding sources: This research did not receive any specific grant from funding agencies in the public, commercial, or not-for-profit sectors.

Funding disclosures: There are no funding disclosures from any authors.

Conflict of interest: No conflicts of interest.

ACKNOWLEDGMENTS

The author would like to thank Dr. Wafaa Anwar, Demonstrator of Oral and Maxillofacial Surgery, Faculty of Dental Medicine for Girls, Al-Azhar University for her valuable work in computer-assisted design and rapid prototyping. Special thanks to Dr. Susan Abdel-Hakim Hassan, Professor of Oral and Maxillofacial Surgery, Faculty of Dental Medicine for Girls, Al-Azhar University for her assistance and performance during the surgeries.

REFERENCES

1. Avelar RL, Primo BT, Pinheiro-Nogueira CB, Studart-Soares EC, de Oliveira RB, Romulo de Medeiros J, Hernandez PA. Worldwide incidence of odontogenic tumors. *J Craniofac Surg* 22: 2118-2123, 2011.
2. Fregnani ER, da Cruz Perez DE, de Almeida OP, Kowalski LP, Soares FA, de Abreu Alves F. Clinico-pathological study and treatment outcomes of 121 cases of ameloblastomas. *Int J Oral Maxillofac Surg* 39:145-149, 2010.
3. Cox DP, Muller S, Carlson GW, Murray D. Ameloblastic carcinoma ex ameloblastoma of the mandible with malignancy-associated hypercalcemia. *Oral Surg Oral Med Oral Pathol Oral Radiol Endod* 90:716-722, 2000.
4. Salgueiro MI, Stevens MR. Experience with the use of pre-bent plates for the reconstruction of mandibular defects. *Craniofac Trauma Reconstr* 3: 201-208, 2010.

5. Azuma M, Yanagawa T, Ishibashi-Kanno N, Uchida F, Ito T, Yamagata K, Hasegawa S, Sasaki K, Adachi K, Tabuchi K, Sekido M, Bukawa H. Mandibular reconstruction using plates pre-bent to fit rapid prototyping 3-dimensional printing models ameliorates contour deformity. *Head Face Med* 10: 45-53, 2014.
6. Wang YY, Zhang HQ, Fan S, Zhang DM, Huang ZQ, Chen WL, Ye JT, Li JS. Mandibular reconstruction with the vascularized fibula flap: comparison of virtual planning surgery and conventional surgery: *Int J Oral Maxillofac Surg* 45: 1400-1405, 2016.
7. Wurm MC, Hagen J, Nkenke E, Neukam FW, Schlittenbauer T. The fitting accuracy of pre-bend reconstruction plates and their impact on the temporomandibular joint. *J Craniomaxillofac Surg* 47: 53-59; 2019.
8. Cilento BW, Izzard M, Weymuller EA, Futran N. Comparison of approaches for oral cavity cancer resection: Lip-split versus visor flap. *Otolaryngol Head Neck Surg* 137: 428-432, 2007.
9. Wilde F, Plail M, Riese C, Schramm A, Winter K. Reconstruction plates: comparison of a transfer key method to the standard method—results of an in vitro study. *Int J CARS* 7:57-63, 2012.
10. Wilde F, Winter K, Kletsch K, Lorenz K, Schramm A. Mandible reconstruction using patient-specific pre-bent reconstruction plates: comparison of standard and transfer key methods. *Int J CARS* 10:129-140, 2015.
11. Zhang WB, Yu Y, Wang Y, Mao C, Liu XJ, Guo CB. Improving the accuracy of mandibular reconstruction with vascularized iliac crest flap: role of computer assisted techniques. *J Craniomaxillofac Surg* 44: 1819-1827, 2016.
12. Naros A, Weise H, Tilsen F, Hoefert S, Naros G, Krimmel M, Reinert S, Polligkeit J. Three-dimensional accuracy of mandibular reconstruction by patient specific pre-bent reconstruction plates using an “in-house” 3D-printer. *J Craniomaxillofac Surg* 46:1645-1651, 2018.
13. Hou JS, Chen M, Pan CB, Wang M, Wang JG, Zhang B, Tao Q, Wang C, Huang HZ. Application of CAD/CAM-assisted technique with surgical treatment in reconstruction of the mandible. *J Craniomaxillofac Surg* 40: e432-e437, 2012.
14. Reichart PA, Philipsen HP, Sonner S. Ameloblastoma: biological profile of 3677 cases. *Eur J Cancer B Oral Oncol* 31B: 86-99, 1995.
15. Bianchi B, Ferri A, Ferrari S, Leporati M, Copelli C, Ferri T, Sesenna E. Mandibular Resection and Reconstruction in the Management of Extensive Ameloblastoma. *J Oral Maxillofac Surg* 71: 528-537, 2013.
16. Akinosi JO, Williams AO. Ameloblastoma in Ibadan Nigeria. *Oral Surg Oral Med Oral Pathol* 27: 257-265, 1969.
17. Mitchel DA, Mitchel L. *Clinical dentistry*. 3rd ed. New York: Oxford University Press, Inc. 2003: pp. 424.
18. Arotiba GT, Ladeinde A, Arotiba JT, Ajike SO, Ugboko VI. Ameloblastoma in Nigerian children and adolescents: a review of 79 cases. *J Oral Maxillofac Surg* 63: 747-751, 2005.
19. Adekeye EO. Ameloblastoma of the jaws: a survey of 109 Nigerian patients. *J Oral Surg* 38: 36-41, 1980.
20. Al-Qamachi L, Mawji S, Nandra B, Aga H, Praveen P, Martin T, Parmar S. Staging Resection and Reconstruction in Solid Ameloblastomas to reduce the rate of positive margins and recurrences. *Br J Oral Maxillofac Surg* 54: e66-e153, 2016. Free poster abstracts
21. Al Shetawi AH, Fernandes R. Alternative Approach in Mandibular Reconstruction for Benign Disease. *J Oral Maxillofac Surg* 76:229.e1-229.e9, 2018.
22. Myers EN. Reconstruction of the oral cavity. *Otolaryngol Clin North Am* 5:413-433, 1972.
23. Bianchi B, Ferri A, Ferrari S, Copelli C, Sesenna E. Subtotal mandibular reconstruction using an intraoral approach: Report of 2 cases. *J Oral Maxillofac Surg* 66: 2654-2656, 2008.
24. Jacobson AS, Alpert E, Persky M, Okay D, Buchbinder D, Lazarus C. Transoral mandibulectomy and double barrel fibular flap reconstruction. *Laryngoscope* 125:2119-2122, 2015.
25. Cohen A, Laviv A, Berman P, Nashef R, Abu-Tair J. Mandibular reconstruction using stereolithographic 3-dimensional printing modeling technology. *Oral Surg Oral Med Oral Pathol Oral Radiol Endod.* 108:661-666, 2009.
26. Hirsch DL, Garfein ES, Christensen AM, Weimer KA, Saddeh PB, Levine JP. Use of computer aided design and computer-aided manufacturing to produce orthognathically ideal surgical outcomes: A paradigm shift in head and neck reconstruction. *J Oral Maxillofac Surg* 67: 2115-2122, 2009
27. Zweifel DF, Simon C, Hoarau R, Pasche P, Broome M. Are virtual planning and guided surgery for head and neck reconstruction economically viable? *J Oral Maxillofac Surg* 73: 170-175, 2015.
28. Cevidanes LH, Styner MA, Proffit WR. Image analysis and superimposition of 3-dimensional cone-beam com-

- puted tomography models. *Am J Orthod Dentofacial Orthop* 129: 611–618, 2006.
29. Wolford LM, Reiche-Fischel O, Mehra P. Changes in temporomandibular joint dysfunction after orthognathic surgery. *J Oral Maxillofac Surg* 61: 655-660, 2003.
 30. Bak M, Jacobson AS, Buchbinder D, Urken ML. Contemporary reconstruction of the mandible: *Oral Oncology* 46: 71-76, 2010.
 31. Sawh-Martinez R, Parsaei Y, Wu R, Lin A, Metzler P, DeSesa C, Steinbacher DM. Improved temporomandibular joint position after 3-Dimensional planned mandibular reconstruction. *J Oral Maxillofac Surg* 75:197-206, 2017.
 32. Crawford SD. Condylar axis position, as determined by the occlusion and measured by the CPI instrument, and signs and symptoms of temporomandibular dysfunction. *Angle Orthod* 69: 103-116, 1999.
 33. Huang JW, Shan XF, Lu XG, Cai ZG. Preliminary clinic study on computer assisted mandibular reconstruction: The positive role of surgical navigation technique. *Plast Reconstr Surg* 37: 20-27, 2015.