

## Pre-treatment of ozone therapy in rat model provides good prophylaxis against nephrotoxicity induced by cyclophosphamide

Gehan Moustafa Badr<sup>1,2</sup>

<sup>1</sup>Zoology Department, Faculty of Science, Ain Shams University, Abbassia, 11566, Cairo, Egypt.

<sup>2</sup>Biological Sciences Department, Faculty of Science, King Faisal University, P.O. 380, Al hasa 31982, Saudi Arabia.

Received: 28 Nov. 2015  
Accepted: 16 Jan 2016  
Available online: 7 Feb 2016

### Keywords

- Cyclophosphamide
- Ozone therapy
- Kidney
- Serum
- Histopathology

### Abstract

Cyclophosphamide (CP) is a drug with a wide spectrum of clinical uses. It has a potent effect in treatment of many types of cancers. CP adverse side effects limit its therapeutic uses. Renal damage is one of the limiting side effects of CP. Recently; ozone therapy (OT) has important clinical effects in minimizing the renal injury. Thus, the aim of our study was to investigate whether ozone has potency to reduce the adverse toxic effects of cyclophosphamide in rat kidney. **Methods:** Forty male albino rats were divided in five groups: Control (C), cyclophosphamide –induced nephrotoxicity (CPIN) injected I.P. with a single dose 200mg/kg CP. Two groups treated with CP in pre- or post-treatment of ozone therapy PRO/POO; respectively and the fifth group is ozone- only treated group (OT- only), rats treated with a single I.P. dose of ozone/oxygen mixture (0.7 mg/kg). Serum and kidney tissues used to evaluate the urea and creatinine levels, histopathological examinations, oxidative stress parameters and pro-inflammatory cytokines expressions. **Results:** The results showed that CP administration caused damage in the kidney after 24 h with significant decrease in total glutathione (tGSH), super oxide dismutase (SOD) and increased in lipid peroxidation (MDA) and nitric oxide (NO) values. In line with elevations in the serum (TNF- alpha) and (IL-6). The results showed improvement in PRO group but no changes in POO group compared to the CPIN group results. **Conclusions:** The study represents that pre-treatment of ozone decreased the renal severity of CP in a manner leading to modulations in kidney histopathology alterations.

## INTRODUCTION

Treatment with a gas mixture comprising O<sub>2</sub> and O<sub>3</sub> is known as ozone therapy (OT). Although O<sub>3</sub> is a potent oxidant agent, it may act as antioxidant agent at low doses <sup>[1]</sup>. Ozone (O<sub>3</sub>) used in treatment of numerous diseases such as wounds, advanced ischemic infectious diseases, chronic skin ulcers, burns, diabetes, inflammations, arthritis, renal and hepatic ischemia-reperfusion injury <sup>[2]</sup>. Ozone treatment showed an improvement in antioxidant mechanisms against free radicals <sup>[3, 4]</sup>. Ozone therapy significantly reduced the nephrotoxicity mediated by reactive oxygen species (ROS), by decreasing the malondialdehyde (MDA) level, normalizing the renal histology, supporting the cellular antioxidant defense to reduce local levels of ROS, such as superoxide anion by superoxide dismutase (SOD) and hydrogen peroxide by glutathione peroxidase (GSH-Px) <sup>[4]</sup>. Previous studies indicated the protective effect of ozone closely related to the NO production in injured tissue <sup>[5-7]</sup>. The ozone post-conditioning in diabetic cardiomyopathy patients and pre-conditioning in methotrexate-induced intestinal injury have demonstrated decreasing tissue damage, control of free radicals and oxidative stress by improving the antioxidant defense mechanisms <sup>[8, 9]</sup>.

The majority of cancer chemotherapeutic agents even their successful results in human cancers showed induction of undesirable physiological side effects. The anticancer chemotherapeutic drug cyclophosphamide induce oxidative stress, it plays a major role in kidney toxicity associated with its two active metabolites; phosphoramidate mustard which increase the

production of free oxygen radicals and acrolein which cause the adverse effects to renal epithelium <sup>[10, 11]</sup>.

The nephrotoxicity of CP is due to the overproduction of ROS during inflammation leading to histopathological changes in rat kidneys affecting the redox status <sup>[12-17]</sup>. The alterations of the renal function (Urea and Creatinine levels) induced by CP will be accompanied by the changes in the serum Nitric oxide (NO); the amino acid L-arginine derivative, which is an intercellular messenger regulating cellular functions and inflammation.

Overproduction NO accompanied by tissue injury and may contribute to T-cell dysfunction where NO under physiological condition has been shown to regulate T-cell function <sup>[18-20]</sup>. Lower concentrations of NO have direct effects on proliferation and cell survival, while high concentrations serves nitrosative stress and oxidative stress <sup>[21]</sup>. The CP toxicity involved release of cytokines and inflammatory mediators into the blood stream mediating inflammation and act as central stimuli for the acute phase response <sup>[15, 20]</sup>.

Recent studies showed that pre-conditioning ozone significantly inhibit the increased levels of some inflammatory cytokines like TNF- $\alpha$ , IL-1 $\beta$  and IL-6 induced by renal ischemic reperfusion injury <sup>[22]</sup>.

The present study designed to investigate the impact of ozone anti-inflammatory activity in prophylaxis and/or treatment of cyclophosphamide renal injury in rat model.

## MATERIALS AND METHODS

The present study was carried on (40) adult male albino rats (*Rattus norvegicus*), weighing (230±20g). Animals housed in cages with free access to water and food, at temperature of 22 ± 2°C, on a 12-hour light/dark cycle. All experimental protocols are in accordance with the Guidelines for Ethical Care of Experimental Animals. Cyclophosphamide (CP) was purchased in the form of white powder under the trade name of Endoxan (ASTA Medica AG, Germany).

### *Experimental Design:*

Control group (C): Animals injected intraperitoneally 1ml normal saline and sacrificed after 24h. Cyclophosphamide-induced nephrotoxicity group (CPIN): Animals intraperitoneally injected with single dose of cyclophosphamide 200 mg/kg b.w. in 1 ml of normal saline [23].

Pre-treated Ozone group: Animals injected intraperitoneally with a single dose of ozone/oxygen mixture 0.7 mg/kg b.w. 24 hrs before CP administration as in CPIN group [24].

Post-treated Ozone group: Animals injected intraperitoneally with a single dose of ozone/oxygen mixture 0.7 mg/kg b.w. 24 hrs after CP administration as in CPIN group [24].

Ozone treated group (OT): Animals injected intraperitoneally with a single dose of ozone/oxygen mixture 0.7 mg/kg b.w.

### *Ozone treatment*

Ozone treatment performed immediately Pre/Post the induction of kidney injury by CP in the rats. Ozone generated with ozonator equipment. Ozone used immediately upon generation and represented

only about 3% of the O<sub>3</sub>/O<sub>2</sub> gas mixture. The ozone concentration measured by an UV spectrophotometer at 254 nm. The ozone dose expressed as mg/L is the product of the ozone concentration by the gas mixture volume (L). By knowing the body weight of the rat, the ozone doses calculated as 0.7 mg/kg b.w. The volume of each ozone dose was 1ml [24]. (Environmental Sciences, National Research Centre).

### *Biochemical Assays*

At the end of the experiment, immediately blood collected for serum preparation to estimate the biochemical parameters: serum creatinine [25], urea [26], nitric oxide (NO) [27]. In addition, to cytokines, serum tumor necrosis factor-alpha (TNF- $\alpha$ ) and Interleukine-6 (IL-6) were measured by using Thermo Fisher Scientific Rat TNF- $\alpha$ . ELISA Kit (Catalog No. KRC3011) and Rat IL-6 ELISA Kit, (Catalog. No. KRC0061), respectively. Fresh kidneys were separated and washed with ice-cold phosphate-buffered saline (PBS) solution (10 mM Na<sub>2</sub>HPO<sub>4</sub>, 10 mM KH<sub>2</sub>PO<sub>4</sub>, 0.9 g NaCl/100 mL, pH 7.4). Homogenization of right kidney was done using glass-teflon homogenizing tube under ice-cold condition. The tissue homogenate centrifuged at 2500 rpm for 10 min and supernatant kept at -70°C until used for the colorimetric determination of total glutathione (tGSH) [28], superoxide dismutase (SOD) [29] and malondialdehyde (MDA) [30].

### *Estimation of renal TNF- $\alpha$ and IL-6 levels*

Renal TNF- $\alpha$  and IL-6 determined by homogenizing the tissue in 5% PBS, each aliquot containing 300  $\mu$ g of total protein used for the assay by ELISA kit as aforementioned.

### *Expression analysis and PCR reaction of renal IL-6 and TNF- $\alpha$*

Total RNA extracted from kidney tissue, then mRNA purified from each by using GeneJET™ RNA Purification Kit (Fermentas) and used for first strand cDNA (complementary DNA) synthesis by reverse transcription using Revert Aid™ First Strand cDNA Synthesis Kit (Fermentas) according to the manufacturer protocol. The cDNA for IL-6 and TNF- $\alpha$  was used as the template for the specific primers and while amplification was done using PTC-100™ by thermal controller (MJ, U.S.A.). The PCR products were run by agarose gel electrophoresis and resultant bands were explored and the density of each band was compared with that of  $\beta$ -actin as a positive control.

### *Light microscopy study*

The left kidney fixed in 10% neutral buffered formalin for 24 hours then embedded in paraffin and sectioned at 3 and 5  $\mu$ m thick and stained with hematoxylin and eosin (H&E) and followed by microscopically examination<sup>[31]</sup>.

### *Statistical analysis*

Data expressed as means  $\pm$  SEM. Statistical analysis evaluated by one-way ANOVA. Once a significant F test obtained, LSD comparisons performed to assess the significance of differences among various treatment groups. Statistical Processor System Support "SPSS" for Windows software, Release 20.0 (SPSS, Chicago, IL) was used.

## **RESULTS**

### *Effect of ozone on serum and renal biochemical parameters*

As shown in table (1): CPIN group showed significant increase in the levels of creatinine, urea and NO in serum and MDA in kidney homogenate as well as significant decrease in kidney tGSH level and SOD activity as compared to control group values.

Meanwhile, urea level increased significantly in OT group comparing to the control value. The results of OT group compared to that of CPIN group showed significant increase in the kidney tGSH level & SOD activity and significant decrease in serum creatinine, urea and NO and kidney MDA levels.

The results of ozone pretreated group compared to CPIN group showed significant improvement in all parameters in a manner that tend to reverse that in CPIN group achieving normalization. Data about POO group showed significant decrease in NO level and increase in tGSH value as compared to CPIN group values. On the other hand the results of ozone post-treatment compared to the ozone pre-treatment showed significant increase in the levels of creatinine, Urea and NO in serum and MDA in kidney homogenate as well as significant decrease in kidney tGSH level and SOD activity, reflecting failure of the post treatment as compared to pretreatment of ozone to overcome the effect of cyclophosphamide. Post-treatment group declared no significant changes in all biochemical parameters.

### *Effect of ozone on cytokines TNF- $\alpha$ and IL-6 in serum and kidney*

As shown in Fig. 1, TNF- $\alpha$  and IL-6 levels were increased significantly in serum as well as their expressions in kidney of the CPIN group compared to the control values. The OT group exhibited significant decrease in TNF- $\alpha$  and IL-6 levels in serum and their expression in the kidney compared to CPIN group. In addition, kidney TNF- $\alpha$  level decreased significantly in OT group as compared to their levels in pre and post-treated groups. Serum and renal tissue level of IL-6 were significantly decreased in OT group compared to that recorded in ozone pretreated group.

The cytokine levels in serum and kidney levels and expressions recorded in ozone pretreated group decreased significantly as compared to values in CPIN and ozone post-treated groups.

### *Effect of ozone on kidney histopathology*

The histopathological examination of the kidney tissue in control group demonstrated normal renal parenchyma and normal glomerular and tubular structure (Fig. 2A). Kidney of ozone treated rat showing the normal histological structure of renal parenchyma (Fig.2B).

Kidney cyclophosphamide (CPIN) group showed glomerular atrophy, acute tubular necrosis, vacuolation and congestion of endothelial lining

glomerular tuft and epithelial lining renal tubules as well as protein cast in the lumen of some renal tubules (Fig. 2C-D). The pretreatment with ozone in the PRO group showed apparent normal renal parenchyma and normal glomerular and tubular structure (Fig. 2E). Kidney of rat post treated with ozone in POO group showed congestion of glomerular tuft and congestion of the intertubular blood vessels (Fig. 2F-G H).

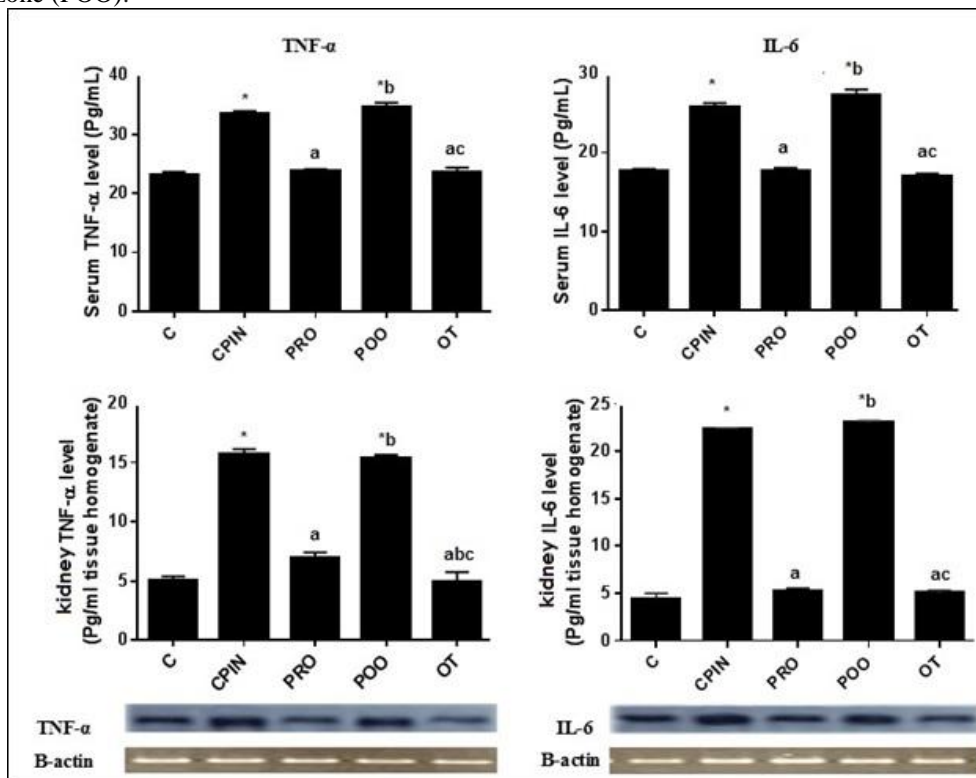
## **DISCUSSION**

Cyclophosphamide (CP) can disturb the biochemical and physiological functions resulting from oxidative stress by disrupting the balance between ROS release and tissue antioxidant system leading to the development of tissue damage in animals<sup>[32-34]</sup>. The cellular mechanism for cyclophosphamide toxicity in kidney explained through its cellular oxidative stress, by reacting with unsaturated fatty acids in membranes causing structural and physiological adverse changes and oxidation of the lateral chains of amino acid and protein skeleton resulting in fragmentation<sup>[35,36]</sup>. This is done due to the active metabolites of CP (phosphoramidate and acrolein), which slow down the growth of cancer cells as they interfere with the cellular DNA<sup>[36]</sup>. Acrolein cause alkylation of renal cells by its sulfhydryl group and this alkylation leads to variable reduction of glomerular filtration rate as well as tubular dysfunction resulting from acute renal failure<sup>[36]</sup>. This feature of oxidative stress reflected histopathologically in our work by the glomerular atrophy, acute tubular necrosis, vacuolation and congestion of endothelial lining glomerular tuft and epithelial lining renal tubules as well as protein cast in the lumen of some renal tubules.

**Table (1):** Effect of ozone on serum and kidney biochemical parameters

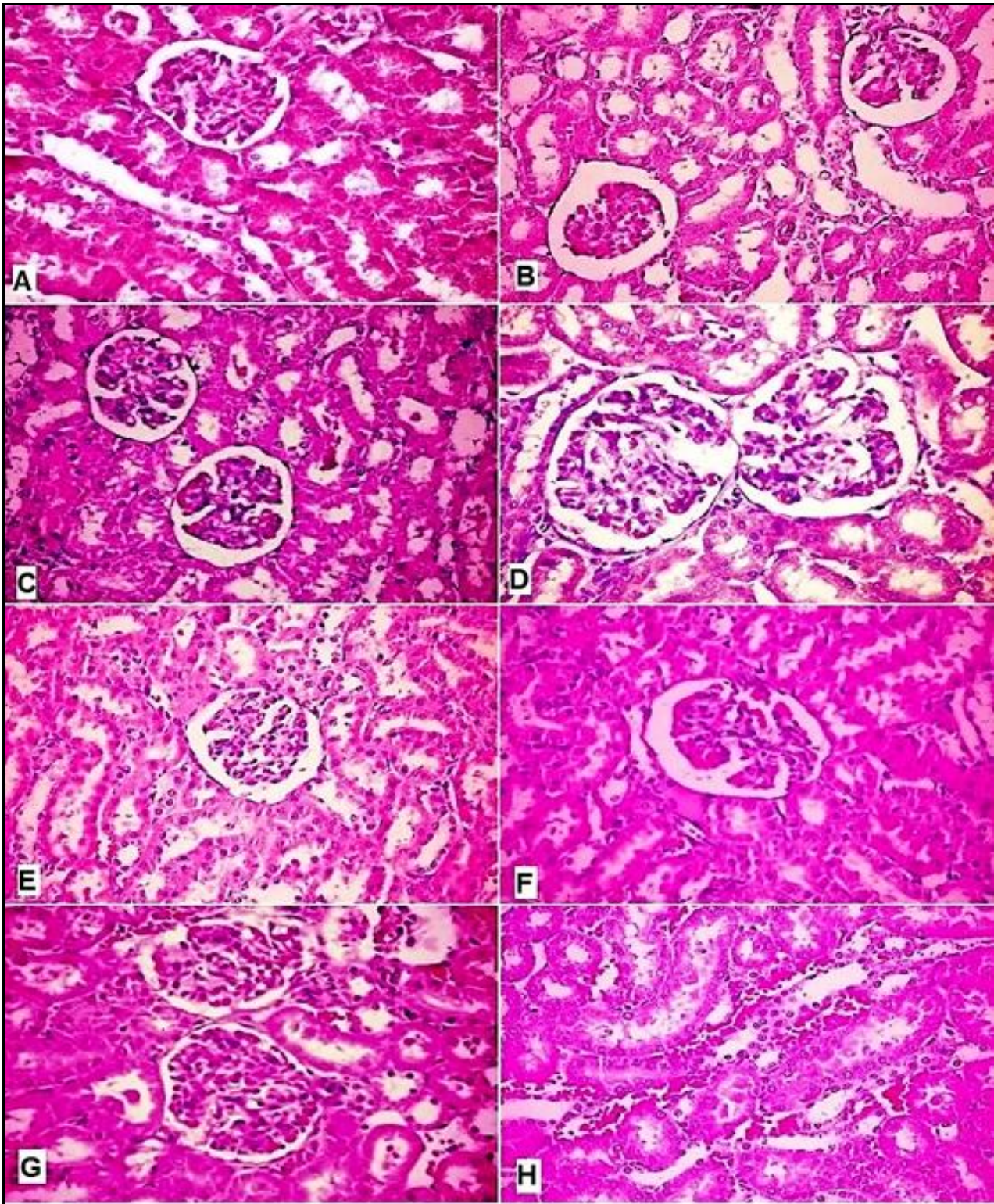
Tissues	Group	C	CPIN	PRO	POO	OT
	Item					
Serum	<b>Creatinine</b> (mg%)	0.77±0.03	1.26± 0.05 <sup>*</sup>	0.83± 0.01 <sup>a</sup>	1.18± 0.043 <sup>*b</sup>	0.79±0.01 <sup>ac</sup>
	<b>Urea</b> (mg%)	36.49±0.52	45.95±0.32 <sup>*</sup>	38.27±0.36 <sup>*a</sup>	45.65±0.38 <sup>*b</sup>	37.76±0.43 <sup>*ac</sup>
	<b>NO</b> (µmol/L)	14.29±0.15	35.89±0.36 <sup>*</sup>	15.09±0.29 <sup>a</sup>	34.93±0.49 <sup>*b</sup>	14.55±0.19 <sup>ac</sup>
Kidney	<b>tGSH</b> (nmole/g)	19.25±0.15	3.52± 0.09 <sup>*</sup>	12.45±0.07 <sup>*a</sup>	4.39± 0.43 <sup>*ab</sup>	19.01±0.24 <sup>abc</sup>
	<b>SOD</b> (U/g)	76.08±0.38	29.71±1.07 <sup>*</sup>	70.52±1.21 <sup>*a</sup>	30.68±1.93 <sup>*b</sup>	76.01±0.52 <sup>abc</sup>
	<b>MDA</b> (U/g)	91.63±0.13	233.40±3.22 <sup>*</sup>	116.36±2.14 <sup>*a</sup>	238.14±3.50 <sup>*b</sup>	101.32±1.42 <sup>ac</sup>

Data expressed as mean ± SEM (n=8). Significance (p < 0.05) between groups represented by superscripts as (<sup>\*</sup>) significant as compared to control (C) group, (<sup>a</sup>) significant as compared to cyclophosphamide induced nephrotoxicity (CPIN) group, (<sup>b</sup>) significant as compared to pre-treated with ozone (PRO) group, (<sup>c</sup>) significant as compared to Post-treated with ozone (POO).



**Figure 1:** Effect of ozone on serum and kidney IL-10 (pg/ml) and TNF-α (pg/mL) levels and expression. Data expressed as mean±SEM (n=8). Significance (p < 0.05) between groups represented by superscripts as (<sup>\*</sup>) significant as compared to control (C) group, (<sup>a</sup>) significant as compared to cyclophosphamide induced nephrotoxicity (CPIN) group, (<sup>b</sup>) significant as compared to pre-treated with ozone (PRO) group, (<sup>c</sup>) significant as compared to Post-treated with ozone (POO).





**Figure 2:** Light micrograph of kidney in control group (C) showing normal glomerular appearance Fig. (A). Light micrograph of Kidney of ozone treated group (OT) showing the normal histological structure of renal parenchyma Fig. (B). Light micrograph of Kidney of cyclophosphamide (CPIN) group showing glomerular atrophy, acute tubular necrosis, vacuolation and congestion of endothelial lining glomerular tuft and epithelial lining renal tubules as well as protein cast in the lumen of some renal tubules Figs. (C and D). Light micrograph of kidney of ozone pretreated group (PRO) showing normal renal parenchyma and normal glomerular and tubular structure Fig. (E). Light micrograph of kidney of ozone post treated (POO) group showing congestion of glomerular tuft and congestion of the intertubular blood vessels Figs. (F, G and H). (H&Ex100)



This assessed by the explorative renal function indicators serum NO, urea and creatinine significantly elevated in CPIN group as well as the elevated serum levels of the proinflammatory cytokines, TNF- $\alpha$ , IL-6,. In addition to the significant increase in kidney MDA level and decrease in tGSH level and SOD activity. Our results in line with previous results suggesting that depletion of GSH content may be attributed to the direct conjugation of CP and its metabolites with free or protein bound -SH groups leading to decrease the levels of some glutathione antioxidant enzymes<sup>[37,38]</sup>. In line with elevated MDA which lead to the destruction of membrane lipids and the excessive NO production cause nitrosative stress that induce renal damage<sup>[39,40-43]</sup>. The pro-inflammatory cytokines, TNF- $\alpha$ , IL-6 and their mRNA levels increased significantly in response to CP-induced renal damage. TNF- $\alpha$  that induce numerous mediators associated with glomerular endothelial damage and renal tissue failure and play a key role in the development, activation of the inflammatory cytokine response in the mouse model of nephrotoxicity and maintenance of inflammatory response<sup>[22, 44]</sup>. The other proinflammatory cytokine IL-6 is the initiator of the inflammatory response and its high expression level is a marker of inflammation and its production is also a common response to tissue injury and organ failure<sup>[44-47]</sup>.

The therapeutic strategy to prevent the renal toxicity is to decrease the production of ROS as much as possible or neutralize them as early as possible. The present results clarified that pre-treatment with ozone significantly prevented CP-induced lipid peroxidation which manifested in reduced (MDA) and increased tGSH in the renal

tissue which could be explained by decreasing the ROS formation through improvement in oxidant status<sup>[48,49]</sup>. Our data confirmed that ozone pre-treatment significantly reduced urea and creatinine, improved renal function and demonstrated increase in SOD activity and hence, morphology and histological appearance. Meanwhile, lesions were remained in the ozone post-treated group. The current study showed that ozone affects NO level protectively in similar to some previous studies in which preconditioning ozone significantly lowered the levels of serum and renal NO and renal total antioxidant system in CP treated group<sup>[50]</sup>. In addition to that, ozone modulated CP-induced renal damage by improving kidney-metabolizing enzymes, suppressing oxidative stress, inhibiting renal proinflammatory cytokines. As ozone pre – treatment significantly reduce the mRNA level of TNF- $\alpha$  and IL-6 Thus, our data indicated that ozone pre-treatment reduced the inflammatory responses after renal injury. In the present findings, It has been clearly demonstrated that ozone provide some sort of pre-treatment and has protective effect in kidneys while, in ozone post-treated group may increase the oxidative stress. Ozone pre-treatment not only increases antioxidant endogenous systems but also regulates ROS. Previous study explained that ozone is able to maintain the body calcium homeostasis preventing any damage of cell structure<sup>[2]</sup>.

## CONCLUSION

The current study declared the effect of pre and post treatment of ozone on cyclophosphamide-induced renal failure in rats. The data confirmed the protective role of ozone treatment on renal



tissue damage induced by cyclophosphamide through a quantitative survey on oxidative stress, inflammatory response and renal histopathology. The study represents that pre-treatment of ozone-decreased severity of injury induced by CP which indicated by reducing the renal MDA and increasing GSH and SOD values in line with reducing serum urea, creatinine and NO values. In addition to the decrease in the proinflammatory cytokines TNF- $\alpha$  and IL-6 in serum, kidney and their tissue expressions leading to modulations in renal structural alterations.

### CONFLICT OF INTEREST

The author has declared that no conflict of interests exists.

### ACKNOWLEDGMENT

The author gratefully acknowledges the Deanship of the Scientific Research, King Faisal University, Saudi Arabia, for funding all the biochemical parameters.

### REFERENCES

1. **Ozler M, Oter S, Korkmaz A:** The use of ozone gas for medical purposes. *TAF PrevMed Bull* 8: 59-64, 2009.
2. **Re L, Mawsouf MN, Menendez S, Leon OS, Sanchez GM, and Hernandez F:** Ozone therapy: clinical and basic evidence of its therapeutic potential. *Arch Med Res* 39: 17–26, 2008.
3. **Calunga JL, Zamora ZB, Borrego A, Sarahi del Rio, Barber E, Menendez S, Hernandez F, Montero T, Taboada D:** Ozone Therapy on Rats Submitted to Subtotal Nephrectomy: Role of Antioxidant System. *Mediators of Inflammation* 4: 221–227, 2005.
4. **Ucar F, Taslipinar MY, Alp BF, Aydin I, Aydin FN, Agilli M, Toygar M, Ozkan E, Macit E, Oztosun M, Cayci T, Ozcan A:** The effects of N-acetylcysteine and ozone therapy on oxidative stress and inflammation in acetaminophen-induced nephrotoxicity model. *Ren Fail* 35: 640-647, 2013.
5. **Chen H, Xing B, Liu X, Zhan B, Zhou J, Zhu H, Zhiyuan, Chen Z:** Ozone Oxidative Preconditioning Protects the Rat Kidney from Reperfusion Injury: The Role of Nitric Oxide. *Journal of Surgical Research* 149: 287–295, 2008.
6. **Demirbag S, Uysal B, Guven A, Cayci T, Ozler M, Ozcan A, Kaldirim U, Surer I, Korkmaz A:** Effects of medical ozone therapy on acetaminophen-induced nephrotoxicity in rats. *Ren Fail* 32: 493-7, 2010
7. **Koca K, Yutttaş Y, Yıldız C, Cayci T, Uysal B, Korkmaz A:** Effect of hyperbaric oxygen and ozone preconditioning on oxidative/nitrosative stress induced by tourniquet ischemia/reperfusion in rat skeletal muscle. *Acta Orthop Traumatol Turc* 44: 476-483, 2010.
8. **Calunga JL, Trujillo Y, Mene'ndeza S, Zamorac Z, Alonsoc Y, Merinod N, Monteroe T:** Ozone oxidative post-conditioning in acute renal failure. *JPP*: 61: 221–227, 2009.
9. **Kesik V, Uysal B, Kurt B, Kismet E, Koseoglu V:** Ozone ameliorates methotrexate-induced intestinal injury in rats. *Cancer Biol Ther* 8: 1623-1628, 2009.

10. **Angulo I, Jimenez-Diaz MB, Garcia-Bustos JF, Gargallo D, de las Heras FG, Munoz-Fernandez MA, Fresno M:** Candida albicans infection enhances immunosuppression induced by cyclophosphamide by selective priming of suppressive myeloid progenitors for NO production. *Cell Immunol.* **218:** 46–58, 2002
11. **Kim SH, Lee IC, Lim JH, Moon C, Bae CS, Kim SH, Shin DH, Park SC, Kim HC, Kim JC:** Protective effects of pine bark extract on developmental toxicity of cyclophosphamide in rats. *Food Chem Toxicol* 50: 109–115, 2012.
12. **Abraham P, Rabi S:** Nitrosative stress, protein tyrosine nitration, PARP activation and NAD depletion in the kidneys of rats after single dose of cyclophosphamide. *Clin Exp Nephrol.* 13: 281–287, 2009.
13. **Ayhanci A, SibelGünes S, Sahinturk V, Appak S, Uyar R, Cengiz M, Altuner Y, Yaman S:** Seleno L-Methionine Acts on Cyclophosphamide-Induced Kidney Toxicity. *Biol Trace Elem Res* **136:** 171–179, 2010.
14. **Morsy MD, Hassan WN, Zalat SI:** Improvement of renal oxidative stress markers after ozone administration in diabetic nephropathy in rats. *Diabetology & Metabolic Syndrome* **2:** 29 doi: 10.1186/1758-5996-2-29, 2010.
15. **Sinanoglu O, Yener AN, Ekici S, Midi A, Fehime Benli Aksungar FB:** The Protective Effects of Spirulina in Cyclophosphamide Induced Nephrotoxicity and Urotoxicity in Rats. *UROLOGY* **80:** 1392.e1–1392.e6, 2012.
16. **Zuo L, Otenbaker NP, Bradley A, Rose BA, Salisbury KS:** Molecular mechanisms of reactive oxygen species-related pulmonary inflammation and asthma. *Molecular Immunology* **56:** 57–63, 2013.
17. **Ince S, Kucukkurt I, Demirel HH, Acaroz DA, Akbel E, Cigerci IH:** Protective effects of boron on cyclophosphamide induced lipid peroxidation and genotoxicity in rats. *Chemosphere* **108:** 197–204, 2014
18. **Huang HS, Ma MC, Chen CF, Chen J:** Changes in nitric oxide production in the rat kidney due to CaOx nephrolithiasis. *NeuroUrol Urodyn* **25:** 252–8, 2006
19. **Perl A, Fernandez DR, Talarico T, Doherty E, Francis L, Phillis PG:** T-cell and B-cell signaling biomarkers and treatment targets in lupus. *Curr Opin Rheumatol* **21:** 454 – 464, 2009.
20. **Otunctemur A, Ozbek E, Cakir SS, Polat EC, DursunM, Cekmen M, Somay A, Ozbay N:** Pomegranate extract attenuates unilateral ureteral obstruction-induced renal damage by reducing oxidative stress. *Urol Ann* **7:** 166–171, 2015.
21. **Chung HT, Pae HO, Choi BM, Billiar, TR, Kim YM:** Nitric oxide as a bioregulator of apoptosis. *Biochem. Biophys. Res Commun.* **282:** 1075-1079, 2001.
22. **Xing B, Chen H, Wang L, Weng X, Chen Z, Li X:** Ozone oxidative preconditioning protects the rat kidney from reperfusion injury via modulation of the TLR4-NF- $\kappa$ B pathway. *Acta Cir Bras* **1:** 60-66, 2015.
23. **Alenzi FQ, El-Bolkiny, Yel-S, Salem ML:** Protective effects of Nigella sativa oil and thymoquinone against toxicity induced by the anticancer drug cyclophosphamide. *Br J Biomed Sci.* **67:** 20-8, 2010.

24. **Gul H, Uysal B, Cakir E, Yaman H, Macit E, Yildirim AO, Eyi YE, Kaldirim U, Oztas E, Akgul EO, Cayci T, Ozler M, Topal T, Oter S, Korkmaz A, Toygar M, Demirbag S:** The protective effects of ozone therapy in a rat model of acetaminophen-induced liver injury. *Environ toxicol. Pharmacol* 34: 81-86, 2012.
25. **Henry RJ:** Clinical chemistry, principles and techniques, 2<sup>nd</sup> ed., Harper and Row, P.525, 1974
26. **Patton CJ, Crouch SR:** Enzymatic colorimetric determination of urea. *Anal Chem* 49: 464-469, 1977
27. **Cortas NK, Wakid NW:** Determination of inorganic nitrate in serum and urine by kinetic cadmium reduction method. *Clin Chem* 36: 1440-1443, 1990
28. **Sedlak J, Lindsay RH:** Estimation of total, protein bound, and non protein sulfhydryl groups in tissue with Ellman's reagent *Analytical Biochemistry* 25: 192-205, 1968
29. **Kwiecień S, Brzozowski T, Konturek PC, Konturek SJ:** The role of reactive oxygen species in action of nitric oxidedonors on stress-induced gastric mucosal lesions. *J Physiol Pharmacol* 53: 761-773, 2002
30. **Ohkawa H, Ohishi N, Yagi K:** Assay for lipid peroxides in animal tissues by thiobarbituric acid reaction. *Anal Biochem* 95: 351-358, 1979.
31. **Bancroft JD, Gamble M:** Theory and practice of histological techniques. Fifth ed. Churchill Livingstone. London. pp: 109-136, 2002.
32. **Selvakumar E, Prahalathan C, Mythili Y, Varalakshmi P:** Mitigation of oxidative stress in cyclophosphamide-challenged hepatic tissue by DL-alpha-lipoic acid. *Mol Cell Biochem* 272: 179-185, 2005
33. **Selvakumar E, Prahalathan C, Sudharsan PT, Varalakshmi P:** Protective effect of lipoic acid on cyclophosphamide-induced testicular toxicity. *Clin Chim Acta* 367: 114-119, 2006
34. **Tarek MK, Motawi Nermin AH, Sadik Refaat A:** Cytoprotective effects of DL-alpha-lipoic acid or squalene on cyclophosphamide-induced oxidative injury: An experimental study on rat myocardium, testicles and urinary bladder. *FoodChem Toxicol* 48: 2326-2336, 2010
35. **Abraham P, Indiranib K, Sugumar E:** Effect of cyclophosphamide treatment on selected lysosomal enzymes in the kidney of rats. *Exp Toxicol Pathol.* 59: 143-149, 2007
36. **Rehman MU, Tahir M, Ali F, Qamar W, Lateef A, Khan R, Quaiyoom A, Oday-O-Hamiza, Sultana S:** Cyclophosphamide-induced nephrotoxicity, genotoxicity, and damage in kidney genomic DNA of Swiss albino mice: the protective effect of Ellagic acid. *Mol Cell Biochem* 365: 119-127, 2012
37. **Cooper JA, Merrill WW, Reynolds HY:** Cyclophosphamide modulation of bronchoalveolar cellular populations and macrophage oxidative metabolism: possible mechanisms of pulmonary pharmacotoxicity. *Am Rev Respir Dis* 134: 108-114, 1986
38. **Kehrer JP, Biswal SS:** The molecular effects of acrolein. *Toxicol. Sci* 57: 6-15, 2000
39. **Schubert SY, Neeman I, Resnick N:** A novel mechanism for the inhibition of NF-kappaB activation in vascular endothelial cells by

- natural antioxidants. *FASEB J* 16: 1931–1933, 2002
40. **Kuhad A, Tirkey N, Pilkhwal S, Chopra K:** Effect of Spirulina, a blue green algae, on gentamicin-induced oxidative stress and renal dysfunction in rats. *Fundam Clin Pharmacol* 20: 121–128, 2006
41. **Abraham P, Sugumar E:** Enhanced PON1 activity in the kidneys of cyclophosphamide treated rats may play a protective role as an antioxidant against cyclophosphamide induced oxidative stress. *Arch Toxicol*. 82: 237–238, 2008.
42. **Bhatia K, Ahmad F, Rashid H, Raisuddin S:** Protective effect of S-allylcysteine against cyclophosphamide-induced bladder hemorrhagic cystitis in mice. *Food Chem Toxicol*. 46: 3368–3374, 2008.
43. **Abraham P, Rabi S:** Protective effect of aminoguanidine against cyclophosphamide induced oxidative stress and renal damage in rats. *Redox Rep*. 16: 8-14, 2011.
44. **Kim SH, Lee IC, Ko JW, Moon C, Kim SH, Shin IS, Seo YW, Kim HC, Kim JC:** Diallyl Disulfide Prevents Cyclophosphamide-Induced Hemorrhagic Cystitis in Rats through the Inhibition of Oxidative Damage, MAPKs, and NF- $\kappa$ B Pathways. *Biomol Ther* 23: 180-188, 2015
45. **Kielar ML, John R, Bennett M, Richardson JA, Shelton JM, Chen L, Jeyarajah DR, Zhou XJ, Zhou H, Chiquett B, Nagami GT, Lu CY:** Maladaptive role of IL-6 in ischemic acute renal failure. *J Am Soc Nephrol* 16: 3315-3325, 2005
46. **Hudzik B, Szkodzinski J, Danikiewicz A, Romanowski W, Lekston, A, Polonski L, Zubelewicz-Szkodzinska B:** Serum interleukin-6 concentration predicts contrast-induced nephropathy in patients undergoing percutaneous coronary intervention. *Eur Cytokine Netw* 21: 129-35, 2010
47. **Deng J, Wu G, Yang C, Li Y, Jing Q, Han Y:** Rosuvastatin attenuates contrast-induced nephropathy through modulation of nitric oxide, inflammatory responses, oxidative stress and apoptosis in diabetic male rats. *Journal of Translational Medicine* 13: 53 DOI 10.1186/s12967-015-0416-1, 2015
48. **Lu Y, Cederbaum A:** The mode of cisplatin-induced cell death in CYP2E1-overexpressing HepG2 cells modulation by ERK, ROS, glutathione, and thioredoxin. *Free Radic Biol Med* 43: 1061–1075, 2007
49. **Nannelli A, Messina A, Marini S, Trasciatti S, Longo V, Gervasi PG:** Effects of the anticancer dehydrotarplatin on cytochrome P450 and antioxidant enzymes in male rat tissues. *Arch Toxicol* 81: 479-487, 2007
50. **Ozbek E, Cekmen M, Ilbey YO, Simsek A, Polat EC, Somay A:** Atorvastatin prevents gentamicin-induced renal damage in rats through the inhibition of p38-MAPK and NF-kappaB pathways. *Ren Fail* 31: 382–92, 2009.
51. **Kurtoglu T, Durmaz S, Akgullu C, Gungor H, Eryilmaz U, Meteoglu I, Karul A, Boga M:** Ozone preconditioning attenuates contrast-induced nephropathy in rats. *J Surg Res* 15: S0022-4804, 2015.