

## **USING OF CELLS AND THEIR ORGANELLES AS TOOLS IN STUDY THE TOXIC EFFECT OF DELTAMETHRIN AND PROFENOFOS.**

**Negm, Salwa E.; M. M. Kady; A. A. Saleh and A. A. El Alfy  
Pesticides Dept., Fac. Agric., Mansoura Univ.**

### **ABSTRACT**

The purpose of the present study is to investigation the potential toxic effects of deltamethrin and profenofos (1/10 and 1/20 of LD<sub>50</sub>) that have different active ingredient on blood picture and ultrastructure changes on cell's contents of liver and Kidney as tools in study the toxic effects on albino rats.

Obtained data indicated that deltamethrin and profenofos at 1/10 and 1/20 of LD<sub>50</sub> caused increase in WBC's count after nine months. While the two formulations caused significant decrease in RBC's count after same time , similar effects were noticed on Hemoglobin value , and platelets count of treated rat.

No sharp variations were noticed between different two formulations and different doses in cellular organelles in liver cells treated rats. The results so far obtained indicated histo-and cytopathological alteration by electron microscope due to the effect of compounds when compared with control ones, some sections poorly differentiated hepatocellular showing marked polymorphis of the nuclei, irregularity of the chromatin and prominent nucleoli in treated rats with deltamethrin when compared with control. Also, in treated with profenofos showed numbers of nuclei and their content in different section by many powers of vision, results show differences and all treatments induce genotoxicity.

Kidney sections of different pesticides revealed many phases of degeneration changes when compared with those of control. Electron microscope appeared differentiated cells containing a cytoplasmic indentation or inclusion filled with brush border material and showed also, that cytoplasm is filled with prominent granular, endoplasmic reticulum containing some dense flocculam materials. Also, electron micrograph appeared differentiated in nuclei and changed in their content such as nucleolus, and chromosomes (chromatid and centromere) so, from the dose applied during nine months results conclude that all tested pesticides show genotoxicity in treated animals.

### **INTRODUCTION**

Pest control is necessary for adequate production of the food. Despite the important role of the insecticides in plant protection and health care programs, their widespread use is yet considered as one of the main causes in the creation of environmental pollution. This has stimulated research into evaluation of the toxic effect of various compounds which belong to different insecticides groups.

Organophosphorus and pyrethroides insecticides have been reported extensively to induce a variety of both peripheral and central effects. Among the peripheral effect are bronchial, involuntary defecation frequent, urination and bradycardia that can progress to heart block, whereas, central action include anxiety , emotional instability, tremor, depression of respiratory and circulatory centers at higher doses convulsion Davies *et al .*, (1975), Karemar (1984).

Generally, the present investigation was conducted to evaluate the chronic toxicity of deltamethrin and profenofos that widely used in open field on vegetables by measuring the effect on blood picture and ultrastructure changes in liver and kidney cells in vivo exposure .

## **MATERIALS AND METHODS**

### **1. Insectides used**

#### **1. Deltamethrin**

**Chemical name** :Cyano-(3-phenoxy phenyl)-methyl-3-(2,2-dibromo ethenyl)-2,2- dimethyl cyclopropane carboxylate

#### **2. Profenofos**

**Chemical name** :O- 4 – bromo -2- chlorophenyl-O- ethyl- S- propyl- Phosphorothioate.

### **1. Experimental animals and determination of the median lethal doses.**

Adults females albino rat with average weight of 70-80 gm were provided by the farm of experimental animals at Helwan. The animals were kept under laboratory condition for at least 15 days before initiation of the experiment , and were allowed free access to water and fed on adequate stable diet.

The two tested insecticides were orally administered to female rats using a stomach tube to detect their median lethal doses, sixteen females (120-140 gm body weight were used in this experiment. Doses of the two insecticides (deltamethrin and profenofos) were prepared in geometric progression starting by doses which kill of 20-100% of treated rats during the period 24 hours. The obtained data were statistically analyzed according to the method adopted by Finney (1952) .

### **2. Haematological study :**

The animals were allocated into five groups. The 1<sup>st</sup> was considered as control, while the other groups were treated by (1/10 and 1/20 of LD<sub>50</sub> from two insecticides (Rather tolerance dose) day after two days for nine months. Toxicants were administered by convenient stomach tube. After nine months of treatments (last doses) blood samples were collected in tubes contained heparin (7.5 I. U/ml according to Schalm 1980) for haematological investigation.

White blood cells (WBCs) , Red blood cells (RBCs) count, Haemoglobin (Hb) values and platelet counts were determined according to Schalm (1986) method.

### **3. Ultrastructural study (Specimens preparations for transmission Electron Microscope)**

In preparing of transmission electron microscope virtually every step of the procedure affects the quality of the final electron micrographs. Tissues preparation for transmission electron microscope can be divided into major steps. Most fixation protocols developed subsequently are modifications of the two steps. A primary fixative was developed that combined glutaraldehyde and low concentration of formaldehyde (up to 4%). A secondary fixative using an osmium tetroxide solution that is reduced with ferrocyanide, was introduced to enhance preservation of membrane and glycogen. After fixation

samples were washed by using the same buffer as that utilized in the fixation mixture and dehydrate in ascending grads of methanol (30% for 30min., 50% for 30min.and 70% for 30min.). The tissues were stored in 70% ethanol overnight, then 90% for 30-60 min. and 100% 2 changes of 3 min. each. Samples were carried out in cold, the dehydration was also completed at 0 to 4°C. Samples were put after dehydration in propylene oxide, pure for 30-60 min. Final embedding was most conveniently done in polyethylene capsules in troughs with performed molds. The capsules containing the embedding mixture and tissue blocks were polymerized in an oven for 2-3 days at 60 °C. when polymerized, the blocks were every hard and ready for sectioning.

Semithin sectioning (0.5µm thick section) are cut by ultramicrotome to select suitable areas for ultrathin sectioning for electron microscope. When an area for fine structural examination has been selected from the thick section, the block face must be retrimmed to a size suitable for ultramicrotome. Generally the thin of suitable sections of electron microscope is 800Å (1°A= 0.001 µm). After that, sections collecting from trough of ultramicrotome onto specimen grid made of copper. Grids of this type offer a sufficiently large mesh width (85 µm) to give an adequate field at low magnification as well as a relatively good heat dissipation. The grid with section was dried by placing it on a piece of filter paper that adsorbs the adhering fluid. The grids was placed in a dust free area and not released until completely dry. Thin sections were stained with solution of uranyl acetate to produce a general increase in contrast. The grids were examined by Electron Microscope.

## RESULTS AND DISCUSSION

### 1. Estimation of the LD<sub>50</sub> of deltamethrin and profenofos

The toxicity of deltamethrin and profenofos on the experimental animals was evaluated using orally administration . Different concentrations of each insecticide were prepared and orally tested against white albino rat females. The lethal doses were calculated according to the bases of mg a.i / Kg body weight. The LD<sub>50</sub> value, the confidence limits, and slope value for the two insecticides were calculated according to Finney method (1952). The median lethal doses of deltamethrin and profenofos were 34.05 and 569.81 mg/kg respectively against the white albino rat females (Table 1).

**Table (1): Median lethal doses of deltamethrin and profenofos on female white rats.**

<b>insecticides</b>	<b>deltamethrin</b>	<b>profenofos</b>
<b>Some measures</b>		
<b>LD<sub>95</sub> mg/kg</b>	190.9	652.52
<b>LD<sub>5</sub> mg/kg</b>	6.07	497.588
<b>LD<sub>50</sub> mg/kg</b>	34.05	569.81
<b>Slope</b>	2.197±2.996	27.9 ± 3.22
<b>Upper limit mg/kg F95</b>	2316.66	738.28
<b>lower limit mg/kg F95</b>	17.407	576.73
<b>Upper limit mg/kg F99</b>	145.6	592.19
<b>lower limit mg/kg F99</b>	0.2209	418.08

**2. Effect on some blood components:**

Data presented in Table (2) indicated increase in white blood cells (WBCs) count in deltamethrin and profenofos treated rat (+58.62 , +27.58, +46.22 and +43.86%) more than normal level after nine months of treatment with 1/10 and 1/20 for both insecticides, respectively. In the same tables, obtained data revealed that treatments caused reduction in red blood cells (RBC's) count (-28.88 , -36.55 , -37.44 and -11.11%) below the normal level.

Also the obtained data indicated that the hemoglobin values and platelets count had the same trend as previously mentioned in case of RBCs count after nine months of treatment. The reduction of Hb content as will as RBCs counts may be attributed to the toxic effect of the insecticides, and with the acute pesticides exposure and malignant tumors of the animals organs (Hoffman *et al.*, 1991). Mitema and Masha (1984) observed that the average value of Hb, RBCs and WBCs were increase in cattle poisoned with organophosphorus insecticides. Also, El-Maghraby (2004) reported that 1/5 and 1/10 LD<sub>50</sub> of malathion and its metabolite induced the activity of some blood content of treated mice, the maximum inhibition was observed after 10 days of treatmet. All treated mice returned to their normal statement often on weak recovery period.

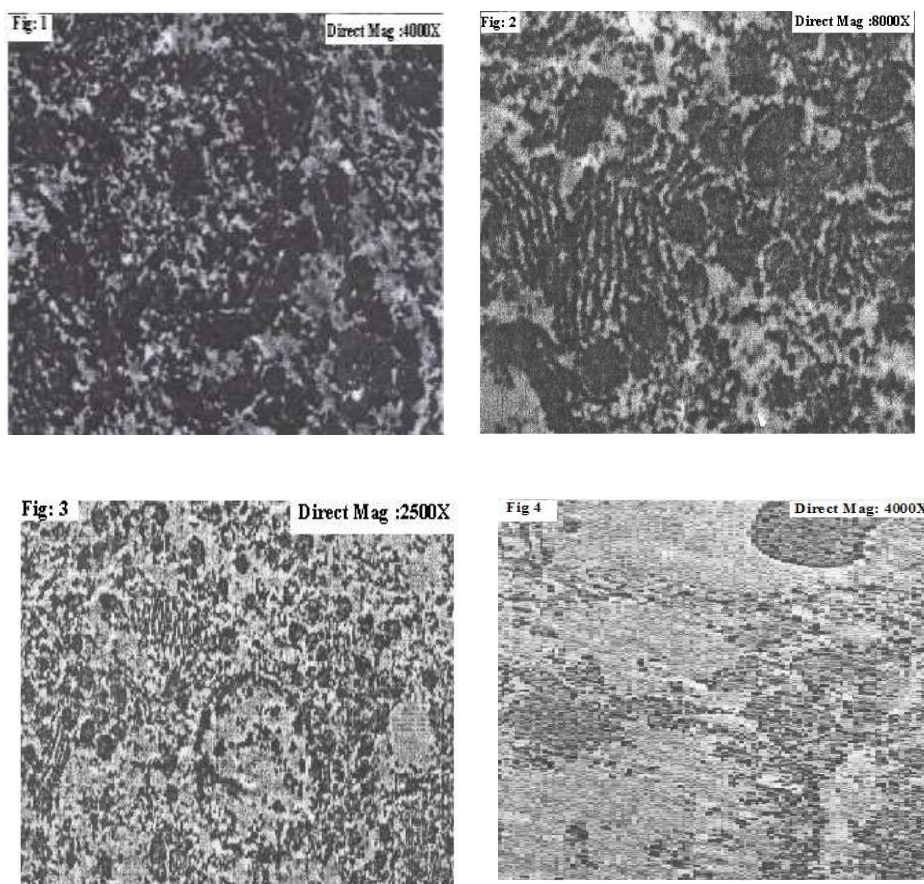
**Table (2): Effects of deltamethrin and profenofos on WbCs , RBCs counts, Hemoglobin values and platelets counts of female white rats.**

insecticides parameters	deltamethrin		profenofos		Control
	1/10 LD <sub>50</sub>	1/20 LD <sub>50</sub>	1/10 LD <sub>50</sub>	1/20 LD <sub>50</sub>	
W.b.C (10 <sup>3</sup> / ml)	9.2 (+58.62)	7.4 (+27.58)	8.5 (+46.55)	8.2 (+43.86)	5.8
R.B.C (10 <sup>6</sup> / ml)	3.2 (-28.88)	3.8 (-36.55)	3.4 (-37.44)	4.0 (-11.11)	4.5
Hemoglobin (g /dl)	8.2 (-33.87)	8.4 (-32.26)	9.2 (-25.80)	10.0 (-19.35)	12.4
Platelets (10 <sup>3</sup> / ml)	130 (-29.72)	160 (13.51)	140 (-24.32)	155 (-16.21)	185

Each figure between brackets represents the percentage of the content as check


**3. Ultrastructural changes**

Sharp variation were noticed between treated rats with 1/10 and 1/20 of LD<sub>50</sub> (both deltamethrin and profenofos) for liver, the results so far obtained indicate histo–and cytopathological alteration under the effect of two pesticides when compared with those of the control ones by light and electron microscope (Fig 1, 2, 3 and 4).



**Fig: 1, 2, 3 and 4 Control of Liver**


Histologically, marked reduction in the size of cells, vacuolation, pyknosis of nuclei and necrosis of the numerous cells were observed. Cytolopathologically (1/10 and 1/20 of LD<sub>50</sub> of deltamethrin and profenofos), Golgi bodies lost their normal distribution net-like structure and were fragment into faintly stained discrete particles which disappeared progressively from the cells with prolonged treatment. Mitochondria elements were swollen coalesced together forming few large massive bodies which became hardly visible in cytoplasm. Lysosomes lost their normal distribution and some of them were ruptures (Fig 5, 6, 7 and 8).




**Fig.5: Treated with 1/10 LD<sub>50</sub> of Deltamethrin**



**Fig.6: Treated with 1/20 LD<sub>50</sub> of Deltamethrin**



**Fig.7: Treated with 1/10 LD<sub>50</sub> of Profenofos**



**Fig.8: Treated with 1/20 LD<sub>50</sub> of Profenofos**

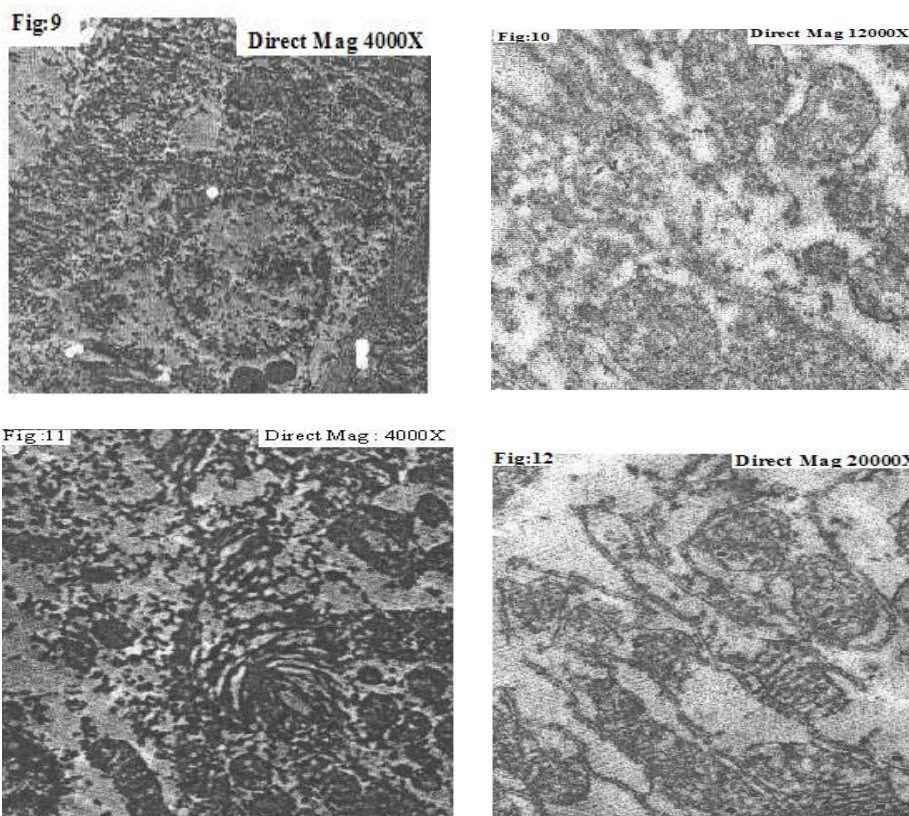
**Treated of Liver**

**Figs. 5 , 6, 7 and 8: No variation between two insecticides and two doses in effect on organelles of hepatocyte cells of treated rates, Golgi bodies lost their normal distribution. Mitochondria elements were swollen and coalescard together forming few large massive bodies which become hardly visible in cytoplasm. Lysosom lost their shape and some of it was ruptures. Section showing polymorphism of nuclei, irregular of chromatin and prominent nucleoli.**

On the other hand, some section of hepatocellular showing marked polymorphism of nuclei irregularity of the chromatin and prominent nucleoli in rats treated with two pesticides at two doses treated.

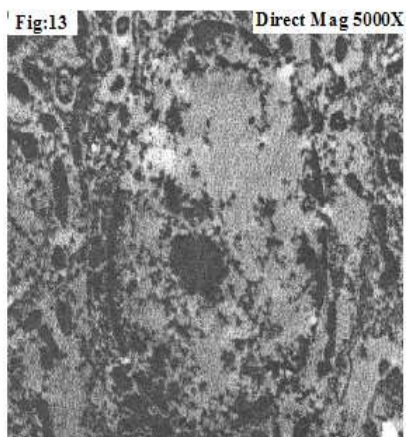
Kidney section of different treatments revealed many phases of degenerative changes in cells as compared with those of control (fig 9, 10, 11 and 12). Histologically, these changes appeared in form of cloud swelling, hydropic degeneration and detached cells. In the could swelling phase , the epithelial lining the affected tubes become swollen .



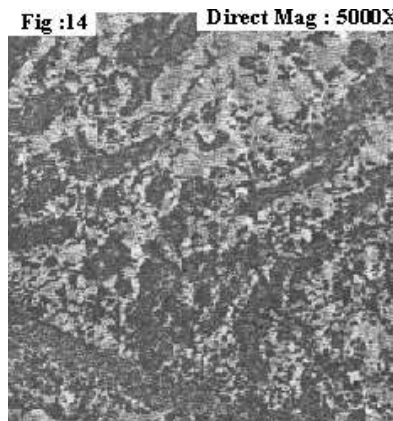


**Fig: 9, 10, 11 and 12 Control of Kidney**


Cytopathology showed that, the structure of Golgi bodies were demonstrated in renal cells. Doses application during nine months caused serious damage and fragmented these organelles in the form small particles most of which disappeared from the living cell of few remnant scattered in cytoplasm. The normal mitochondria of renal cells were markedly swollen under the effect of insecticides and in some cases, they coalesced together into large bodies. Lysosomes showed different pattern of localization in the various types of renal cells. Some cells were loaded with lysosomes and other were rather poor. Electron microscope showed differentiated cells containing a cytoplasmic indentation or inclusion filled with brush border materials. It also showed that cytoplasm was filled with prominent granules, endoplasmic reticulum containing some dense floccular material. Also, electron micrography appeared differentiated nuclei and changes in their content such as nucleolus or chromosomes (chromatid and centromere) (Fig 13, 14, 15 and 16) .




**Fig.13: Treated with 1/10 LD<sub>50</sub> of Deltamethrin**



**Fig.14: Treated with 1/20 LD<sub>50</sub> of Deltamethrin**



**Fig.15: Treated with 1/10 LD<sub>50</sub> of Profenofos**



**Fig.16: Treated with 1/20 LD<sub>50</sub> of Profenofos**

#### **Treated of Kidney**

(Fig 13, 14 15 and 16) Kidney section of treated animals revealed different phases of degenerative changes when compared with those of control.

Cytologically showing that, Golgi bodies are demonstrated in renal cells. Insecticides application seriously damage and fragmented these bodies into small particles. Mitochondria of renal cell were markedly swollen under the effect of chronic effects with deltamethrin and Profenofos. Lysosom particles show different pattern of localization in the various types of renal cells. Renal cells showing polymorphic of nuclei, irregular of chromatin.

These change might due to epithelial necrosis in the renal tubules that were associated with nuclear and chromatin changes (Janssen 1984) our results are in agreement with those obtained by Farrage and Shalby (2007). who reported that treated rats by Lufururon and Profenofos cause venous congestion in the liver and focal necrosis of hepatocytes in the portal and



periportal area. Many of hepatocytes were pale-stained and a few exhibited early vacuolation. Also, several cells showed histological features of necrosis, and the kidney exhibited inflammatory cell infiltration, congestion and hypercellularity of the glomeruli. The results are in agreement with those found by Saleh (1997), who reported that chlorpyrifos caused considerable effect on RBCs, WBCs counts and Hb.

Concerning the ultrastructural changes of the used deltamethrin and profenofos either in liver or in kidney cells in treated rat by low doses during nine months (as chronic effect), it was found an undesirable changes in the ultrastructural of cell tissues. These unwelcome changes may be due to the metabolic fates of the tested insecticides and the interference of their metabolites with the vital components of the cells. Till now, these metabolites still unknown for us, so that these point of research need more investigations.

## REFERENCES

- Davies, J. E. ; Barquet, A. and Vaclavek, C. (1975). Human pesticides poisoning by fat soluble organophosphate insecticides. Arch. Environ. Health, 30:609-613.
- El-Maghraby, S. (2004). Comparative toxicity of malathion and its metabolites (O,O dimethyl phosphorodithio propionic acid ethyl ester) towards mice. Bull. NRC. Egypt. Vol, 29 (6): 669-680.
- Farrag, A. H. and Sh. E. M. Shalaby (2007). Comparative histopathological and histochemical studies of IGR, lufenuron and Profenofos insecticides on albino rat J. Appl. Sci. Res. 3 (5): 277-388.
- Finney, D. J. (1952) probit analysis. A statistical treatment of the sigmoid response curve. Cambridge Uni. Press. London.
- Hoffman, D. J.; W. J. Spann, L. J. Lecaptain, C. M. Bunch and B. A. Rathner (1991). Developmental toxicity diphenyl ether herbicides in nesting. American Kastrds. J. Toxi. And Environ. Health, 26 (2) :201.
- Janssen. W. (1984). Forensic histopathology. Spring- Veriag, Berlin, NY, pp. 314-315.
- Karemar, S. (1984). Acute and long lasting central actions of organophosphorus agents. Fund . Appl. Pharmacol., 4: 511-512.
- Mitema E. S. and J. B. Masha (1984). Organophosphate poisoning in cattle :A report of clinical cases. Vet Med ., 79: 111-114.
- Saleh, Amal . Y. (1997). Toxicological influence of technical and formulated chlorpyrifos on blood fractions, respiratory cytochrome-c-system and growth rate of male albino rats (*Rattus norvegicus*). J. Agric. Sci. Mansoura Univ., 22(7) : 2483-249.
- Schalm, O. W. (1986). Veterinary Hematology 4<sup>th</sup> Ed., Lea and Fibiger Philadelphia, pp 21-86.

**استخدام الخلية وعضياتها كأدوات لدراسة سمية الدلتا ميثرين والبروفينوفوس**  
سلوي السعيد نجم , محمد محمد قاضي , عادل عبد المنعم صالح وعلي علي الألفي  
قسم المبيدات كلية الزراعة جامعة المنصورة

هناك العديد من مستحضرات المبيدات تتبع مجموعات مختلفة من المبيدات ومن هذه المستحضرات مبيد الدلتا ميثرين ومبيد بروفينوفوس وكلاهما قد يستخدم علي الخضار والفاكهة . يهدف هذا البحث الي دراسة الأثر السام بتركيزات امه الي حد كبير حيث تم تحديد 10/1 , 20/1 من الجرعة النصفية القاتلة وتم المعاملة بهذه الجرعات مرة كل ثلاثة أيام لمدة وصلت الي 9 أشهر لمعرفة التأثير المزمن علي كلا من مكونات الدم مثل كرات الدم البيضاء والحمراء الهيموجلوبين وكذلك الصفائح الدموية لتكون علامة واضحة علي التأثير المزمن . تم ايضا أخذ عينات من النسيج الكبدي والنسيج الكلوي للفئران المعاملة في نهاية المدة لمعرفة مدي التغير الدقيق لهذه الأنسجة باستخدام الميكروسكوب الإلكتروني .

**وكانت النتائج المتحصل عليها كالآتي:**

1. حدوث زيادة واضحة في عدد كرات الدم البيضاء في الفئران المعاملة بجميع التركيزات لكلا المبيدين.
2. كلا من الدلتا ميثرين والبروفينوفوس بالجرعات المعاملة 10/1 , 20/1 من LD<sub>50</sub> (الجرعة النصفية) أدت الي اختزال واضح في كرات الدم الحمراء كذلك نسبة الهيموجلوبين والصفائح الدموية
3. أظهر الفحص بالميكروسكوب الإلكتروني حدوث تغيرات واضحة في كلا من عضيات خلايا الكبد والكلبي بالجرعات المعاملة
4. في خلايا الكبد للفئران المعاملة حدث تغير في السيتوبلازم كذلك النواه – تغيرات في أجسام جولجي والريبوسومات والشبكة الاندوبلازمية – أيضا تغيرات في الميتوكوندريا عدم انتظام في كروماتيدات الأنوية.
5. كذلك اظهرت خلايا الكلبي ان المعاملات أدت الي حدوث تحطم في أجسام جولجي والميتوكوندريا والشبكة الاندوبلازمية وتغيرات في شكل الليسوسومات وبعض المعاملات ظهر فيها خيوط كثيفة بالإضافة الي تغيير في الكروماتيدات.

عموما هذه المبيدات أظهرت تغييرات واضحة عند المعاملة المزمنة وقد يرجع ذلك الي تأثيرها علي عمليات الميتابوليزم وتدخلها في عمل وافراز كثير من الانزيمات وهذا يحتاج الي مزيد من البحث.

قام بتحكيم البحث

كلية الزراعة – جامعة المنصورة  
مركز البحوث الزراعية

أ.د / علي علي عبد الهادي  
أ.د / أحمد السيد عبد المجيد