

Bilateral Foraminal Stenosis in Patient with Dandy-Walker Malformation: Hiding Pathology

Hieder Al-Shami¹, Farah Sameer Othman², Ahmed Hegazy³, Mohammed Fathy Adel Ali³

1 Department of Neurosurgery, Al-Ahly Bank Hospital, Cairo, Egypt,

2 Department of Pediatric, Faculty of Medicine, Mousl University, Mousl, Iraq, 3 Department of

Neurosurgery, Faculty of Medicine, Cairo University, Cairo, Egypt

Corresponding Author: Hieder Al-Shami, email: Adamhouse73@gmail.com

ABSTRACT

Background: Etiologies of hydrocephalus are many and sometimes it can be attributed to be multifactorial in origin. Presence of known cause of hydrocephalus like fourth ventricular pathology may mask foraminal stenosis. Diagnosis of unilateral and bilateral stenosis of foramen of Monro should be included in the treatment plan in hydrocephalus

A case report of a 9 months-old boy presented with delayed milestones of development and an increase in head circumference. The patient has been diagnosed as hydrocephalus and associated Dandy-Walker malformation. Ventriculoperitoneal shunt was inserted successfully but drained only one lateral ventricle. The association of isolated lateral ventricle with Dandy-Walker malformation is due to stenosis of foramen of Monro. Our case report is unique due to association between foramen occlusion and Dandy-Walker malformation.

Keywords: foramen of Monro, Dandy-Walker malformation, VP shunt.

INTRODUCTION

Etiologies of hydrocephalus are many and sometimes it can be attributed to be multifactorial in origin ⁽¹⁾. Presence of known cause of hydrocephalus like fourth ventricular pathology may mask foraminal stenosis ⁽²⁾. Diagnosis of unilateral and bilateral stenosis of foramen of Monro should be included in the treatment plan in hydrocephalus to prevent shunt malfunctioning ⁽³⁾. Our case reported bilateral stenosis of foramen of Monro associated with Dandy-Walker malformation.

CASE REPORT

A 9-month male patient complaining of failing or delayed milestones development and an increase in skull circumference (HC=42 cm) presented to our clinic. He was diagnosed as obstructive hydrocephalus.

He was prepared for ventriculo-peritoneal shunt. No specific operative findings other than high pressure of cerebrospinal fluid (CSF) were found. The post-operative period was unremarkable with relaxation of the anterior fontanelle after 24 hours.

Follow up CT brain (see Figure 1) showed that the lateral ventricle of the same side was drained completely while the contra-lateral ventricle was

enlarged and showing no drainage as well as a cyst in the posterior fossa. The diagnosis was bilateral foraminal stenosis at the level of the foramen of Monro associated with Dandy-Walker malformation.

Patient was prepared for endoscopic dilatation of foramen of Monro and fenestration of the septum pellucidum.

Operation. The patient was under general anaesthesia in supine position with head fixation by Mayfield head holder. A burr hole was made in the left Kocher's point as the left lateral ventricle was slightly wider than right one and directed to contralateral frontal horn for later on septostomy. The left foramen was occluded by thin membrane.

The right foramen of Monro was stenosed with no evidence of neoplastic activity and normal choroid plexus. The left foramen was dilated by a Fogarty catheter and balloon to dilate the opening. By using bipolar and monopolar, large fenestration of septum pellucidum (septostomy) was made. After completing of foramenoplasty, visualization of third ventricle was made. An additional third ventriculostomy was not made due to small sized room.

Postoperative care. The patient was monitored in ICU and discharged on Day 2 with no complications.

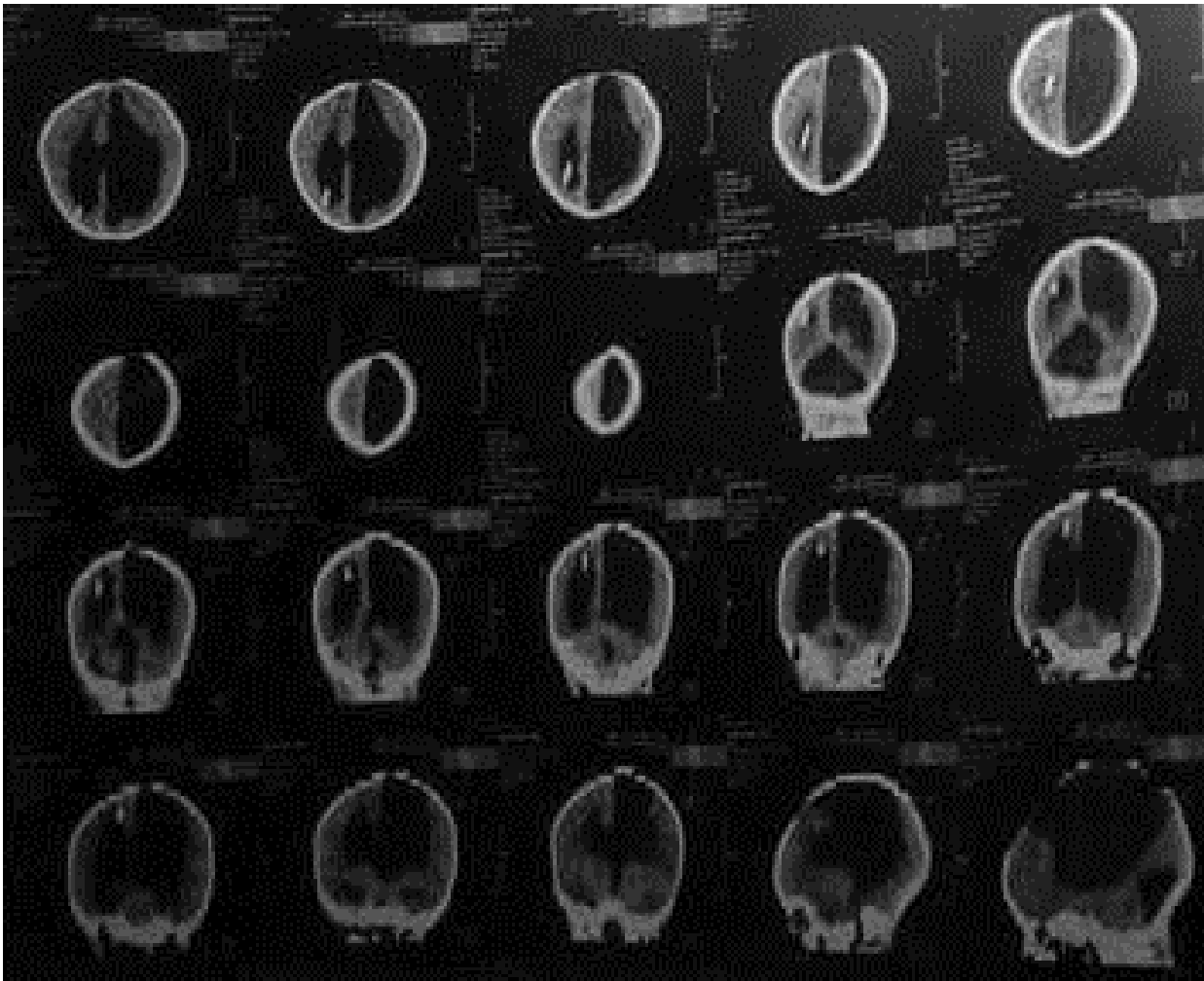


Figure (1): Axial, coronal and sagittal non contrast CT scan after 3 months follow up showed incomplete evacuation of left ventricle.

DISCUSSION

Although Dandy-Walker malformation is a common cause of obstructive hydrocephalus in children, the presence of an associated obstruction at the level of the foramen of Monro is very rare and has never been previously reported or reported very rarely in the literature ⁽⁴⁾.

Our case report is unique as it for the first time bilateral foraminal stenosis accompanying Dandy-Walker malformation.

Idiopathic foramen of Monro obstruction may be caused by either stenosis or membranous obstruction ^(5,6).

In case of absent previous interventions, congenital cause of stenosis is highly probable. Stenosis can be classified either as primary or secondary to an occlusive process like colloid cyst ^(3,7). In our case report, the foraminal stenosis is found to be bilateral in association with Dandy-

Walker malformation which is not frequently reported in previous literatures. In our case, failed CSF diversion was due to incomplete evacuation of contralateral ventricle with encystation of left lateral ventricle with compression on cerebral cortex and effacement of sulci and gyri. Inadequate drainage of ventricles resulted in herniation of brain tissues toward decompressed lateral ventricle ⁽⁸⁾.

Our case needed urgent neuroendoscopy through left frontal burr-hole to navigate left lateral ventricle, opening of the foramen of Monro, septostomy and opening contralateral foramen.

Neoplastic, infectious and developmental anomalies were diagnosed as causes of foraminal stenosis ^(6,9).

In our case, there was no past history of ventriculitis or encephalitis or any other cause rather than Dandy-Walker malformation on MRI

^(3,7). Endoscopic techniques were procedures of choice in treating hydrocephalus ⁽⁶⁾. Dilatation of foramen and septostomy were regarded as enough steps in idiopathic unilateral stenosis ⁽¹⁰⁾.

Presence of thin vascular membrane obscuring the foramen is not contraindication to foraminoplasty ⁽⁸⁾. Few drops of blood are usually seen in such scenarios. The most important structure during this step is injury to the fornix ⁽⁵⁾. In these cases, shunt insertion or septostomy by performing a septostomy and bilateral dilatation of foramina. Thus, CSF restores its circulation ⁽⁵⁾. Third ventriculostomy was not possible in our case as third ventricle was small. Postoperatively, the patient's fundus examination returned to normal ⁽¹¹⁾.

REFERENCES

1. **Dastgir G, Awad A, Salam A, Attia M (2006):** Unilateral Hydrocephalus Due to Foramen of Monro Stenosis. *min - Minim Invasive Neurosurg*, 49(3):184–6.
2. **Nigri F, Gobbi GN, da Costa Ferreira Pinto PH, Simões EL, Caparelli-Daquer EM (2016):** Hydrocephalus caused by unilateral foramen of Monro obstruction: A review on terminology. *Surg Neurol Int.*, 7(12):S307-13.
3. **Mizrahi CJ, Cohen JE, Gomori JM, Shoshan Y, Spektor S, Moscovici S (2016):** Idiopathic bilateral occlusion of the foramen of Monro: An unusual entity with varied clinical presentations. *J Clin Neurosci.*, 34:140–4.
4. **Zhang X, Gu Y, Sun X, Wang Y, Wang A (2013):** Dandy-Walker complex: a clinicopathologic study of 9 cases. *Chinese J Pathol.*, 42(12):815–8.
5. **Kalhorn SP, Strom RG, Harter DH (2011):** Idiopathic bilateral stenosis of the foramina of Monro treated using endoscopic foraminoplasty and septostomy. *Neurosurg Focus*, 30(4):E5.
6. **Vaz-Guimarães FA, Ramalho CO, Suriano ÍC, Zymberg ST, Cavalheiro S (2011):** Neuroendoscopic surgery for unilateral hydrocephalus due to inflammatory obstruction of the Monro foramen. *Arq Neuropsiquiatr.*, 69:227–31.
7. **Glastonbury CM, Osborn AG, Salzman KL (2011):** Masses and malformations of the third ventricle: normal anatomic relationships and differential diagnoses. *Radiographics*, 31(7):1889–905.
8. **Nigri F, Gobbi G, da Costa Ferreira Pinto P, Simões E, Caparelli-Daquer E (2016):** Hydrocephalus caused by unilateral foramen of Monro obstruction: A review on terminology. *Surg Neurol Int.*, 7(13):307.
9. **Tubbs RS, Oakes P, Maran IS, Salib C, Loukas M (2014):** The foramen of Monro: a review of its anatomy, history, pathology, and surgery. *Childs Nerv Syst.*, 30(10):1645–9.
10. **Schulman H, Landau D, Schulman P, Hertzanu Y (2000):** Congenital unilateral hydrocephalus — CT findings. *Eur J Radiol.*, 36(3):161–4.
11. **Tobias-Gonzalez P, Gil Mira M, Valero de Bernabe J, Zapardiel I (2012):** Differential diagnosis of Dandy-Walker syndrome different presentations. *Ginecol Obstet Mex.*, 80(8):534–9.