

Low Profile Ilizarov Frame in Correction of Varus Deformity in Patients with Adolescent Blount's Disease

Mustafa F. Abd Alkader, Mootaz F. Thakeb, Ahmad S. Aly

Department of Orthopedic, Faculty of Medicine, Ain Shams University, Cairo, Egypt
Corresponding author: Mustafa F. Abd Alkader . phone :01020033418 email: mustafafarook@yaoo.com

ABSTRACT

Background: Adolescent Blount disease or late onset tibia vara constitutes the most common cause of pathologic genu varum in late childhood and adolescence. It is a developmental condition characterized by disordered endochondral ossification of the posteromedial part of the proximal tibial physis resulting in multiplanar deformities of the lower limb.

Objective: the aim of This work was to evaluate the results of treatment of acute correction of varus deformity in patients with Blount disease by using low profile Ilizarov frame.

Patients and Methods: It is a retrospective and a prospective study for 10 patients who had adolescent Blount disease treated by acute correction using low profile Ilizarov frame. We looked principally into the following variables to evaluate the results of the treatment: Deformity correction (expressed as mechanical axis restoration), the average normal values were used as a reference (medial proximal tibial angle, 85–90; posterior proximal tibial angle, 77–84; thigh–foot angle, +10 external rotation)

Results: the patients were 9 boys (90%) and one girl (10%). The mean age at presentation was 13.60 years, range (11- 17 years) , 6 patients (60%) presented with unilateral affections and 4 patients (40%) presented with bilateral affection. Mean preoperative to postoperative changes of MPTA from 74.57 (range 65-80) improved to 89.21 (range 86-95), Mean preoperative to postoperative changes of PPTA from 74.21 (range 66-80) improved to 79.07 (range 77-82) , Mean preoperative to postoperative changes of MAD from 31.14 mm (range 18-45 mm) improved to 3.64 mm (range 0-8 mm). Mean preoperative to postoperative changes of TFA from -23.57 (range -30 – -15) of internal tibial torsion improved to 5.36 (range 0-10) of external tibial torsion

Conclusion: Management of adolescent Blount disease by acute correction strategy using a low profile Ilizarov is a safe technique offering excellent results with low incidence of complications.

,Low profile Ilizarov is lighter and less bulky so more comfortable for patients than classic Ilizarov external fixation , Acute correction technique can achieve the same result of correction as gradual correction technique in patient with no limb length discrepancy , Acute correction offers a shorter time in frame as compared to gradual correction with fewer follow-up visits and exposure to radiation.

Keywords: Blount disease, Low profile Ilizarov , acute correction.

INTRODUCTION

Adolescent Blount disease or late onset tibia vara constitutes the most common cause of pathologic genu varum in late childhood and adolescence. It is a developmental condition characterized by disordered endochondral ossification of the posteromedial part of the proximal tibial physis resulting in multiplanar deformities of the lower limb⁽¹⁾.

In 1922, **Erlacher**⁽²⁾ is credited with the first description of progressive tibial varus deformity in otherwise healthy children.

In 1937, **Blount**⁽³⁾ reviewed previous reports adding his own cases. He was the first to identify two forms of this disorder; infantile and adolescent (late onset) and coined the term “osteochondrosis deformans tibiae”. However, the

condition also referred to as “tibia vara” in the literature, is often referred to as Blount disease.

Langenskiold⁽⁴⁾ made significant early contributions to the identification and management of infantile Blount disease in 1964. He described a prognostic radiographic classification system.

Although Blount coined the term tibia vara implying a solely frontal plane deformity, subsequent authors noted that multiplanar deformities are commonly seen with this condition. Secondary to the asymmetrical growth with relative inhibition of the posteromedial portion of the proximal tibial growth plate, a three dimensional deformity of the tibia with varus, procurvatum (apex anterior), and internal rotation develops, along with possible limb shortening in unilateral cases^(5,6).

This entity can lead to a progressive deformity with gait deviations, limb length discrepancy, and premature arthritis of the knee^(7,8).

Two clinically distinct forms of Blount disease; early onset (infantile) and late onset have been described, with the classifications based on whether the limb deformity develops before or after the age of four years^(3,4,9).

Thompson and Carter⁽⁹⁾ further classified late onset Blount disease as a juvenile type (onset at the age of four to ten years) and an adolescent type (onset after the age of ten years).

Bilateral involvement is common, particularly with an early onset presentation⁽⁶⁾. Although there are clinical and radiographic differences between early and late onset Blount disease, there are several similarities, including a predisposition for obese black children. Also, there are comparable histologic findings at the proximal tibial growth plate^(9,10).

The prevalence of adolescent Blount disease may be as high as 2.5% in the population at greatest risk, obese black males^(11,12). Incidence may further more be escalating because of the increasing prevalence of morbid obesity in western society⁽¹³⁾. Male: female ratio of 4:1 and over 90% of patients obese and black^(14,15).

It is postulated that the medial femoral physis also suffers growth inhibition due to the high loads through the medial knee joint particularly in older obese patients with a fat thigh gait⁽¹⁶⁾.

Several treatment modalities were described for these cases as proximal tibial osteotomy, growth modulation, and medial plateau elevation that are either carried out as an isolated procedure or in combination with other osteotomies^(17,18).

Proximal tibial osteotomy is still the standard surgical management for late onset cases where the researchers observed that the proximal tibial physis typically grow symmetrically following this osteotomy^(19,20,24). Methods of fixation of the osteotomy have changed, from plaster alone to include limited internal fixation with Steinmann pins, stable internal fixation with compression plates or external fixation.

Due to the difficulties associated with obesity in late onset Blount disease, external fixators have become a popular fixation method, including monolateral and circular fixators. The deformity correction using external fixation can be done either acutely or gradually^(21, 22 ,23). While the gradual

correction strategy using distraction osteogenesis has its crucial indication in certain situations like addressing severe deformity or a coincident significant anatomical limb length discrepancy, as it requires a high degree of patient compliance and still has its recorded complications^(25,26). Conversely, acute correction strategy has its merits as being more compliant to the patient and requires less regular follow up visits, but it needs proper case selection to get a successful outcome⁽²⁷⁾.

This works was aimed to evaluate the results of treatment of acute correction of varus deformity in patients with Blount disease by using low profile Ilizarov frame.

PATIENTS AND METHODS

After approval of the Ethics Committee written informed consents from all the subjects were obtained ,and a total of 10 patients who had adolescent Blount disease treated by acute correction using low profile Ilizarov frame were retrospectively and a prospectively evaluated between (January 2016-December 2017) this study was done in Department of Orthopedic ,Ain Shamas University Hospital .

Inclusion criteria

- Patients with adolescent Blount disease (≥ 10 years age).
- Medial proximal tibial angle > 64
- Normal lateral distal femoral angle

Exclusion criteria

- Significant limb length discrepancy.
- Patients who have previous operation for tibia vara

Preoperative planning

Preoperative evaluation included clinical examination of the patient and the affected limb to exclude the presence of skeletal dysplasia, short stature and leg length discrepancy. The limb was examined for neurovascular status and skin condition.

Radiographic examination included long standing plain radiographic films for mechanical axis study and limb length evaluation. Short films for the tibia and femur on both sides were obtained for deformity analysis and preoperative planning according to the method described by **Paley and Tetsworth**⁽²⁸⁾. Assessment of the limb length inequality by the CT scanogram.

Operative Technique

The operation was performed under spinal anesthesia for patients older than 15 years and general anesthesia for younger adolescent. One hour

preoperative intravenous antibiotic is used. The patient is operated in a supine position in a radiolucent table without tourniquet application. The leg is draped free including the iliac crest, so as to be able to check alignment intraoperatively, even under image intensification. The affected limb was sterilized from upper thigh to toes. Intraoperative fluoroscopy is checked prior to start to ensure adequate views can be obtained.

Fibular osteotomy:

Lateral incision about 2 cm was done at the level of mid leg and incise skin and superficial fascia and deep fascia and identify the plane between the peroneal muscle and the superficial posterior muscle, incise the periosteum, the soft tissue was protected with drill sleeve.

Make multiple drill holes and with thin osteotome and hammer make the osteotomy and translate proximal part of the fibula medially and distal part laterally. The fascia is left open and the skin closed with simple sutures (figure 1).

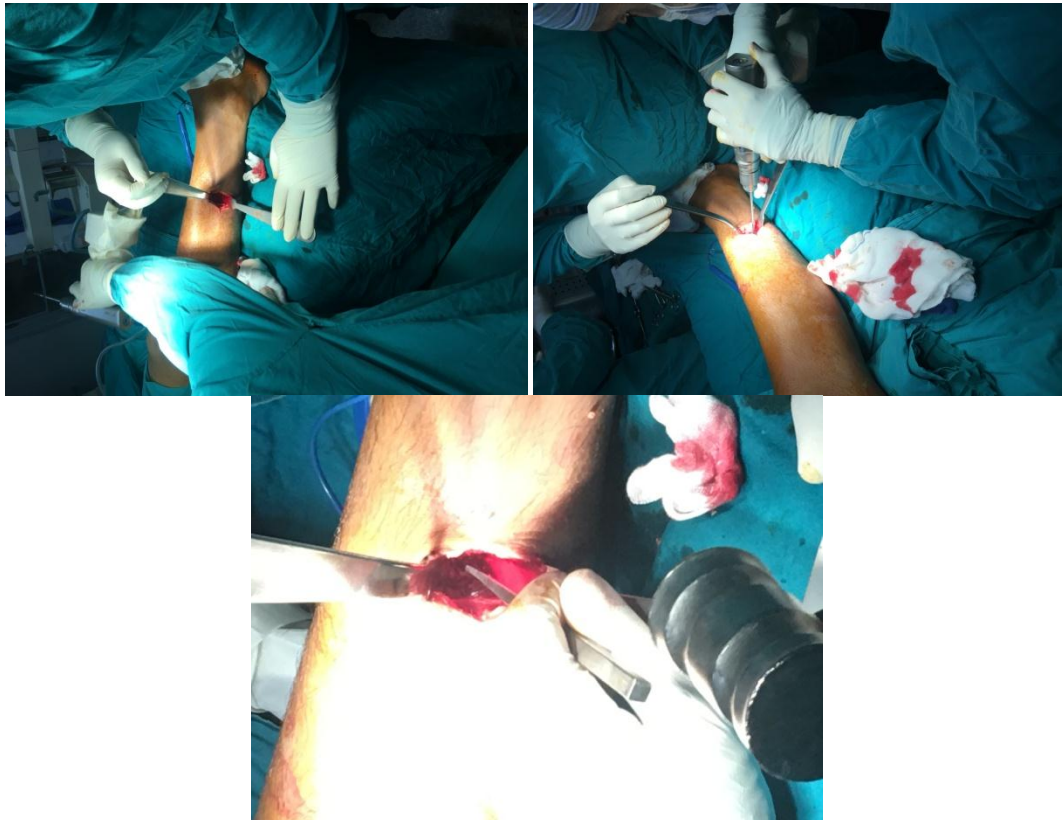

Figure 1; fibular osteotomy, (A) Side of incision for fibular osteotomy,(B) multiple drilling guide ,(C) Small osteotomy for complete fibular osteotomy.

External fixator frame:

The preassembled frame consisted of two full rings. The proximal ring was placed parallel to tibial articular surface in all planes. Distal ring away from proximal ring by about 15cm and connected to it by a hinge which were placed perpendicular to the tibial axis at the level of the CORA.

A reference wire was inserted parallel to the knee joint orientation line under image intensifier control below physal plate from lateral to medial. The hinges were placed at the correct level and location (lateral surface) and checked by image intensifier. The proximal ring closest to the knee (first ring) was attached to the reference wire. A half-pin is placed anterolateral at Gerdy's tubercle. A second half-pin is placed anteromedial perpendicular to the first half-pin for best fixation both fixed for first ring. The distal ring (second ring) fixed to distal bone segment by two wire and two half-pins. The first half-pin was inserted perpendicular to the anatomical axis of the distal bone segment and fixed to the second ring via Rancho cube. At this stage, the overall alignment of the device and hinge placement was checked. The second half-pin was then inserted, in divergent manner via another Rancho cube fixed to the ring. The hinges were temporarily loosened for bone osteotomy (figure 2).

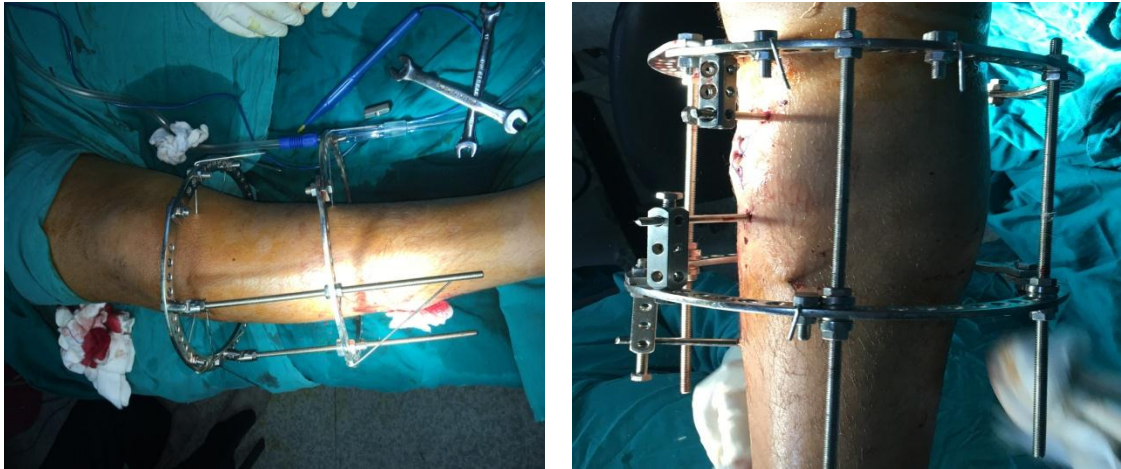


Figure 2; shape for external fixator frame side of hinge & after remove of hinge and put rods.

Tibial osteotomy:

Tibial osteotomy was done just distal to tibial tuberosity to avoid injury to physis of the proximal tibia and the tibial tuberosity to avoid recurvatum.

The surgical approach:

Anteromedial Vertical incision below tibial tuberosity. Incise skin and subcutaneous tissue , incise the periosteum longitudinal and make multiple drill holes just below the tuberosity from medial to lateral to facilitate the osteotomy and with small osteotome and hammer complete the osteotomy.

Four straight, threaded rods were then attached obliquely to staggered holes on the rings to rotate the distal segment externally to correct the torsional deformity. Derotation was done until the second toe of the plantigrade foot alligned with the patella. And lastly extension if procurvatum was present. The hinges were removed and the rods were used for axial compression of the osteotomy

The sequence of deformity correction proceeded as follows: translation, derotation, angulation and lastly compression of the osteotomy. The mechanical axis of the limb was checked using the electrocautary wire stretched between the hip

and ankle joint. Under image intensifier its proximal end was seen at the center of the hip joint and its distal end was at the center of the ankle joint; correction was accepted when it crossed the center of the knee joint.

The wound was closed with simple sutures, leg was washed with saline and pin sites were dressed with gauze and sterile dressings.

Post operative management:

The patients were discharged from the hospital mostly on the second postoperative day after confirmation of good peripheral circulation and follow up in outpatient clinic.

Patients were encouraged to do active exercises once the postoperative pain was relieved. Weight bearing as tolerated was allowed using crutches .

They were reviewed at the clinic; 2, 4, 8 and 12 weeks postoperative. Patients are allowed to wash the operative site and bathe as soon as the wounds heal. Patients were advised to perform three time daily pin care, by washing and brushing the pin sites using saline solution and a soft brush.

Fixator removal: Frame was removed under sedation after complete union clinical and radiological , and above knee cast was applied for 2 weeks (figure 3).

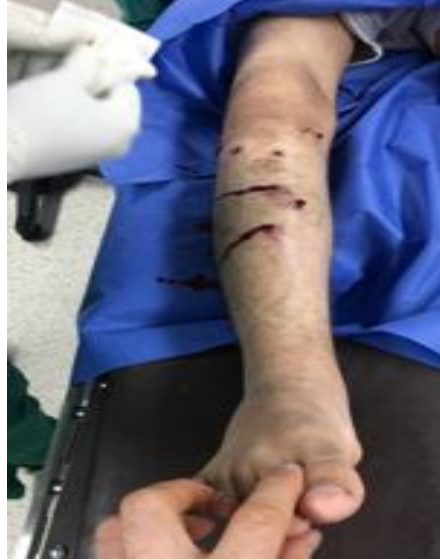

Figure 3; Fixator Removal

The patients were reassessed clinically and by radiographs at 1, 3, 6 and 12 months

Method of evaluation of the results

This included both clinical and radiological (objective and subjective) evaluation.

We looked principally into the following variables to evaluate the results of our treatment:

(A) Deformity correction (expressed as mechanical axis restoration), the average normal values were used as a reference (medial proximal tibial angle, 85–90; posterior proximal tibial angle, 77–84; thigh-foot angle, +10 external rotation)⁽²⁹⁾.

(B) External fixation time (EFT).

(C) Time to bone healing.

(D) Ability to bear weight postoperatively (stability of the osteotomy and fixation).

(E) Gait and knee range of motion (ROM).

RESULTS

A. Age and Gender: There are 9 boys (90%) and one girl (10%). The mean age \pm SD at presentation was 13.60 ± 1.90 years (11- 17 years) .

B. Side affection: 6 patients (60%) presented with unilateral affections and 4 patients (40%) presented with bilateral affection.

C. Medial proximal tibial angle (MPTA): Mean preoperative to postoperative changes of MPTA from 74.57 (range 65-80) with SD \pm 3.92 improved to 89.21 (range 86-95) with SD \pm 2.61.

D. Posterior proximal tibial angle (PPTA): Mean preoperative to postoperative changes of PPTA from

74.21 (range 66-80) with SD \pm 4.15 improved to 79.07 (range 77-82) with SD \pm 1.69.

E. Mechanical axis deviation (MAD) : Mean preoperative to postoperative changes of MAD from 31.14 mm (range 18-45 mm) with SD \pm 7.61 improved to 3.64 mm (range 0-8 mm) with SD \pm 2.13.

F. Thigh foot angle (TFA) : Mean preoperative to postoperative changes of TFA from -23.57 (range -30 – -15) of internal tibial torsion with SD \pm 4.97 improved to 5.36 (range 0-10) of external tibial torsion with SD \pm 3.08

G. External fixation time (EFT) : The mean time in frame was 12.0 weeks with a range from 8 to 14 weeks.

H. Maintenance of correction after fixator removal: All osteotomies healed with no re-fracture or loss of correction after fixator removal.

I. Time to bone healing: All cases come one month after fixator removal during follow up with complete consolidation of bone with no pain at osteotomy site.

J. Ability to bear weight postoperatively: (stability of the osteotomy and fixation) All patients advised to bear weight early postoperative as tolerated. Within two weeks.

K. Gait and knee range of motion: All patients reported improvement in their gait pattern postoperative. All patients retained their range of motion for the knee within the preoperative range.

All patients were able to achieve full knee flexion and extension during follow-up.

L. Total treatment time (TTT): All cases come in 2nd visit after two months of fixator removal with complete range of motion of knee and ankle joints and absence of pain at osteotomy site.

M. Patient's satisfaction and tolerance to the procedure: All patients tolerated the procedure well with full range of knee and ankle motion and most of them satisfied from the procedure except one patient always complaining from cosmetic appearance of pin sites scars.

N.Complications : Most cases had pin tract infections graded as grade 1, 2: and one case had grade 3 pin tract infection according to **Dahl classification (1994)**⁽³⁵⁾. Grade 1 inflamed requiring daily pin care only, Grade 2 serous discharge requiring oral antibiotics, Grade 3 purulent discharge requiring parental antibiotics, Grade 4 osteolysis requiring pin removal, and Grade 5 ring sequestrum requiring debridement .

- Most of the pin tract infections were related to the wire and proximal pins in the metaphyseal side, on lateral side more than medial side and was treated with oral antibiotics and local pin site care. No cases

of deep infection were encountered in this study. There was no need to exchange any of the pins or wires in the frames applied.

- Neurologic complications occurred in one case which presented with numbness and paresthesia on the lateral side of the leg mostly due to high level of fibular osteotomy which done in this case only and recovered completely after six weeks.

- One case complained from cosmetic appearance of pin site scars. We did subcutaneous elevation of depressed scars surgically under sedation and these depressed scars was improved

- No vascular injuries or compartment syndromes occurred in this study. septic arthritis of the knee, delayed union, non union or joint stiffness were not reported .

- Few patients reported occasional insomnia, more noticed in the few days postoperative.

- No other neurological or vascular complications occurred intraoperatively or during follow-up.

- All patients completed the follow-up that ranged from 12 to 18 months.

Table 1 ; our study compared with other studys

Study	Operation	MPTA	PPTA	TFA	MAD	TIME
Our study	pre	74.57°	74.21 °	-23.57°	31.14mm	12 week
	post	89.21°	79.07 °	+5.36°	3.64mm	
Feldman ⁽³¹⁾	pre	72.5°	71.8 °	-17.5°	53.9mm	12.9 week
	post	83.6°	80.9 °	+10°	1.4 mm	week
Eidlman ⁽³³⁾	pre	71.4°	74.66 °	- 10°	55.8 mm	12.8 week
	post	87.1°	78.8 °	+10°	4.9 mm	week

MPTA;medial proximal tibial angel , PPTA;posterior proximal tibial angel , TFA;thigh-foot angel , MAD;mechanical axis deviation .

DISCUSSION

The mean of preoperative MPTA in this study was 74.57 ° range (65 -80°) with SD± 3.92 improved to 89.21° range (86-95°) with SD± 2.61. The findings observed in this study near those of the previous studies , in **Eidelman et al.**⁽³³⁾ study mean preoperative MPTA was 71.4 range (67-77°) and was corrected to a mean of 87.1° range (85-89°). The MPTA increased 17 degree postoperative with mean 88° in **Gordon et al.**⁽³²⁾ study . In **Feldman et al.**⁽²⁶⁾ study mean preoperative to postoperative changes of MPTA were from 71.4 range (38 -80°) to

87.9 ° range (84-90°). In **Feldman et al.**⁽³¹⁾ mean preoperative MP TA 72.5° range (60-82°) improved to 83.6° postoperative in acute correction group and mean preoperative MPTA 70.9° improved to 85.7° postoperative in gradual correction group.

In this study the mean preoperative of PPTA was 74.2 ° range (66-80°) with SD ± 4.15 improved postoperative to 79.07° range (77 -82°) with SD± 1.69. The present findings seem to be consistent with other research which found in **Feldman et al.**⁽³¹⁾ study mean preoperative of PPTA was 71.8° range (60-83°) improved postoperative to

80.9° range (78-80°). **Coogan *et al.*** ⁽³⁰⁾ inadequately reduced the average sagittal plane procurvatum deformity from 19° to 9° using Ilizarov fixation. **Eidelman *et al.*** ⁽³³⁾ used TSF to correct adolescent Blount mean preoperative mean PPTA was 75.7° range (68-81°), improved postoperation to 78.8° range (77-81°)

In the current study most cases has internal tibial torsion with mean 23.57° with SD ± 4.97 internal tibial torsion range (30° – 15°) improved to 5.36° with SD± 3.08 external tibial torsion range (0° - 10°). **Alekberov *et al.*** ⁽³⁴⁾ used Ilizarov external fixator the preoperative TFA improved from 20.7° internal torsion to 3.5° external torsion postoperatively. **Eidelman *et al.*** ⁽⁹¹⁾ used TSF device with the mean correction of internal tibial torsion 10° performed in six patients with eight tibiae. In **Feldman *et al.*** ⁽²⁶⁾ study six tibiae had clinical internal rotation deformity with preoperative mean of 17.5° to no postoperative clinical evidence of internal rotation.

In this study the mean preoperative of MAD was 31.14 mm with SD ± 7.61 range (18 – 45mm) was significantly improved to mean postoperative 3.64 mm with SD ± 2.13 range (0 – 8 mm). this finding is in agreement with **Gordon *et al.*** ⁽³²⁾ as their method was able to achieve mean decrease of 107 mm in the MAD and in **Feldman *et al.*** ⁽³¹⁾ study mean preoperative to postoperative changes in MAD from 53.9 mm range (31-120 mm) to 1.4 mm range (0-4 mm) in gradual correction group and mean preoperative to postoperative changes in MAD from 64.4mm range (34-102 mm) to 13.9 mm range (2-40 mm) in acute correction group. Also in **Eidelman *et al.*** ⁽³³⁾ study preoperative mean for MAD was 55.8 mm medial to the centre of the knee range (44-77mm) and was corrected to a mean of 4.9mm range (2-11mm).

The duration of the frame fixation in this study was from the time of application to the time of removal averaged 12 weeks with SD± 1.62 (range 8-14weeks) compared to **Gordon *et al.*** ⁽³²⁾ study the mean fixator wear time was approximately 150 days (21.4 weeks). and **Eidelman *et al.*** ⁽³³⁾ used TFS in adolescent Blount disease frames were removed at an average of 12.8 weeks range (12-15 weeks) and **EL-Rosasy and Khanfour** ⁽²⁷⁾ findings which showed that the mean time spent in the fixator was 3.5 months (15 weeks) range (3-4 months) in acute correction of specific group of patient with late onset tibia vara. This result match those observed in study

done by **Feldman *et al.*** ⁽³¹⁾ as the total time that the external fixator was used was similar for the acute correction group with a mean of 12.9 weeks range (8-22weeks) and a mean of 14.3 weeks range (9-24 weeks) for the gradual correction group.

CONCLUSION

Management of adolescent Blount disease by acute correction strategy using a low profile Ilizarov is a safe technique offering excellent results with low incidence of complications.

Low profile Ilizarov is lighter and less bulky so more comfortable for patients than classic Ilizarov external fixation

Acute correction technique can achieve the same result of correction as gradual correction technique in patient with no limb length discrepancy.

Acute correction offers a shorter time in frame as compared to gradual correction with fewer follow-up visits and exposure to radiation.

To our knowledge, there are no long term follow-up studies for series of patients treated by this technique to clarify the superiority of this technique over other techniques in terms of preventing or delaying recurrence or early degenerative changes.

Acute correction of adolescent Blount disease deformity using low profile illizarov technique yields good results with accurate correction of the deformity and no increase in complications rate.

REFERENCES

1. **Sabharwal S (2009):** Current concepts review. Blount disease. *J Bone Joint Surg (Am)*, 91-A:1758-76.
2. **Erlacher P (1922):** Deformierende Prozesse der Epiphysengegend bei Kindern. *ArchOrthop Unfallchir.* ,20:81.
3. **Blount WP (1937):** Tibia vara. Osteochondrosis deformans tibiae. *J Bone Joint Surg (Am)* , 19:1-29.
4. **Langenskiöld A, Riska EB (1964):** Tibia vara (osteochondrosis deformans tibiae). A survey of 21 cases. *J Bone Joint Surg (Am)*,46:1405-20.
5. **Siffert RS, Katz JF (1970):** The intra-articular deformity in osteochondrosis deformans tibiae. *J Bone Joint Surg (Am)*, 52:800-4.
6. **Sabharwal S, Lee J , Zhao C (2007):** Multiplanar deformity analysis of untreated Blount disease. *J Pediatr Orthop.* , 27:260-5.
7. **Hofmann A, Jones RE, Herring JA (1982):** Blount's disease after skeletal maturity. *J Bone Joint Surg (Am)*, 64:1004-9.

8. **Zayer M (1980):** Osteoarthritis following Blount's disease *Int Orthop.* , 4:63-6.
9. **Thompson GH, Carter , Smith CW (1984):** Late-onset tibia vara: A comparative analysis. *J Pediatr Orthop.* , 4:185-94.
10. **Wenger DR, Mickelson M, Maynard JA (1984):** The evolution and histopathology of adolescent tibia vara. *J Pediatr Orthop.* , 4:78-88.
11. **Henderson RC, Kemp GJ , Hayes PR (1993):** Prevalence of late onset tibia vara. *J Pediatr Orthop.* ,13:255-8.
12. **Noonan KJ, Price CT, Sproul JT, Bright RW (1998):** Acute correction and distraction osteogenesis for the malaligned and shortened lower extremity . *J Pediatr Orthop.* ,18 (2) : 178-186.
13. **Golding JSR, McNeil-Smith JD (1963):** Observations on the etiology of tibia vara. *J Bone Joint Surg (Br)*, 45:320-5.
14. **Ingvarsson T, H'agglund G, Ramgren B, Jonsson K, Zayer M (1997):** Long-term results after adolescent Blount's disease. *J Pediatr Orthop.* , 6:153-6.
15. **Kling TF (1987):** Angular deformities of the lower limbs in children. *Orthop Clin North(Am)* ,18 (4) : 513-527.
16. **Thompson GH, Carter (1990):** Late-onset tibia vara (Blount's disease). *Current Concepts. Clin Orthop.* ,225:24-35.
17. **Amer AR, Khanfour AA (2010):** Evaluation of treatment of late onset tibia vara using gradual angulation translation high tibial osteotomy. *Acta Orthop Belg.* ,76 (3) : 360-366.
18. **Price CT, Scott DS, Greenberg DA (1995):** Dynamic axial external fixation in the surgical treatment of tibia vara. *J Pediatr Orthop.* ,15 (2) : 236-243.
19. **Birch JG (2013):** Blount disease. *J Am Acad Orthop Surg* . ,21 (7) : 408-418.
20. **Davidson RS (2011):** The MAC (Multi-Axial Correcting) Monolateral External Fixation System (Biomet/EBI) Technique : An Easier Way to Correct Deformity. *Oper Tech in Orthop.* ,21 : 113-124.
21. **Gilbody J, Thomas G, Ho K (2009):** Acute versus gradual correction of idiopathic tibia vara in children : a systematic review. *J Pediatr Orthop.* ,29 (2) : 110-114.
22. **Probe RA (2003):** lower extremity angular malunion : evaluation and surgical correction. *J Am Acad Orthop Surg* . , 11 (5) : 302-311.
23. **Sakurakichi K, Tsuchiya H, Kabata T, Yamashiro T, Watanabe K, Tomita K (2005):** Correction of juxtaarticular deformities in children using the Ilizarov apparatus. *J Orthop Sci.* ,10 : 360-366.
24. **Smith SL, Beckish ML, Winters SC, Pugh LI, Bray EW (2000):** Treatment of late-onset tibia vara using afghan percutaneous osteotomy and orthofix external fixation. *J Pediatr Orthop.* , 20 (5) : 606-610.
25. **Stanitski DF, Dahl M, Louie K, Grayhack J (1997):** Management of late-onset tibia vara in the obese patient by using circular external fixation. *J Pediatr Orthop.* , 17 (5) : 691-694.
26. **Feldman DS, Madan SS, Koval KJ, van Bosse HJ, Bazzi J, Lehman WB (2003):** Correction of tibia vara with six axis deformity analysis and the Taylor Spatial Frame.*J Pediatr Orthop.* , 23 (3) : 387-391.
27. **El-Rosasy M, Khanfour A (2014):** Tibia vara, acute correction strategy :proper case selection and a simple external fixation technique. *Actaorthop Belg.* , 80, 241-250
28. **Paley D, Tetsworth (1992):** Mechanical axis deviation of the lower limbs. Preoperative planning of uniapical angular deformities of the tibia or femur. *Clin Orthop Relat Res.* ,280:48-64.
29. **Akyuz E, Braun JT, Brown NA, Bachus KN (2006):** Static versus dynamic loading in the mechanical modulation of vertebral growth. *Spine* , 31(25):E952-8.
30. **Coogan PG, Fox JA, Fitch RD (1996):** Treatment of adolescent Blount disease with the circular external fixation device and distraction osteogenesis. *J Pediatr Orthop.* ,16:450-4.
31. **Feldman DS, Madan SS, Ruchelsman DE, Sala DA, Lehman WB (2006):** Accuracy of correction of tibia vara : acute versus gradual correction. *J Pediatr Orthop.* , 26 (6) : 794-798.
32. **Gordon JE, Heidenreich FP, Carpenter CJ, Kelly-Hahn J,Schoenecker PL (2005):** Comprehensive treatment of late-onset tibia vara. *J Bone Joint Surg (Am)*, 87(7):1561-1570.
33. **Eidelman M, Bialik V, Katzman A (2008):** The use of the Taylor spatial frame in adolescent Blount's disease: Is fibular osteotomy necessary? *J Child Orthop.* , 2(3):199-204.
34. **Alekberov C, Shevtsov VI, Karatosun V, Gunal I, Alici E (2003):** Treatment of tibia vara by the Ilizarov method.. *Clin Orthop Relat Res.* , (409) : 199-208.
35. **Dahl MT, Gulli B, Berg T (1994):** Complications of limb lengthening. A learning curve. *Clin Orthop Relat Res.* , 301:10-18.